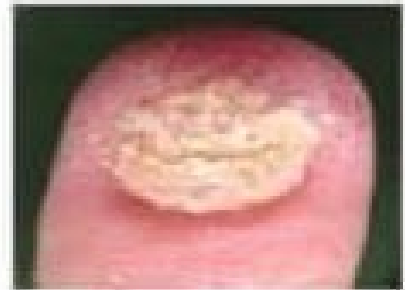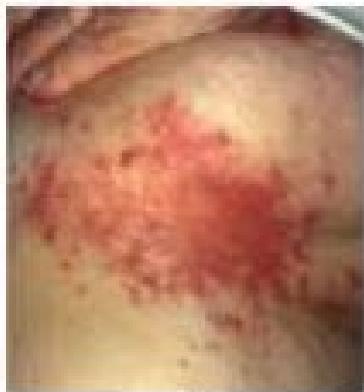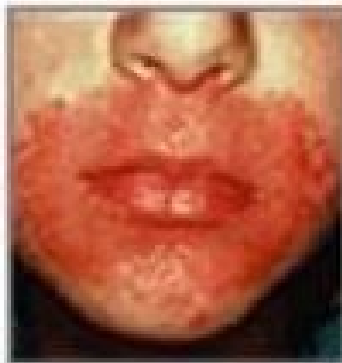
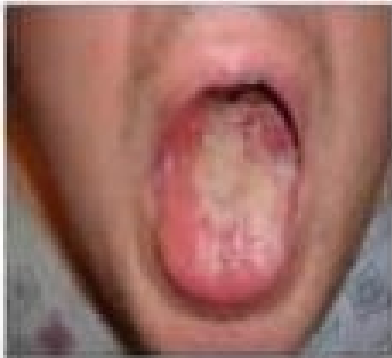


On
Skin
Mouth
Nail
Vulvovaginitis



18

Cutaneous mycoses

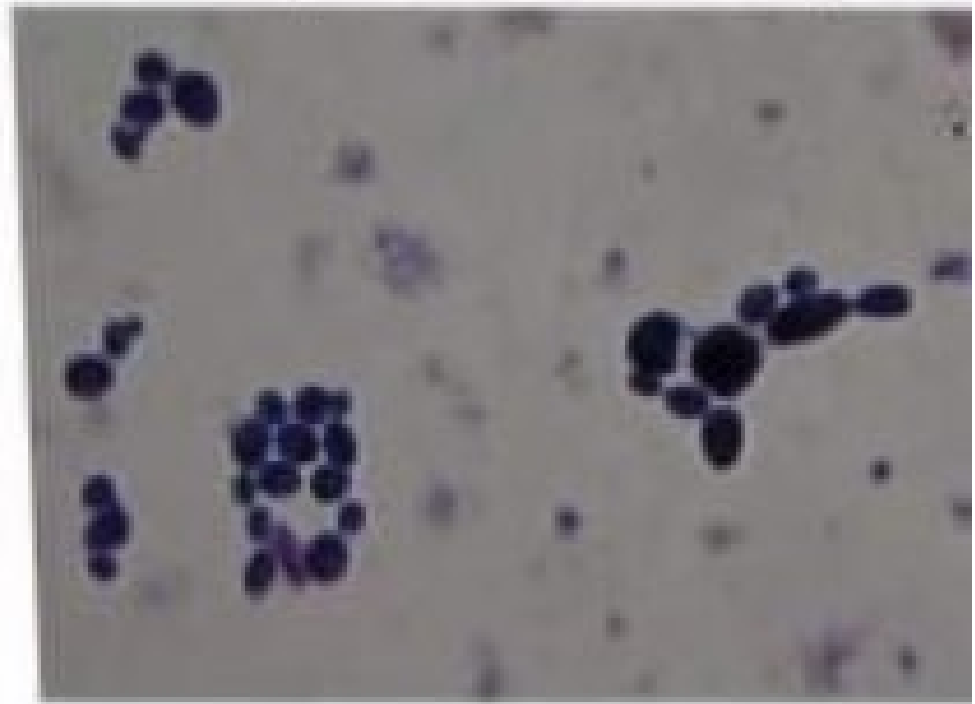
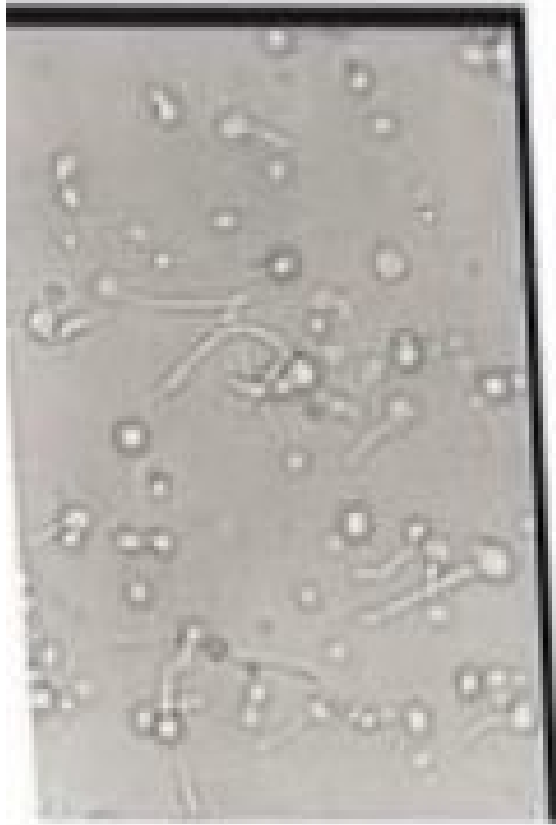C. Albicans



15 of 18



G+ stain



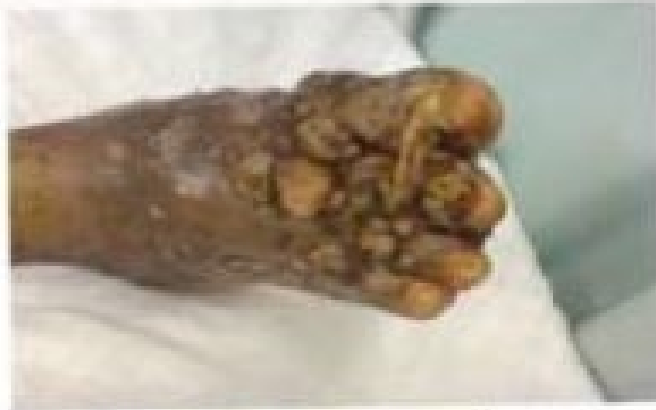Candidiasis



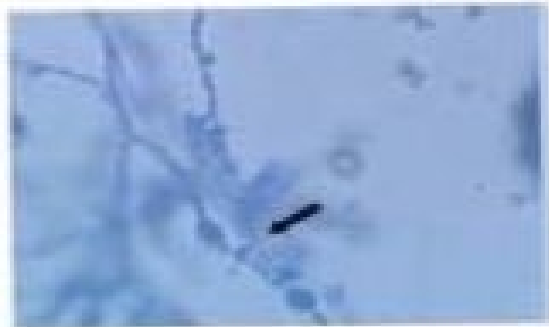
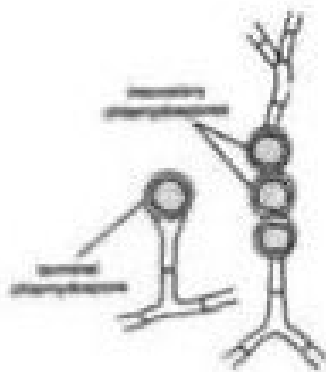
14

of 18





Madura foot



Madurella mycetomatis with intercalary chlamydospores

Sub cutaneous mycoses

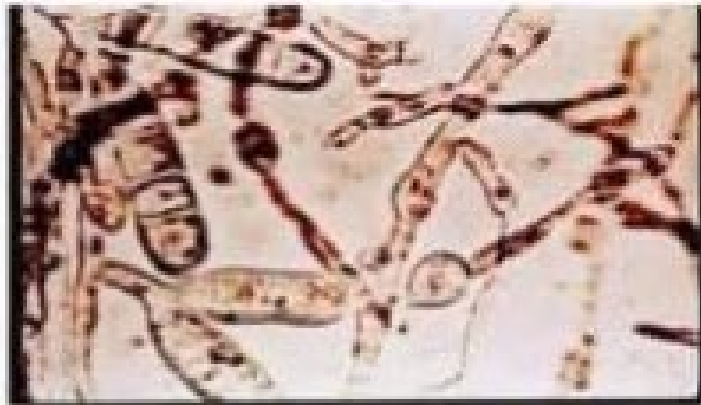Caused by *madurella mycetomatis*



17 of 18



Epidermophyton floccosum



Microscopic image of Epidermophyton floccosum hyphae showing characteristic double-septate structure.

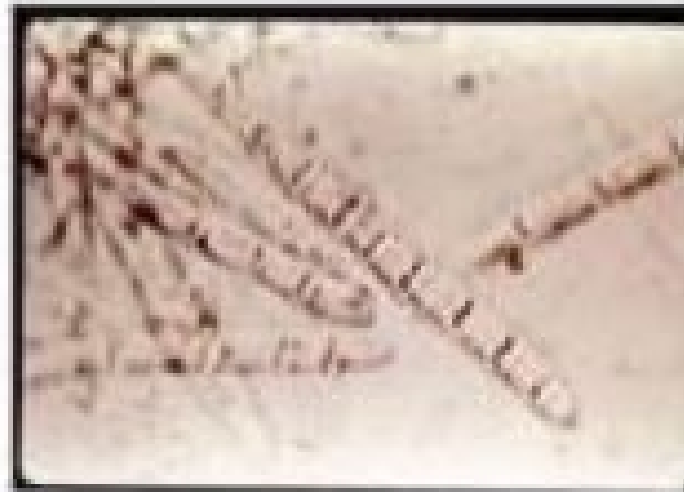
نوع من انواع الفطريات



13 of 18



Microsporium and Trichophyton species



Microsporium:
Thick wall spindle shape
multicellular

Trichophyton:
Large smooth thin wall
septa, pencil-shaped

فطريات
انواعهم



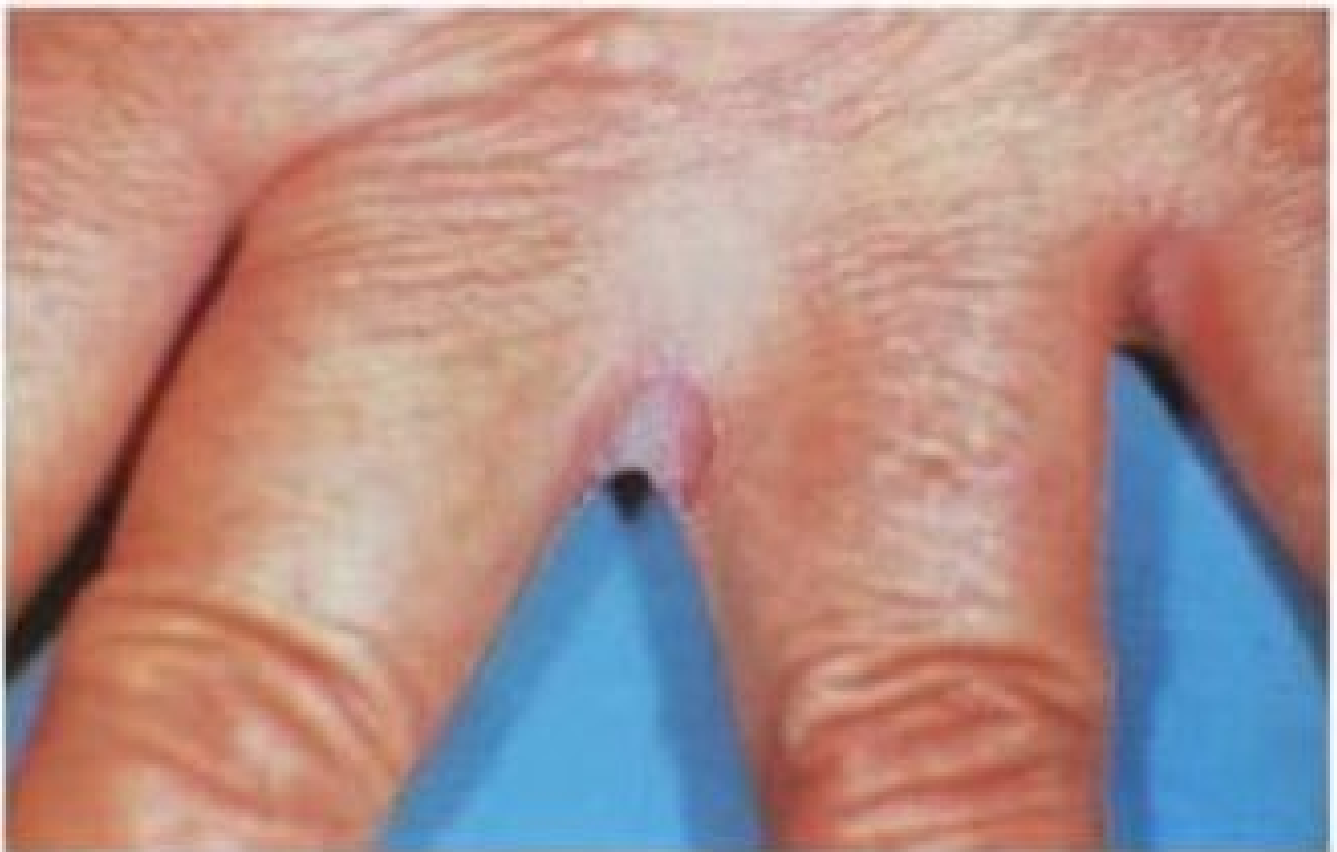12

of 18

P



Candida finger web erosion: related to fatness , occupation etc.





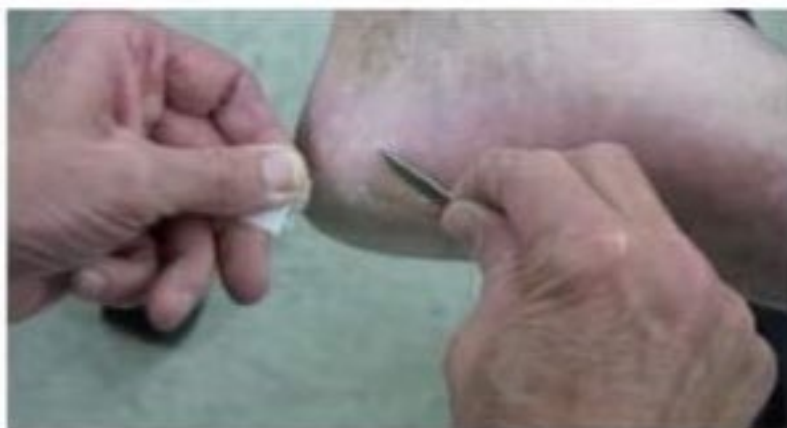Meeting in 'MSS Module A (...4+3+2+1 الشعب

Join to share content from this device

Join

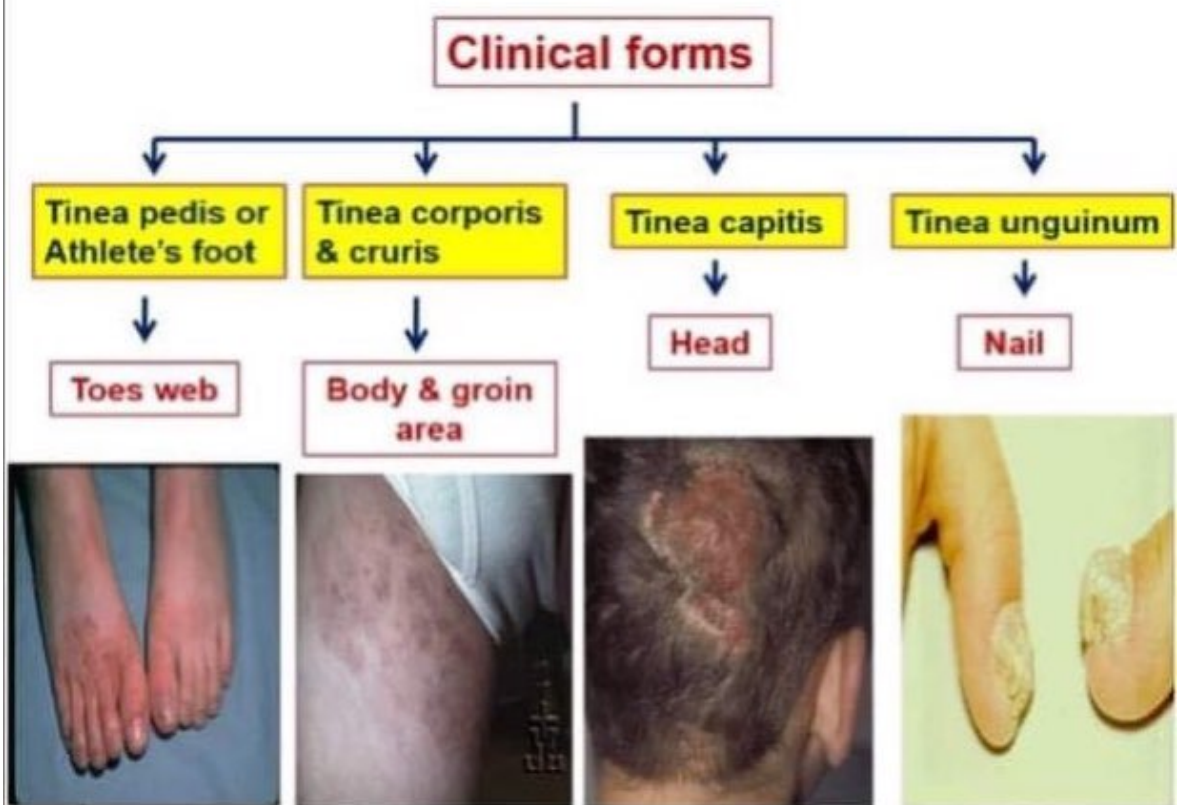

Mutah mss lab.pptx



11 of 18





Cutaneous mycoses



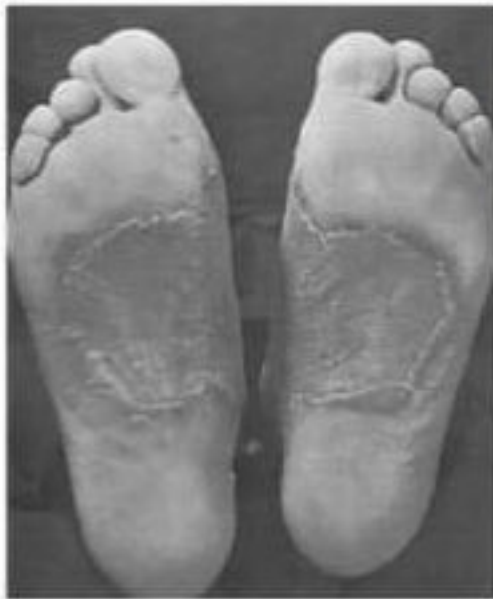Meeting in 'MSS Module A (...4+3+2+1 الشعب

Join to share content from this device

Join



Mutah mss lab.pptx



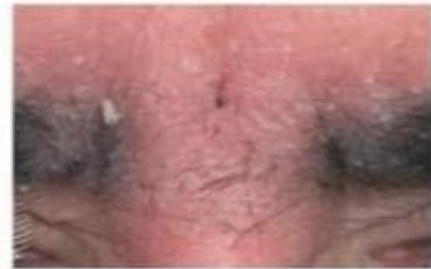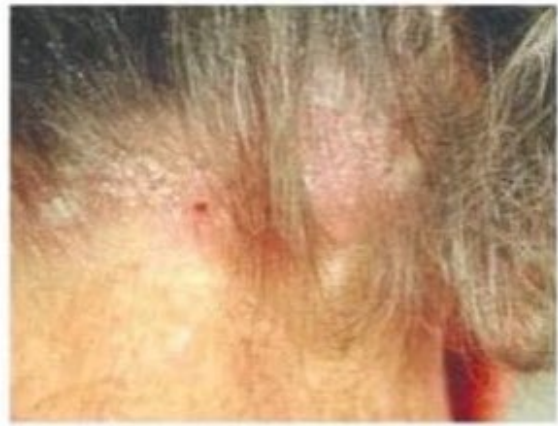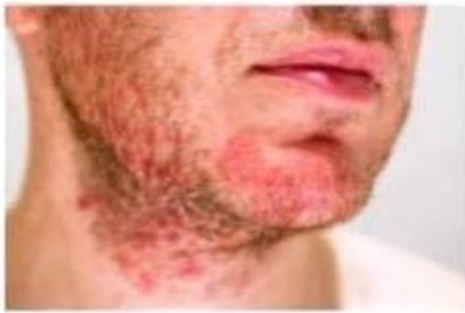- Dermatophytes of the soles
- *Trichophyton mentagrophytes*



10

of 18





Seborrheic dermatitis

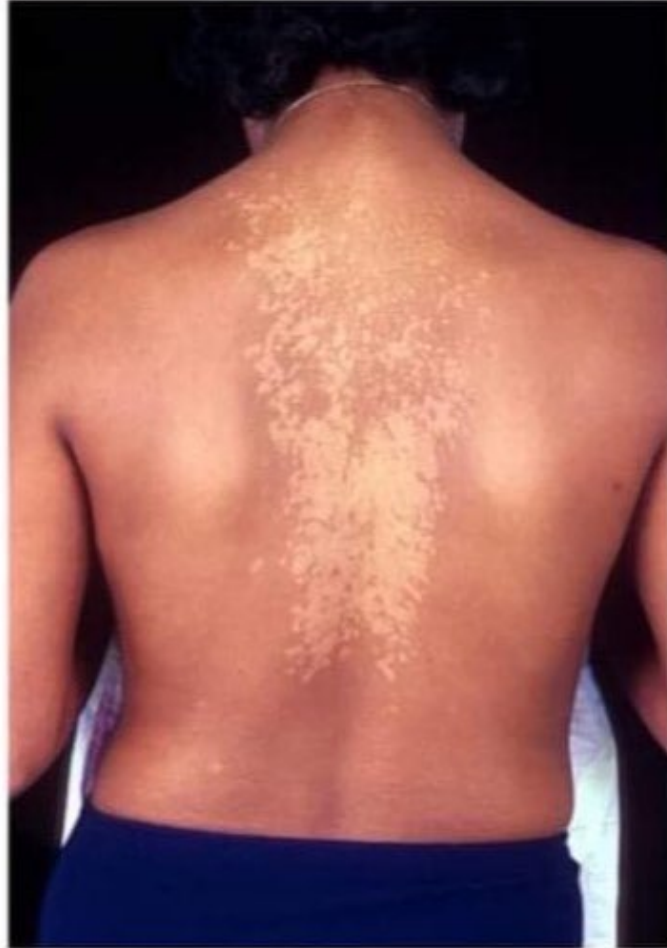Caused by m. Furfur



6

of 18





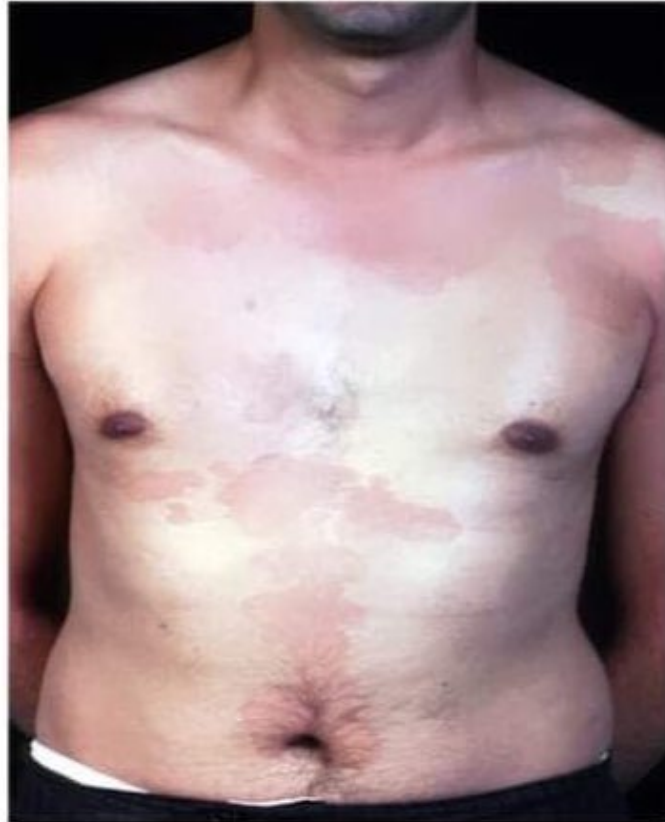Pityriasis versicolor



4

of 18

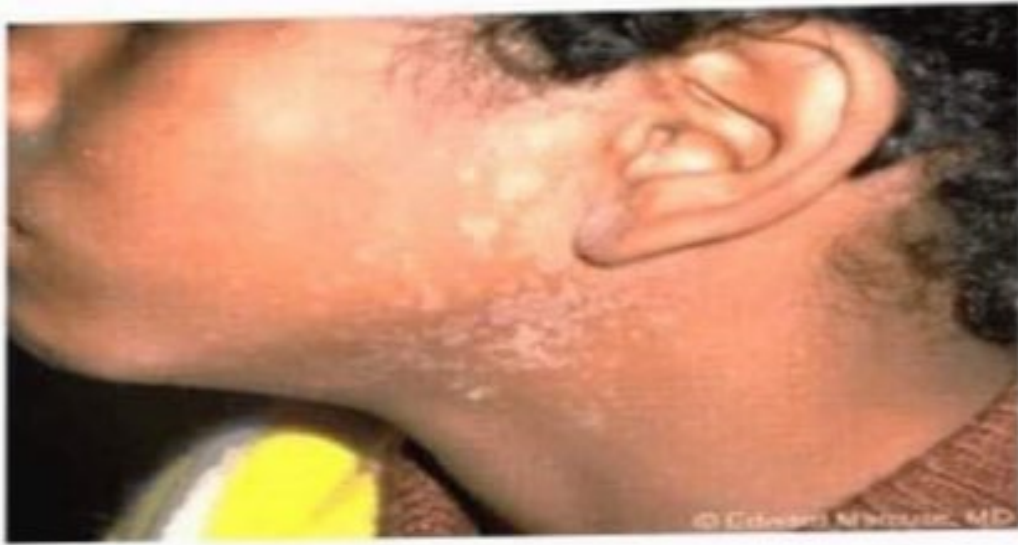



Pityriasis versicolor

< > 3 of 18





Pityriasis versicolor

**Caused by m. Furfur m.
Globosa**

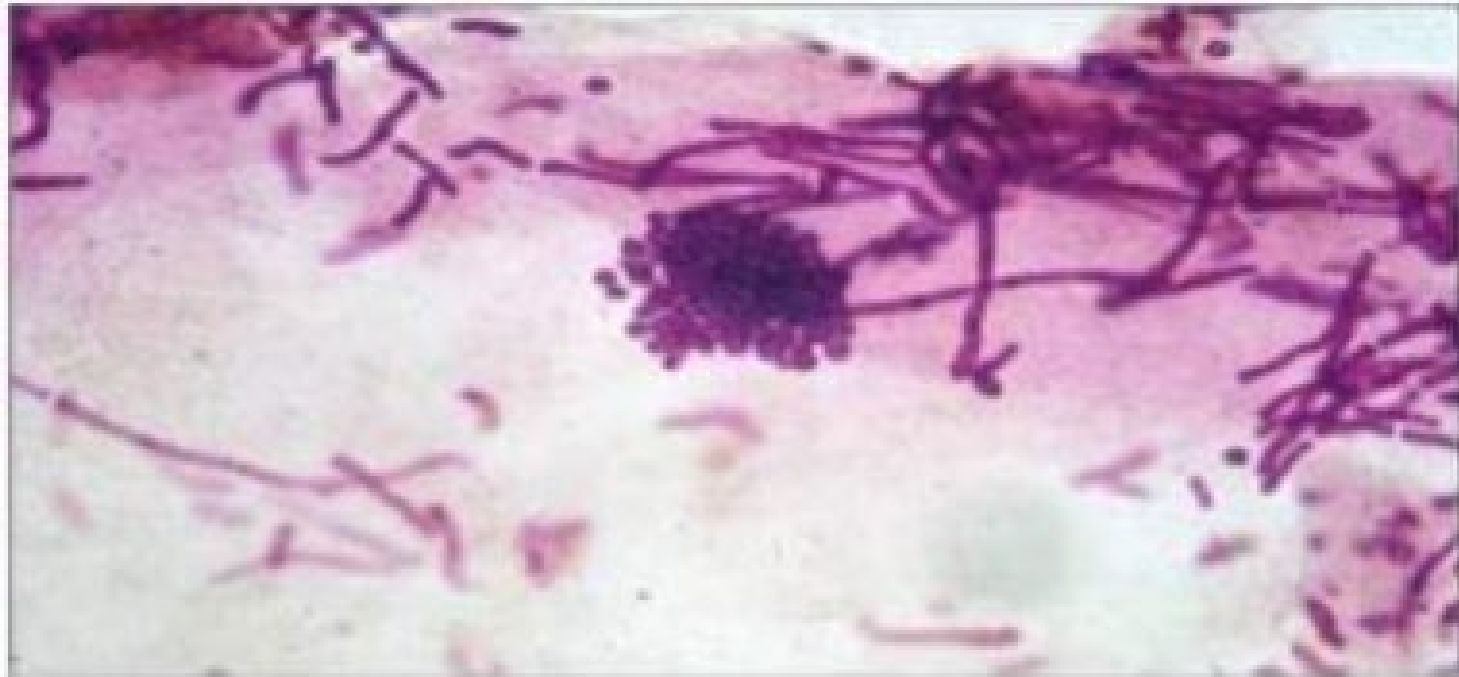**Non itchy
Hypo or Hyper pigmented**



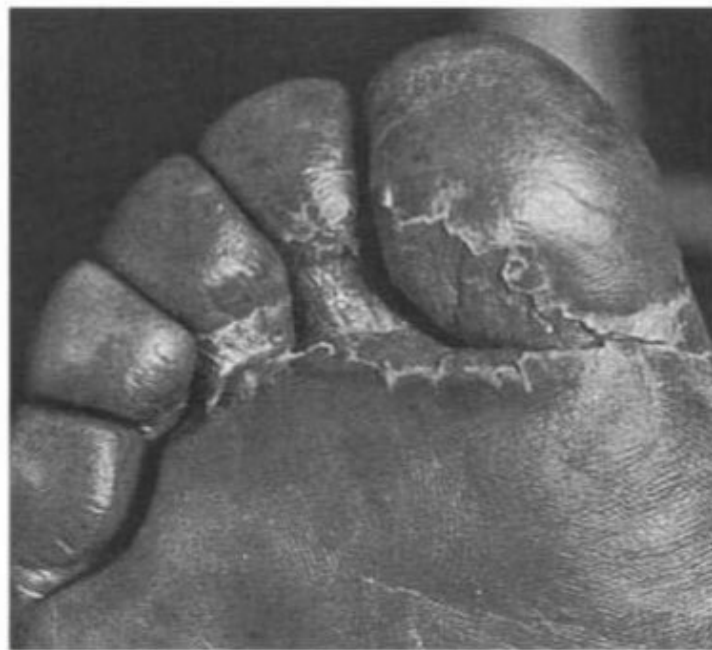2

of 18





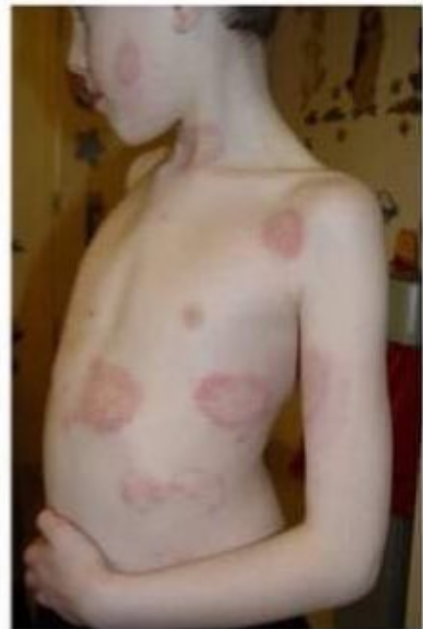***Malassezia furfur* is a lipophilic yeast showing short thick septate hyphae and clusters of budding yeast cells.**



- Tinea pedis showing interdigital scalping
- *T. mentagrophytes*

Cutaneous mycoses
Caused by dermatophytes

Tinea corporis



Ring like lesion