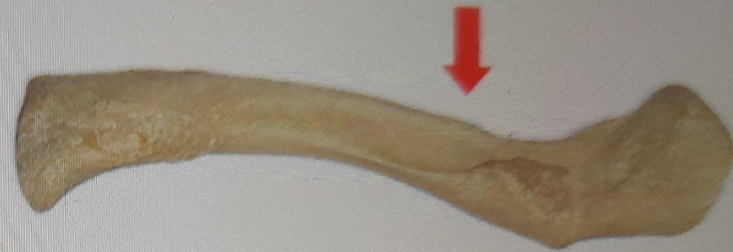
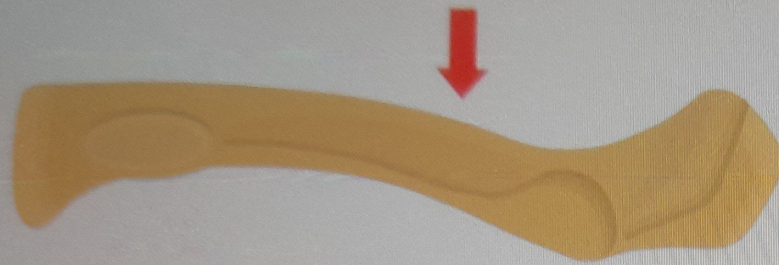


Is this an inferior or superior view of the clavicle?



Illustration

Real Bone

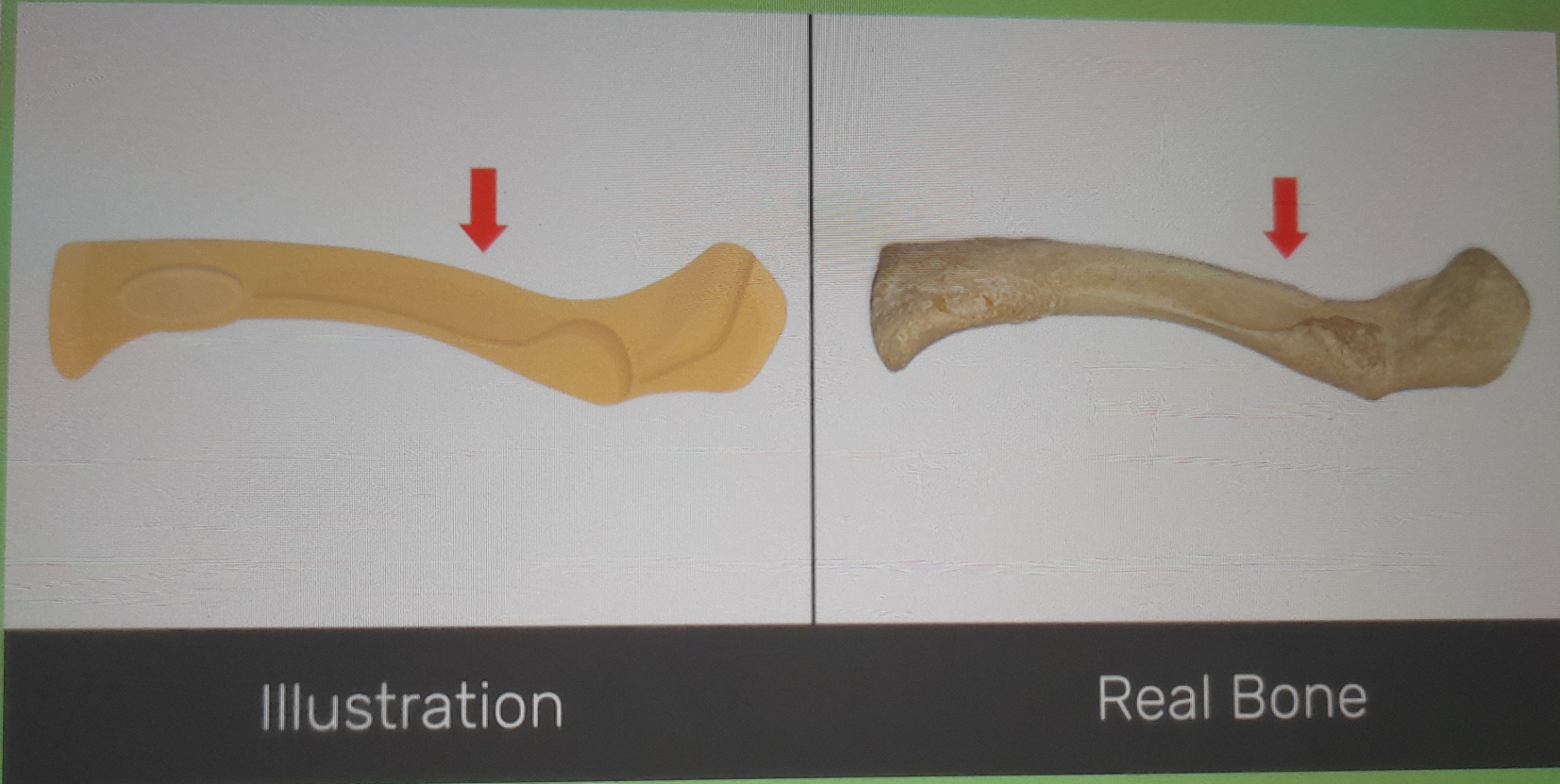


Superior



Inferior

Correct!



Is this an inferior or superior view of the clavicle?

Your answer: Inferior

Next

Is this a right or left clavicle?



Illustration

Real Bone

Left

Right

Correct!



Illustration




Real Bone

Is this a right or left clavicle?

Your answer: Left

Next



Illustration


Real Bone

Acromial or lateral end (*extremitas acromialis*)

Sternal or medial end (*extremitas sternalis*)

Conoid tubercle (*tuberculum conoideum*)

Correct!



Illustration



Real Bone

Name of the bone

Your answer: Conoid tubercle (tuberculum conoideum)

Next

Name of the bone



Illustration

Real Bone



Sternal or medial end (*extremitas sternalis*)

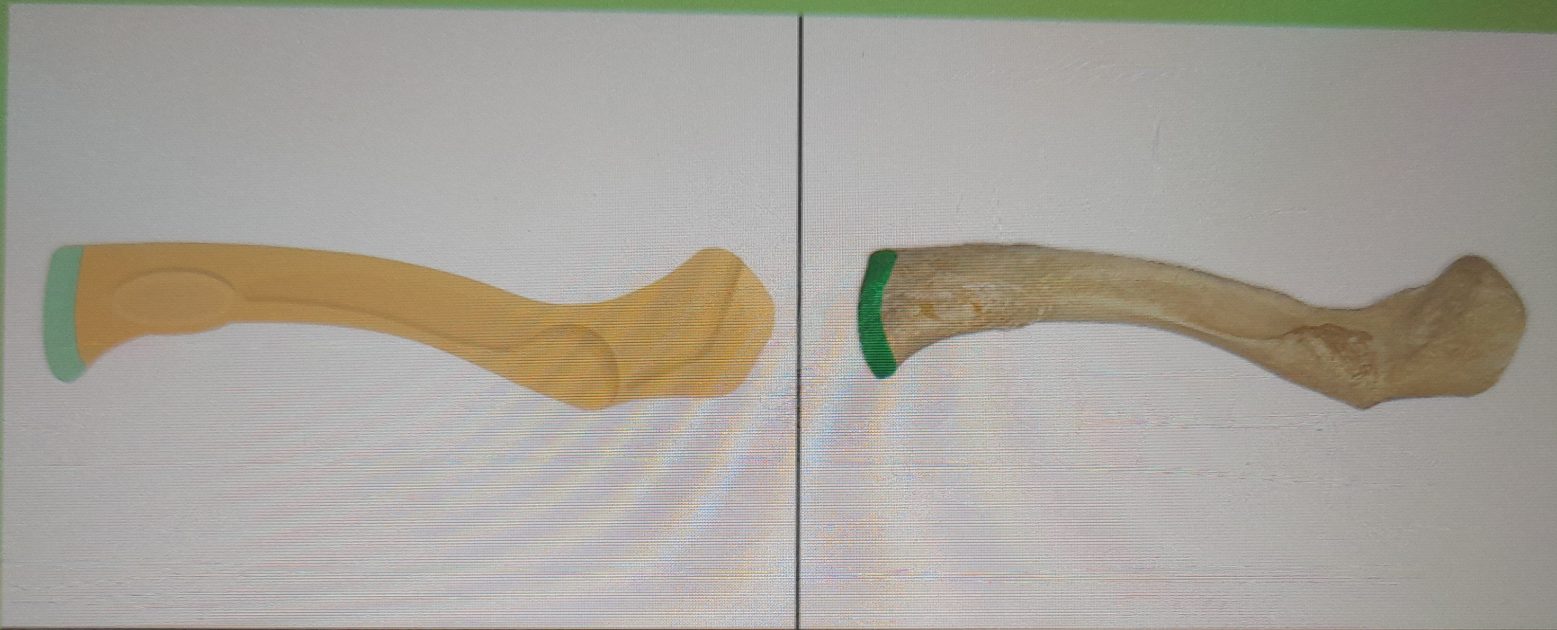


Acromial or lateral end (*extremitas acromialis*).



Costal tuberosity (*impressio ligament costoclavicularis*).

Correct!



Illustration


Real Bone

Name of the bone

Your answer: Sternal or medial end (extremitas sternalis)

Next

Name of the bone



Illustration

Real Bone

Subclavian groove or sulcus (sulcus musculi subclavii)

Costal tuberosity (impressio ligament costoclavicularis)

Acromial or lateral end (extremitas acromialis)

Correct!



Illustration



Real Bone

Name of the bone

Your answer: Subclavian groove or sulcus (sulcus musculi subclavii)

Next

Name of the bone



Illustration

Real Bone

Subclavian groove or sulcus (sulcus musculi subclavii)

Acromial or lateral end (extremitas acromialis)

Costal tuberosity (impressio ligament costoclavicularis)

Correct!



Illustration



Real Bone

Name of the bone

Your answer: Acromial or lateral end (extremitas acromialis)

Next



Illustration



Real Bone

- Trapezoid line or ridge (linea trapezoid)
- Costal tuberosity (impressio ligament costoclavicularis)
- Subclavian groove or sulcus (sulcus musculi subclavii)

Correct!



Illustration

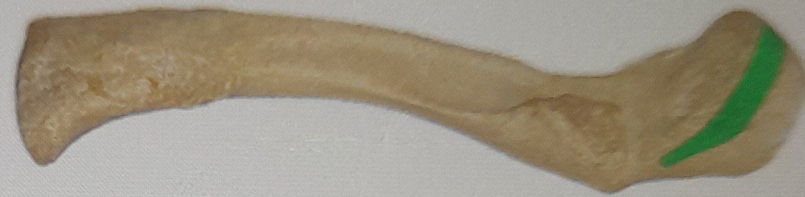

Real Bone

Name of the bone


Your answer: Costal tuberosity (impressio ligament costoclavicularis)

Next




Illustration


Real Bone



Trapezoid line or ridge (linea trapezoid)



Sternal or medial end (extremitas sternalis)



Costal tuberosity (impressio ligament costoclavicularis)

Correct!



Illustration



Real Bone

Name of the bone

Your answer: Trapezoid line or ridge (linea trapezoid)

Next