

وسهلا

أهلا



الأستاذ الدكتور يوسف حسين

أستاذ التشريح وعلم الأجنة - كلية الطب - جامعة الزقازيق - مصر

رئيس قسم التشريح و الأنسجة و الأجنة - كلية الطب - جامعة مؤتة - الأردن

دكتورة من جامعة كولونيا المانيا

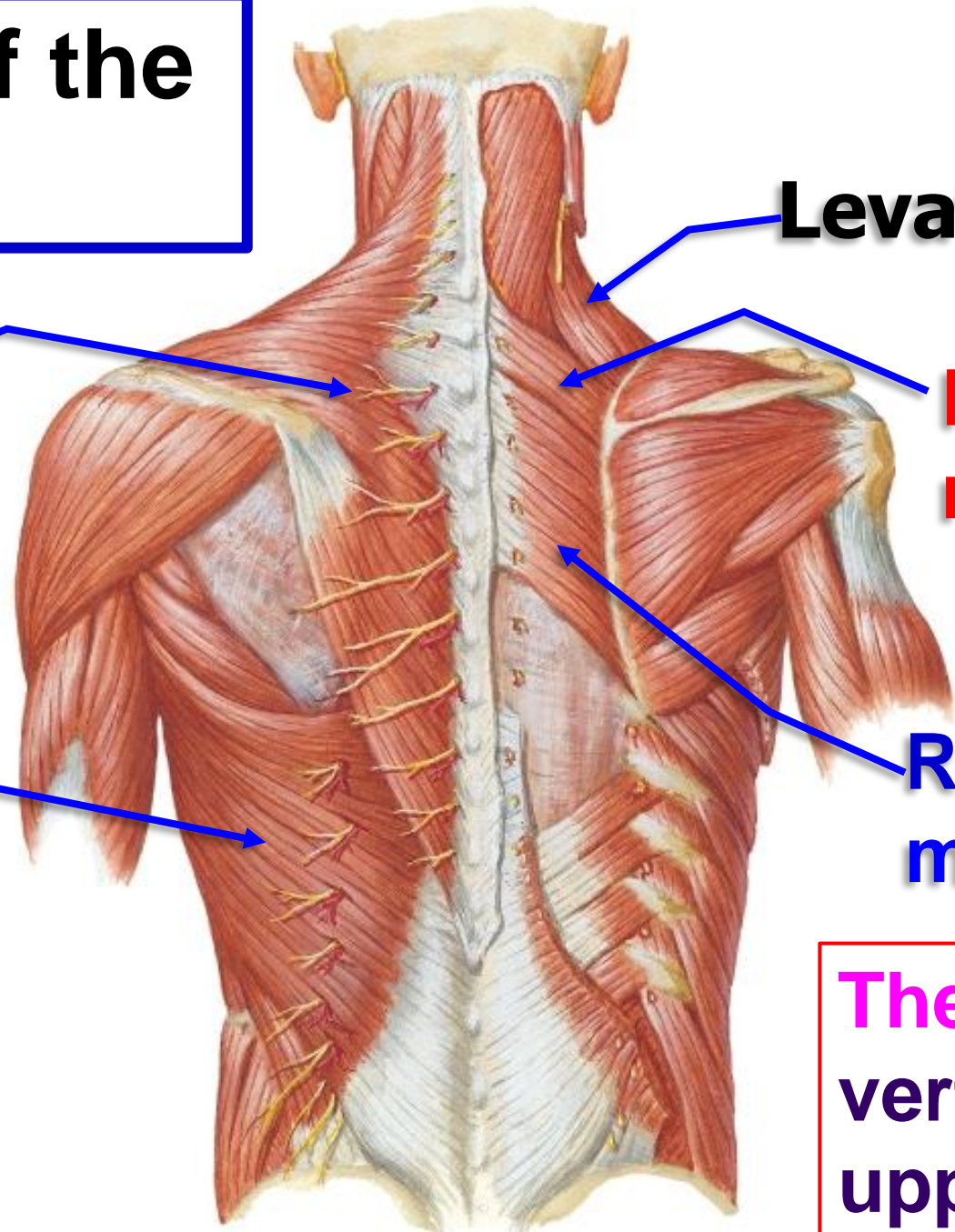
Dr. Youssef Hussein Anatomy اليوتيوب

جروب الفيس د. يوسف حسين (استاذ التشريح)



**Muscles of
the back**

Muscles of the back



Levator scapula

Trapezius

Rhomboideus minor

Latissimus dorsi

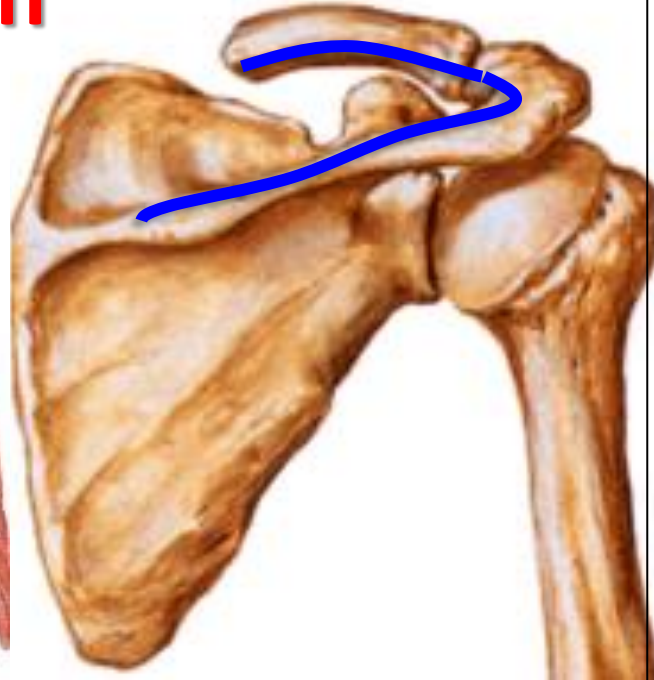Rhomboideus major

The muscles connect vertebral column with upper limb



Trapezium

Origin



Insertion

• Trapezius شبه منحرفة

** Origin:

- 1- **Back of the skull**; external occipital protuberance and medial 1/3 of superior nuchal line.
- 2- **Back of the neck**; ligamentum nuchae and spine of the 7th cervical.
- 3- **Back of the thorax**; all thoracic spines.

** Insertion:

- 1- **Upper fibers** into posterior border of the lateral third of the clavicle.
- 2- **Middle fibers** into medial border of the acromion of the scapula.
- 3- **Lower fibers** into upper lip of the spine of the scapula.

**** Nerve supply (double)**

1- Motor; spinal part of accessory nerve.

2- Sensory (Proprioceptive sensation) from the cervical plexus.

**** Actions:**

1. Upper fibers elevate the scapula.

2. Middle fibers retract the scapula.

3. Lower fibers Depress the scapula.

4. Middle and lower fibers Abduction of the arm

more than 90 degree (with lower 5 digitations of the serratus anterior).

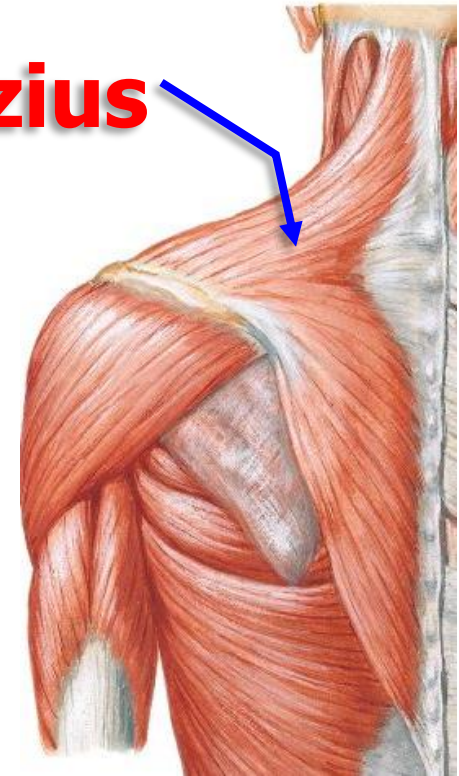
N.B; It is the **only muscle of upper limb**

a- Arises from the skull.

b- Not supplied by the brachial plexus.

- **Wasting of the muscles leading to loss the normal lateral slope of the neck with drop shoulder on affected side**

Trapezius





**Latissimus
dorsi**

• Latissimus Dorsi

** Origin:

1- From lower 6 thoracic spines under cover of the trapezius.

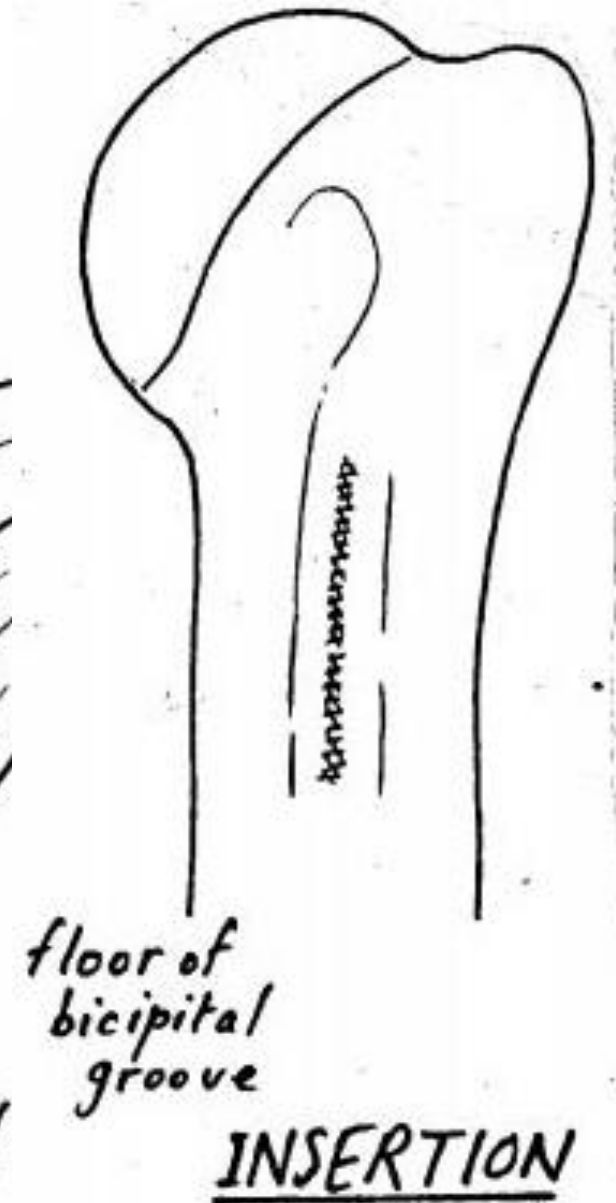
2- Lumbar fascia.

3- Posterior part of the outer lip of the iliac crest.

4- The lower 3 ribs.

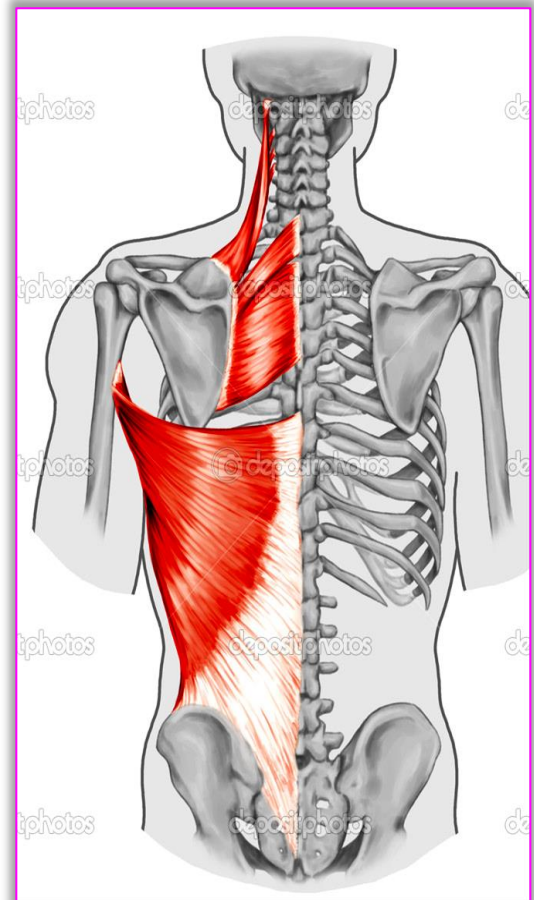
5- The back of the inferior angle of the scapula.

** **Insertion:** into the floor of the bicipital groove of the humerus.



- **Latissimus Dorsi**

- ❖ **Nerve supply:** nerve to latissimus dorsi (thoracodorsal nerve) from posterior cord of brachial plexus.
- ❖ **Actions:**
- ❖ Adduction, extension and medial rotation of the arm (as teres major) **Used in Swimming**
- ❖ It pulls the trunk towards the arm used in **climbing and Gymnastics** with pectoralis major.
- ❖ It assists in deep expiration (**cough**).



- ❖ The only muscles of upper limb has pelvic attachment
- ❖ Accessory muscle of expiration
- ❖ It has triple relations to teres major (it lies behind, below and finally in front).





**Deep muscles
of the back**

- **Levator Scapulae**

** **Origin:** transverse processes of **C1-C4**

** **Insertion,** dorsal surface of medial border of scapula from superior angle to the spine.

** **Nerve supply (double):**

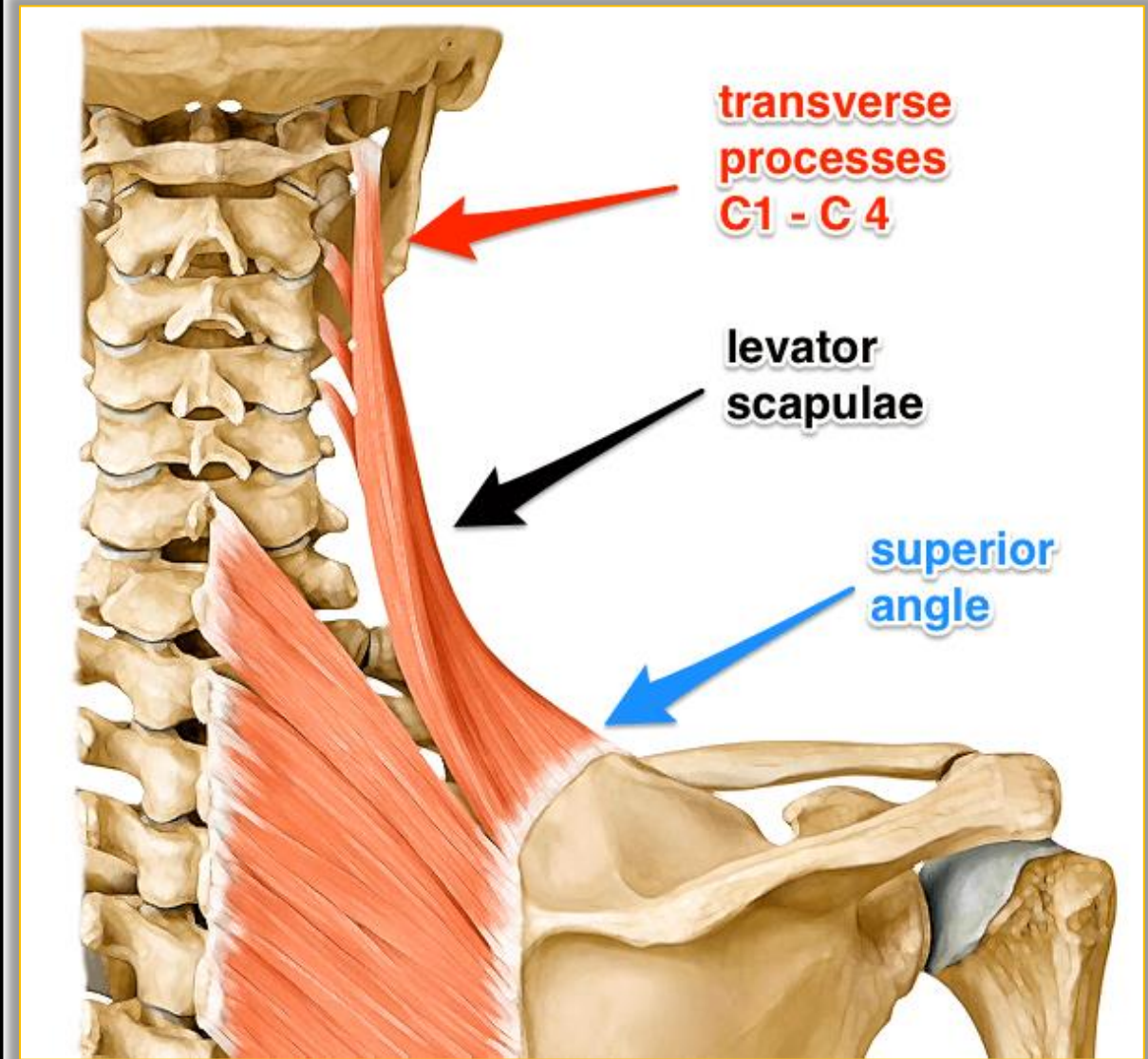
a- Dorsal scapular nerve (nerve to rhomboideus C5).

b- Nerve to levator scapulae from cervical plexus (C3&4)

** **Actions:**

1- Elevates the scapula.

2- Tilts the neck to the same side when shoulder is fixed.



- **Rhomboideus Minor**

** **Origin:** From the lower part of the ligamentum nuchae, spines of **C7 - T1**.

** **Insertion:** dorsal aspect of medial border of scapula opposite root of spine.

- **Rhomboideus Major**

** **Origin:** thoracic spines of **T 2, 3, 4, 5**.

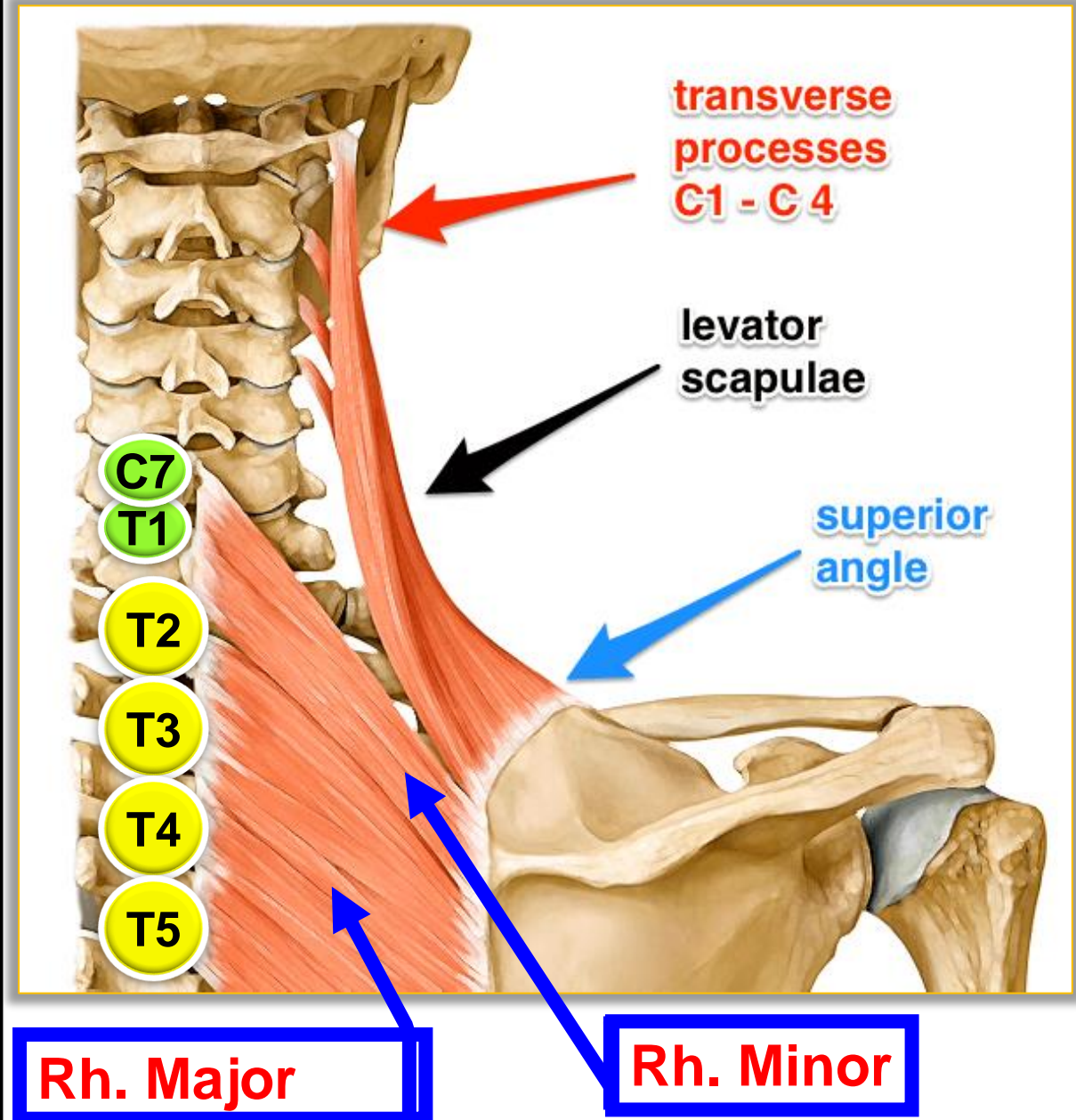
** **Insertion;** dorsal aspect of medial border of scapula from spine to inferior angle.


- **Nerve supply**

- **Dorsal scapular nerve** (nerve to rhomboideus C5).

- **Action of Rhomboideus Minor and major**

- Retraction of the scapula.





Thank You

Questions