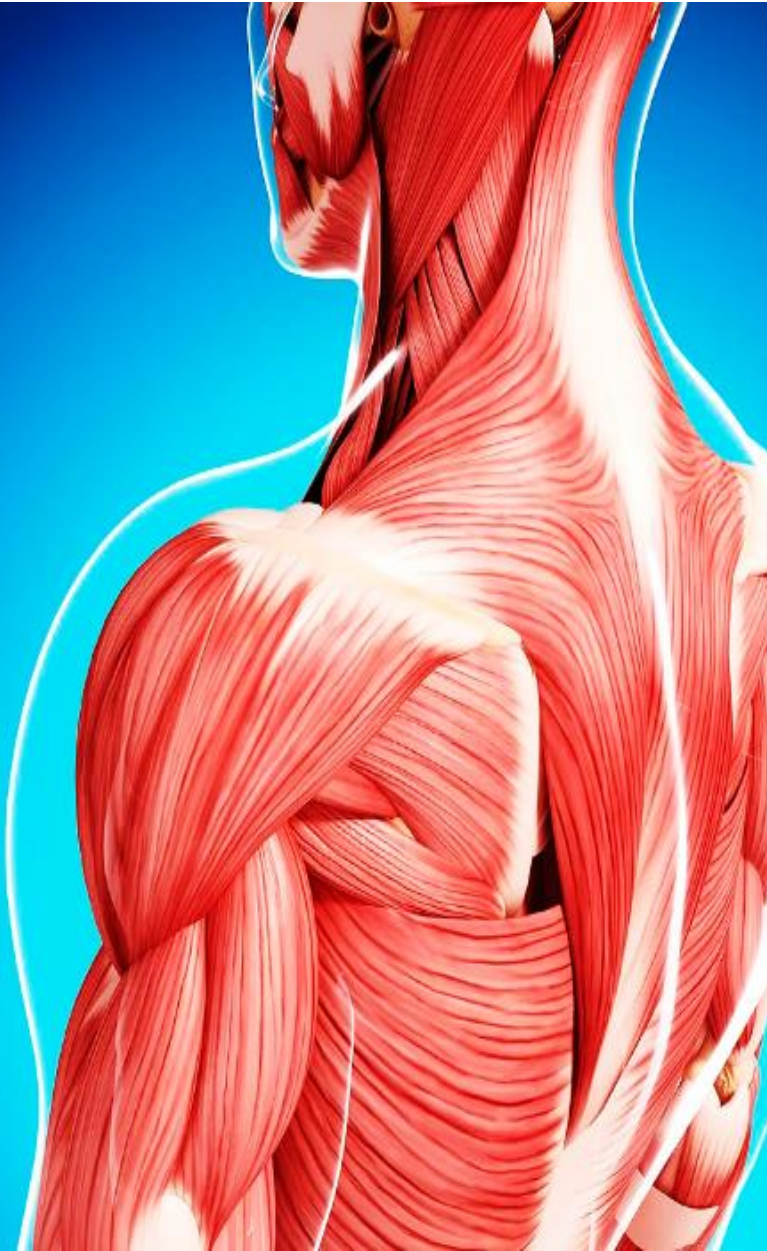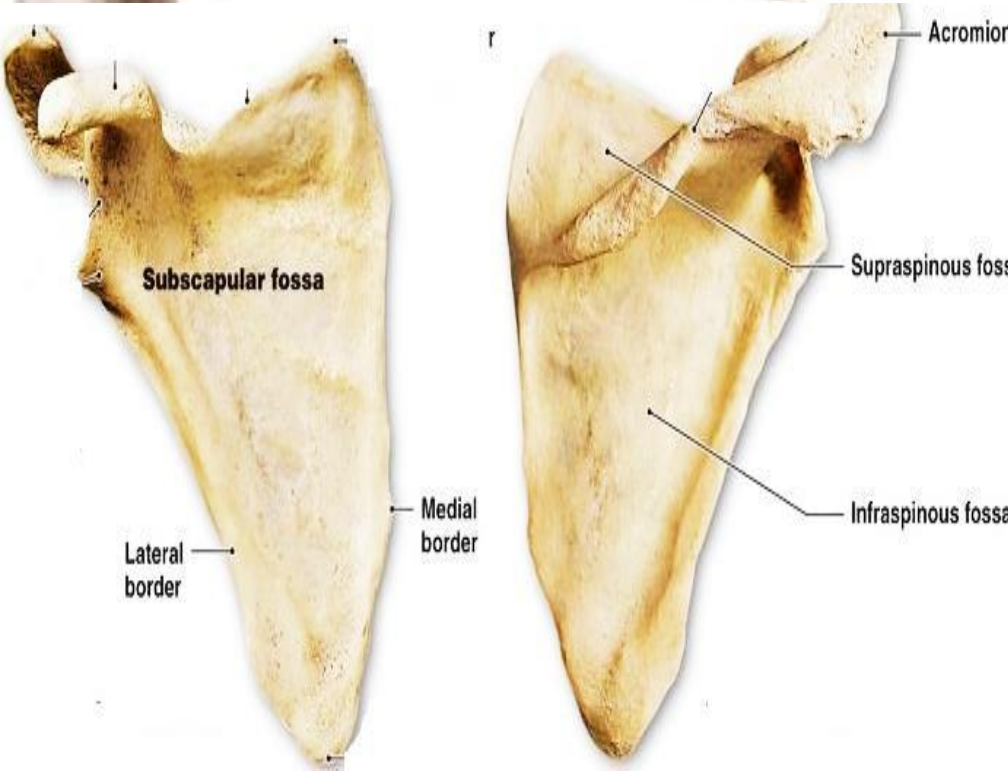

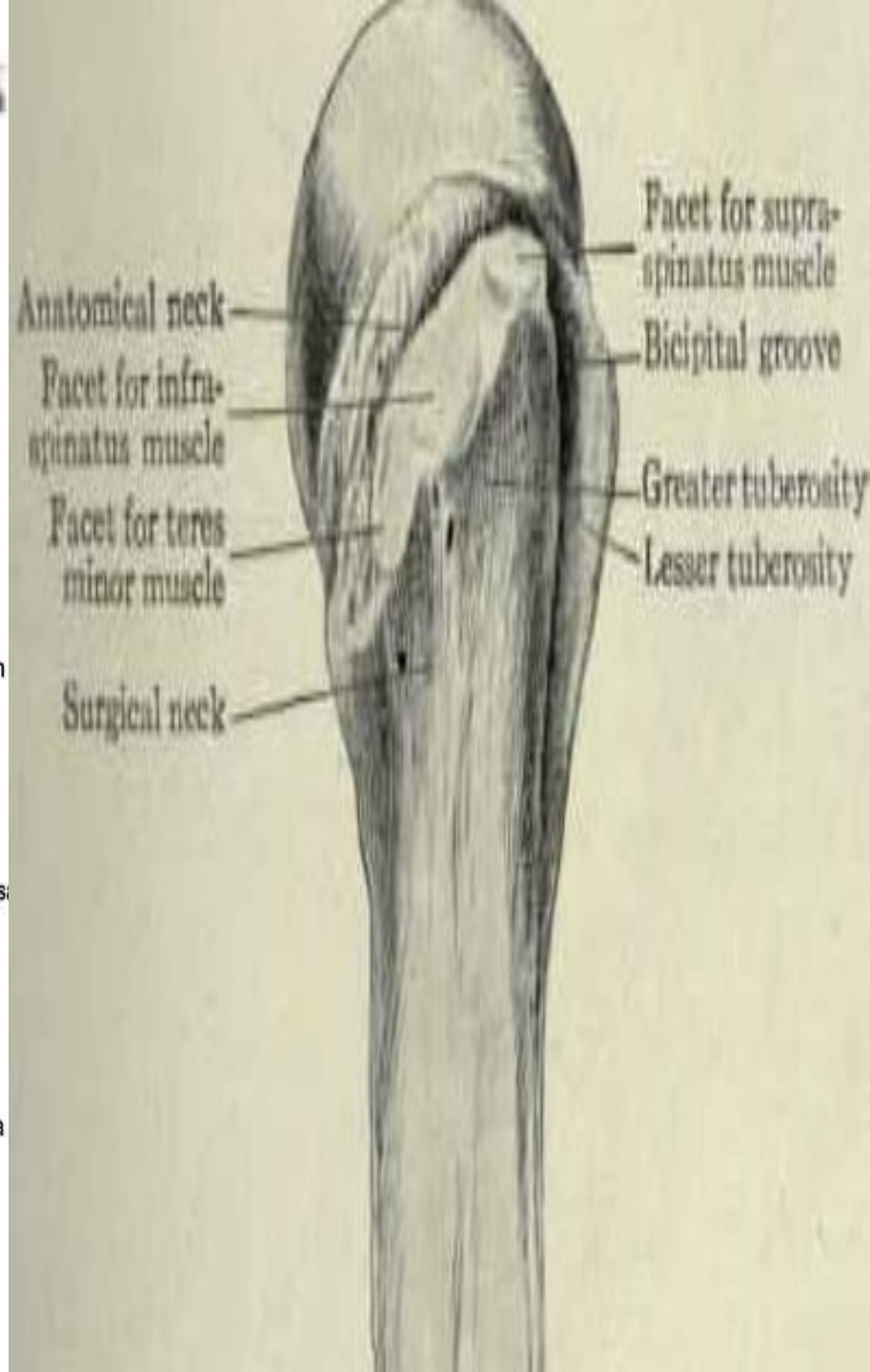
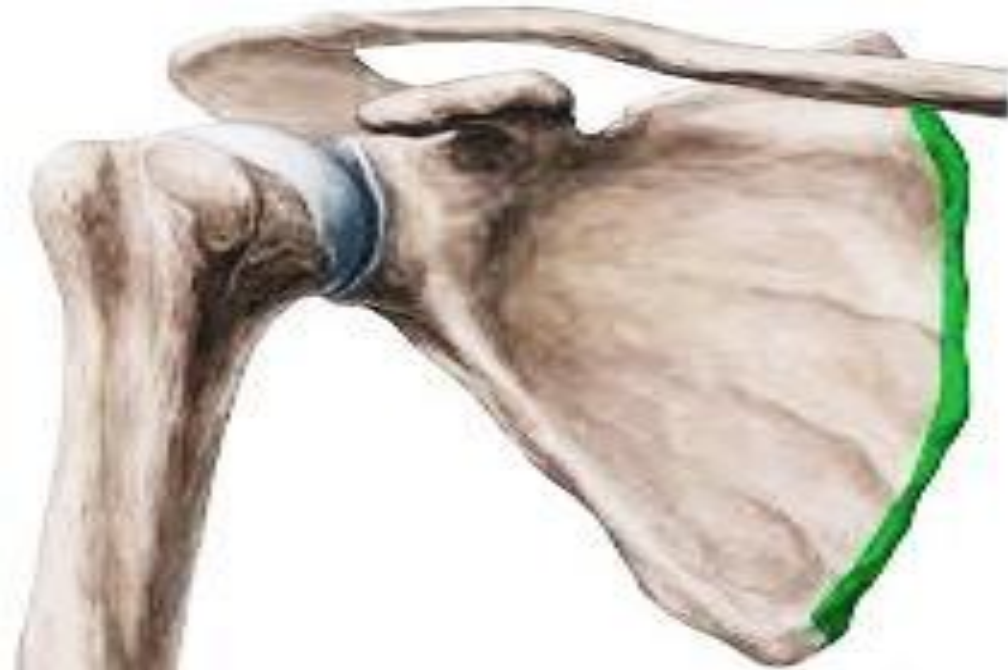SHOULDER REGION



BY
DR ABULMAATY MOHAMED
ASSISTANT PROFESSOR
ANATOMY & EMBRYOLOGY
MUTAH UNIVERSITY



SHOULDER REGION

SUBSCAPULARIS

Origin :

subscapular fossa

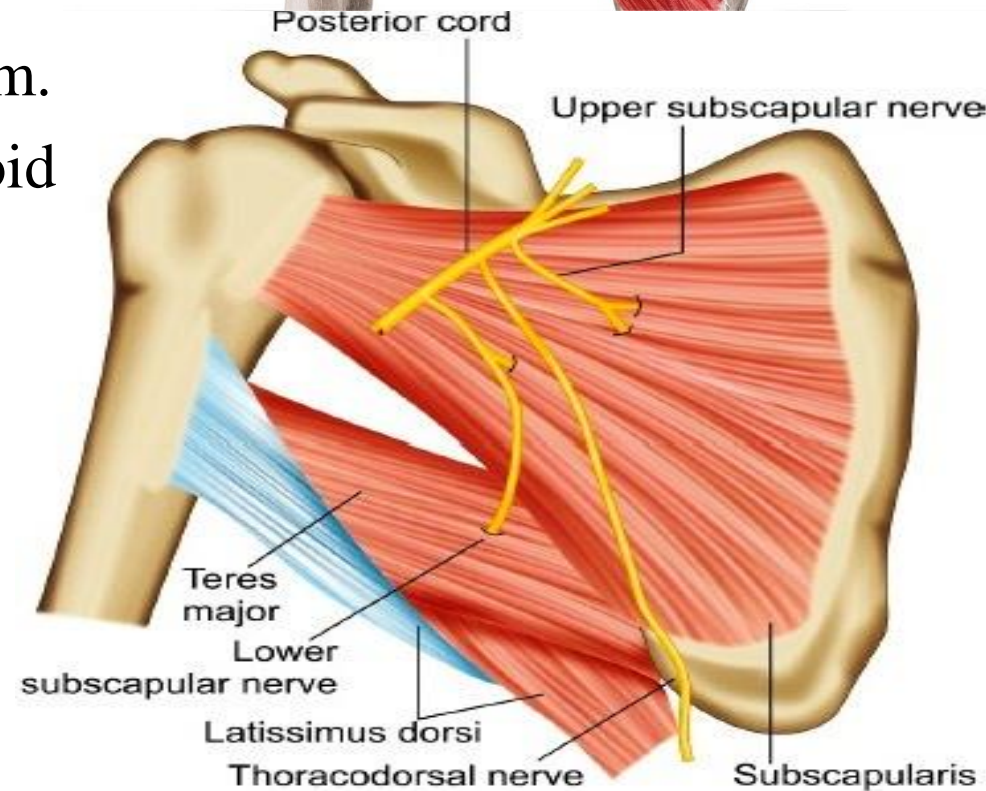
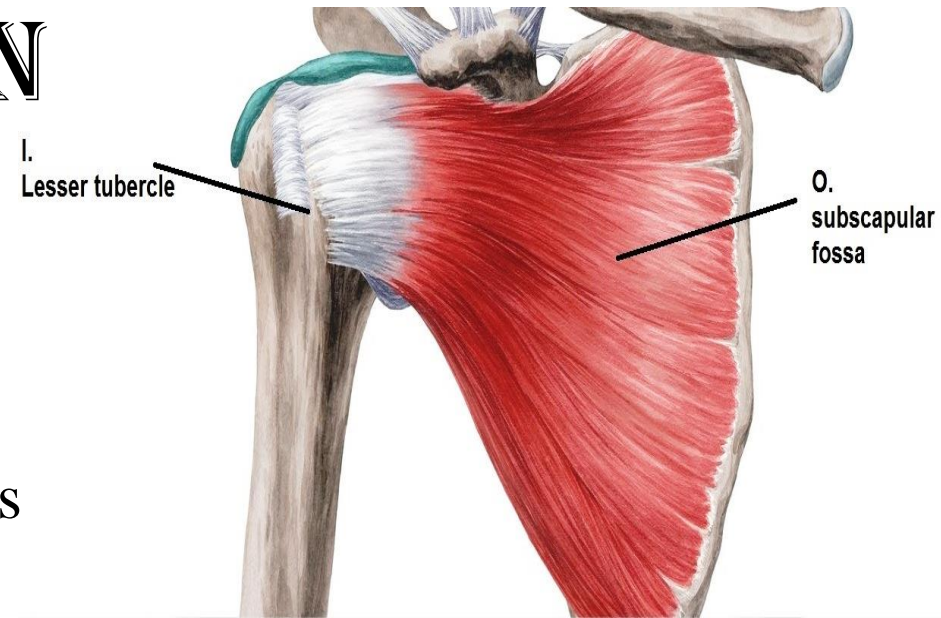
Insertion: Lesser tubercle of humerus

Action :

- Adduction & medial rotation of arm.
- stabilize head of humerus in glenoid cavity as a Rotator cuff muscle?

Nerve supply:

Upper & lower subscapular nerves



SHOULDER REGION

SUPRASPINATUS

Origin :

supraspinous fossa

Insertion:

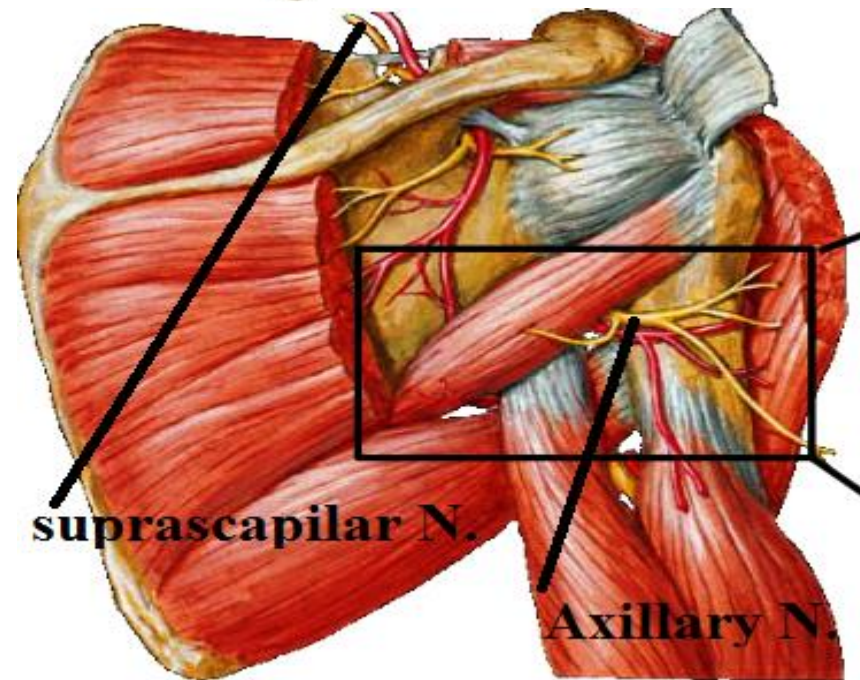
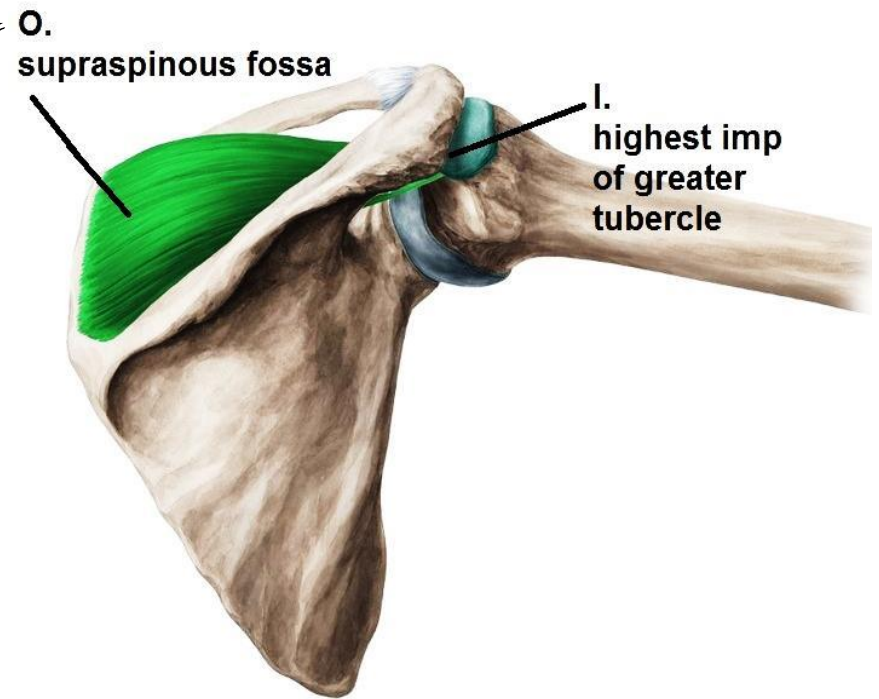
Highest impression
of greater tubercle of humerus

Action :

- start abduction(0-150)
- stabilize head of humerus in glenoid cavity As a Rotator cuff muscle?

Nerve supply:

Suprascapular n.



SHOULDER REGION

INFRASPINATUS

Origin :

infraspinous fossa

Insertion:

middle impression

of greater tubercle of humerus

Action :

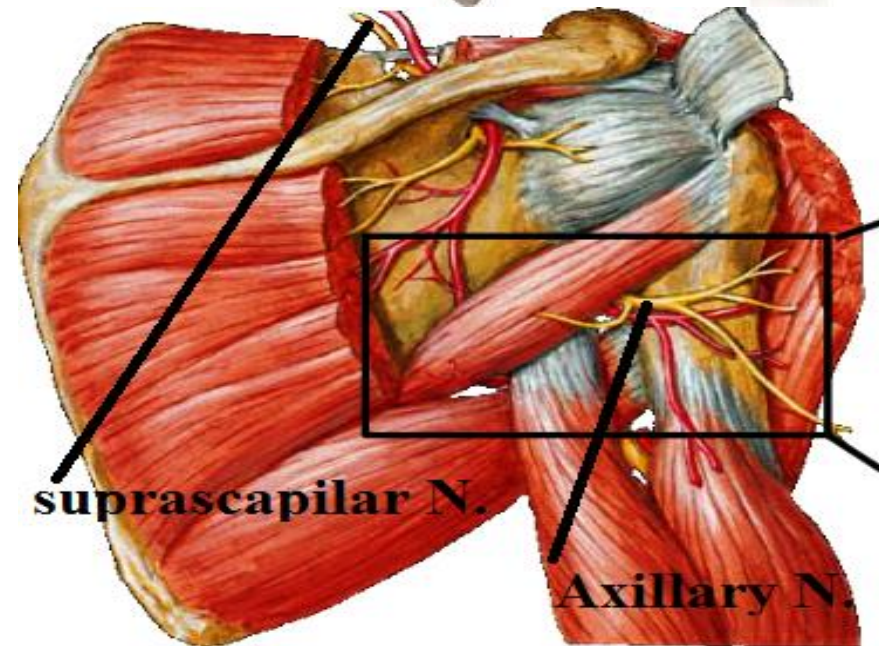
- Adduction & lateral rotation of arm
- Stabilize head of humerus in glenoid cavity as a Rotator cuff muscle?

Nerve supply:

Suprascapular n.

O.
infraspinous
fossa

I.
middle
imp.
of
greater
tubercle



SHOULDER REGION

TERES MINOR

Origin :

upper 2/3 of back
of lateral border of scapula

Insertion:

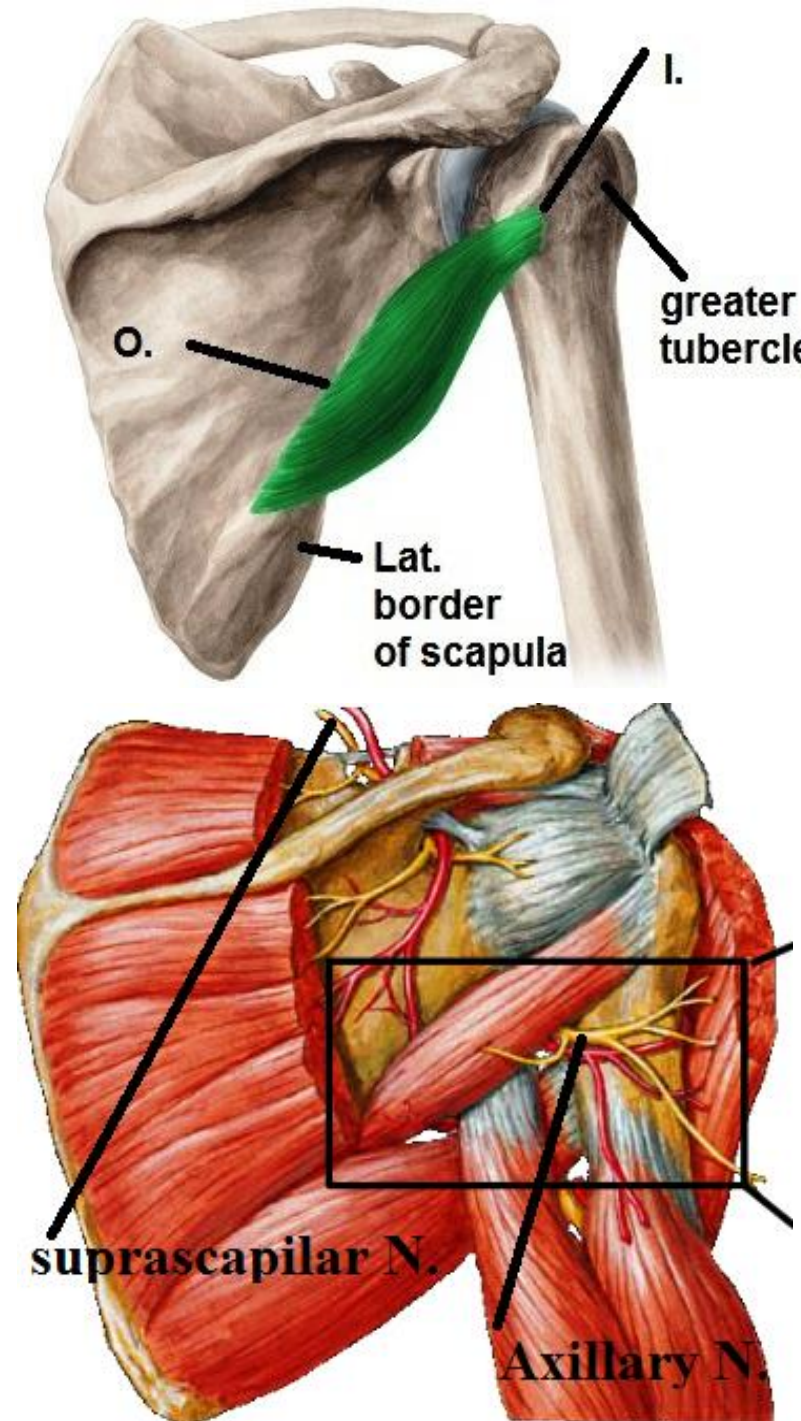
lowest impression
of greater tubercle of humerus

Action :

- Adduction & lateral rotation of arm
- Stabilize head of humerus in glenoid cavity As Rotator cuff muscle?

Nerve supply:

Axillary nerve



SHOULDER REGION

TERES MAJOR

Origin :

lower 1/3 of back
of lateral border of scapula

Insertion:

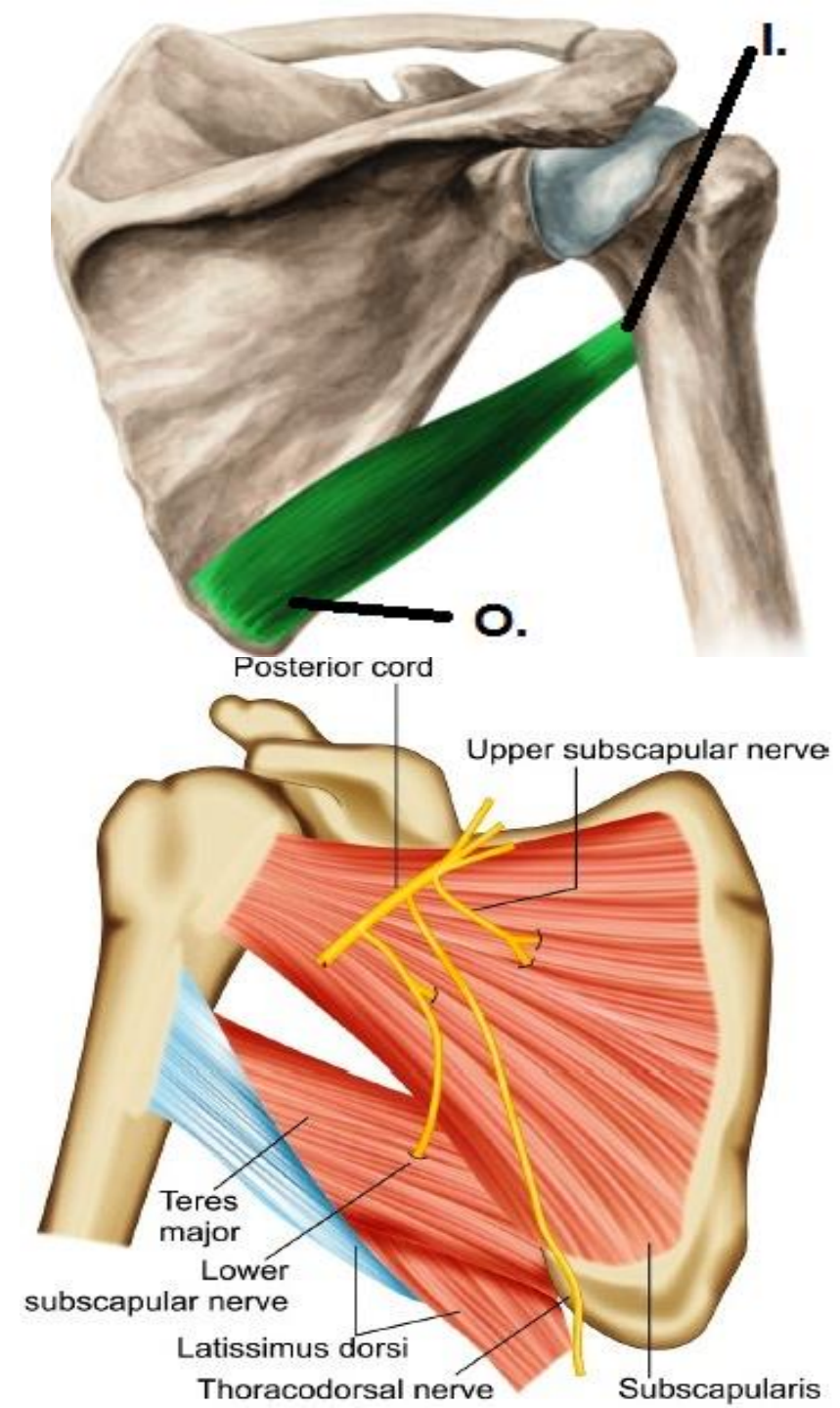
medial lip of intertubercular (bicipital)
groove of humerus

Action :

- Adduction & medial rotation of arm
- Extension of arm

Nerve supply:

lower subscapular nerve



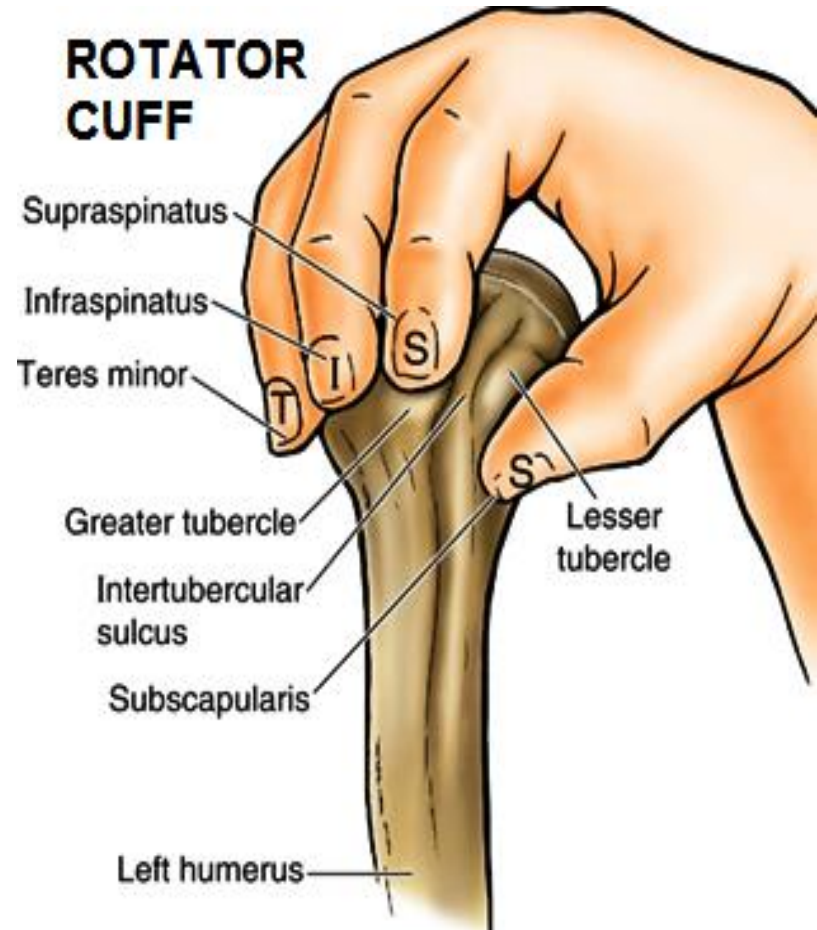
Muscle	O.	I.	A.	N.S.
SUBSCAPULARIS	Medial 2/3 of subscapular fossa	Lesser tubercle of humerus	<ul style="list-style-type: none"> Adduction & medial rotation of arm. Rotator cuff muscle? 	Upper & lower subscapular nerves.
SUPRASPINATUS	Medial 2/3 of Supraspinous fossa	Highest impression of greater tubercle of humerus	<ul style="list-style-type: none"> start abduction (0-15°) Rotator cuff muscle? 	Supracapular n.
INFRASPINATUS	infraspinous fossa	middle impression of greater tubercle of humerus	<ul style="list-style-type: none"> adduction & lateral rotation of arm Rotator cuff muscle? 	Suprascapular n.
TERES MINOR	upper $\frac{2}{3}$ of back of lateral border of scapula	lowest impression of greater tubercle of humerus	<ul style="list-style-type: none"> Adduction & lateral rotation of arm. Rotator cuff muscle? 	n. to teres minor from axillary n.
TERES MAJOR	lower $\frac{1}{3}$ of back of lateral border of scapula	medial lip of intertubercular (bicipital) groove of humerus	<ul style="list-style-type: none"> Adduction, & medial rotation & extension of arm. 	lower subscapular n.

SHOULDER REGION

N.B: rotator cuff muscles:

- 1- Subscapularis
- 2- supraspinatus
- 3- Infraspinatus.
- 4- Teres minor.

Support shoulder joint,
they stabilize head of humerus
in glenoid cavity



SHOULDER REGION

INTERMUSCULAR SPACES

1- Quadrangular space:

Boundaries:

Above: teres minor (in the back) or
Subscapularis (in the front)

Below: teres major

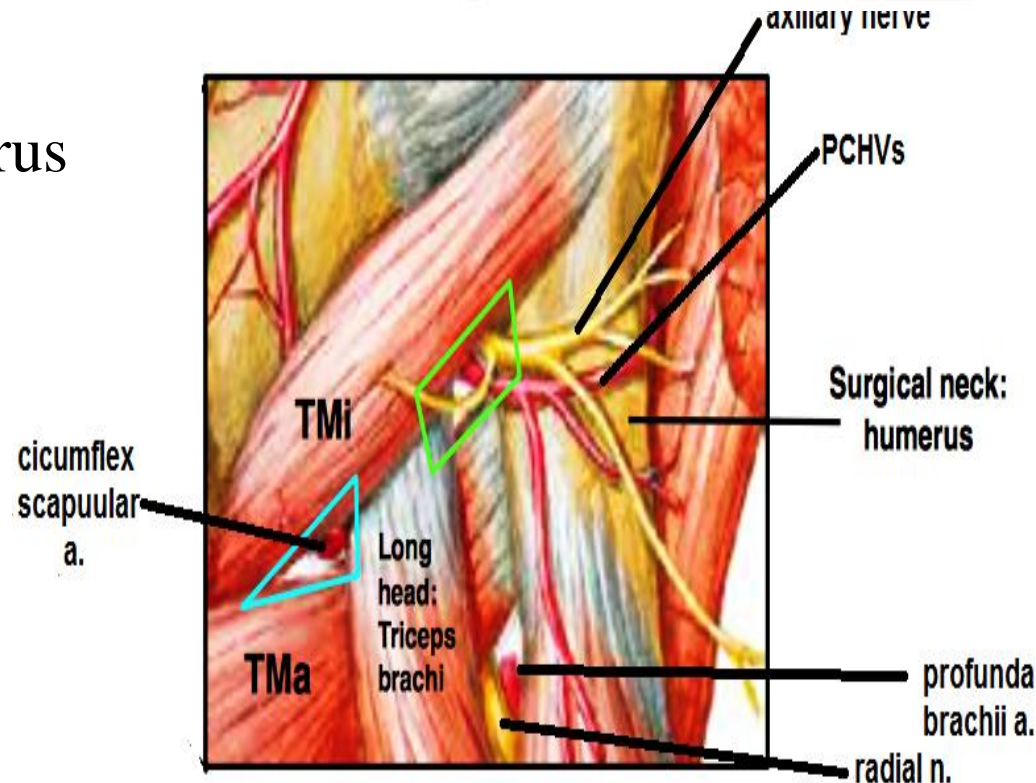
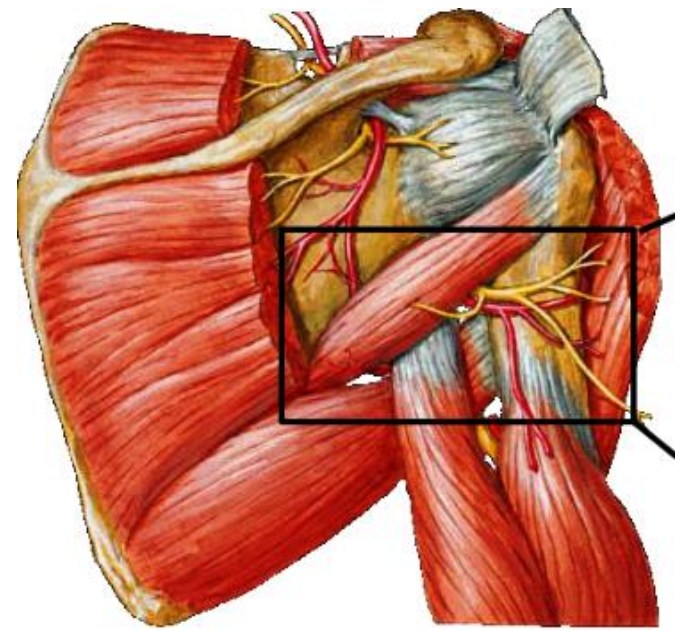
Laterally: surgical neck of humerus

Medially: long head of triceps.

Contents:

Axillary n.

Post. circumflex humeral vessels.



SHOULDER REGION

INTERMUSCULAR SPACES

2-Upper(medial) triangular space

Boundaries:

Above: teres minor (in the back) or
Subscapularis (in the front)

Below: teres major

Laterally: long head of triceps.

Contents:

circumflex scapular vessels

3-lower(lateral) triangular space

Boundaries:

Above: teres major.

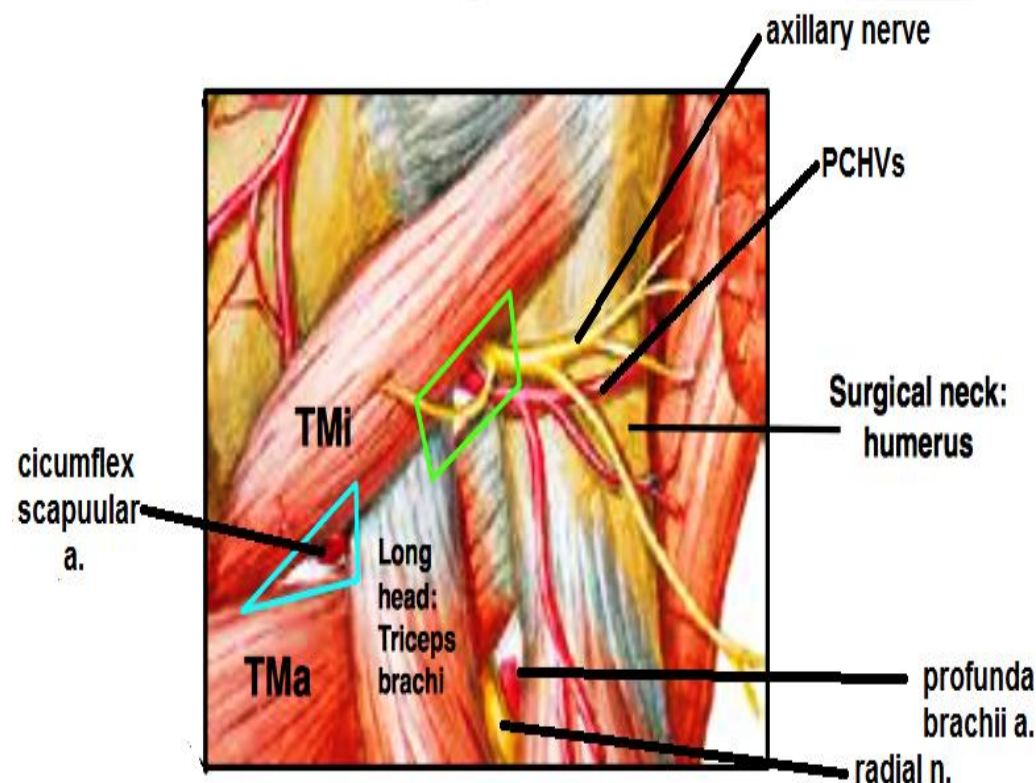
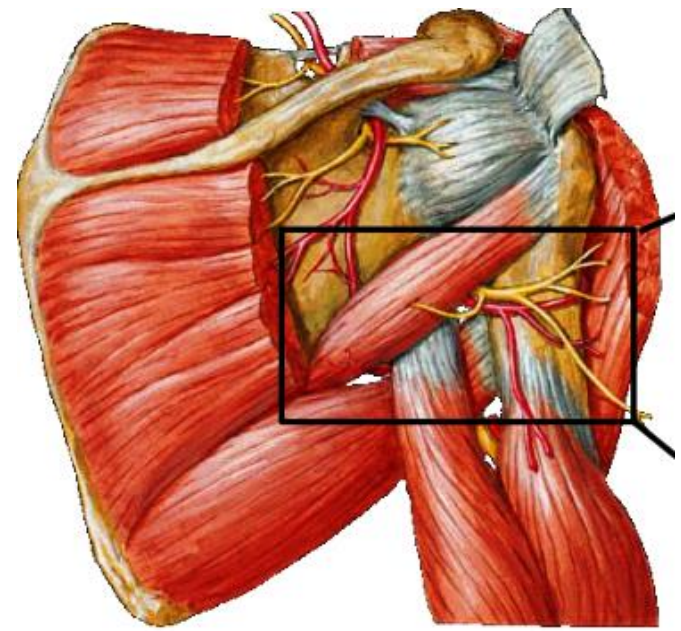
Laterally: spiral groove of humerus.

Medially: long head of triceps.

Contents:

Radial n.

Profunda brachii vessels



SHOULDER REGION

Deltoid muscle

Origin:

Ant. Fibers : ant. border of lateral 1/3 of clavicle

Middle ,, : lateral border of acromion

Post. ,, : lower lip of crest of spine of scapula

Insertion :

deltoid tuberosity on lateral surface of humerus

Action:

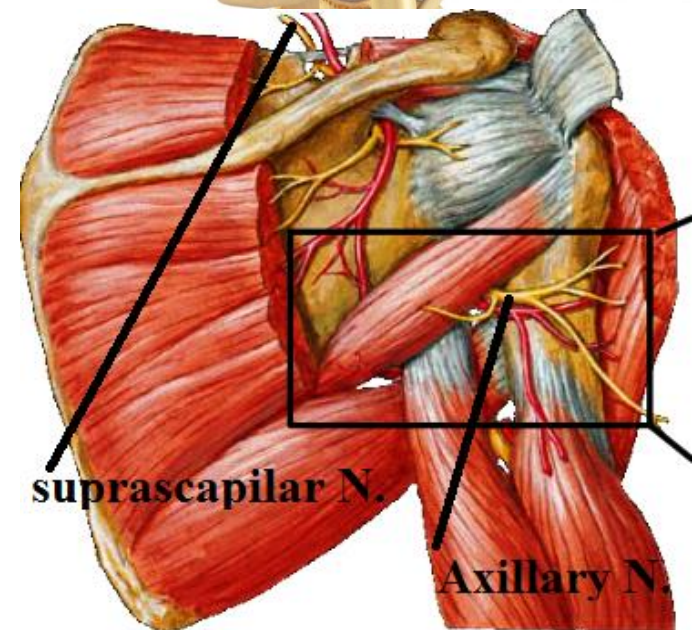
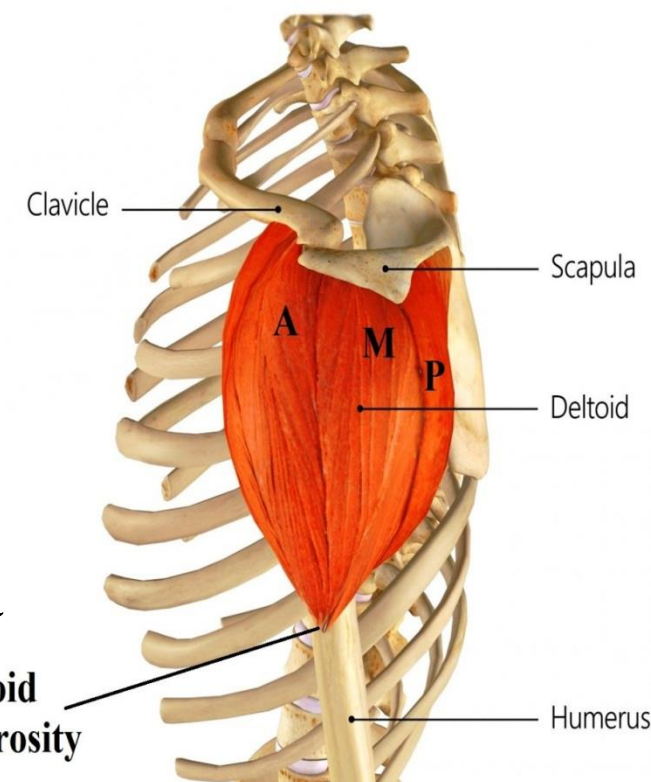
Ant. fibers: flexion of shoulder

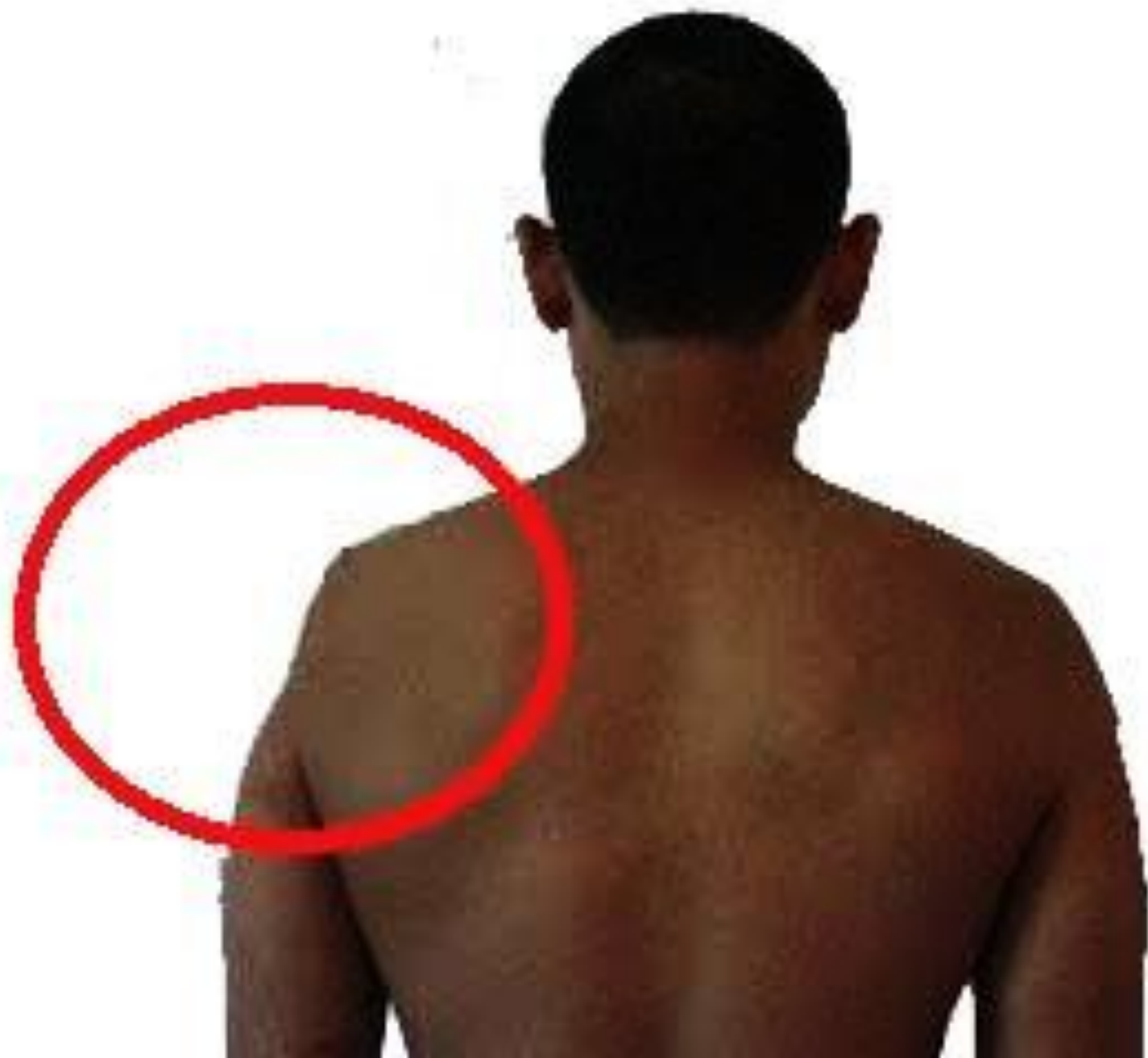Middle ,, : abduction of shoulder from 15 - 90

Post. ,, : extension of shoulder

N.B. it forms the rounded contour of shoulder

Nerve Supply: axillary n.





SHOULDER REGION

Deltoid muscle

Deep relations

1-Bones:

Head of humerus

Lesser & greater tubercles

Bicipital groove & its lips

Surgical neck

coracoid process

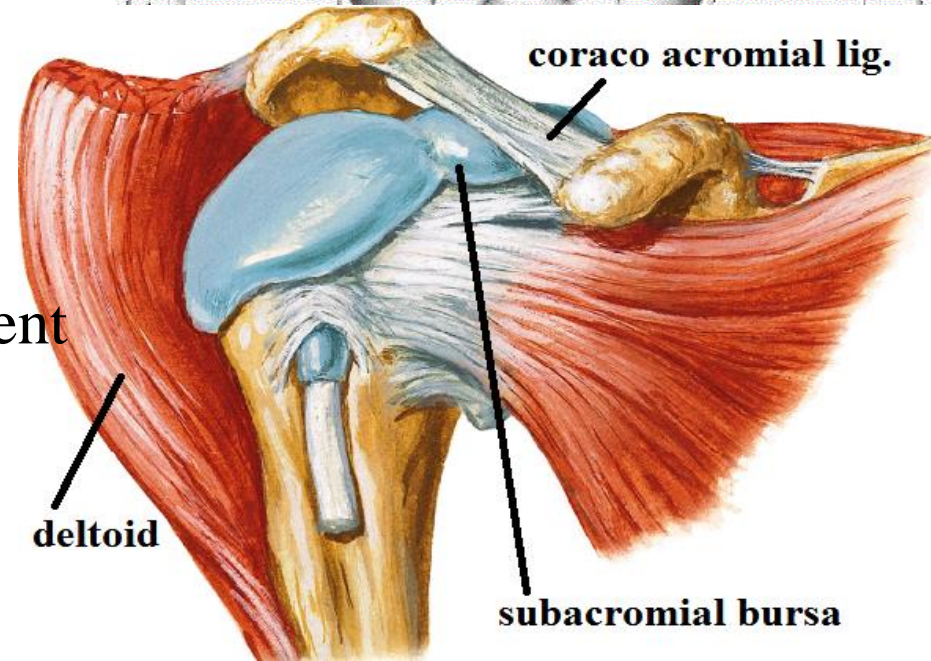
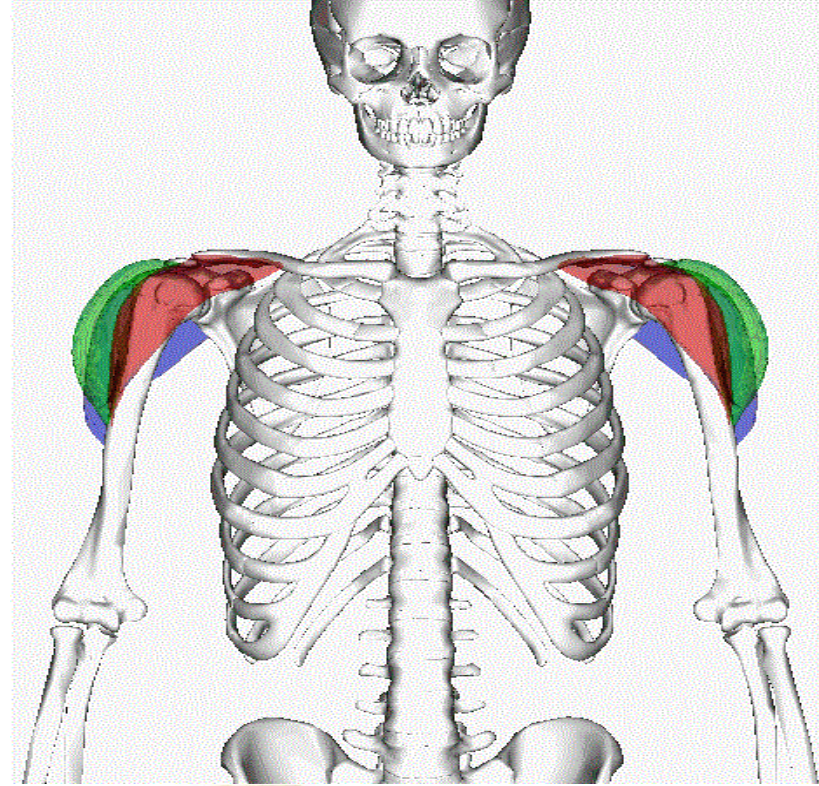
glenoid cavity

supra & infraglenoid tubercles

2-ligaments: - coracoacromial ligament

3- bursa:- sub acromial bursa

4-Joint: - shoulder joint



SHOULDER REGION

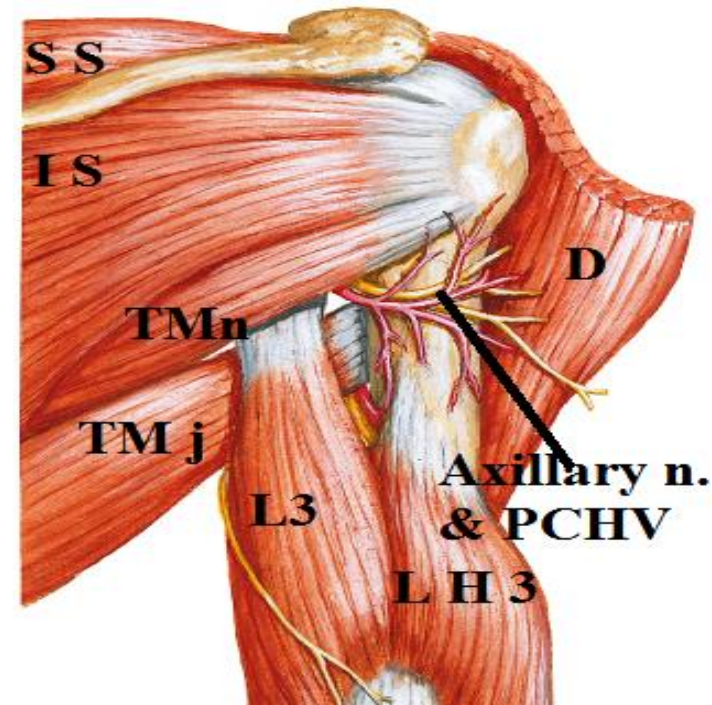
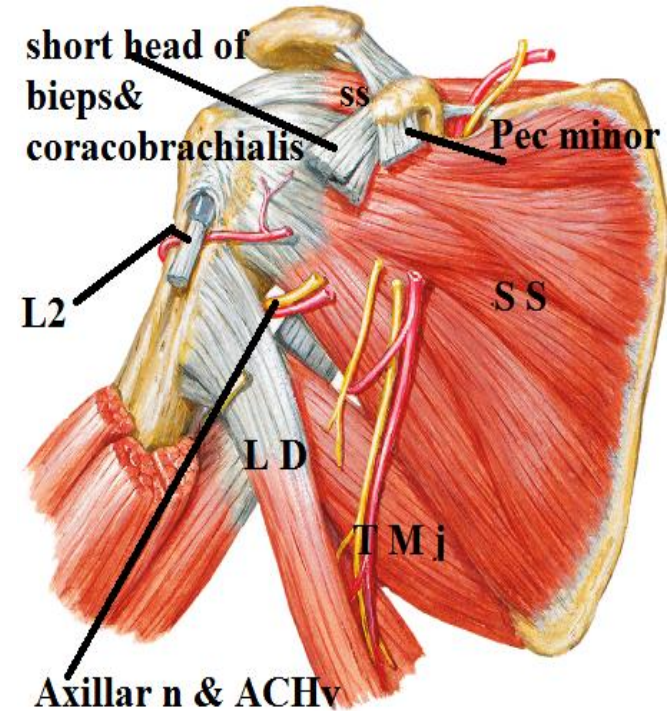
Deep relations

5-muscles

- Subscapularis
- Supraspinatus + infraspinatus
+ teres minor
- Pectoralis major + teres major
+ latissimus dorsi
- Coracobrachialis & short head of biceps
+ pectoralis minor
- Long head of biceps &
long and lateral heads of triceps

6-vessels & nerve:

- Ant. & post. circumflex humeral vessels.
- Axillary (circumflex) n.



THANQ