

You're in Data Mode ?

Go to Free

← ارشيف ميد هستو



Say something...



## RECENT ACTIVITY



ارشيف ميد هستو ▶ لينا محمود



10 Mar 2019 at 23:08 •

1-Platlets granulomere  
Conains ribosome

2-Alpha granules is the most abudant

Ahmad Āymān Al - Maaitah

2 comments



Like



Comment



ارشيف ميد هستو ▶ لينا محمود



10 Mar 2019 at 22:57 •

C.T

1-one of the following is not a fixed cell

Plasma cell ✓

Fibroblasts

Fat cell

Pigment cell

Fibrocytes

2- macrophages in CT is called :

Histocytes

3-mast cells

Secretion of histamine + heparine ✓

1/2-1% of total count ✗

4- metachromatic stain for :

Mast cells

← ارشیف مید هستو

C.T

1-one of the following is not a fixed cell

Plasma cell ✓

Fibroblasts

Fat cell

Pigment cell

Fibrocytes

2- macrophages in CT is called :

Histocytes

3-mast cells

Secretion of histamine + heparine ✓

1/2-1% of total count ✗

4- metachromatic stain for :

Mast cells

5- origin from B- lymphocytes

Plasma cells

6- cart wheel appearance of nuclear

Plasma cell

7- one of the following is not primary cartilage

Tendon

Bone

Blood

Myometrium ✓

8- most abundant cell in loose areolat CT is

Fibroblasts

9- Sudan stain in :

Adipose CT

10- brown fat

One of the following is incorrect

Pherpharal nucles

11-CT in ligament

Regular dense CT

12\_fibers type 1

White fibrous CT

You're in Data Mode ?


Go to Free

← ارشيف ميد هستو

10- brown fat  
One of the following is incorrect  
Pherpharal nucles

11-CT in ligament  
Regular dense CT

12\_fibers type 1  
White fibrous CT

 You and Abd Al-Rhman A Ibdah



Like



Comment



ارشيف ميد هستو ▶ لينا محمود

10 Mar 2019 at 22:45 • 

Glandular epithelium

1- secretion involved destroying the cell  
Holocrine

2-secretion in glands which secret milk  
Apocrine

3- another name for acinar  
Alveolar

4-sweet glands:  
Simple coiled tubular

5- myoepithelium :  
One is incorrect  
Contains secretory acini and ducts of the gland ✗  
Irregular ✗  
Contains RER ✓

6- one of the following is not a function of epithelium  
Transportation ✓  
Diffusion ✗  
Absorption ✗

هاي لل CT

## ← ارشیف مید هستو



ارشیف مید هستو لینا محمود

10 Mar 2019 at 22:45 •

## Glandular epithelium

1- secretion involved destroying the cell  
Holocrine

2- secretion in glands which secret milk  
Apocrine

3- another name for acinar  
Alveolar

4- sweat glands:  
Simple coiled tubular

5- myoepithelium :  
One is incorrect  
Contains secretory acini and ducts of the gland ✗  
Irregular ✗  
Contains RER ✓

6- one of the following is not a function of epithelium  
Transportation ✓  
Diffusion ✗  
Absorption ✗

هاي لل CT

7- epithelial polarity doesn't contain  
Cillia  
Gap junction  
Basal infolding  
Golicalyx ✓

8- Kidney tubules:  
Contain basal infolding for reabsorption

9- apical modification in EPIDIDYMIS is :  
Steriocila

10- macula adherins  
Contains intermediate keratin filament

11- One of the following is a function of basement membrane

You're in Data Mode ?

Go to Free

← ارشيف ميد هستو

Simple coiled tubular

5- myoepithelium :

One is incorrect

Contains secretory acini and ducts of the gland ✗

Irregular ✗

Contains RER ✓

6- one of the following is not a function of epithelium

Transportation ✓

Diffusion ✗

Absorption ✗

هاي لل CT

7-epithelial polarity doesn't contain

Cillia

Gap junction

Basal infolding

Golicalyx ✓

8- Kidney tubules:

Contain basal infolding for reabsorption

9- apical modification in EPIDIDYMIS is :

Steriocila

10- macula adherins

Contains intermediate keratin filament

11- One of the following is a function of basement membrane

Molecular filtration ✓

Excitibility ✗

Prevent tissue regeneration ✗

Contaction ✗

 You and Abd Al-Rhman A Ibdah

 Like

 Comment


ارشيف ميد هستو ▶ لينا محمود

10 Mar 2019 at 22:28 • 

من سلايد

Epithelial tissue



You're in Data Mode ?

Go to Free

← ارشيف ميد هستو

Prevent tissue regeneration ✗

Contaction ✗


 You and Abd Al-Rhman A Ibdah

 Like

 Comment


ارشيف ميد هستو ▶ لينا محمود

10 Mar 2019 at 22:28 • 

من سلايد

Epithelial tissue

1-classification of epithelium is based on :

Number of layers ✓

2-goblet cell is associated with

Simple coumnar epthelium ✓

Pseudostratified ✓

ما بتجيب التنين بنفس الدائرة هيك حكت

3-microvilia:

Increases surface area for absorbtion ✓

Is very similar to cilia ✗

4- lines abdominal cavity

Methothelium

5-what is the classification of the epithelium that lines blood

vessels

Endothelim

6-epithelim that lines the opening in skin

Squamous stratified

 Ahmad Āýmān Al - Maaitah

2 comments

 Like

 Comment


ارشيف ميد هستو ▶ لينا محمود

10 Mar 2019 at 22:08 • 

You're in Data Mode ?

Go to Free

← ارشيف ميد هستو

Increases surface area for absorbtion ✓

Is very similar to cilia ✗

4- lines abdominal cavity

Methothelium

5-what is the classification of the epithelium that lines blood vessels

Endothelium

6-epithelium that lines the opening in skin

Squamous stratified

Ahmad Āýmān Al – Maaitah

2 comments



Like



Comment



ارشيف ميد هستو ▶ لينا محمود

10 Mar 2019 at 22:08 •

في سؤال المعظم مخربط فيه عنا فانتبهوله

Intermediate keratin filaments

همة الي يكونوا في

Dense plaque of macula addherens

فانتبهوله

اما

Zonula

Actin filaments

You and يوسف حاتم الطراونة



Like




Comment



ارشيف ميد هستو ▶ Sulaf Maaitah

10 Mar 2019 at 19:59 •

الاسئلة اللي بتحتمل اجابتين  
اللي عندهم\*اجاباتي



You're in Data Mode ?

Go to Free

← ارشيف ميد هستو

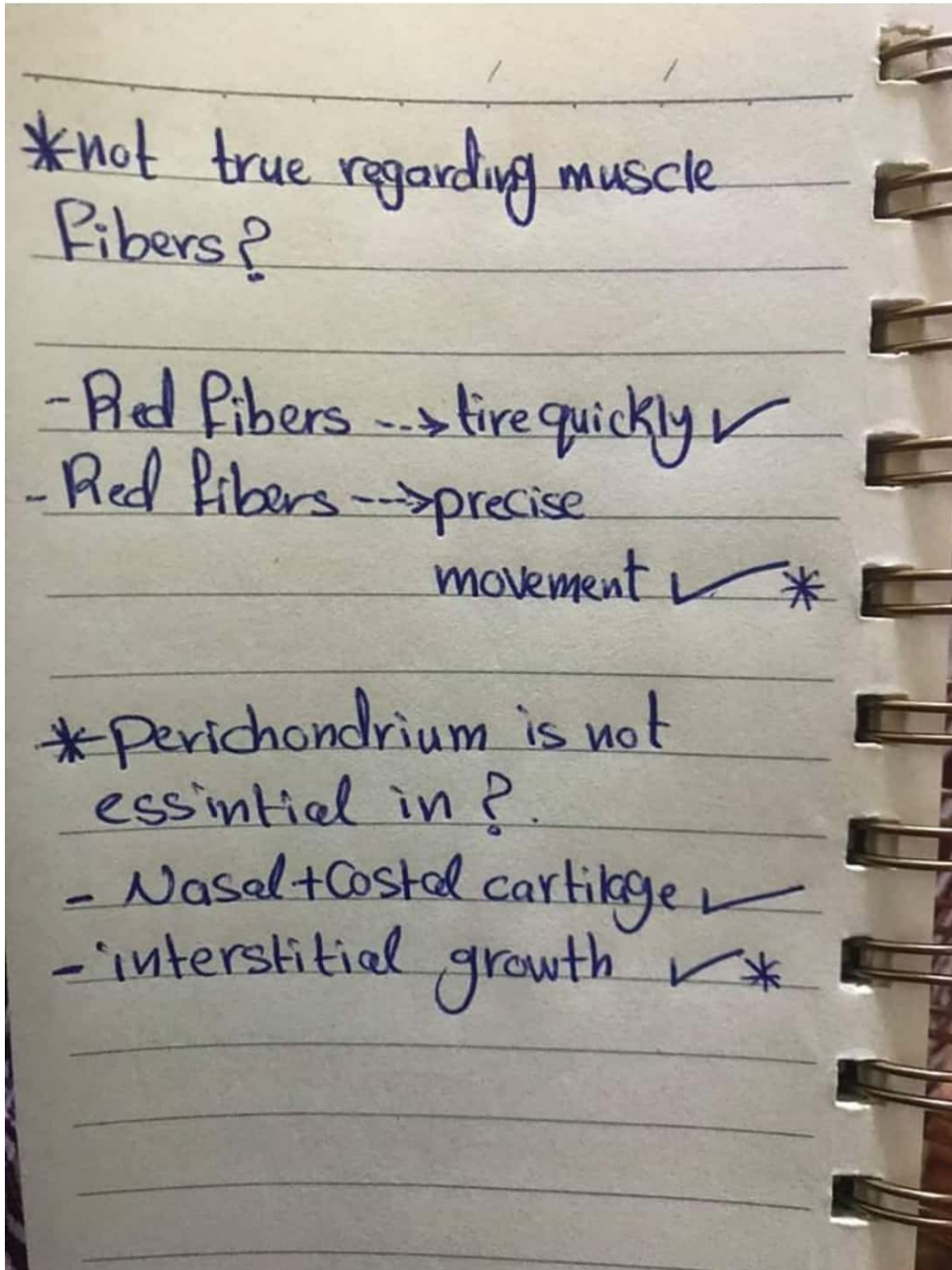


Sulaf Maaitah ▶ ارشيف ميد هستو



10 Mar 2019 at 19:59 • 📷

الاسئله اللي بتحتمل اجابتين  
اللي عندهم\*اجاباتي 🤔😂😂



You, Abdullah M Alzoubi and 2 others

4 comments



Like



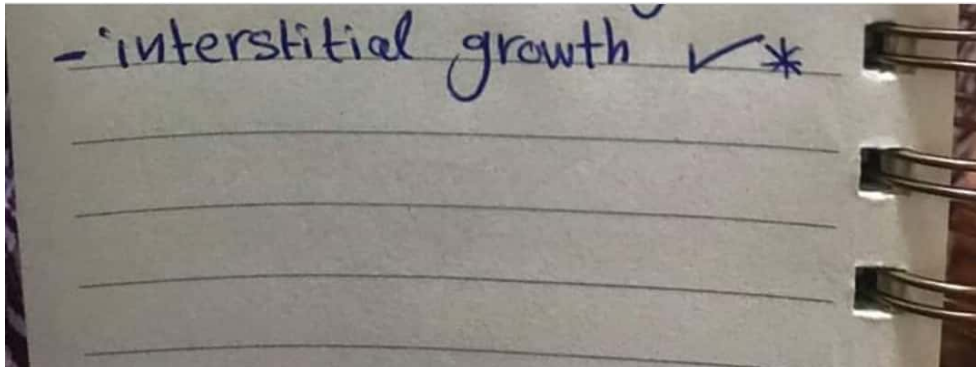
Comment



You're in Data Mode ?

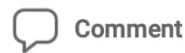Go to Free

← ارشيف ميد هستو



You, Abdullah M Alzoubi and 2 others

4 comments



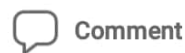Reef Haroun AlQaissi ▶ ارشيف ميد هستو



10 Mar 2019 at 19:44 •

in E.M the correct discribe to eosinophil?  
granules with dense crystalloid core

You, Rania Abdallah Sbieh and 2 others



Thekra Altarawneh ▶ ارشيف ميد هستو



10 Mar 2019 at 19:43 •

✓ الخليه اللي ما عليها MHC1 هي RBC ✓

-platelet not true cell ✓

-abundant granules in platelet granulomere is Alpha granules ✓

Rouleaux FORMATION ✓... See اذا كانت ال circulation الدم بطيئة بصير more

You and 3 others

1 Comment



You're in Data Mode ?

Go to Free

← ارشيف ميد هستو



Reef Haroun AlQaissi ▶ ارشيف ميد هستو



10 Mar 2019 at 19:44 •

in E.M the correct discribe to eosinophil?  
granules with dense crystalloid core

You, Rania Abdallah Sbieh and 2 others



Like



Comment



Thekra Altarawneh ▶ ارشيف ميد هستو



10 Mar 2019 at 19:43 •

✓ الخليه اللي ما عليها MHC1 هي RBC

✓ -platelet not true cell

✓ -abundant granules in platelet granulomere is Alpha granules

✓ -اذا كانت ال circulation الدم بطيئة بصير Rouleaux FORMATION

✓ -انه الوحيد من Blood elements الـ differential count همه WBC

✓ -كل خلايا الدم تتصنع في Bone marrow  
الـ Barr body neutrophiles اللي فيها

✓ Elastic cartilage doesn't clarify

✓ -perichonrium not necessary in interstitial growth

You and 3 others

1 Comment



Like



Comment



Reef Haroun AlQaissi ▶ ارشيف ميد هستو



10 Mar 2019 at 19:39 •

which of these contain fibrocartilage?

الجواب

articular disc in temporomandibular joint

You're in Data Mode ?


Go to Free

← ارشيف ميد هستو

كل خلايا الدم تتصنع في Bone marrow  
الخلية اللي فيها Barr body ← neutrophiles

Elastic cartilage doesn't clarify ✓

-perichonrium not necessary in interstitial growth ✓

 You and 3 others

1 Comment

 Like

 Comment



Reef Haroun AlQaissi ▶ ارشيف ميد هستو

10 Mar 2019 at 19:39 • 

which of these contain fibrocartilage?

الجواب

articular disc in tempromandebular joint

 You, Rania Abdallah Sbieh and 3 others


 Like

 Comment


Reef Haroun AlQaissi ▶ ارشيف ميد هستو

10 Mar 2019 at 19:29 • 

cell of C.T macrophage?  
histocyte

 You and 3 others


 Like

 Comment


Reef Haroun AlQaissi ▶ ارشيف ميد هستو

10 Mar 2019 at 19:28 • 

the cells which form blood element present in  
bone marrow

 مش متأكد من الصيغه

 You, Sulaf Mesleh and 3 others

You're in Data Mode ?

Go to Free

← أرشيف ميد هستو



Keer Haroun AlQaissi ▶ أرشيف ميد هستو

10 Mar 2019 at 19:28 ·

the cells which form blood element present in bone marrow

مش متأكد من الصيغه 🙄

You, Sulaf Maaitah and 3 others

Like

Comment



Sulaf Maaitah ▶ أرشيف ميد هستو

10 Mar 2019 at 19:11 ·

\*which of these is not a function of epithelial tissue?  
Transportation (not sure)

You, Laith F Najada and 2 others

14 comments

Like

Comment



Sulaf Maaitah ▶ أرشيف ميد هستو

10 Mar 2019 at 19:06 ·

\*true regarding mast cells of blood?  
2 correct answers  
I chose (they form 1-2% 1%)

طلعوا حاطين total count يعني فلط

contain histamine and heparin الجواب الصح

You, Rania Abdallah Sbieh and 4 others

12 comments

Like

Comment



Sulaf Maaitah ▶ أرشيف ميد هستو

10 Mar 2019 at 19:05 ·

\*mode of secretion in milk secreting glands?  
Apocrine

You, Laith F Najada and 2 others

You're in Data Mode ?

Go to Free

← ارشيف ميد هستو



Like



Comment



Sulaf Maaitah ▶ ارشيف ميد هستو



10 Mar 2019 at 19:05 •

\*mode of secretion in milk secreting glands?  
Apocrine



You, Laith F Najada and 3 others



Like



Comment



Sulaf Maaitah ▶ ارشيف ميد هستو



10 Mar 2019 at 19:04 •

\*not true regarding myoeputhilum?  
Contain rER



You, Laith F Najada and 4 others



Like



Comment



Sulaf Maaitah ▶ ارشيف ميد هستو



10 Mar 2019 at 19:04 •

\*sweat glands are?  
Simple coild tubular



You, Laith F Najada and 3 others



Like



Comment



Laith F Najada ▶ ارشيف ميد هستو



10 Mar 2019 at 18:35 •

في سؤال كان جوابه myometrium اشفي زي هيڪ هسا تذكرته 😄



You, Sulaf Maaitah and 3 others

4 comments

You're in Data Mode ?

Go to Free

← ارشيف ميد هستو



Like



Comment



Laith F Najada ▶ ارشيف ميد هستو



10 Mar 2019 at 18:35 •

في سؤال كان جوابه myometrium اشفي زي هيڪ هسا تذكرته 😄



You, Sulaf Maaitah and 3 others

4 comments



Like



Comment



Abdullah M. Yasin ▶ ارشيف ميد هستو



10 Mar 2019 at 17:05 •

Actin , spectrin , ankyrin :  
subplasmalemmal cytoskeletone

5

1 Comment



Like



Comment



Abdullah M. Yasin ▶ ارشيف ميد هستو



10 Mar 2019 at 17:00 •

كان في سؤال انه ال epithelial ما بيعمل diffusion or transportation احترت  
بينهم صراحة واتوقع اخر اشفي حطيت transportation

4

4 comments



Like



Comment



Abdullah M. Yasin ▶ ارشيف ميد هستو



10 Mar 2019 at 16:59 •

برضو في سؤال macrophages جو ال C.T هي نفسها histocyte



4

2 comments



Like



Comment

You're in Data Mode ?

Go to Free

← ارشيف ميد هستو



4

4 comments



Like



Comment



Abdullah M. Yasin ▶ ارشيف ميد هستو



10 Mar 2019 at 16:59 •

برضو في سؤال macrophages جو ال C.T هي نفسها histocyte



4

2 comments



Like



Comment



Abdullah M. Yasin ▶ ارشيف ميد هستو



10 Mar 2019 at 16:56 •

في سؤال كان

What is the type of junction that attaches intercalated disks with thin filaments :

zonula adherents

? zonula adherents attaches to which filament

وكان الجواب actin

كان في سؤالين زي هيك مربوطين ببعض اذا ما كنت مخربط صح ؟



2

6 comments



Like



Comment



Tamara Abboud ▶ ارشيف ميد هستو



10 Mar 2019 at 15:02 •

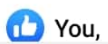Which is the false?

(A) band contraction

Which is the false?

Cardiac muscles have satellite cells

\*في كم سؤال عن ال types of junctions in the disc... See more



You, يوسف حاتم الطراونة and 2 others



You're in Data Mode ?

Go to Free

← أرشيف ميد هستو



Abdullah M. Yasin ▶ أرشيف ميد هستو



10 Mar 2019 at 16:56 •

في سؤال كان

What is the type of junction that attaches intercalated disks with thin filaments :  
zonula adherents

? zonula adherents attaches to which filment انو

وكان الجواب actin

كان في سؤالين زي هيك مربوطين ببعض اذا ما كنت مخربط صح ؟



2

6 comments



Like



Comment



Tamara Abboud ▶ أرشيف ميد هستو



10 Mar 2019 at 15:02 •

Which is the false?  
(A) band contraction

Which is the false?  
Cardiac muscles have satellite cells

\*في كم سؤال عن ال types of junctions in the disc

ال Transverse وال Lateral

\* وانه diad:cardiac

triad:skeletal



You, يوسف حاتم الطراونة and 2 others



Like



Comment



Noor Alkasasbeh ▶ أرشيف ميد هستو



10 Mar 2019 at 15:01 •

سؤال عن type 1 of MHC جوابه RBC

You're in Data Mode ?


Go to Free

← أرشيف ميد هستو

Lateral وال Transverse ال

\* وانه diad:cardiac

triad:skeletal

 You, يوسف حاتم الطراونة and 2 others

 Like

 Comment


Noor Alkasasbeh ▶ أرشيف ميد هستو

⋮

10 Mar 2019 at 15:01 • 

سؤال عن type 1 of MHC جوابه RBC

  Mhmd Azzam and 2 others

4 comments

 Like



 Comment


Tamara Abboud ▶ أرشيف ميد هستو

⋮

10 Mar 2019 at 14:56 • 

Many questions about appositional and interstitial growth

  You and 2 others

2 comments

 Like

 Comment


Naba Essa Al-Saraireh ▶ أرشيف ميد هستو

⋮

10 Mar 2019 at 14:55 • 

epithelium in blood vessels is \*classified\* as

simple squamous epithelium ✓

endothelium ✗

 3

18 comments

 Like

 Comment

You're in Data Mode ?

Go to Free

← ارشیف مید هستو



Like



Comment



Tamara Abboud ▶ ارشیف مید هستو



10 Mar 2019 at 14:56 •

Many questions about appositional and interstitial growth



You and 2 others

2 comments



Like



Comment



Naba Essa Al-Saraireh ▶ ارشیف مید هستو



10 Mar 2019 at 14:55 •

epithelium in blood vessels is \*classified\* as

simple squamous epithelium ✓

endothelium ✗



3

18 comments



Like



Comment



Tamara Abboud ▶ ارشیف مید هستو



10 Mar 2019 at 14:55 •

Cells that contain granules and metachromatic staining?

-Mast cells

Resists tensile stress?

-Dense regular CT (white fibrous)

Differential count related to?

-White blood cells (leucocytes/leukocytes)

With crystalloid dense cores?

-Eosinophils

What is not in the matrix of the rib cartilage?

-Troponin

You're in Data Mode ?

Go to Free

← ارشیف مید هستو



Like



Comment



Tamara Abboud ▶ ارشیف مید هستو



10 Mar 2019 at 14:55 •

Cells that contain granules and metachromatic staining?  
-Mast cells

Resists tensile stress?  
-Dense regular CT (white fibrous)

Differential count related to?  
-White blood cells (leucocytes/leukocytes)

With crystalloid dense cores?  
-Eosinophils

What is not in the matrix of the rib cartilage?  
-Troponin



Anas Alshawawreh and 1 other



Like



Comment



Laith F Najada ▶ ارشیف مید هستو



10 Mar 2019 at 14:46 •

Related to the appositional growth  
✓perichondrium formed chondroblast which lie new matrix



1

6 comments



Like



Comment



Tareq Abu Alnadi ▶ ارشیف مید هستو



10 Mar 2019 at 14:45 •

A question about appositional growth. I Forgot the choices 😊



You and 2 others

You're in Data Mode ?

Go to Free

← ارشيف ميد هستو



Tareq Abu Alnadi ▶ ارشيف ميد هستو



10 Mar 2019 at 14:45 •

A question about appositional growth. I Forgot the choices 😊

You and 2 others



Like



Comment



Laith F Najada ▶ ارشيف ميد هستو



10 Mar 2019 at 14:43 •

Perichondrium is not essential in

nasal and costal cartilages

You and 2 others

13 comments



Like



Comment



Laith F Najada ▶ ارشيف ميد هستو



10 Mar 2019 at 14:41 •

ركزوع هاي الاشياء

•Triad located in the skeletal muscle between the T tubule and two terminal cisterna

•Diad located in the cardiac muscle at the Z line

• T tubule lies in the level of the junction between A

And I bands for skeletal muscle and Z line for cardiac muscle

You and 2 others

2 comments



Like



Comment



Dana Bani Naser ▶ ارشيف ميد هستو



10 Mar 2019 at 14:40 •

لا حدا يأتوت لانها راح تتحول لعاده نصيحه 😊

You and 1 other

1 Comment

You're in Data Mode ?

Go to Free

← ارشيف ميد هستو

You and 2 others

2 comments



Like



Comment



Dana Bani Naser ▶ ارشيف ميد هستو



10 Mar 2019 at 14:40 •

لا حدا ياوت لانها راح تتحول لعاده نصيحه 😂

You and 1 other

1 Comment



Haha



Comment



Ahmad Āymān Al - Maaitah ▶ ارشيف ميد هستو



10 Mar 2019 at 14:36 •

اهم شي ركزوا ع الارشيفات ❤️  
 + الركورڊ للدكتورة فردوس ❤️  
 + أسئلة الدكتور أيمن بالجيبه 😂😂❤️

1



Like



Comment



Monther Qatawneh ▶ ارشيف ميد هستو



10 Mar 2019 at 14:34 •

ادرسوا كل التفاصيل لانها هي الي بتيجي 😂

You and 3 others

4 comments



Like



Comment



Mohammad Mushallah ▶ ارشيف ميد هستو



10 Mar 2019 at 14:29 •

Plasma cell has chart wheel nucleus

You're in Data Mode ?

Go to Free

← ارشيف ميد هستو



Haha



Comment



Ahmad Āymàñ Al - Maaitah ▶ ارشيف ميد هستو



10 Mar 2019 at 14:36 •

اهم شي ركزوا ع الارشيفات ❤️  
 + الركورڊ للدكتورة فردوس ❤️  
 + أسئلة الدكتور أيمن بالجيبه 🤔🤔🤔



1



Like



Comment



Monther Qatawneh ▶ ارشيف ميد هستو



10 Mar 2019 at 14:34 •

ادرسوا كل التفاصيل لانها هي الي بتيجي 🤔



You and 3 others

4 comments



Like



Comment



Mohammad Mushallah ▶ ارشيف ميد هستو



10 Mar 2019 at 14:29 •

Plasma cell has chart wheel nucleus



You, Laith F Najada and 2 others



Like



Comment



Mohammad Mushallah ▶ ارشيف ميد هستو



10 Mar 2019 at 14:28 •

Macrophage :histocytes



2



You're in Data Mode ?

Go to Free

← ارشيف ميد هستو



Monther Qatawneh ▶ ارشيف ميد هستو



10 Mar 2019 at 14:34 •

ادرسوا كل التفاصيل لانها هي الي بتيجي 🤔

You and 3 others

4 comments



Like



Comment



Mohammad Mushallah ▶ ارشيف ميد هستو



10 Mar 2019 at 14:29 •

Plasma cell has chart wheel nucleus

You, Laith F Najada and 2 others



Like



Comment



Mohammad Mushallah ▶ ارشيف ميد هستو



10 Mar 2019 at 14:28 •

Macrophage :histocytes

2



Like



Comment



Mhmd Azzam ▶ ارشيف ميد هستو



10 Mar 2019 at 14:27 •

Which of the following doesn't calcify ?

External ear

You, Feras A. Ahmad and 4 others

4 comments



Like



Comment

You're in Data Mode ?

Go to Free

← ارشيف ميد هستو



Mhmd Azzam ▶ ارشيف ميد هستو



10 Mar 2019 at 14:27 •

Which of the following doesn't calcify ?  
External ear

You, Feras A. Ahmad and 4 others

4 comments



Like



Comment



Mhmd Azzam ▶ ارشيف ميد هستو



10 Mar 2019 at 14:25 •

The Sudan stain considered with ?  
Fat

You, Feras A. Ahmad and 3 others



Like



Comment



Laith F Najada ▶ ارشيف ميد هستو



10 Mar 2019 at 14:21 •

Which is the first step in the collagen production  
 cleavage of propeptides

You and 2 others

10 comments



Like



Comment



Mhmd Azzam ▶ ارشيف ميد هستو



10 Mar 2019 at 14:20 •

One if kidney tubules properties ?  
They have Basel infolding for there modification

You, Feras A. Ahmad and 3 others

6 comments



Like



Comment

You're in Data Mode ?

Go to Free

← ارشيف ميدهستو



Like



Comment



Mhmd Azzam ▶ ارشيف ميدهستو



10 Mar 2019 at 14:20 •

One if kidney tubules properties ?  
They have Basel infolding for there modification



You, Feras A. Ahmad and 3 others

6 comments



Like



Comment



Laith F Najada ▶ ارشيف ميدهستو



10 Mar 2019 at 14:17 •

Which is the embryonic connective tissue  
✓ mucosa tissue



You and 3 others



Like



Comment



Mhmd Azzam ▶ ارشيف ميدهستو



10 Mar 2019 at 14:16 •

The goblet cell is lined with pseudo stratified epithelium  
Note: goblet cell is lined by simple columnar also  
But according to the MSQ options 🌸




You, Feras A. Ahmad and 3 others



Like



Comment



Mhmd Azzam ▶ ارشيف ميدهستو



10 Mar 2019 at 14:15 •

The filament which covers the surface of epideydmis  
Stereocillia

You're in Data Mode ?

Go to Free

← ارشیف مید هستو



Mhmd Azzam ▶ ارشیف مید هستو



10 Mar 2019 at 14:15 •

The filament which covers the surface of epideydmis  
Stereocillia

You, Feras A. Ahmad and 3 others



Like



Comment



Mhmd Azzam ▶ ارشیف مید هستو



10 Mar 2019 at 14:12 •

Which of the following is matched incorrect  
Elastic cartilage ~ calcify with aging

You, Laith F Najada and 3 others



Like



Comment



Mhmd Azzam ▶ ارشیف مید هستو



10 Mar 2019 at 14:11 •

Another name for acinar ?  
Alveolar

You, Laith F Najada and 3 others



Like



Comment



Laith F Najada ▶ ارشیف مید هستو



10 Mar 2019 at 14:11 •

All these cells are fixed EXCEPT  
 plasma cell

2



Like



Comment

You're in Data Mode ?

Go to Free

← ارشيف ميد هستو



Laith F Najada ▶ ارشيف ميد هستو



10 Mar 2019 at 14:11 •

All these cells are fixed EXCEPT

 plasma cell

2



Like



Comment



Mhmd Azzam ▶ ارشيف ميد هستو



10 Mar 2019 at 14:11 •

Which of the following is not a fixed cell

Plasma cell

You and 2 others

1 Comment



Like



Comment



Laith F Najada ▶ ارشيف ميد هستو



10 Mar 2019 at 14:05 •

The epithelium that is covering the opening in the skin

 stratified squamous

Rania Abdallah Sbieh and 3 others

2 comments



Like



Comment



ارشيف ميد هستو ▶ يوسف حاتم الطراونة



10 Mar 2019 at 14:05 •

T.B results in neutropenia and monocytosis

3

6 comments



Like



Comment

You're in Data Mode ?

Go to Free

← ارشيف ميد هستو



Like



Comment



ارشيف ميد هستو ▶ يوسف حاتم الطراونة



10 Mar 2019 at 14:05 •

T.B results in neutropenia and monocytosis



3

6 comments



Like



Comment



Turen Al-lawafya ▶ ارشيف ميد هستو



10 Mar 2019 at 14:00 •

choose the incorrect answer about the cardiac muscle:

It has satellite cells

مش متذكره بقية الاجابات



You, Rania Abdallah Sbieh and 3 others



Like



Comment



ارشيف ميد هستو ▶ يوسف حاتم الطراونة



10 Mar 2019 at 13:59 •

Incorrect about smooth muscles it has sarcotubules and T tubules

مش متأكد من نص السؤال



Rania Abdallah Sbieh and 3 others

1 Comment



Like



Comment



ارشيف ميد هستو ▶ يوسف حاتم الطراونة



10 Mar 2019 at 13:56 •

What is the type of junction that attaches intercalated disks with thin filaments desmosome adherents

You're in Data Mode ?

Go to Free

← ارشيف ميد هستو



10 Mar 2019 at 13:59 •

**Incorrect about smooth muscles** it has sarco**t**ubules and T tubules

مش متأكد من نص السؤال



Rania Abdallah Sbieh and 3 others

1 Comment



Like



Comment



ارشيف ميد هستو ▶ يوسف حاتم الطراونة



10 Mar 2019 at 13:56 •

**What is the type of junction that attaches intercalated disks with thin filaments** zonula adherents

مش متذكر الجواب بالضبط بس مش

Desmosomes



1

6 comments



Like



Comment



Laith F Najada ▶ ارشيف ميد هستو



10 Mar 2019 at 13:53 •

**About cardiac muscle which is incorrect**

the head of the myosin ratchet to the Z line during contraction

مش متأكد



3

6 comments



Like



Comment



ارشيف ميد هستو ▶ يوسف حاتم الطراونة



10 Mar 2019 at 13:53 •

**What is the intermediate filament that attaches to the macula adherence** keratin

مش متأكد من نص السؤال



You're in Data Mode ?

Go to Free

← ارشيف ميد هستو



10 Mar 2019 at 13:53 •

What is the intermediate filament that attaches to the macula adherence keratin

مش متأكد من نص السؤال



4

4 comments



Like



Comment



Laith F Najada ▶ ارشيف ميد هستو



10 Mar 2019 at 13:51 •

About skeletal muscle which is correct

it has a sarcotubules



Rania Abdallah Sbieh and 1 other



Like



Comment



ارشيف ميد هستو ▶ يوسف حاتم الطراونة



10 Mar 2019 at 13:49 •

The epithelium which is associated with goblet cells   
Pseudo stratified columnar epithelium



Rania Abdallah Sbieh and 2 others

2 comments



Like



Comment



Laith F Najada ▶ ارشيف ميد هستو



10 Mar 2019 at 13:47 •

In EM, the thing that present the eosinophils

crystalloid core



Rania Abdallah Sbieh and 1 other



Like



Comment

You're in Data Mode ?

Go to Free

← ارشیف مید هستو



Like



Comment



Sulaf Maaitah ▶ ارشیف مید هستو



10 Mar 2019 at 13:44 •



Zain JO 4G

1:43 PM

27%

&lt; Notes



March 10, 2019 at 1:42 PM

- \*most common type of cells in loose areolar cells ▶ fibroblasts
- \*ligaments are considered ▶ dense regular c.t
- \*bar body is present in ▶ neutrophils
- \*MHC1 is present in these cells except ▶ Red blood cells
- \*which cell has a cart wheel nucleus appearance ▶ plasma cell
- \*which cell is derived from activated B lymphocyte ▶ plasma cell
- \*differential leucocyte count ▶ the count of different WBCs to total count
- \*considered not true cell ▶ platelets
- \*echinocytes stand for ▶ crenation
- \*regarding granulomere which one is correct ▶ presence of ribosomes
- \*which one of these structures can't calcify ▶ external ear
- \*i can't remember the question form, but A bands remain same during contraction



You, Laith F Najada and 6 others

2 comments

You're in Data Mode ?

Go to Free

← ارشيف ميد هستو



Like



Comment



Laith F Najada ▶ ارشيف ميد هستو



10 Mar 2019 at 13:44 •

Which is correct about mast cell

✓ has metachromatic staining



1



Like



Comment



Laith F Najada ▶ ارشيف ميد هستو



10 Mar 2019 at 13:40 •

What is correct about the mast cell of the blood

✓ secrete histamine and heparin



يوسف حاتم الطراونة and 3 others

1 Comment



Like



Comment



Laith F Najada ▶ ارشيف ميد هستو



10 Mar 2019 at 13:40 •

What is the most common cell in the areolar CT

✓ fibroblast



يوسف حاتم الطراونة and 2 others

1 Comment



Like



Comment



Rashed Alqaisi ▶ ارشيف ميد هستو



10 Mar 2019 at 13:39 •

المكون الأساسي للنسيج المخاطي :

1-بكتيريا

You're in Data Mode ?

Go to Free

← أرشيف ميد هستو

What is correct about the mast cell of the blood

✓ secrete histamine and heparin

👍❤️ يوسف حاتم الطراونة and 3 others

1 Comment



Like



Comment



Laith F Najada ▶ أرشيف ميد هستو



10 Mar 2019 at 13:40 • 👤

What is the most common cell in the areolar CT

✓ fibroblast

👍❤️ يوسف حاتم الطراونة and 2 others

1 Comment



Like



Comment



Rashed Alqaisi ▶ أرشيف ميد هستو



10 Mar 2019 at 13:39 • 👤

المكون الأساسي للنسيج المخاطي :

1-بكتيريا

2-يوسف حجازين

3-مكونات لزجة غير مفهومة المكون

هيك بتذكر السؤال والله أعلم 🙏❤️

😂👍 يوسف حاتم الطراونة and 9 others



Like



Comment



Laith F Najada ▶ أرشيف ميد هستو



10 Mar 2019 at 13:38 • 👤

Which is not a true cell

✓ platelets

❤️👍 Shukri AlOmari and 2 others

7 comments

You're in Data Mode ?

Go to Free

← ارشيف ميد هستو



Laith F Najada ▶ ارشيف ميد هستو



10 Mar 2019 at 13:38 •

Which is not a true cell

✓platelets

Shukri AlOmari and 2 others

7 comments



Like



Comment



Laith F Najada ▶ ارشيف ميد هستو



10 Mar 2019 at 13:37 •

Which is incorrect about brown adipose tissue

✓high rER

2

13 comments



Like



Comment



Feras A. Ahmad ▶ ارشيف ميد هستو



10 Mar 2019 at 13:36 •

What is true about kidney tubule

Basal infolding

Laith F Najada and 3 others

3 comments



Like



Comment



Feras A. Ahmad ▶ ارشيف ميد هستو



10 Mar 2019 at 13:34 •

ايش الجمل الصحيحة

Red fiber... Tires fastly

You're in Data Mode ?

Go to Free

← أرشيف ميد هستو

ايش الجمل الصحيحة

Red fiber... Tires fastly

في جملة ثانية كمان صح بس انا حطيت هاي  
حسيت السؤال فيه غلط

 2

10 comments

 Like

 Comment



Eslam Alhloul ▶ أرشيف ميد هستو

10 Mar 2019 at 13:34 • 

A blood picture of a patient shows the number of leukocytes  
16.000 and the percentage of is neutrophils 90%. The diagnosis :

أنا جاوبتها

Acute infection

 Feras A. Ahmad

9 comments

 Like

 Comment


Nadine Alamat ▶ أرشيف ميد هستو

10 Mar 2019 at 13:33 • 

\*One of the following is not present in rib cartilage

كان مكتوب كل مكونات hyaline الخطأ troponin

\*milk secretions -- apocrine

\*halocrine سؤال عن ال

\*the mother cell of formed elements -- bone marrow اشفي زي هيك

\*one of the following is not a function of basement membrane

\*Perichondrium is not essential in ..... See more

 1

 Like

 Comment


Eslam Alhloul ▶ أرشيف ميد هستو





You're in Data Mode ?

Go to Free

← ارشيف ميد هستو

\*One of the following is not present in rib cartilage

troponin كان مكتوب كل مكونات hyaline الخطأ

\*milk secretions -- apocrine

\*halocrine سؤال عن ال

\*the mother cell of formed elements – bone marrow اشبي زي هيڪ

\*one of the following is not a function of basement membrane

\*Perichondrium is not essential in ...

\*One of the following is correct about kidney tubules

\*goblet cell سوال عن ال

One of the following can handle tensile strength

مو حرفي الاسئله

1



Like



Comment



Eslam Ahloul ارشيف ميد هستو

10 Mar 2019 at 13:33 •

What type of epithelium lines most of the skin openings :

stratified squamous epithelium



Rania Abdallah Sbieh and 3 others

1 Comment



Like



Comment



Feras A. Ahmad ارشيف ميد هستو

10 Mar 2019 at 13:33 •

الاسم الثاني ل anicer

Alveolar



Rania Abdallah Sbieh and 1 other



Like



Comment



Feras A. Ahmad ارشيف ميد هستو



You're in Data Mode ?

Go to Free

← ارشيف ميد هستو



Feras A. Ahmad ▶ ارشيف ميد هستو



10 Mar 2019 at 13:33 •

الاسم الثاني ل anicer

Alveolar

Rania Abdallah Sbieh and 1 other



Like



Comment



Feras A. Ahmad ▶ ارشيف ميد هستو



10 Mar 2019 at 13:32 •

Attachment on the epididymmis  
Stereo cilia

2

10 comments



Like



Comment