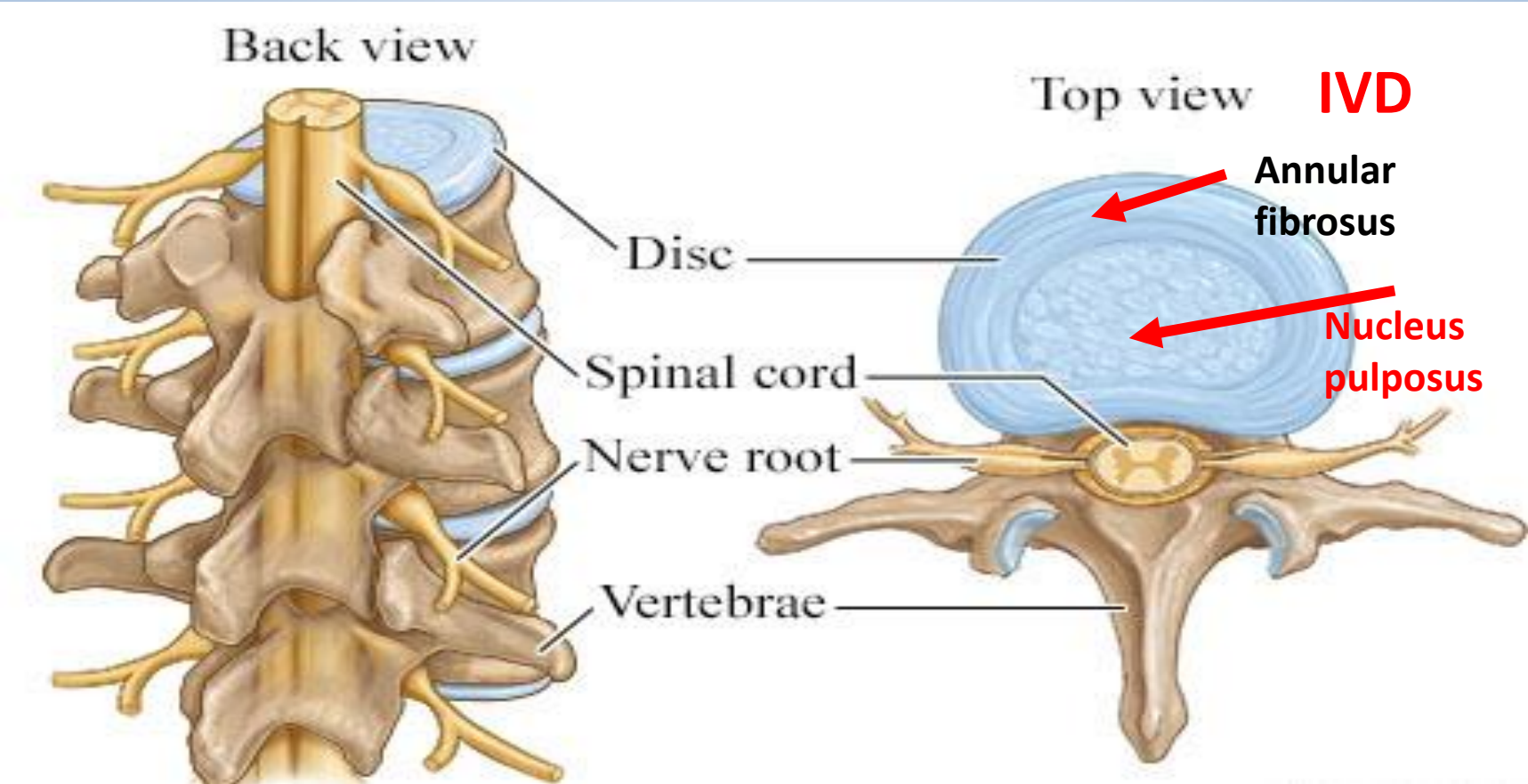




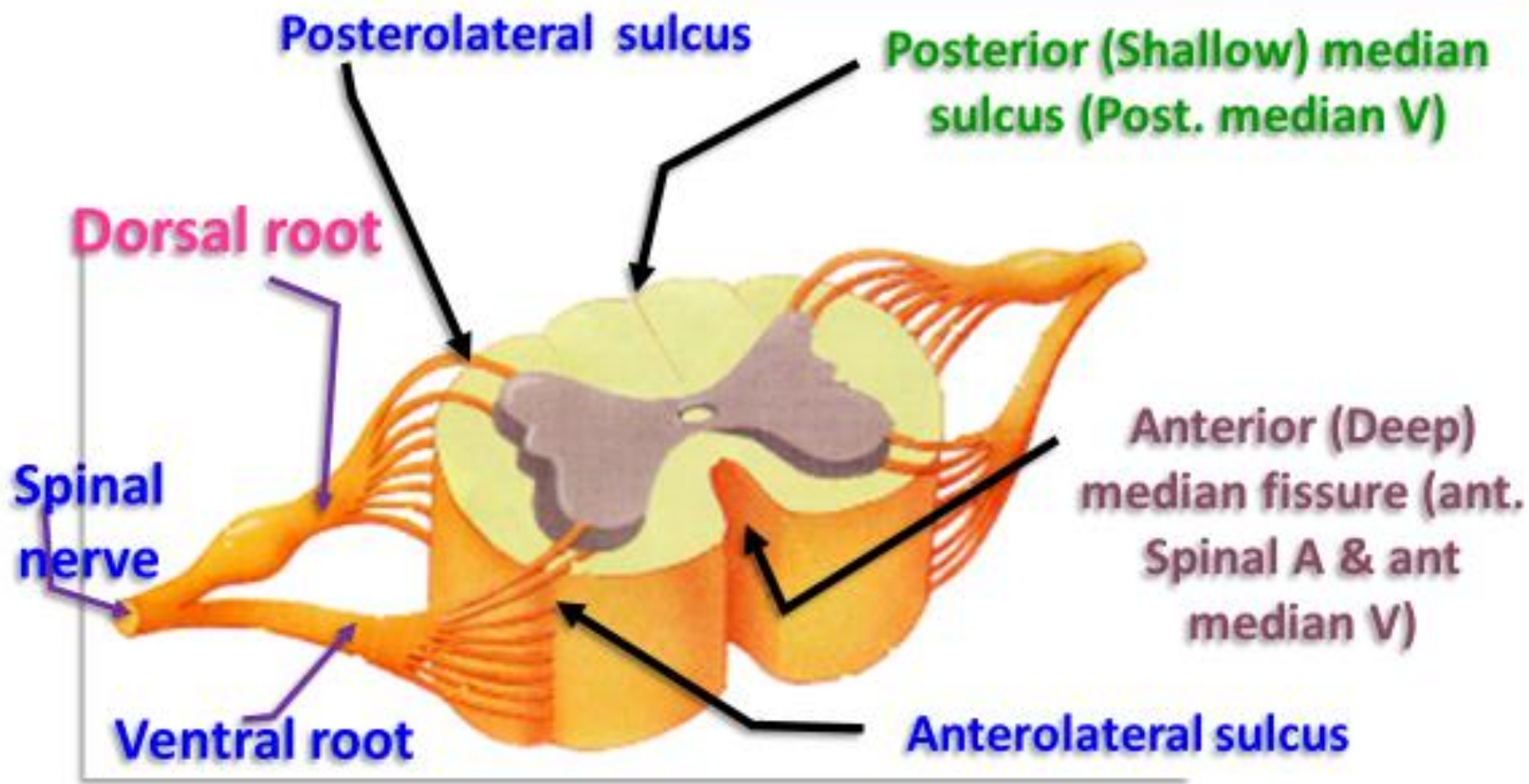
بِسْمِ اللَّهِ الرَّحْمَنِ الرَّحِيمِ

Position of the spinal cord

in the vertebral canal of the vertebral column

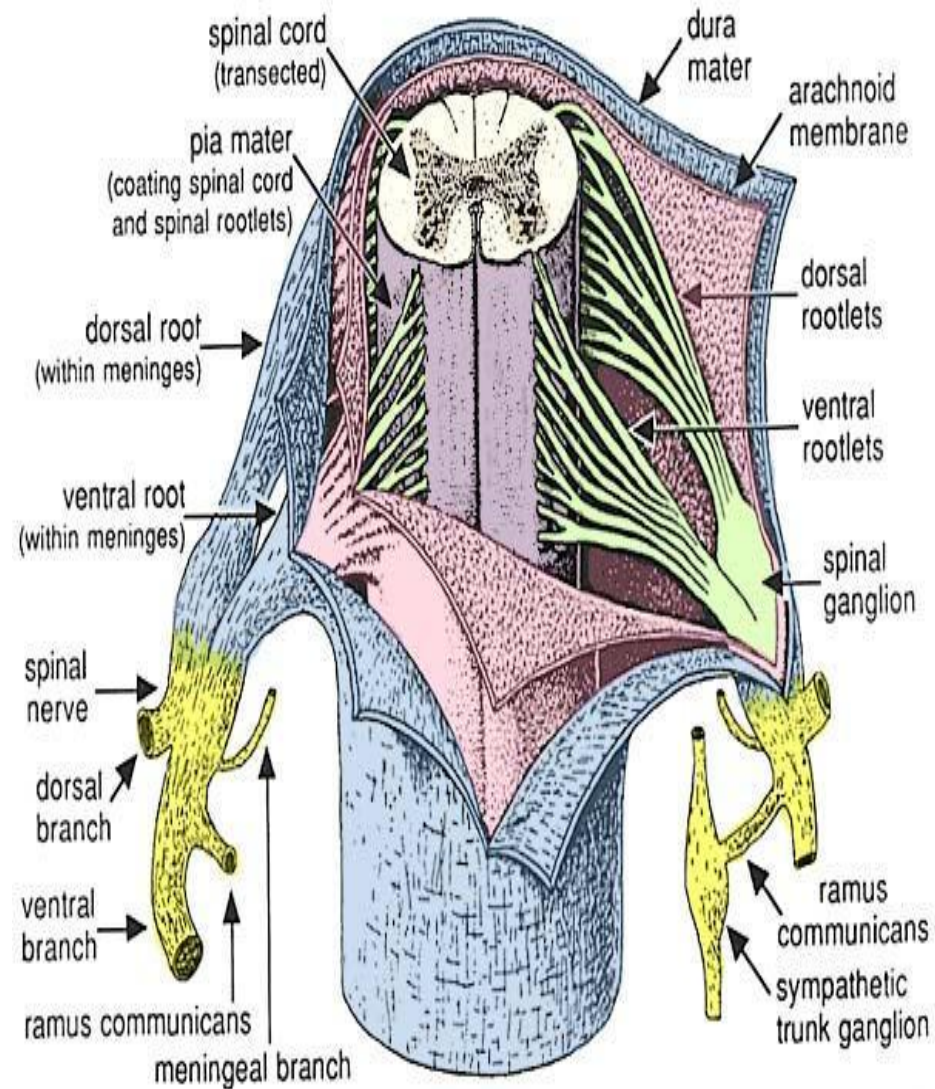


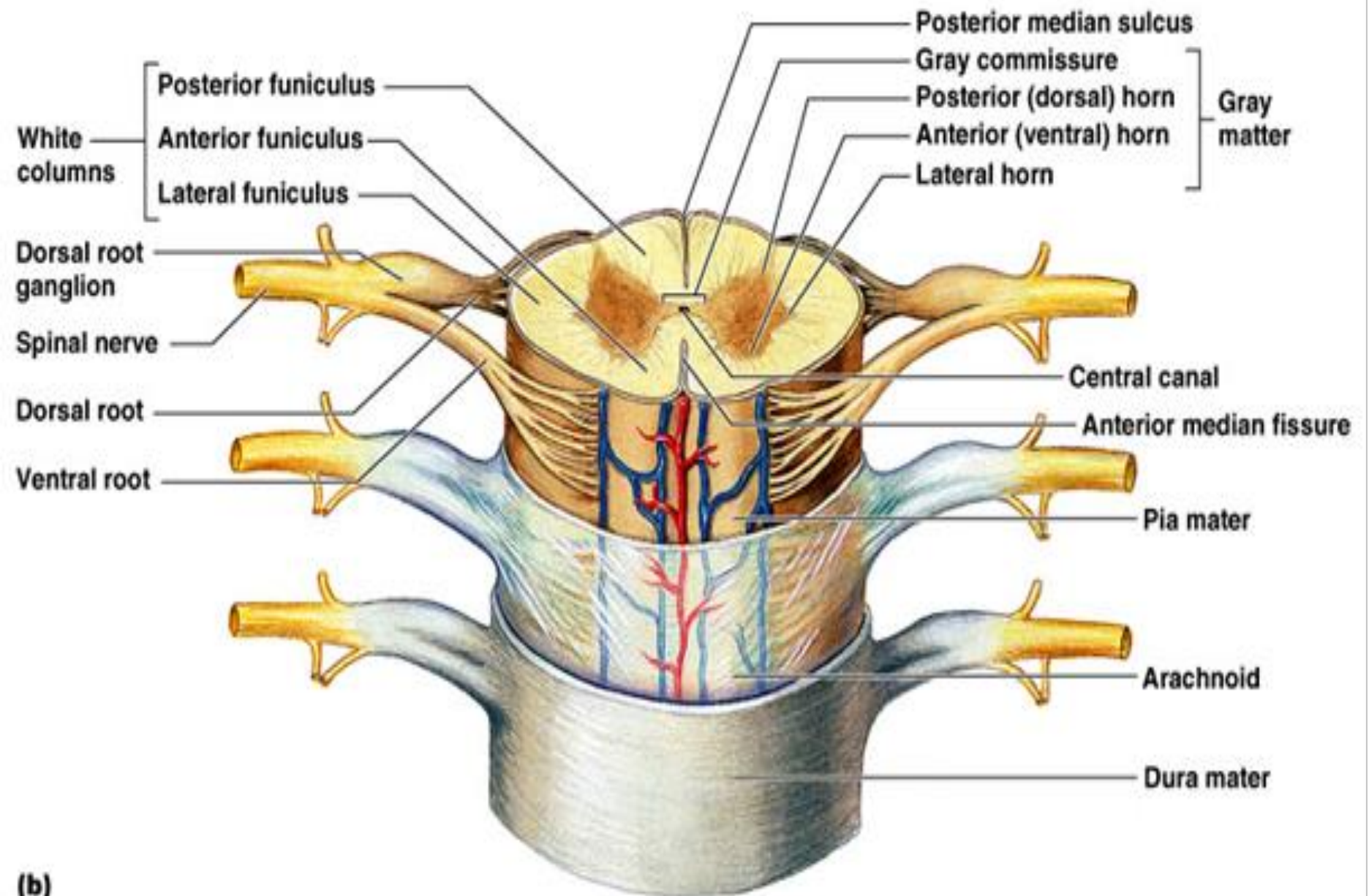
Surface of spinal cord



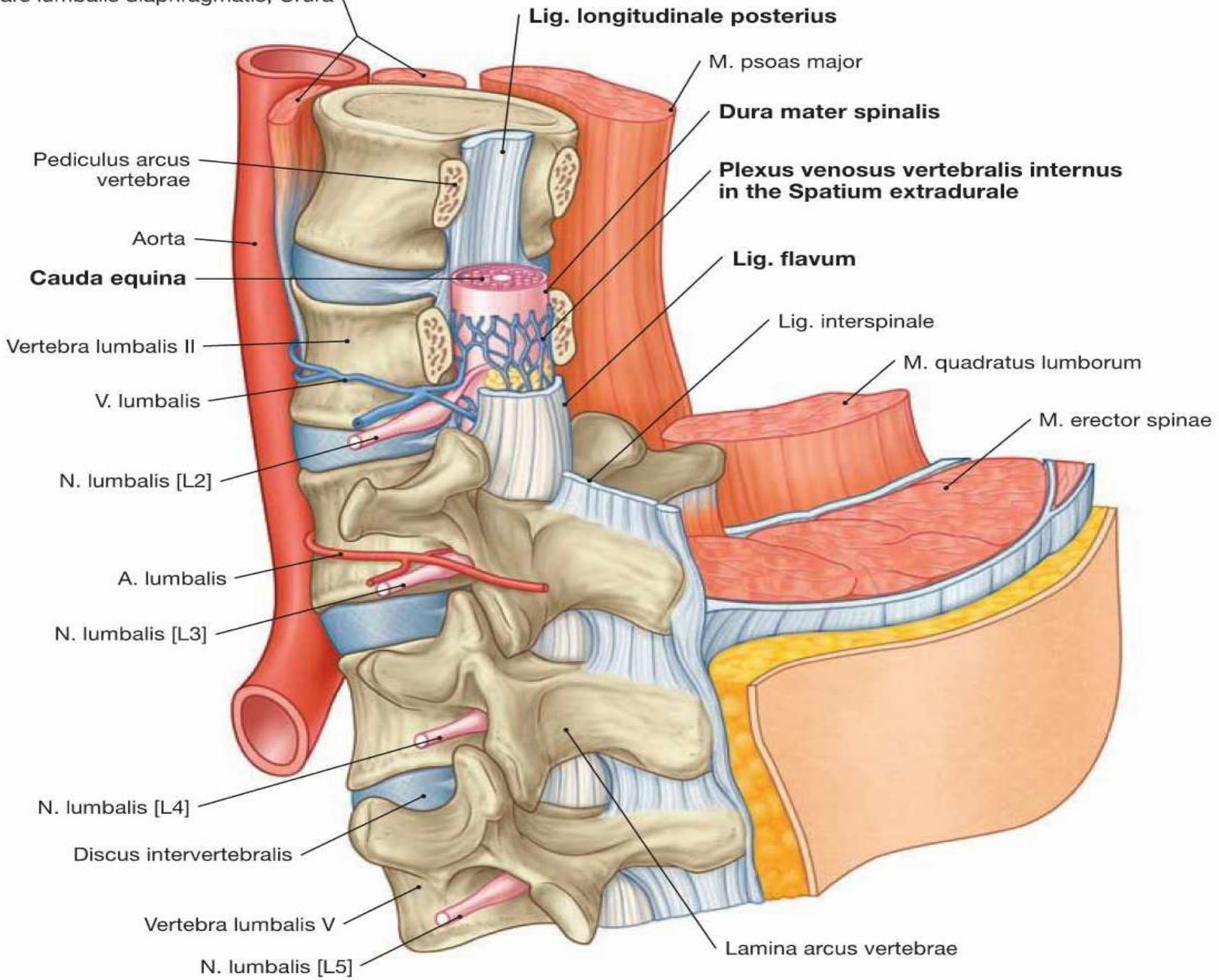
Spinal nerves

- The anterior and posterior roots merge just before the intervertebral foramen and form the trunk of the spinal nerve. The trunk is very short, and soon after exiting the vertebral column, it divides into four branches: anterior ramus, posterior ramus, communicating ramus, and meningeal ramus.





(b)
 Copyright © 2004 Pearson Education, Inc., publishing as Benjamin Cummings.



Arterial supply

3- segmental arteries: supply the lateral part of the spinal cord

- They enter vertebral canal through intervertebral foramina.

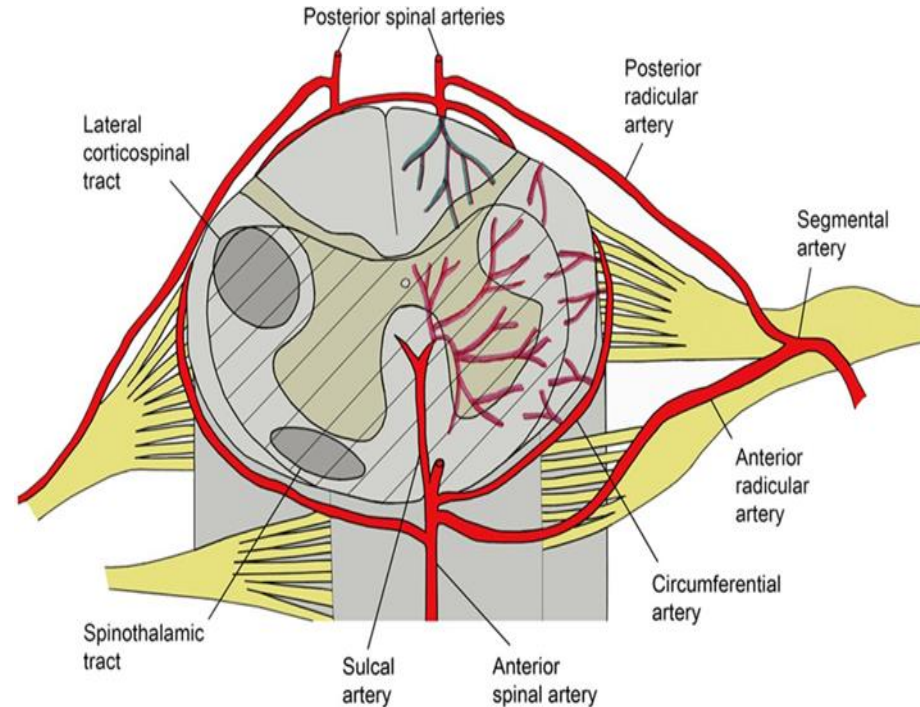
a- Cervical region: from the 2nd part of vertebral artery and ascending cervical artery.

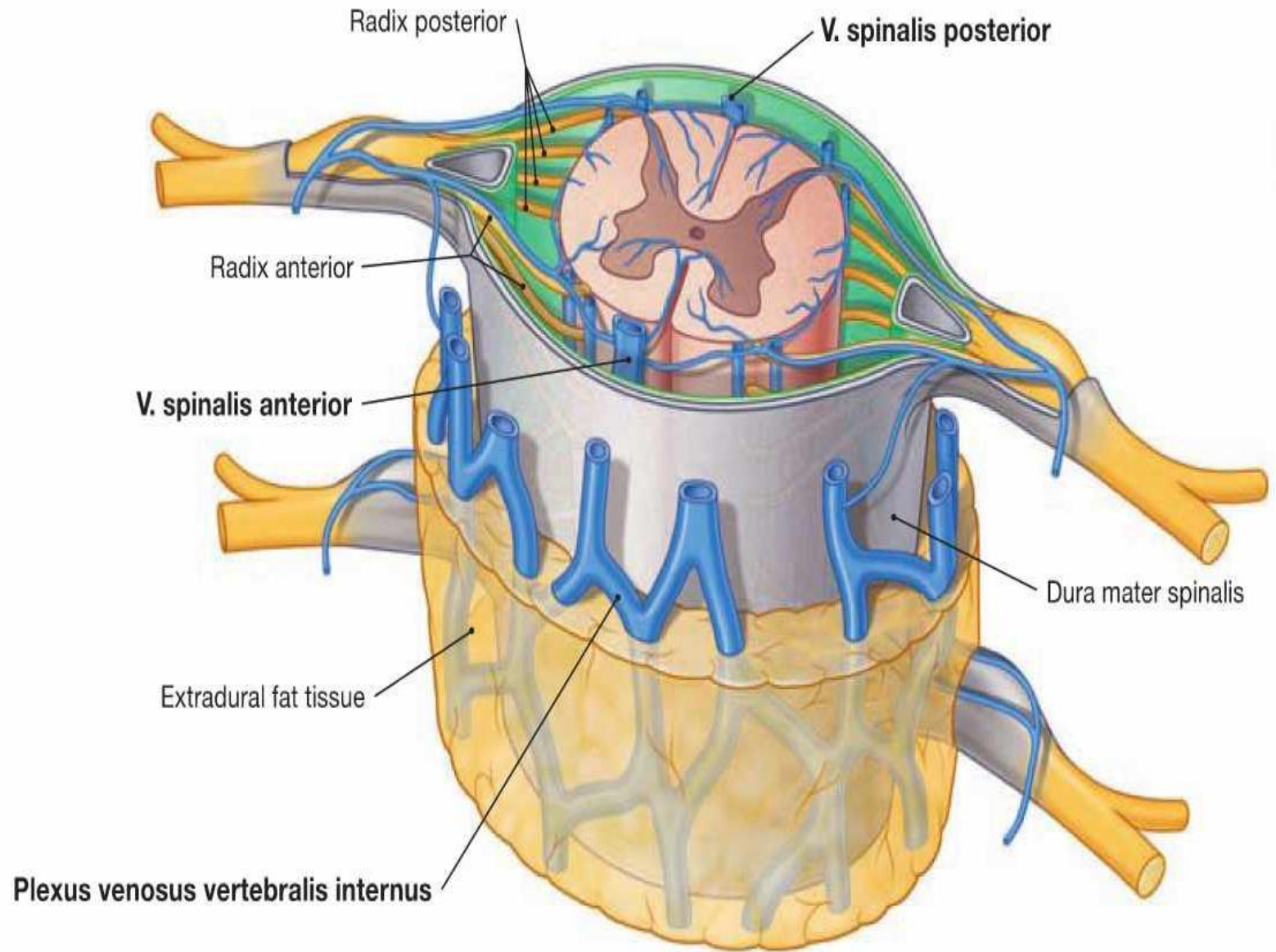
b- Thoracic region: from posterior intercostal and subcostal arteries.

c- In the lumbar region: from the lumbar arteries.

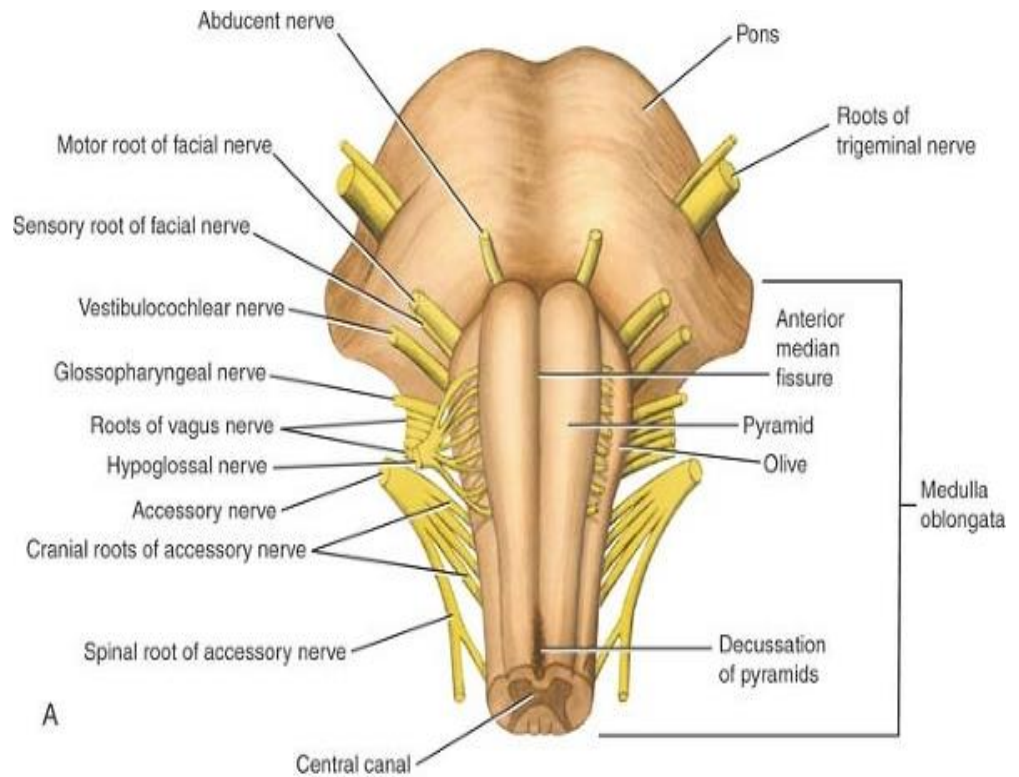
d- In the sacral region, the lateral sacral arteries

- In each segment, the **segmental arteries** that enter the intervertebral foramina divided into anterior & posterior radicular arteries & accompany the dorsal and **ventral & dorsal nerve roots**.
- These branches unite directly with the posterior and anterior spinal arteries to form ring of arteries (**an arterial corona**).

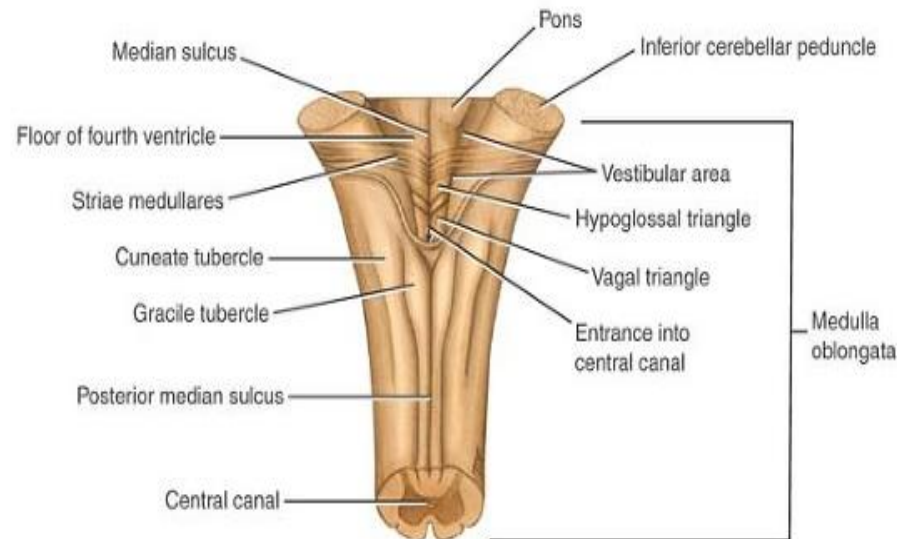



- The elevation on each side of the anteromedian fissure is called **pyramid**. It is formed by **the corticospinal fibers**.
- The oval elevation lateral to the pyramid is called **olive** and is formed by the bulging of the **inferior olivary nucleus**.
- The groove between the pyramid and the olive is called **anterolateral sulcus** and it gives exit for the **rootlets of the hypoglossal nerve**.

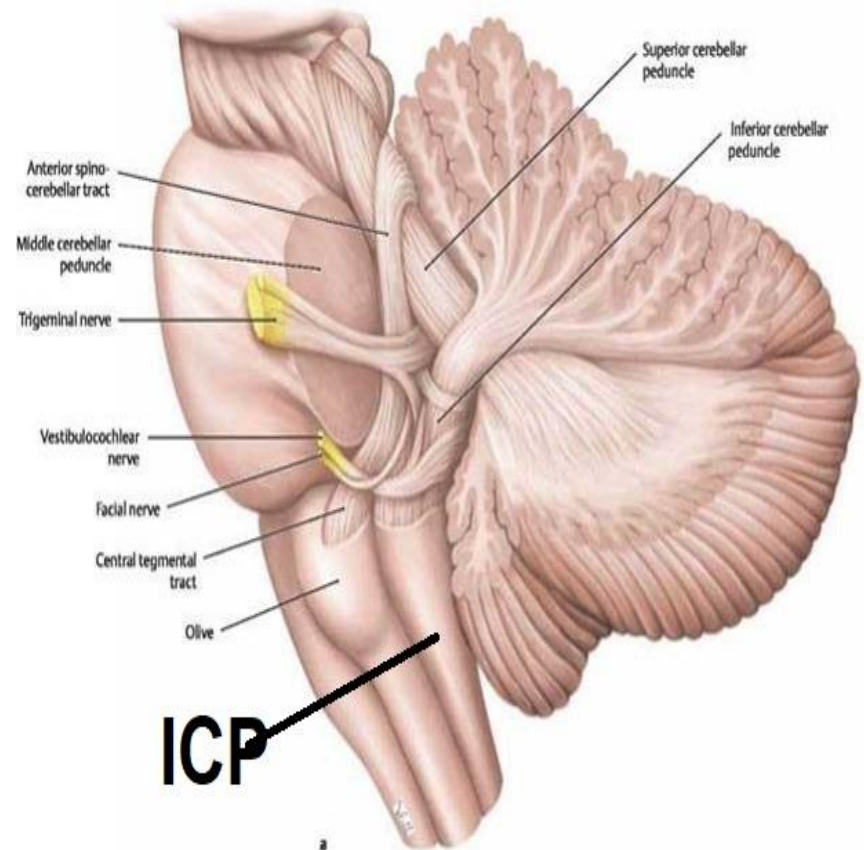


A



B

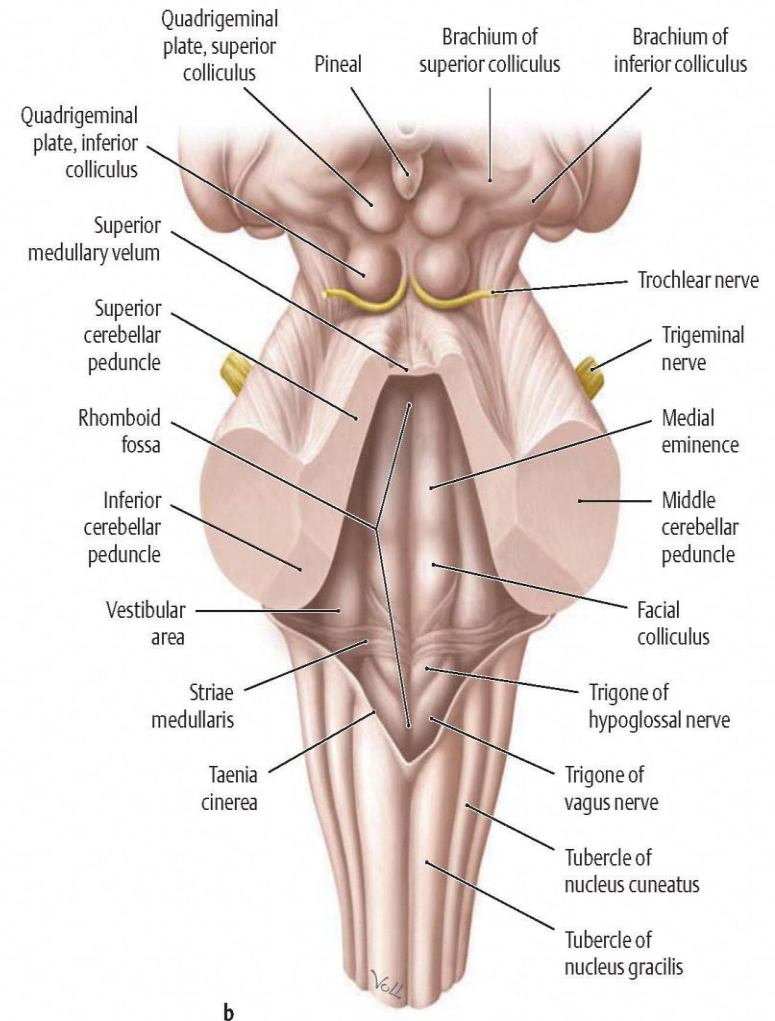
- The groove lateral to the olive is called **posterolateral sulcus**. It gives exit to the rootlets of the glossopharyngeal, vagus and cranial accessory nerves arranged from above downwards.
- **Posterolateral sulcus** separates the olive from the inferior cerebellar peduncle(ICP)



B. Dorsal surface:

1- closed medulla

- A **posteromedian sulcus** which is an upward continuation of the posteromedian sulcus of the spinal cord. It extends up to the lower angle of the fourth ventricle.
- The longitudinal elevation lateral to the posteromedian sulcus is called **gracile fasciculus** as it overlies the gracile tract. its upper end expands to form the **gracile tubercle** which overlies the gracile nucleus.
- The longitudinal elevation lateral to the gracile fasciculus is called **cuneate fasciculus** as it overlies the cuneate tract. Its upper end expands to form the **cuneate tubercle** which overlies the cuneate nucleus.
- The ridge lateral to the cuneate tubercle is the **inferior cerebellar peduncle**



E Brainstem

b Posterior view.

Illustrator: Markus Voll

pp. 226-227

Schuenke et al. THIEME Atlas of Anatomy • Head and Neuroanatomy
© THIEME 2007 • All rights reserved. Usage subject to terms of use. • www.thieme.com/taa

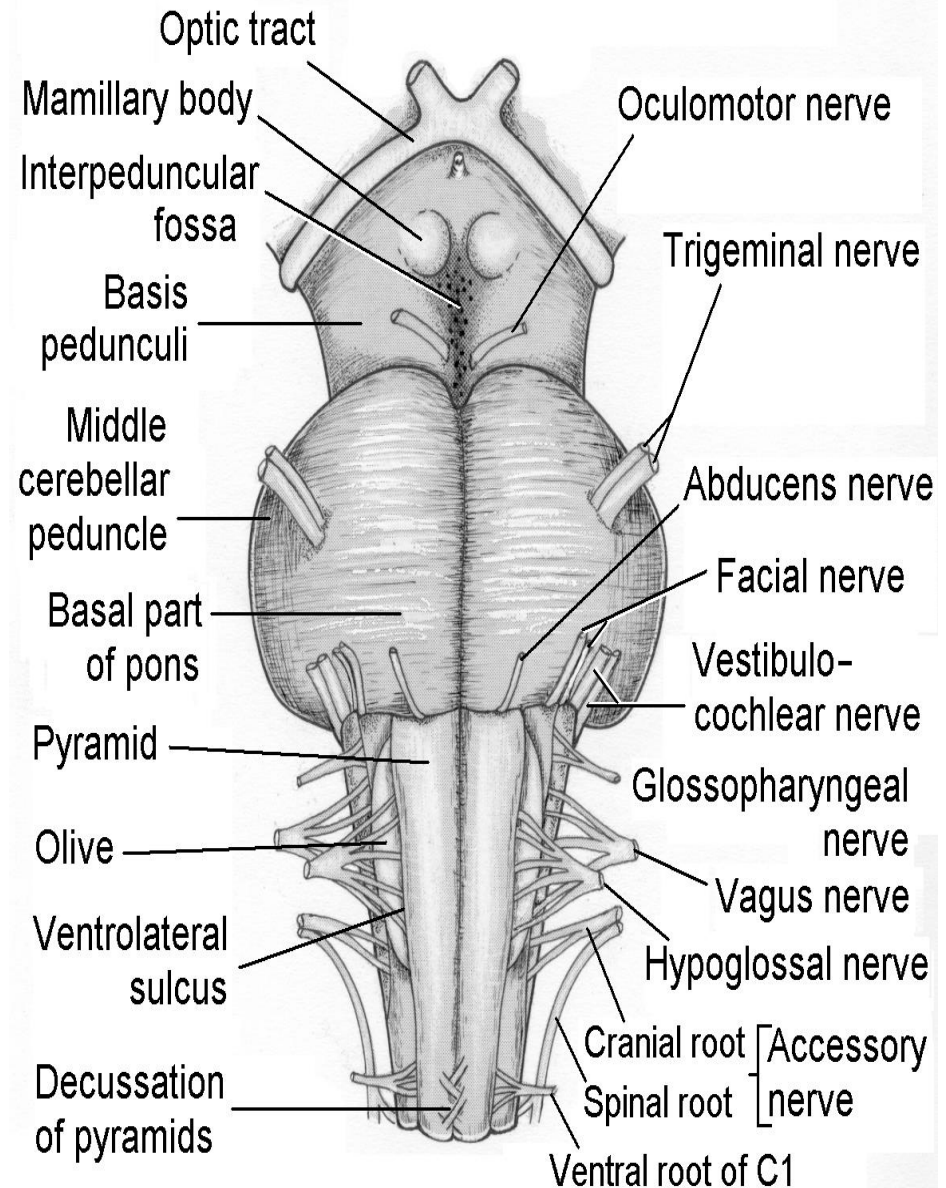
External features of the pons

A. The ventral surface :

- It is convex from side to side; laterally it is continuous with the middle cerebellar peduncle on each side.

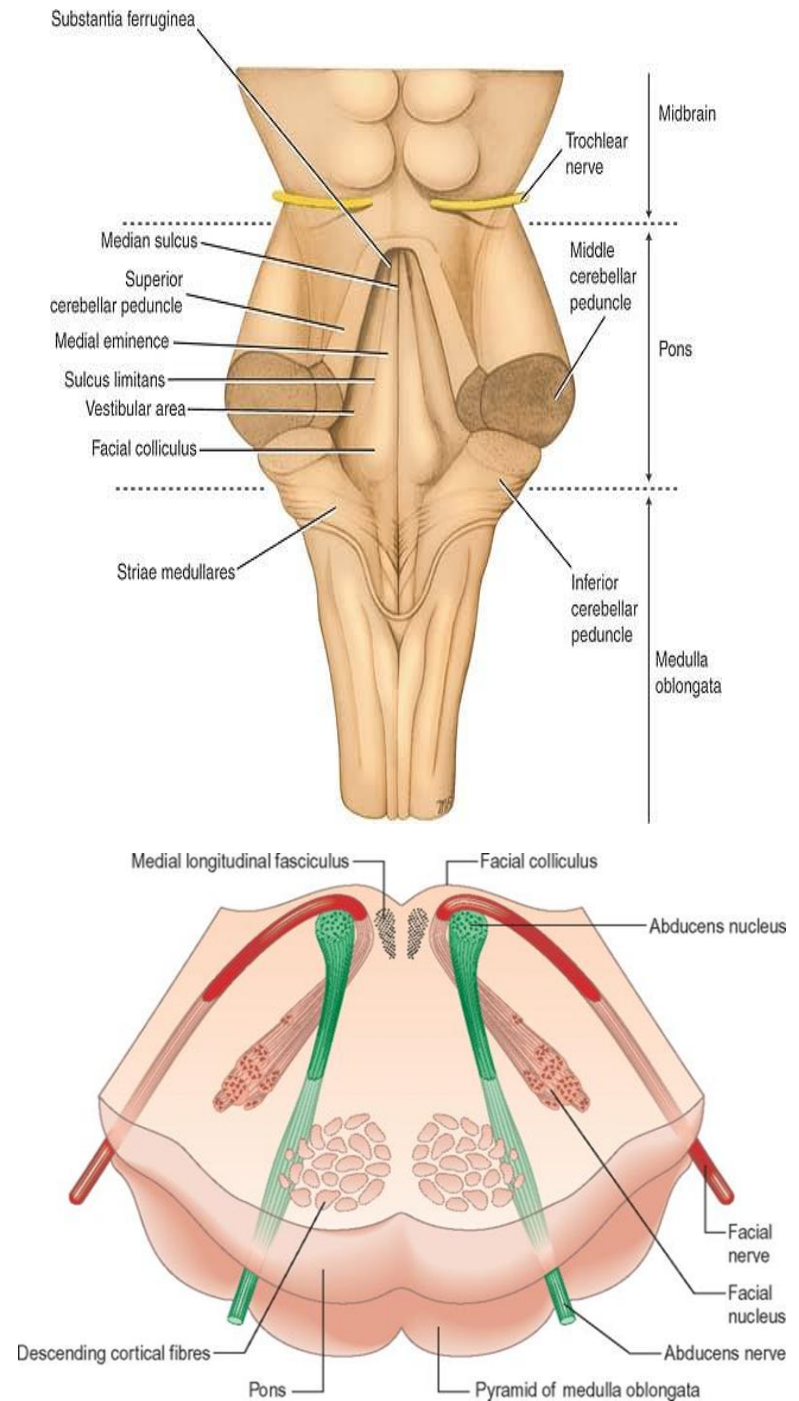
- It presents a median groove called **basilar groove** as it lodges the basilar artery.

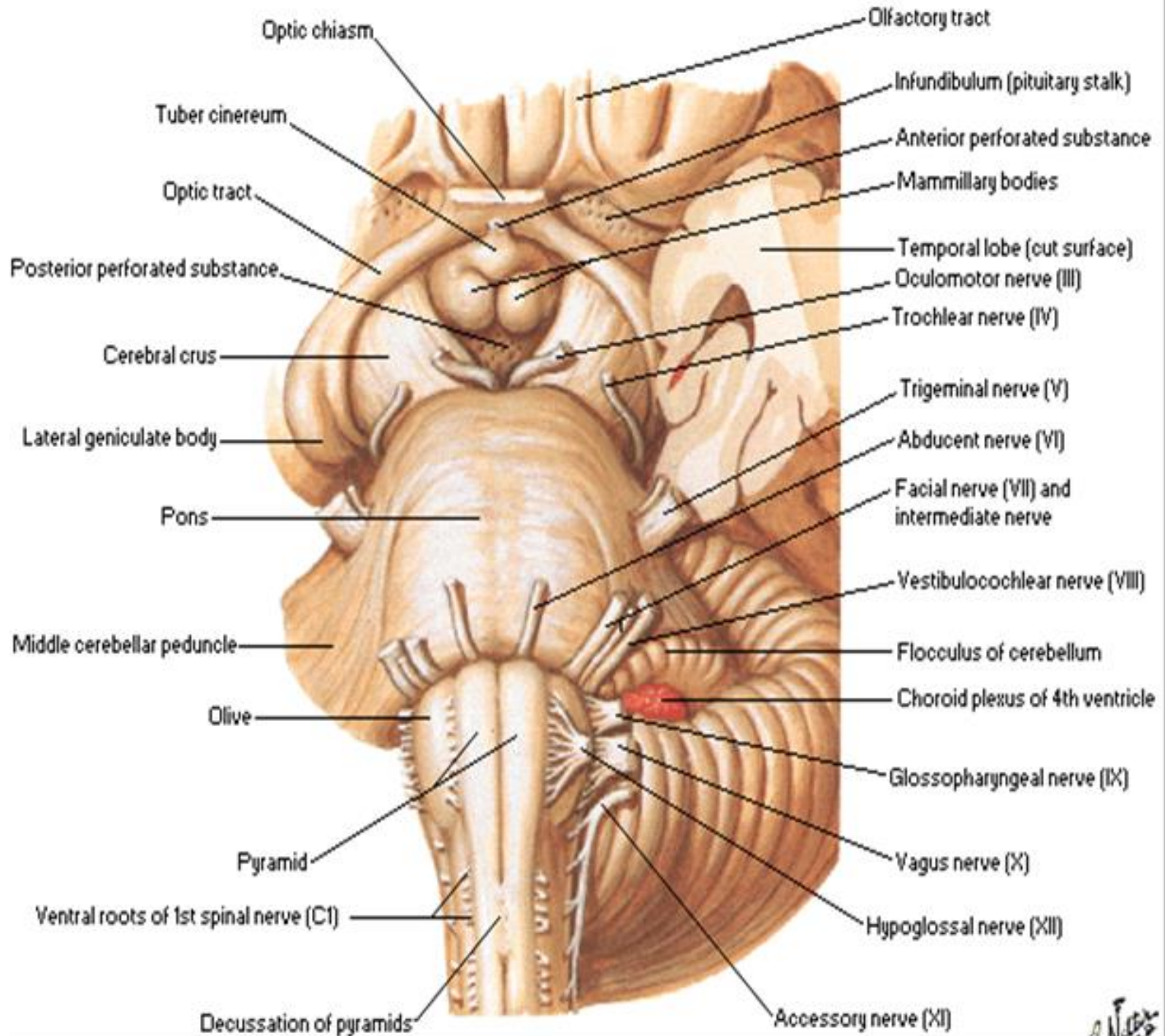
- **The trigeminal nerve** emerges from the middle part of the pons at its junction with the middle cerebellar peduncle. The **abducent nerve** emerges at the lower border of the pons, between it and the pyramid. The **facial and vestibulo-cochlear nerves** also emerge at the lower border of the pons, between it and the olive (The facial nerve is medial to the vestibulo-cochlear).



B. The dorsal surface:

- It forms the upper part of the floor of the fourth ventricle. It presents a depression called **superior fovea** that separates the **medial eminence** from the **upper vestibular area**.
- The lower part of the medial eminence presents a prominent elevation called **facial colliculus**. This **colliculus** is produced by the **abducent nucleus** surrounded by the **facial nerve fibers**. The **upper vestibular area** is produced by the **lateral and superior vestibular nuclei**.





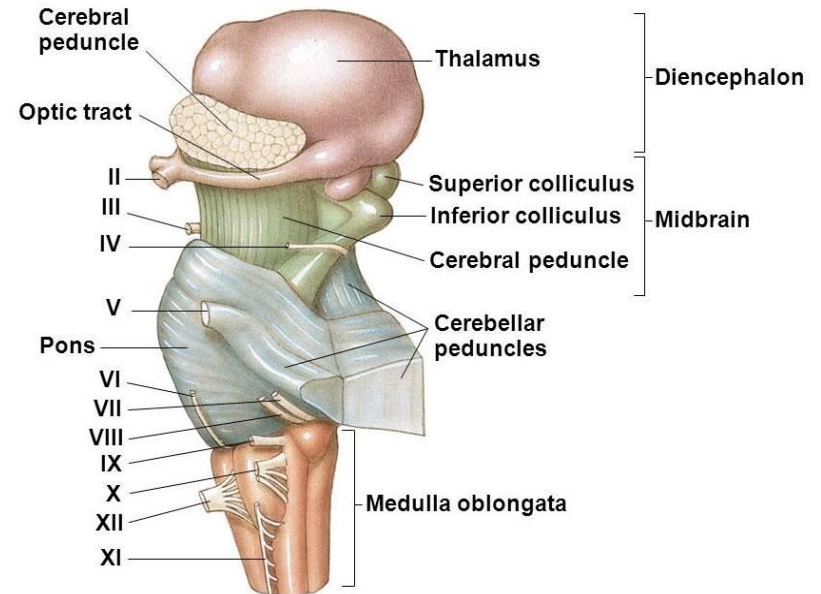
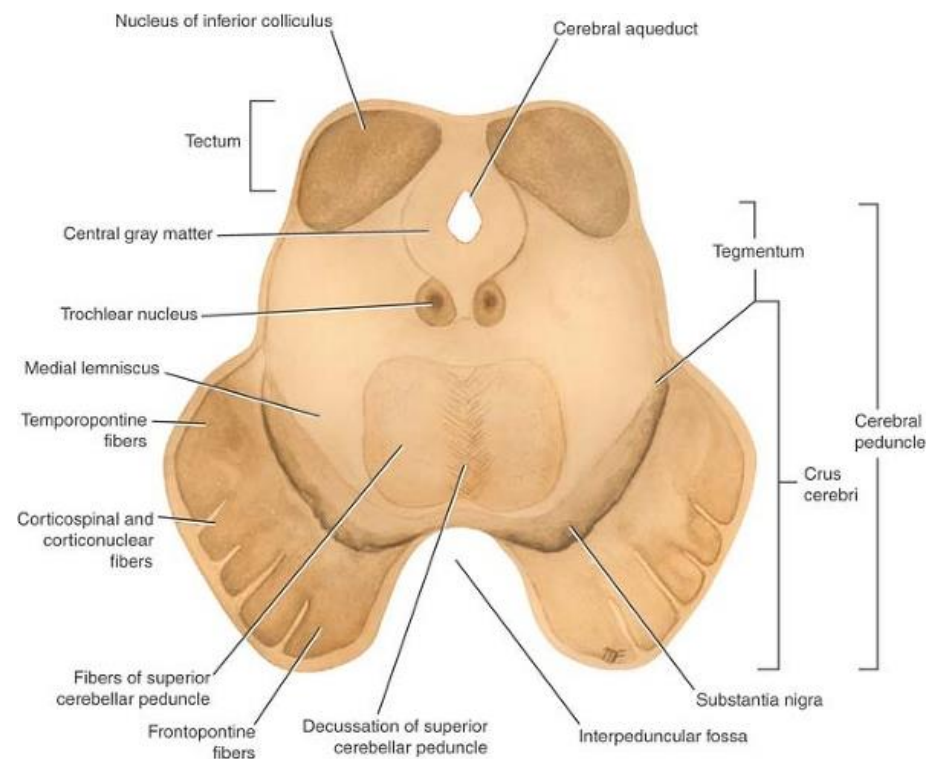
1 . Crus cerebri This is formed of bundles of nerve fibers descending from the cerebral cortex to lower levels of the brain stem and spinal cord. These fibers constitute the corticopontine, corticonuclear and corticospinal fibers (will be given later).

The crus cerebri is crossed by:

- a. Basal vein.
- b. Superior cerebellar artery.
- c. Posterior cerebral artery.
- d. Trochlear nerve.
- e. Optic tract.

2 . Substantia nigra: It is a lamina of pigmented grey matter containing melanin pigment.

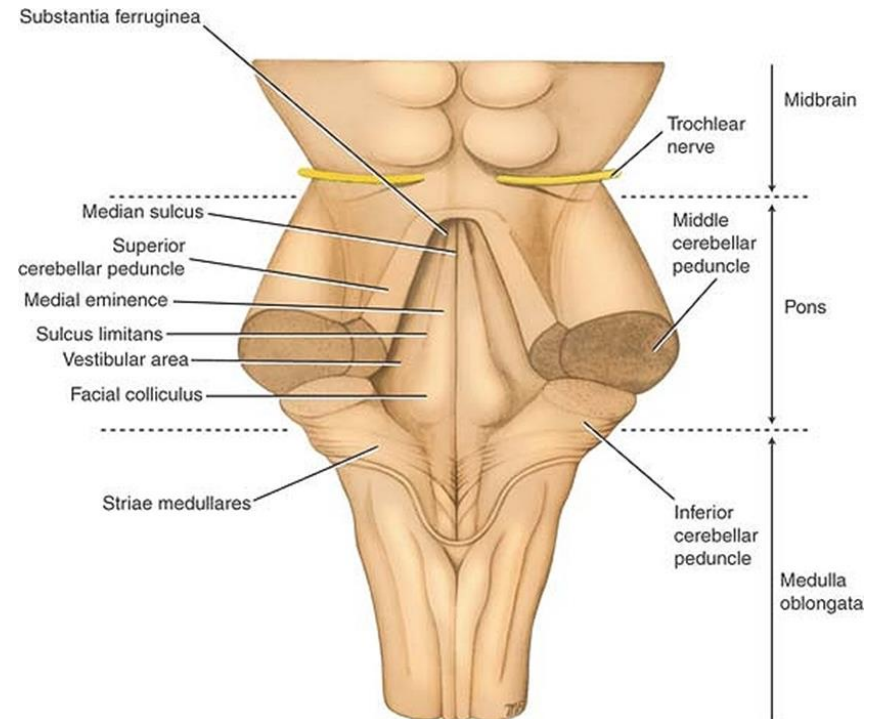
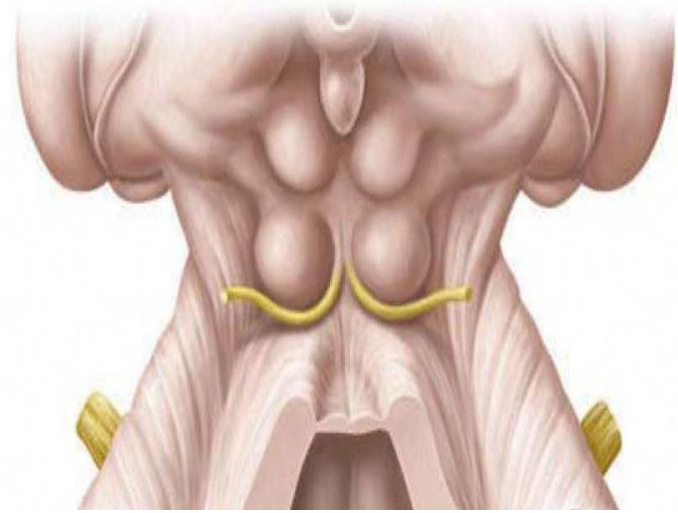
3. Tegmentum: This is the posterior part of the cerebral peduncle and is continuous inferiorly with the tegmentum of the pons.



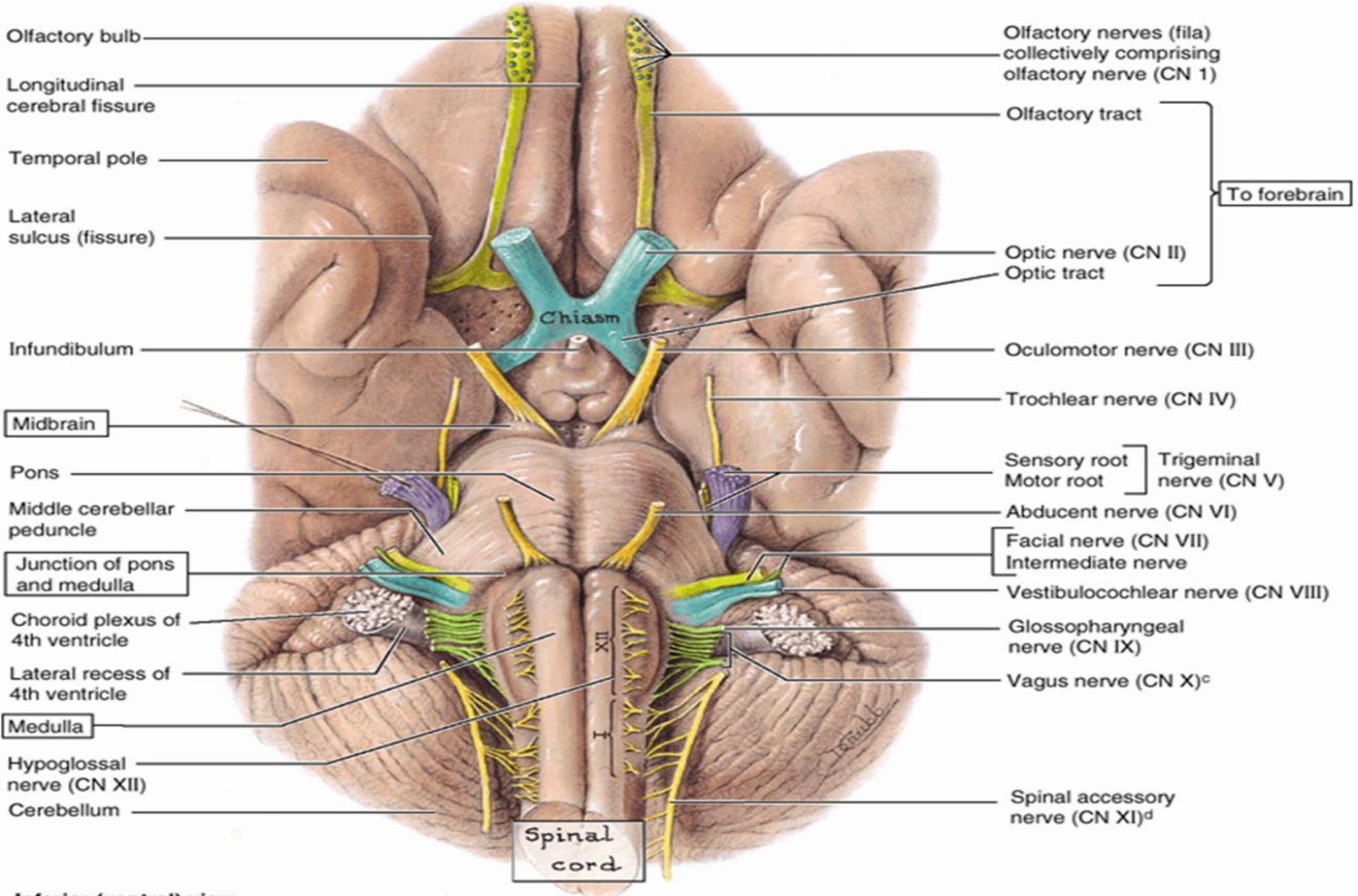
(a) Lateral view

B. Tectum : This is the smaller dorsal part of the midbrain. The tectum is formed of four Knob-like elevation called **colliculi**. They are arranged as two superior and two inferior colliculi.

- Each colliculus gives rise to a **brachium** from its lateral side. The superior brachium connects the superior colliculus with the lateral geniculate body. The inferior brachium connects the inferior colliculus with the medial geniculate body.



EXIT OF CRANIAL NERVES FROM



Inferior (ventral) view

Fourth ventricle

It is a tent- like cavity of the hindbrain. It lies between the pons & medulla anteriorly and the cerebellum posteriorly.

Boundaries of the 4th ventricle

Roof:

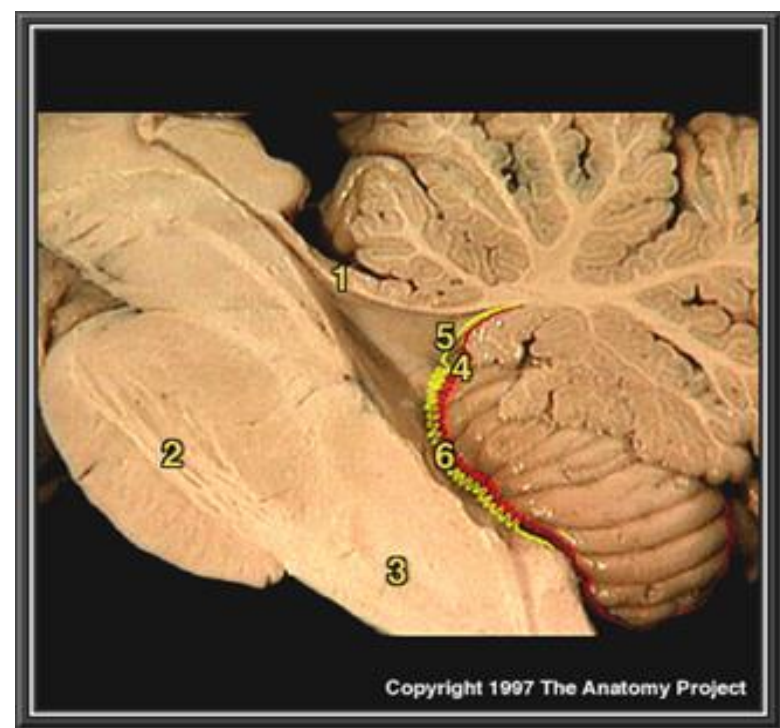
Upper part: the superior medullary velum stretching inbetween the superior cerebellar peduncles.

Middler part : cerebellum

Lower part: Inferior medullary velum stretching in between the two inferior cerebellar peduncles.

Lateral wall :

- **Upper part:** superior cerebellar peduncles.
- **Lower part:** inferior cerebellar peduncles and gracile & cuneate tubercles.



- 1- Superior medullary vellum.
- 2- Pons.
- 3- Medulla oblongata.
- 4- Pia matter.
- 5- Ependyma.
- 6- Choroid plexuses.

- **Floor (Rhomboidal fossa)**

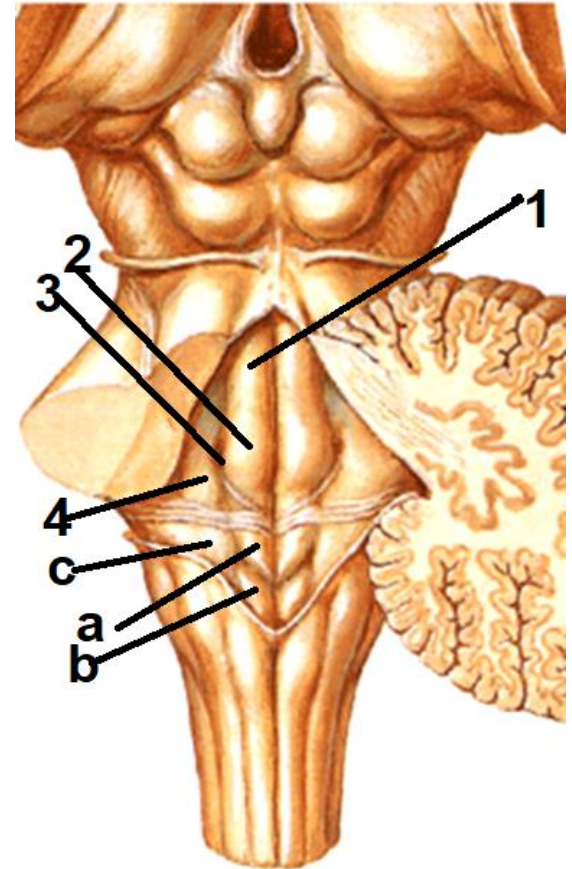
- **Median sulcus** divides floor into right and left halves, extends from superior to inferior angle.
- **Stria medullaris** divides the floor into upper part (**pontine**) and lower part (**medullary**).

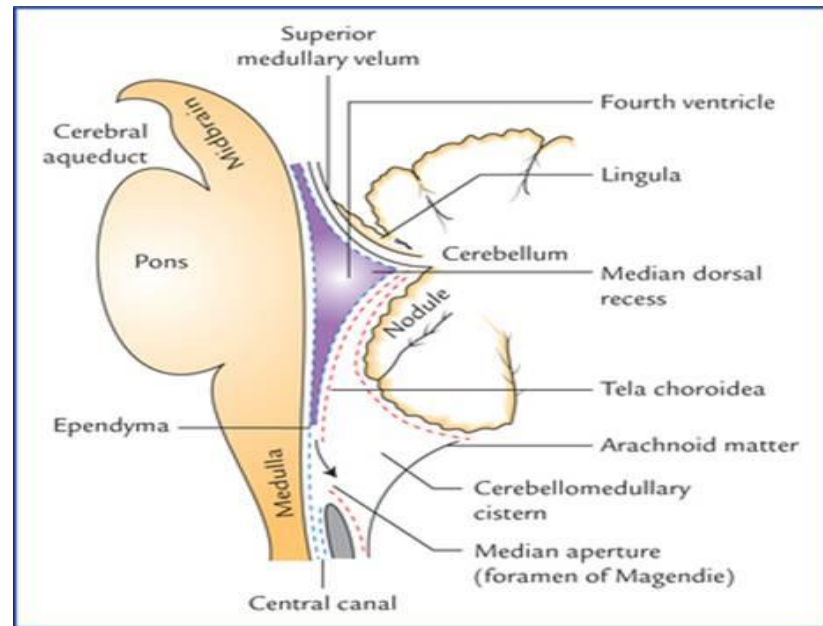
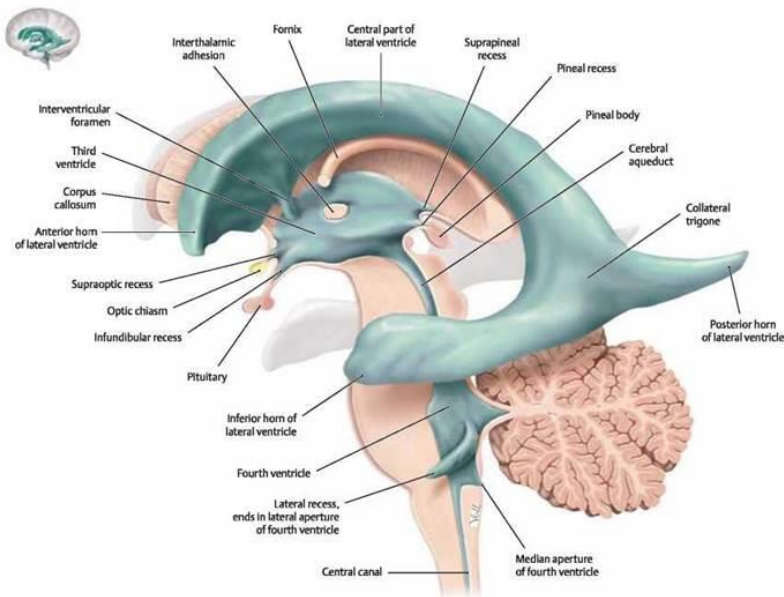
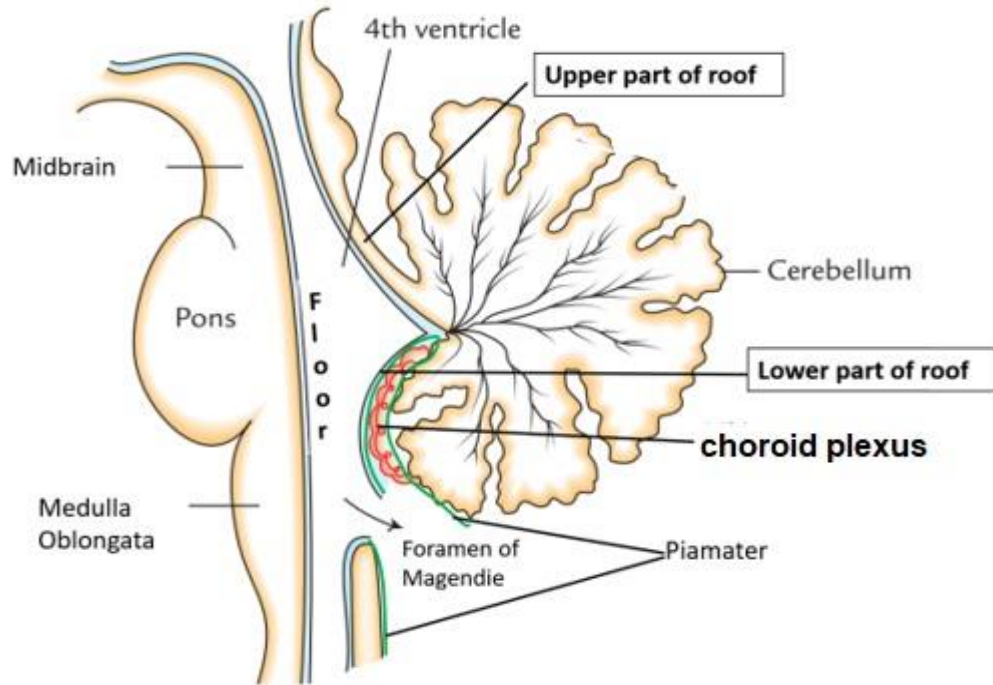
A- The medullary (lower) part presents on each side of the median sulcus,

- An inverted V shaped groove called **inferior fovea**.
- a- Hypoglossal area (trigone)** medial to inferior fovea.
- b- Vagal area (trigone)** between 2 limbs of inferior fovea.
- c- Vestibular area (trigone)** lateral to inferior fovea.

B- The pontine (Upper) part presents on each side of the median sulcus,

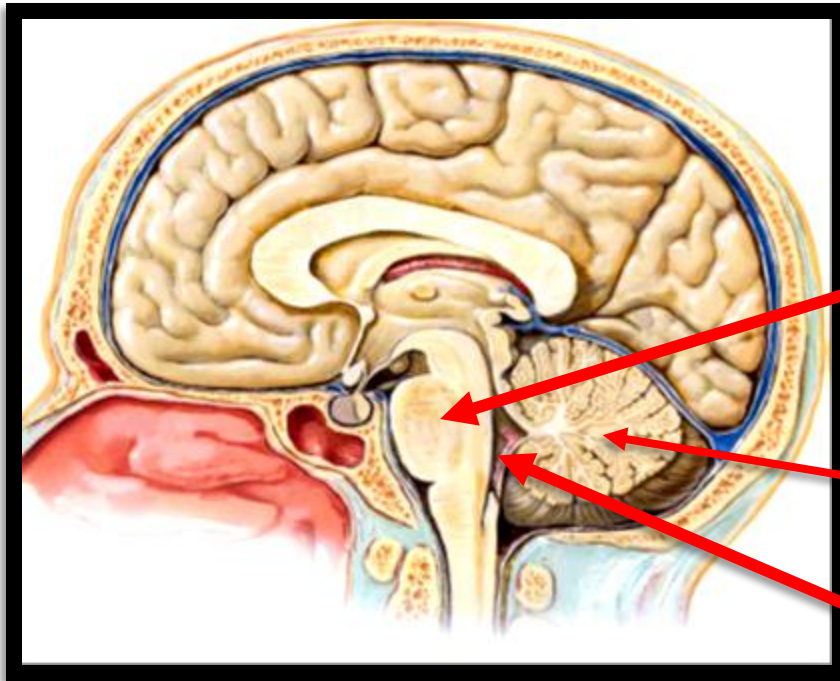
- 1- Medial eminence:** a longitudinal elevation on each side of the median sulcus,
- 2- Facial colliculus;** a round swelling on the lower part of the medial eminence.
- 3- Superior fovea,** a groove lateral to the facial colliculus.
- 4- Vestibular area,** lateral to superior fovea. It overlies superior, medial and lateral vestibular nuclei.





The cerebellum

- The cerebellum is the largest subdivision of the hindbrain.
- * **Position**; It lies posterior to the pons and medulla oblongata separated from them by **the 4th ventricle**.
- It occupies the greater part of **the posterior cranial fossa**.
- It is covered by **the tentorium cerebelli** separating it from the cerebral hemisphere.



PONS

Cerebellum

4th ventricle

• EXTERNAL FEATURES

- It is formed of a median part called **the vermis** and **2 cerebellar hemisphere**.

1- It has 2 surfaces (superior and inferior)

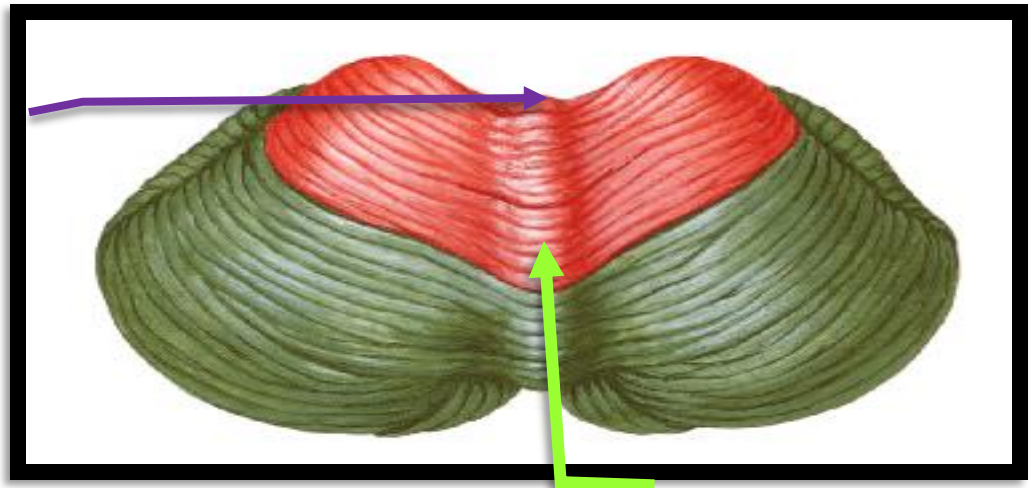
A- Superior surface,

- The middle part is raised and called **the superior vermis**.

- **The lingula** is the most anterior part of **the superior vermis**.

- The superior surface of each cerebellar hemisphere is nearly flat and slopes downwards and laterally.

lingula



superior vermis

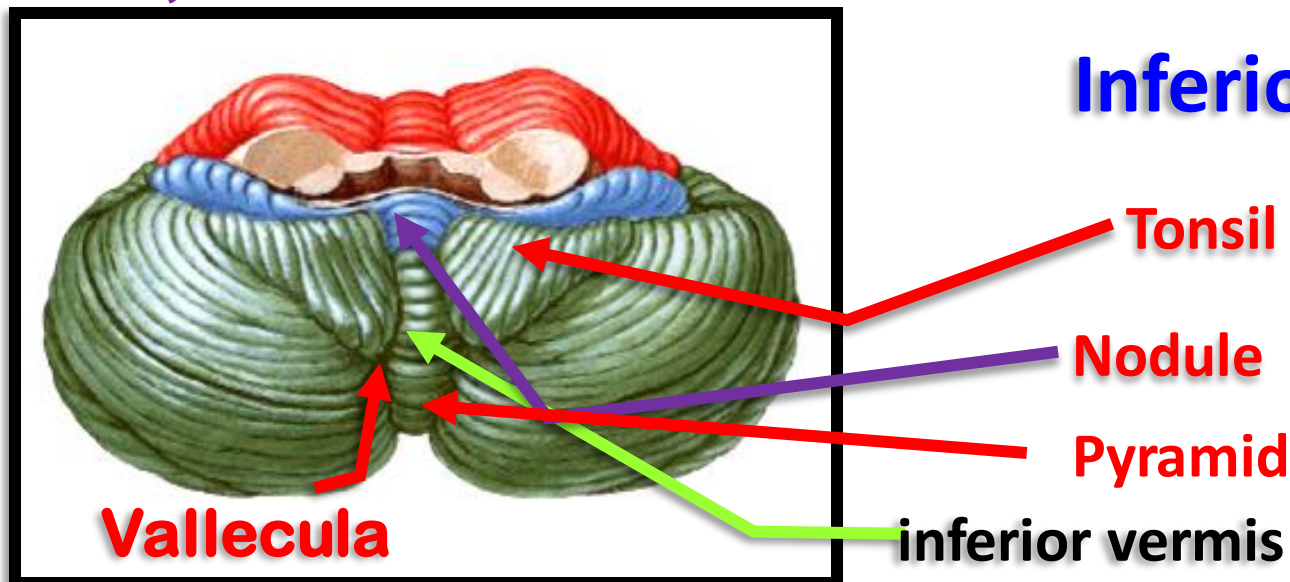
• EXTERNAL FEATURES

Tuesday 20 December 2022

Dr. Aiman Al Maathidy

B- Inferior surface,

- The inferior part of the vermis is called **the inferior vermis** and lies in the bottom of a depression between the two hemispheres called **Vallecula**.
- The inferior vermis consists of **nodule**, **uvula** and **pyramid**.
- The inferior surface of each hemisphere is nearly convex and rests on the floor of the posterior cranial fossa.
- **Tonsil** is a small part of the cerebellar hemisphere that lies lateral to the inferior vermis.



• EXTERNAL FEATURES

2- It has 2 notches (anterior and posterior)


A- Anterior notch;

- It is a large median depression, separated from the back of the pons and open medulla by **the 4th ventricle**.

- It contains **3 cerebellar peduncles** that connecting the cerebellum with the brain stem.

B- **Posterior notch** is a smaller median depression contains **falx cerebelli**.

Wide Anterior
cerebellar
notch



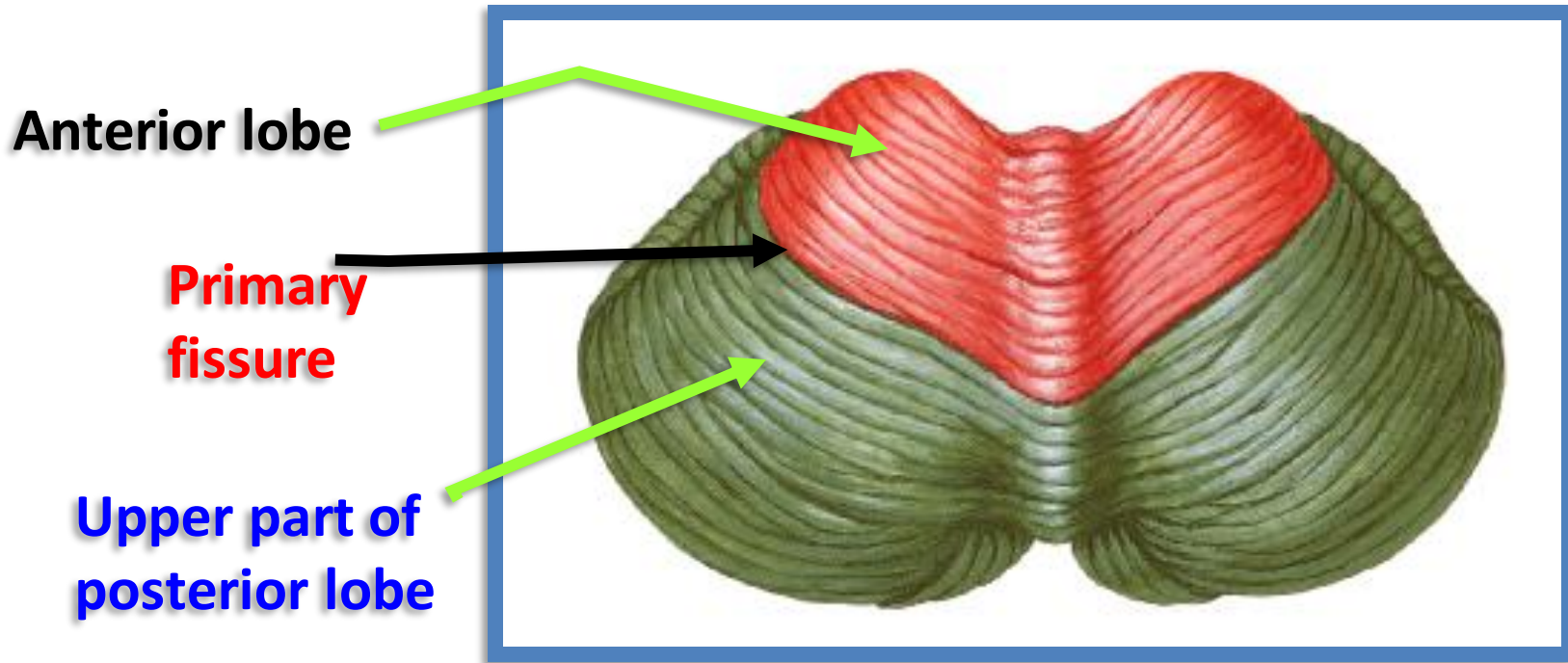
Narrow
Posterior
cerebellar
notch

• EXTERNAL FEATURES

3- Fissures;

a- **Primary fissure**, is a V-shaped fissure on the superior surface.

- It separates the anterior lobe from the posterior lobe.

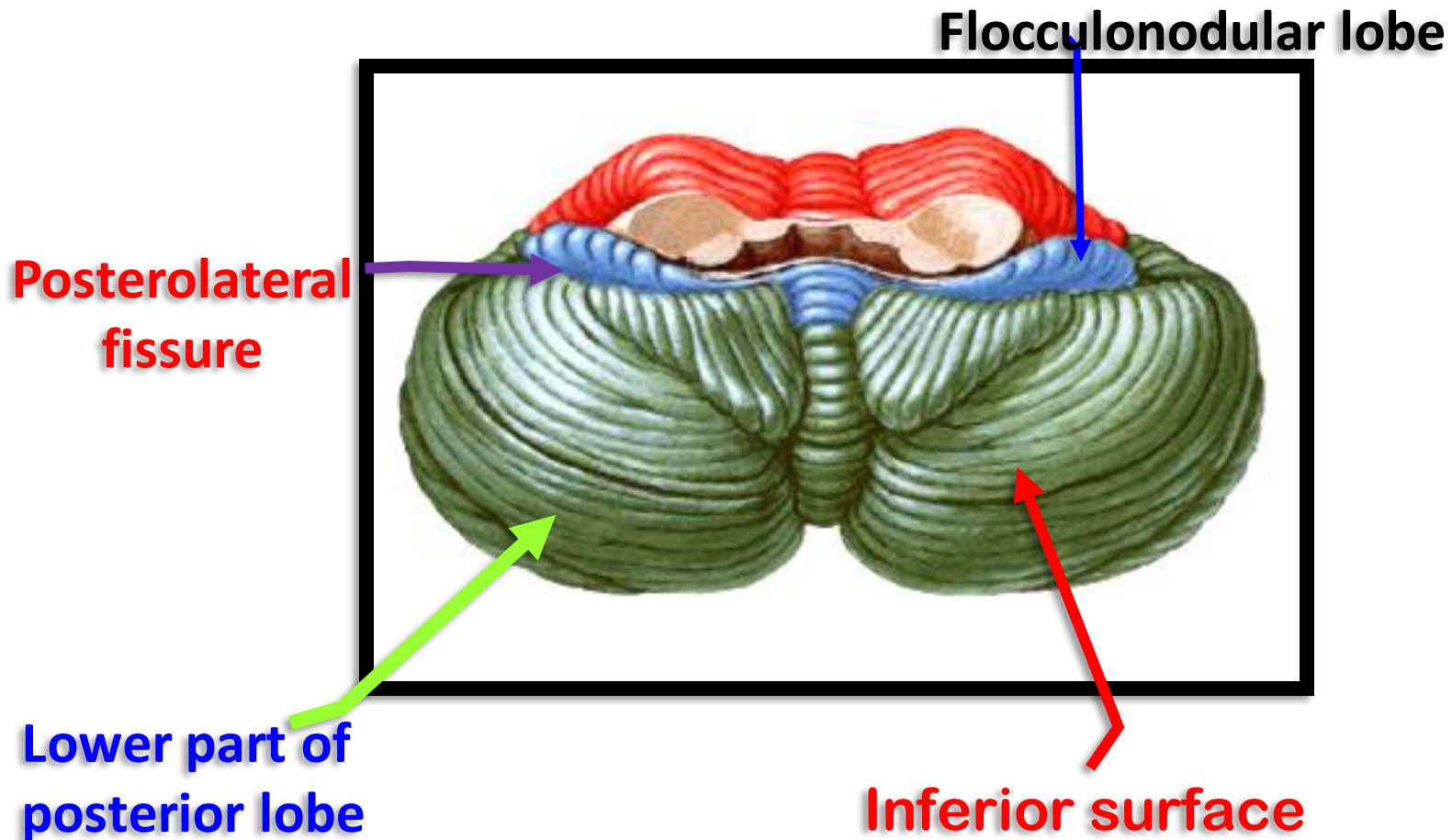


It is a wide V-shaped fissure which separates the anterior lobe from the posterior lobe behind it

• EXTERNAL FEATURES

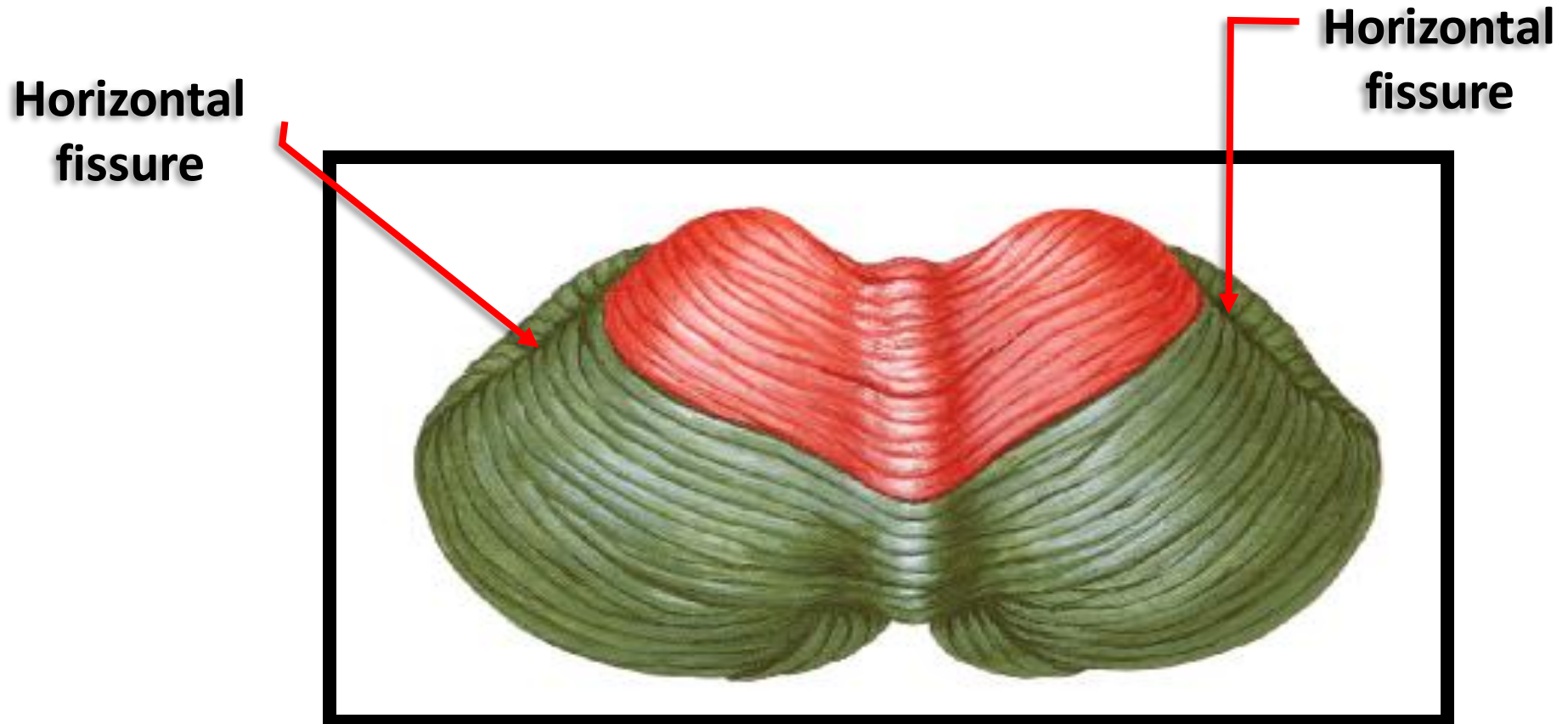
b- Secondary (postero-lateral) fissure on the inferior surface.

• It separates the **folliculo-nodular lobe** (in front) from the **posterior lobe** of the cerebellum



• EXTERNAL FEATURES

c- Horizontal fissure extends from the anterior notch to the posterior notch around the side of the cerebellum between **the inferior and superior surfaces**.




• EXTERNAL FEATURES

d- Great number of transverse fissures on the **inferior and superior surfaces**.

- The part of the cerebellum between the transverse fissures **called folia**.

- They increase the surface area of the cerebellar cortex in a limited space

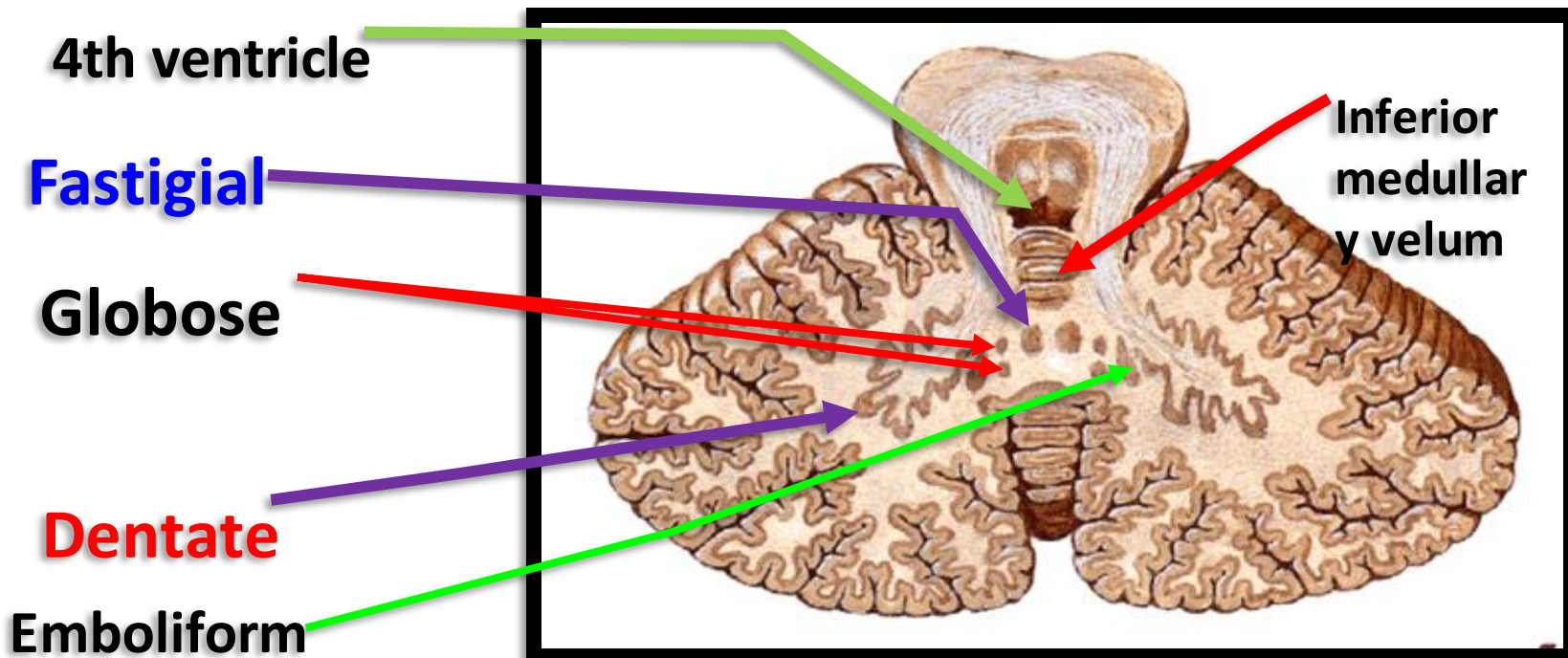
Separated by
Transverse
Fissures



Folia

• Internal Structures

- 2) **Emboliform nucleus:** It lies medial to the dentate nucleus.
- It belongs to the paleo-cerebellum.
- 3) **Globosus nucleus;** It lies medial to the emboliform nucleus.
- It belongs to the paleo-cerebellum.
- 4) **Fastigial nucleus:** It is the most medial nucleus.
- It belongs to the archi-cerebellum.



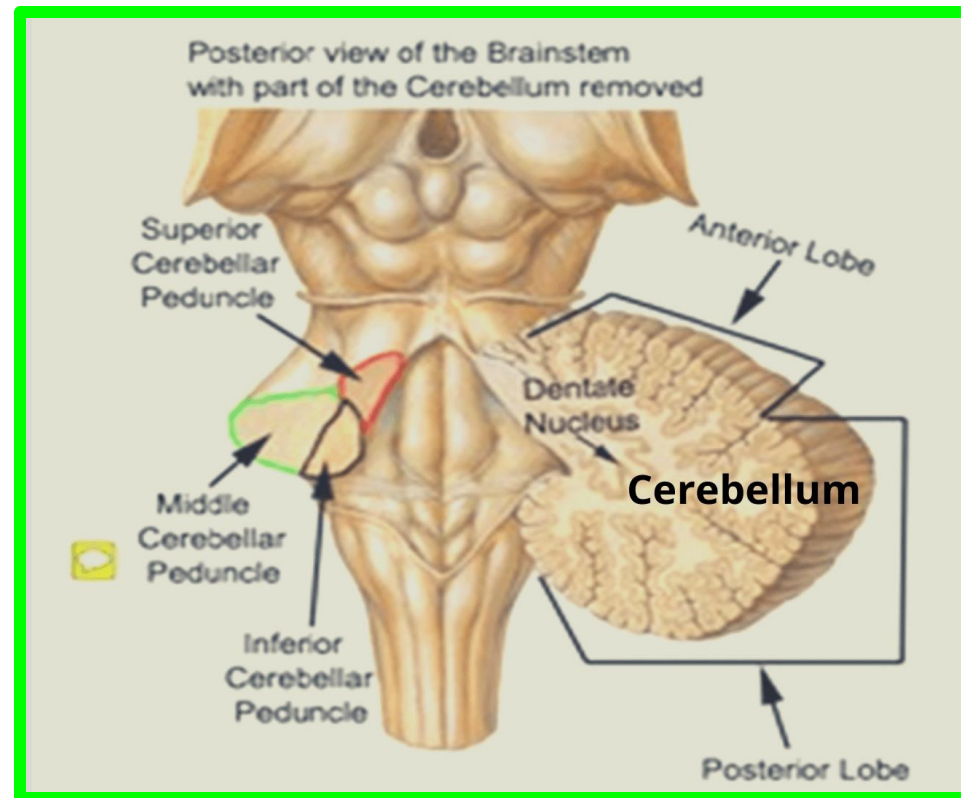
Cerebellar peduncles

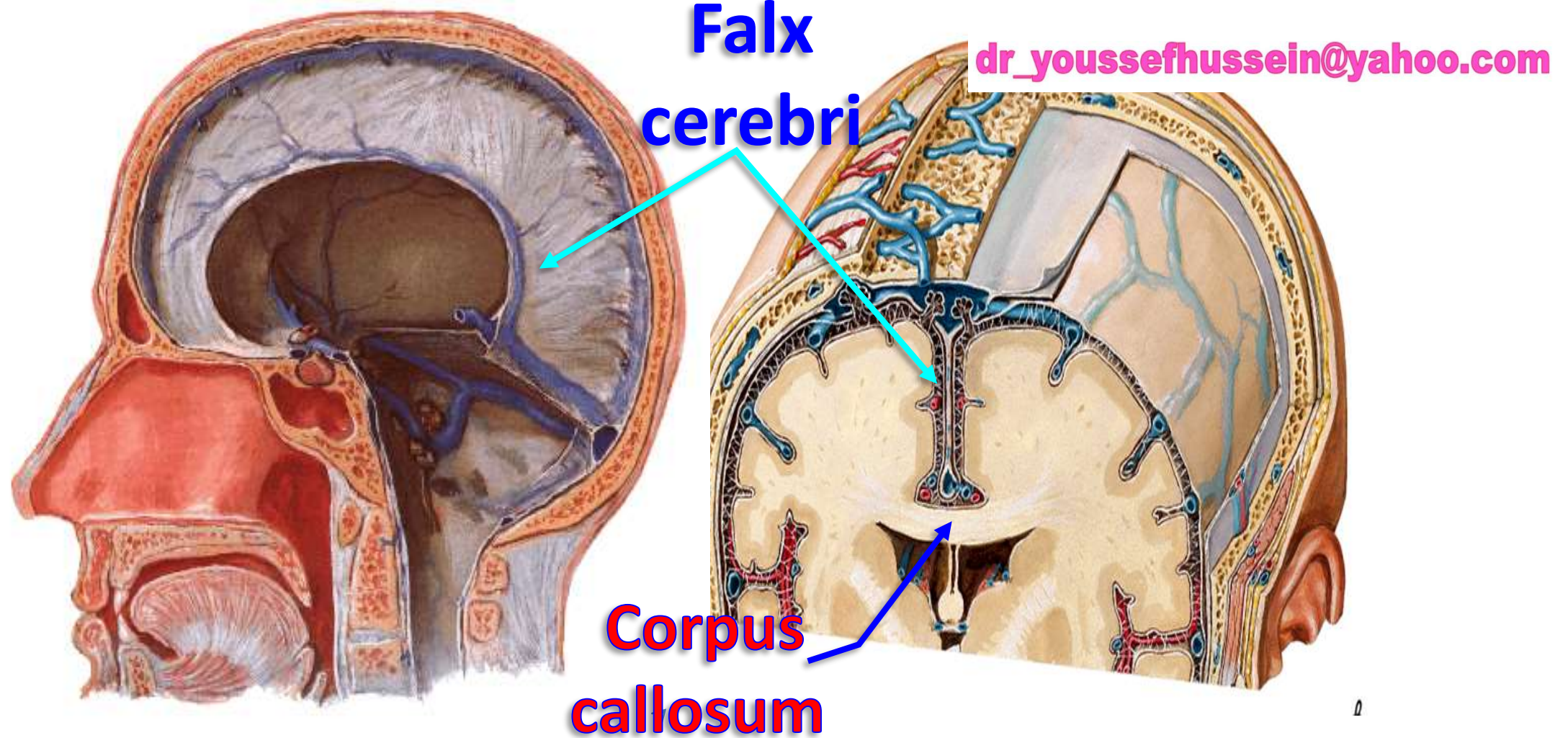
2- Middle cerebellar peduncle:

- It is the thickest of the three cerebellar peduncles.
- It emerges from the lateral aspect of **the pons**.

3- Superior cerebellar peduncle

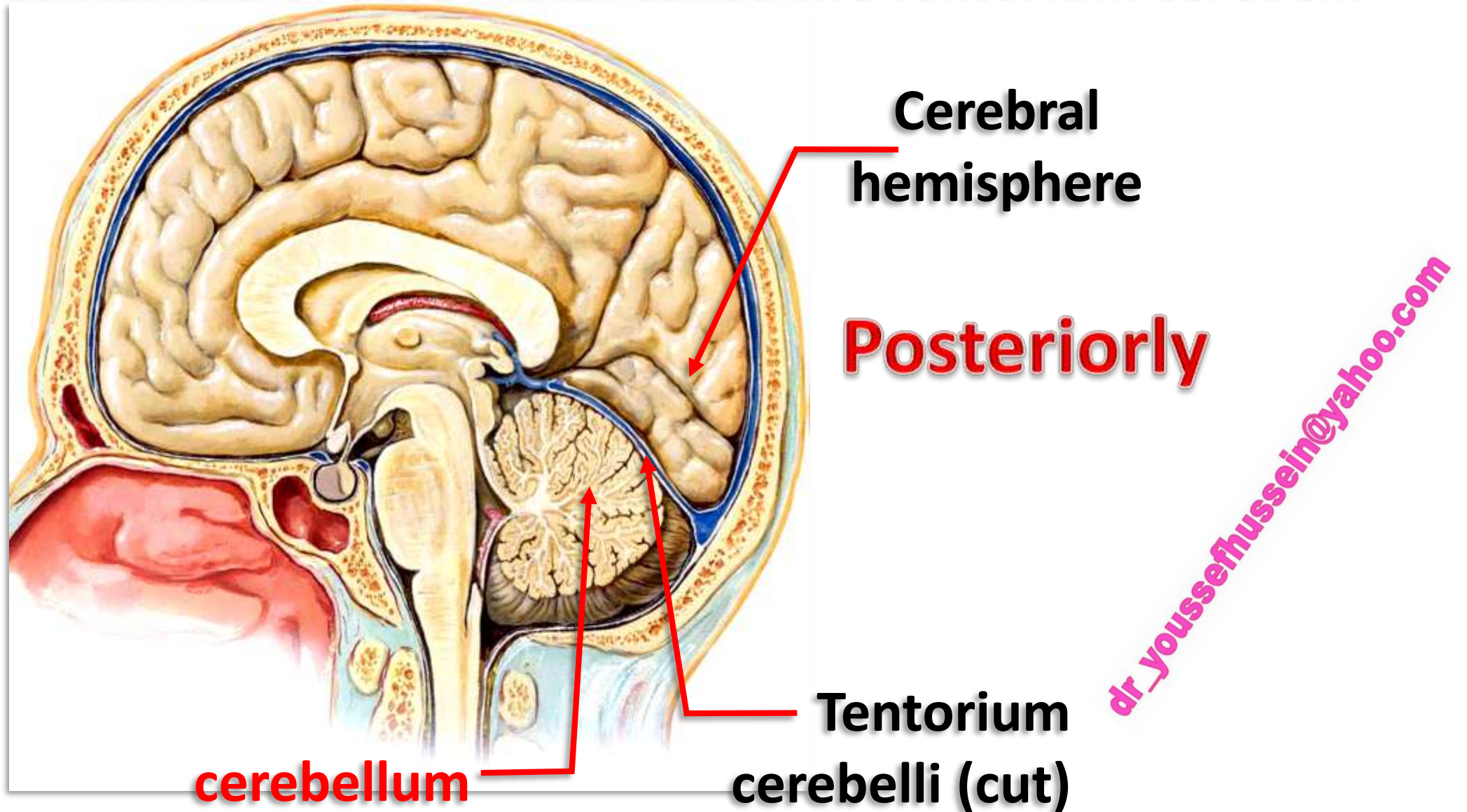
- It emerges from the back of **the midbrain**.
- It runs downward and laterally on the side of the upper part of the 4th ventricle to enter the cerebellar hemisphere.



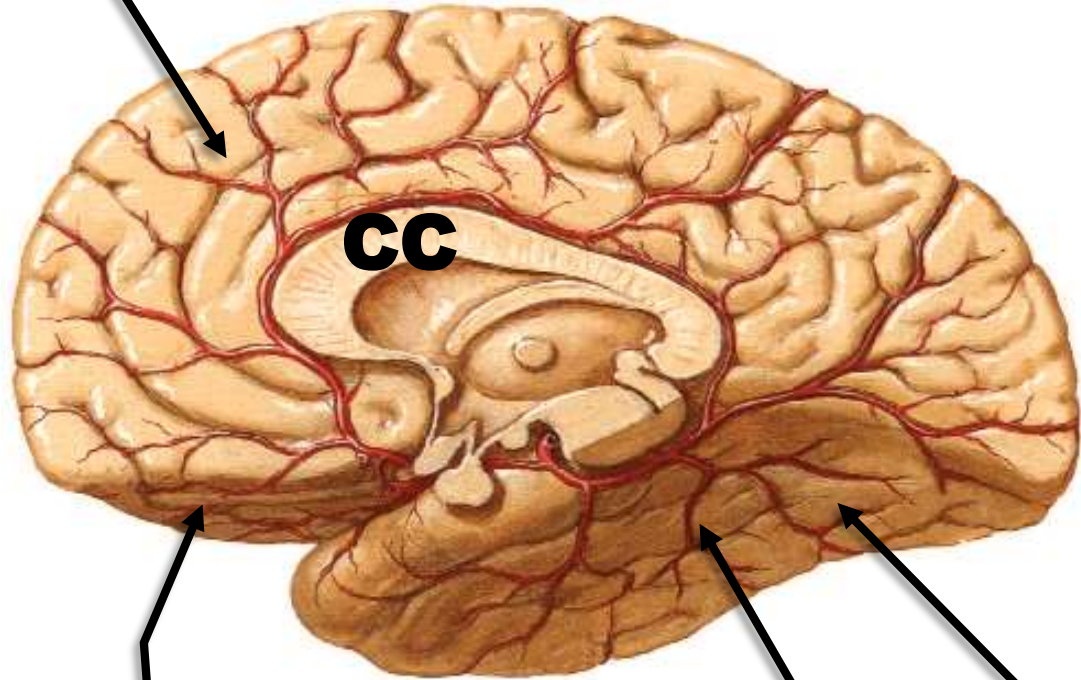


- The longitudinal fissure contains the sickle-shaped fold of dura matter, the falx cerebri
- Two hemispheres connected together by CC

The cerebral hemispheres are separated from the cerebellum by a horizontal fold of dura mater called the tentorium cerebelli



2- Medial Surface

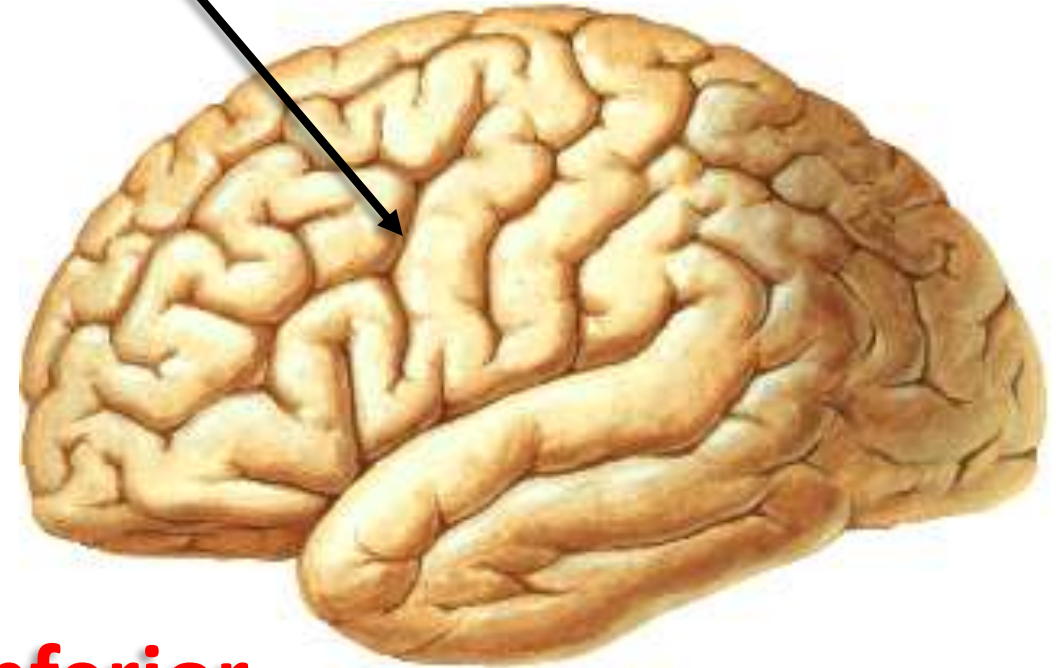


3A- Orbital part

3B- Tentorial part

3- Inferior Surface

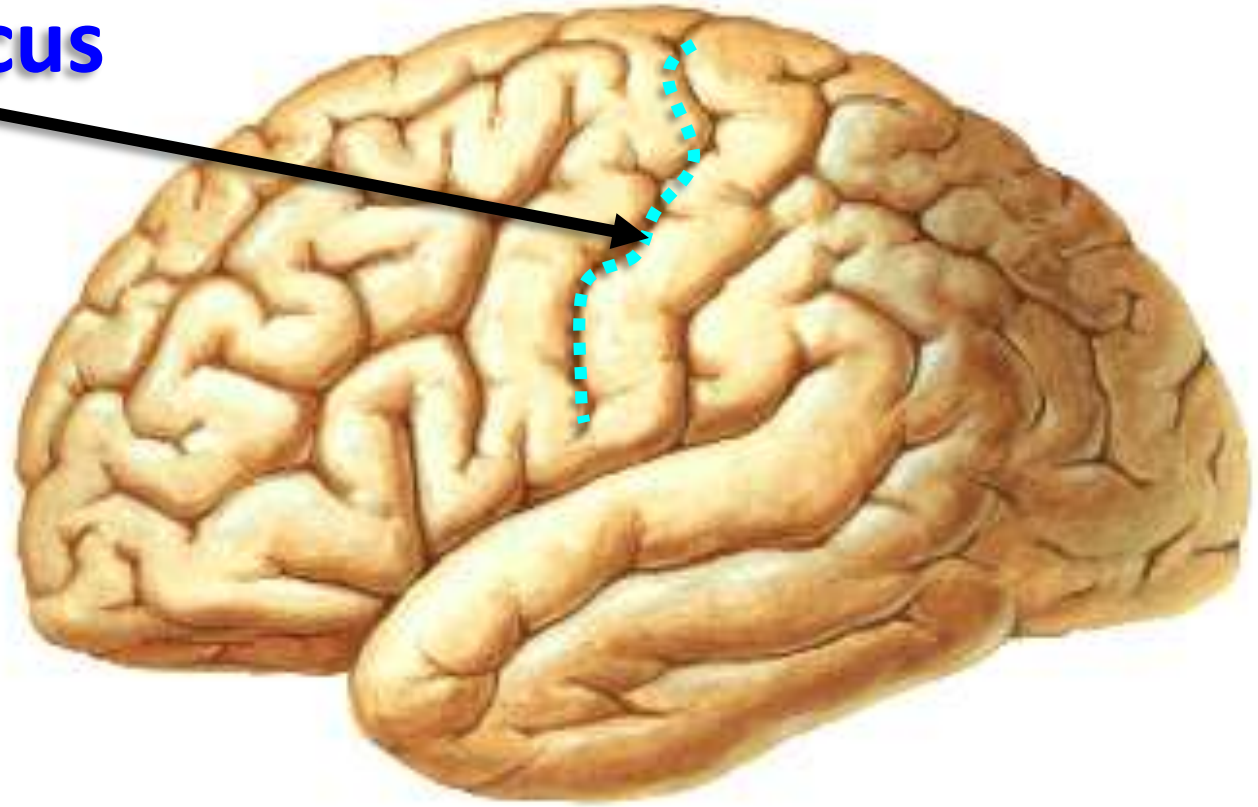
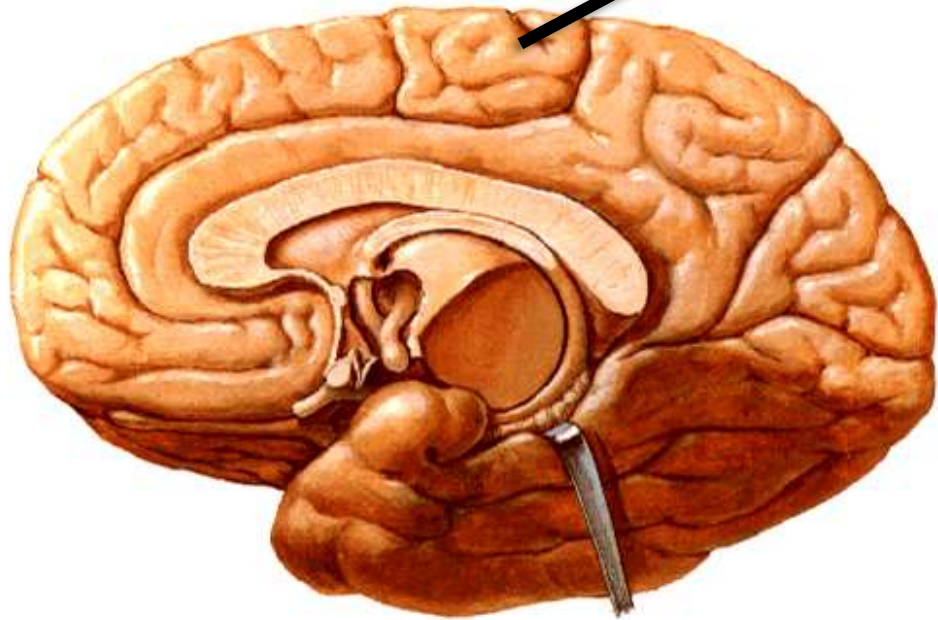
1- Superolateral Surface



dr_youssefhussein@yahoo.com

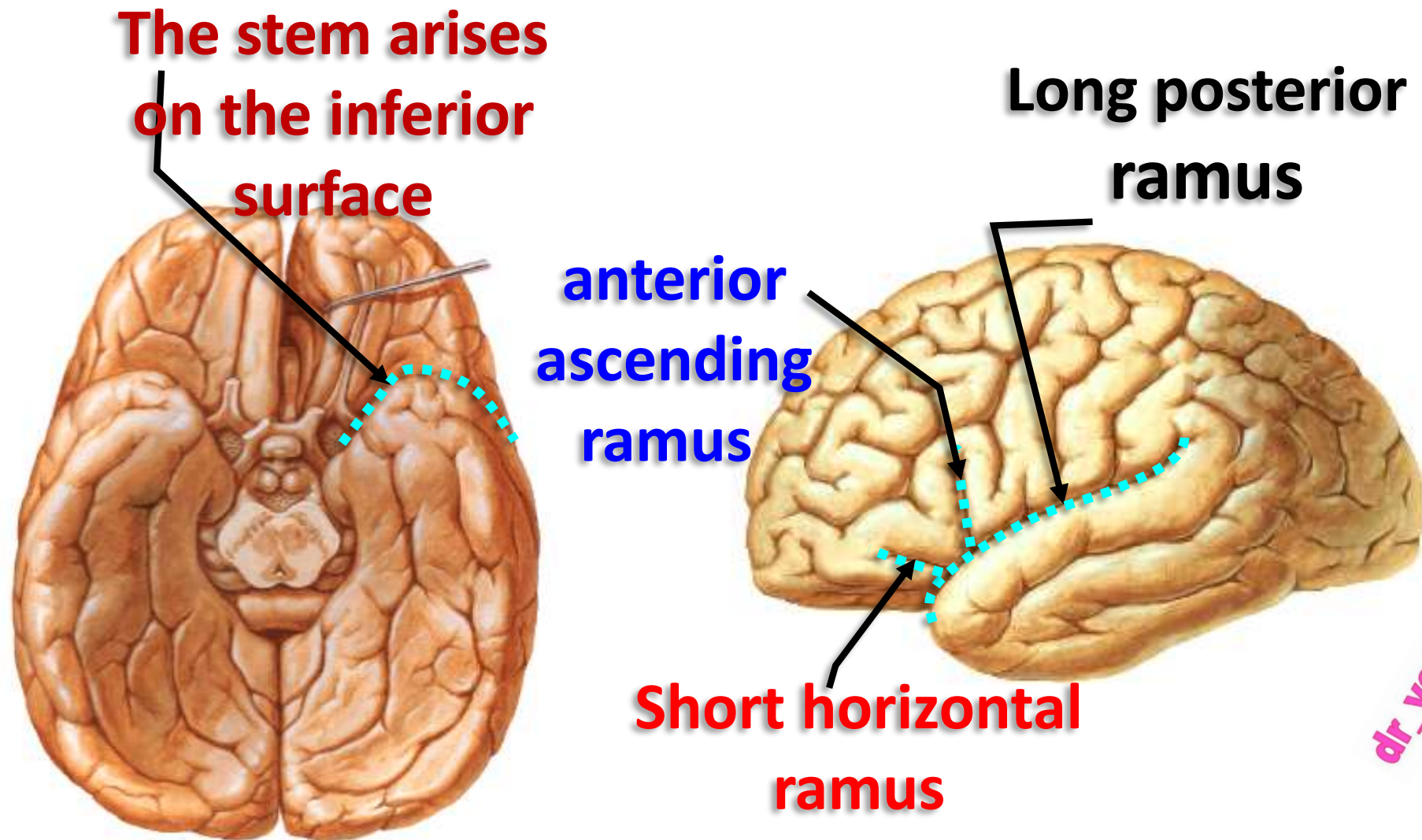
Each cerebral hemisphere has 3 surfaces

Central sulcus

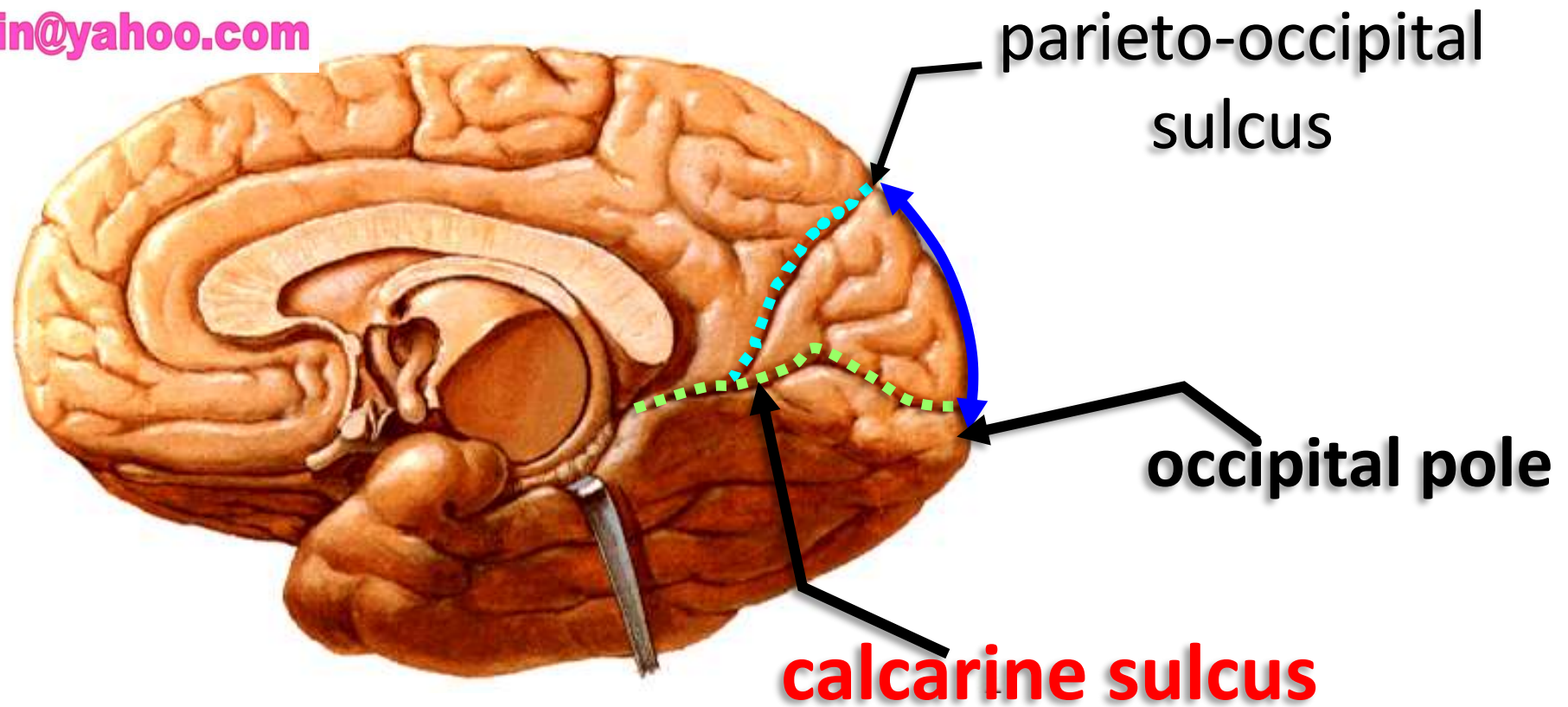


1- Central sulcus (Fissure of Rolando) a deep sulcus about 1/2 inch behind the midpoint between frontal and occipital poles.

- It extends obliquely downwards and forwards and ends slightly above the lateral sulcus.
- It extends a little on the medial surface



2- Lateral sulcus (fissure of Sylvius) consists of a short stem (inferior surface) that divides into three rami (superolateral surface).

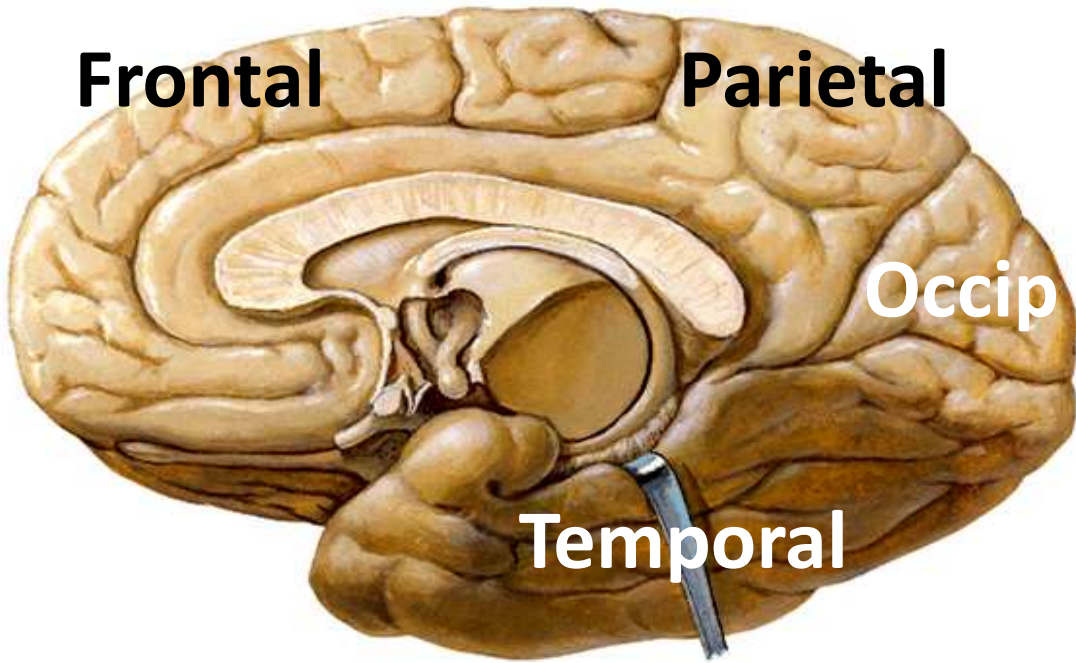


3- Parieto-occipital sulcus begins on the superior medial margin of the hemisphere about 2 inches (5 cm) anterior to the occipital pole, extends downward & forward

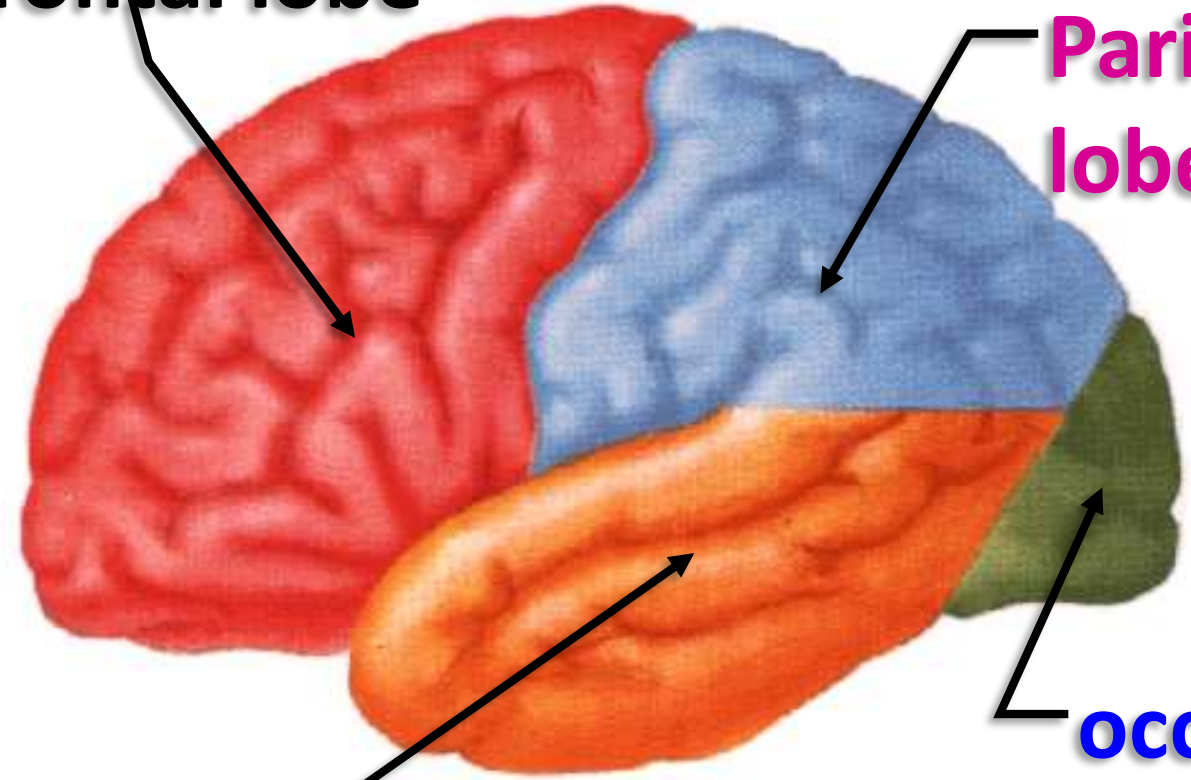
4- Calcarine sulcus; begins below the splenium of the corpus callosum to the occipital pole.

- It is divided by parieto-occipital sulcus into precalcarine and postcalcarine sulcus.

Infero-Medial



frontal lobe

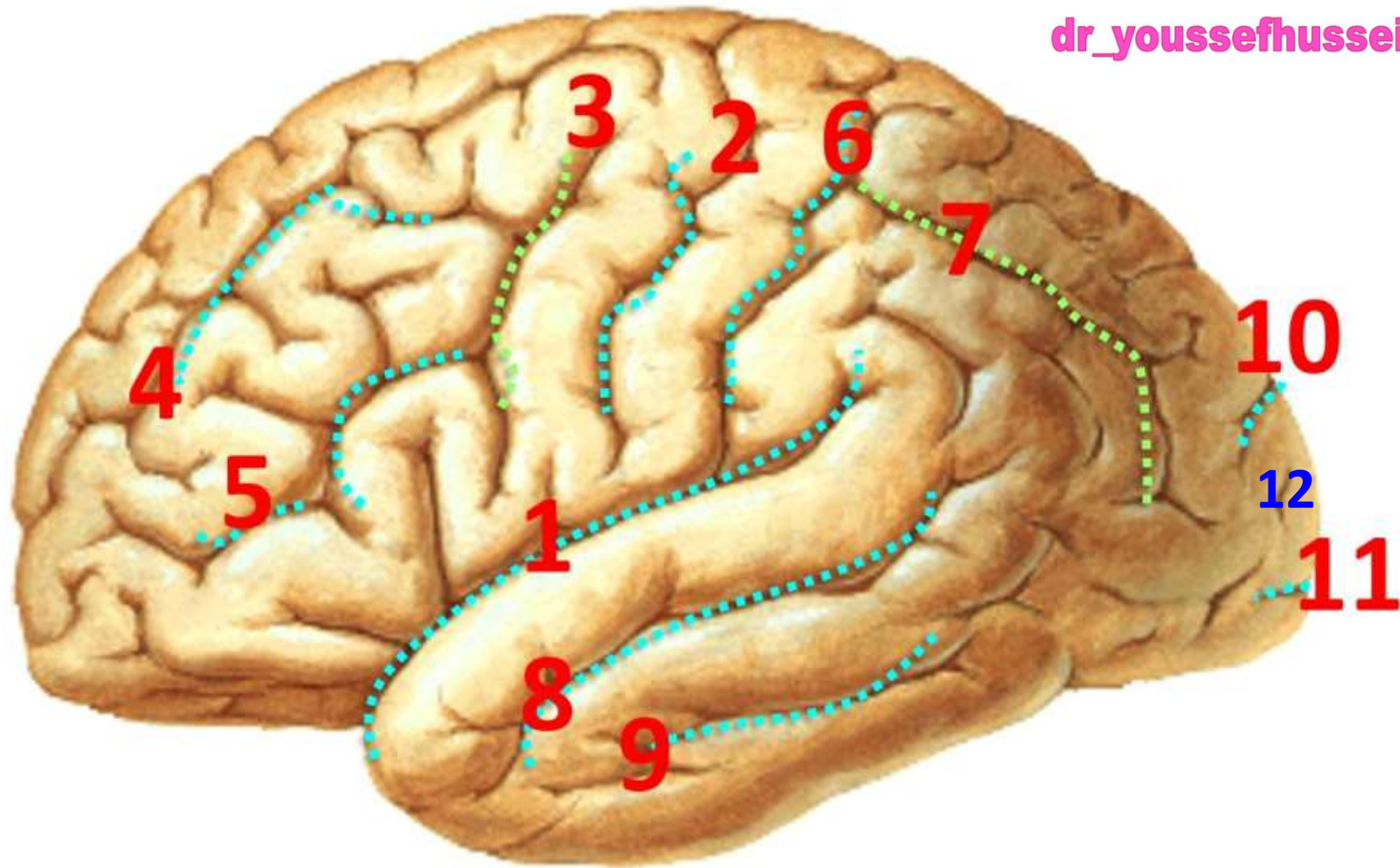


temporal lobe

occipital lobe

Superolateral

Each cerebral hemisphere has 4 lobes



Important Sulci on the supero-lateral surface

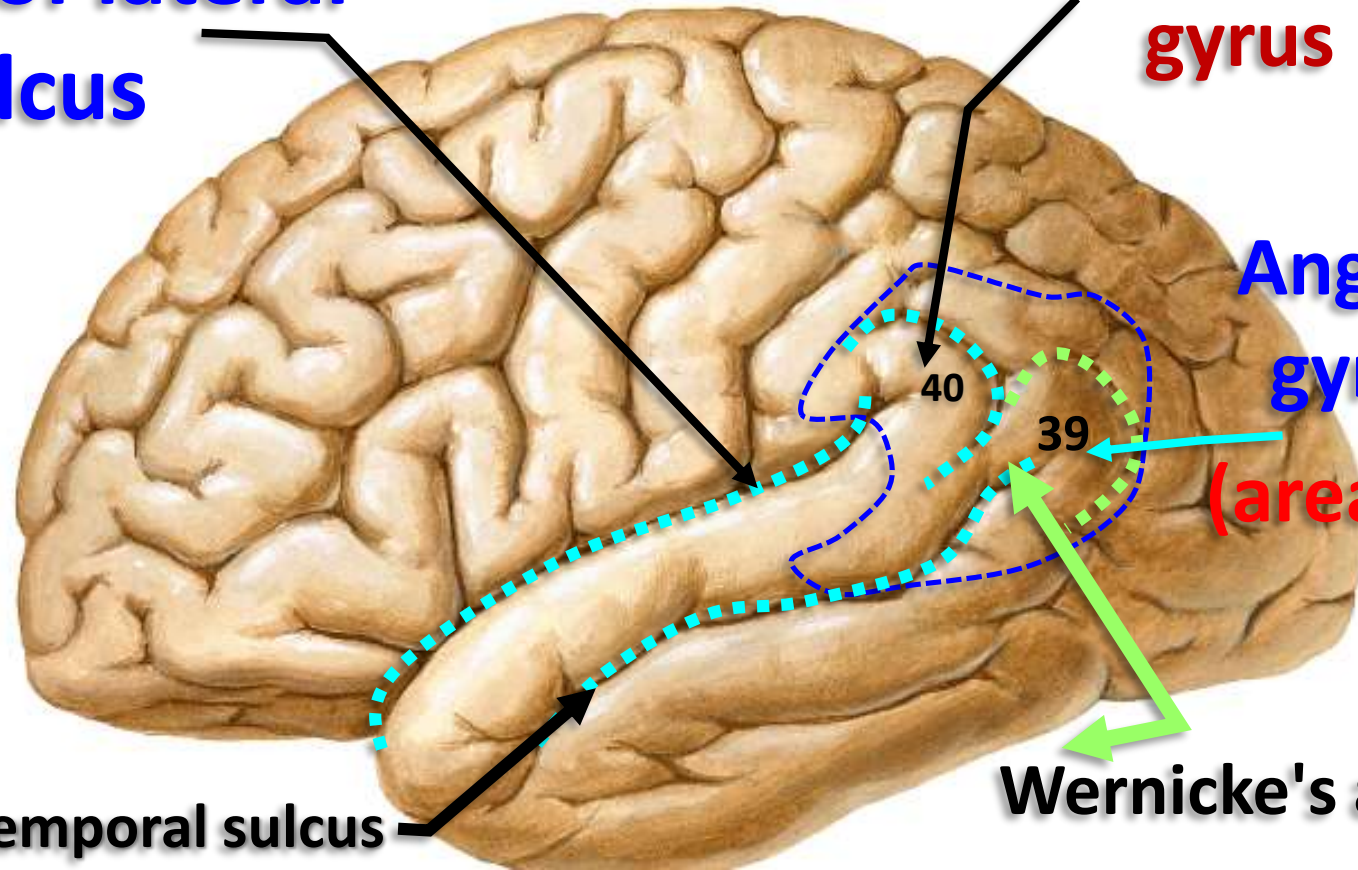
• Sulci on the Supero-lateral surface

- 1- **Lateral sulcus** (fissure of Sylvius):
- 2- **Central sulcus** (Fissure of Rolando):
- 3- **Precentral sulcus**: about 1 cm (finger's breadth) in front of central sulcus.
- 4 & 5- **Superior and inferior frontal sulci**: begin close to the precentral sulcus and extend forwards.
- 6- **Postcentral sulcus**: about 1 cm (finger's breadth) behind central sulcus.
- 7- **Intraparietal sulcus**: extends backwards from the middle of the postcentral sulcus.
- 8 & 9- **Superior and inferior temporal sulci**: on the temporal lobe parallel to the lateral sulcus.
- 10- **Parieto-occipital sulcus**: 5 cm in front of the occipital pole.
- 11- **Calcarine sulcus**: its posterior end reaches to the occipital pole.
- 12- **Lunate sulcus (Simian)** at the occipital lobe

dr_youssefhussein@yahoo.com

Long posterior
ramus of lateral
sulcus

(area 40) Supramarginal
gyrus

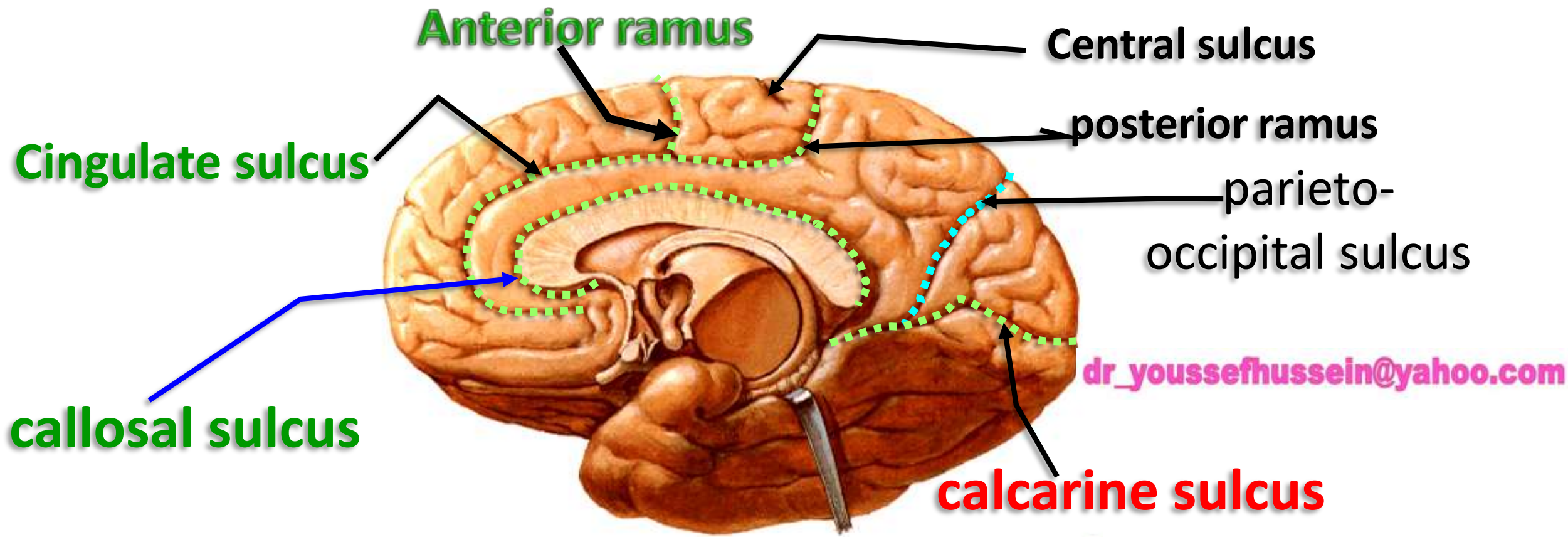


Angular
gyrus
(area 39)

Wernicke's area

Superior temporal sulcus

- **Supramarginal gyrus (area 40)** is gyrus around the posterior end of the lateral sulcus into the parietal region
- **Angular gyrus (area 39):** is gyrus around the posterior end of the superior temporal sulcus into the parietal region



- **Sulci on the Medial Surface**

1- Callosal sulcus: close to the upper surface of the corpus callosum.

2- Cingulate sulcus; about finger's breadth above and parallel to the callosal sulcus.

- It **ends** by dividing into two rami in front and behind the central sulcus.

3- Central sulcus: between the two branches of the cingulate sulcus.

4- Parieto-occipital sulcus.

5- Calcarine sulcus.

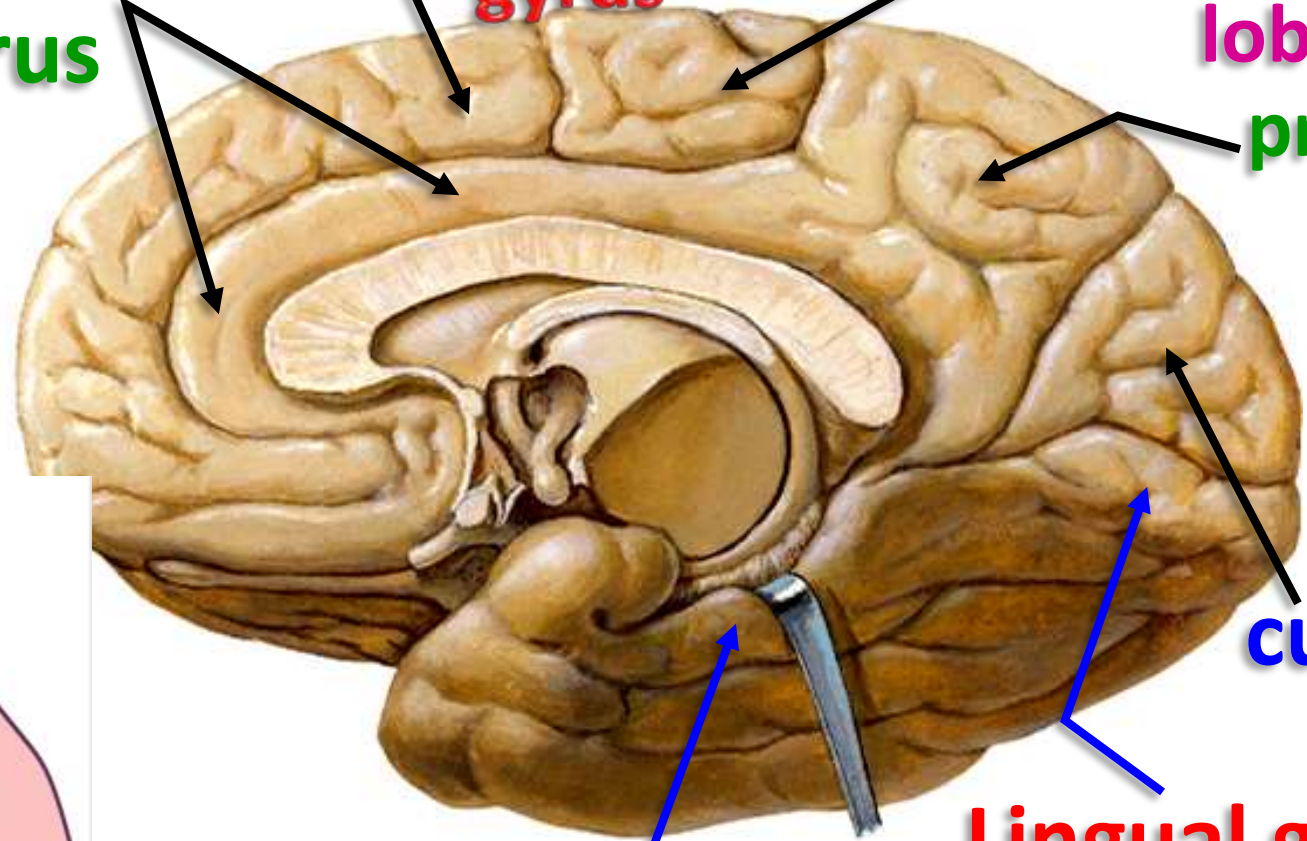
dr_youssefhussein@yahoo.com

cingulate gyrus

medial frontal gyrus

paracentral lobule

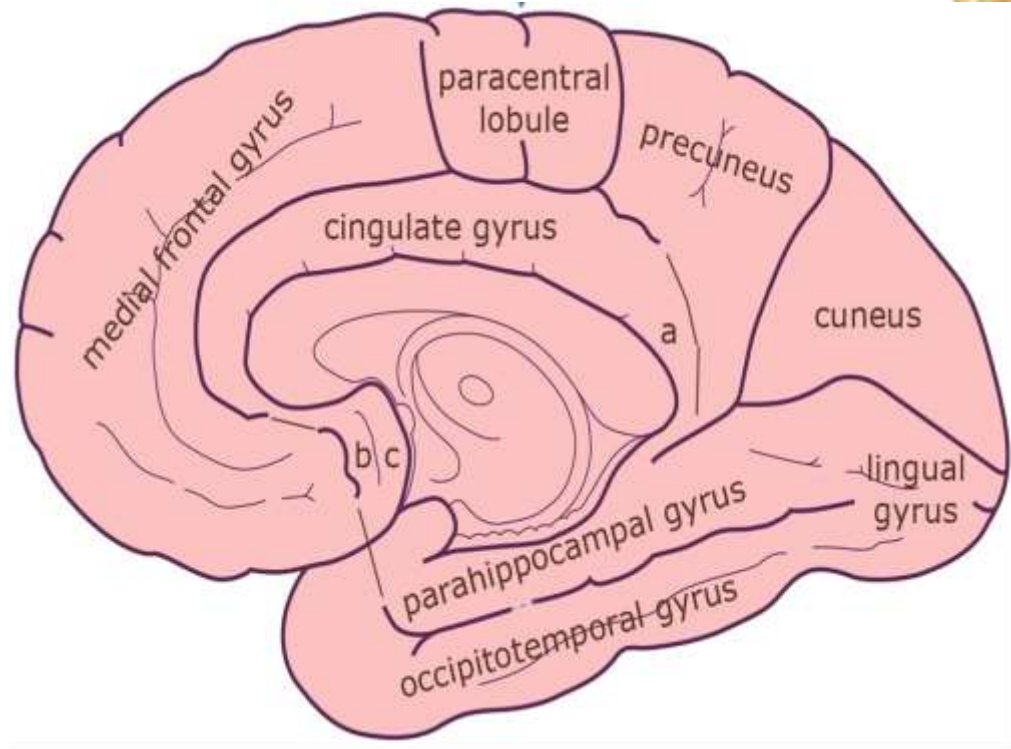
precuneus



cuneus

Lingual gyrus

Parahippocampus



1- Paracentral lobule;

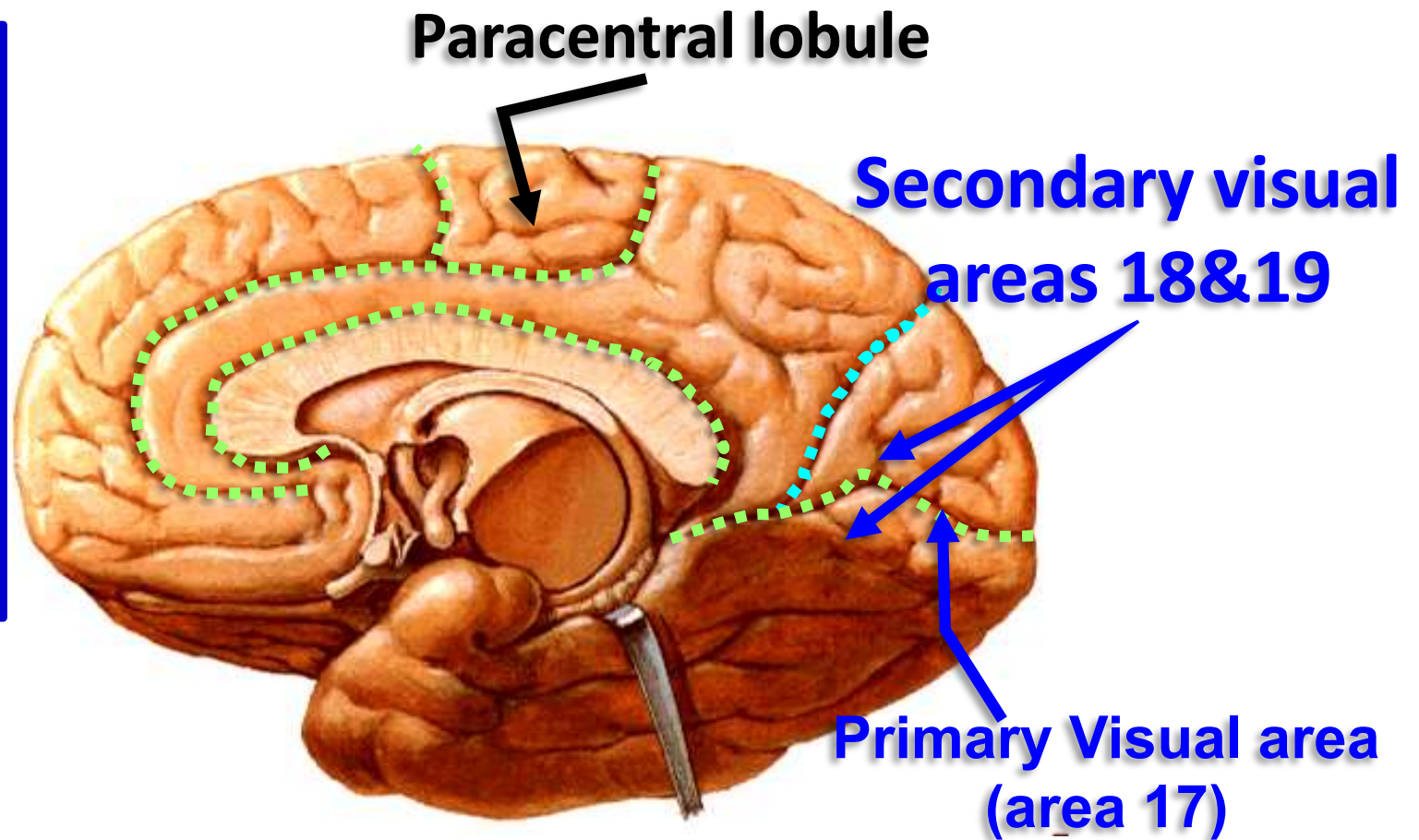
- It continues with the motor and sensory areas in the lateral surface.
- It gives motor fibres and receives sensation from the leg, foot and perineum of the opposite side.
- It controls the micturition and defecation.

2- primary Visual area (area 17);

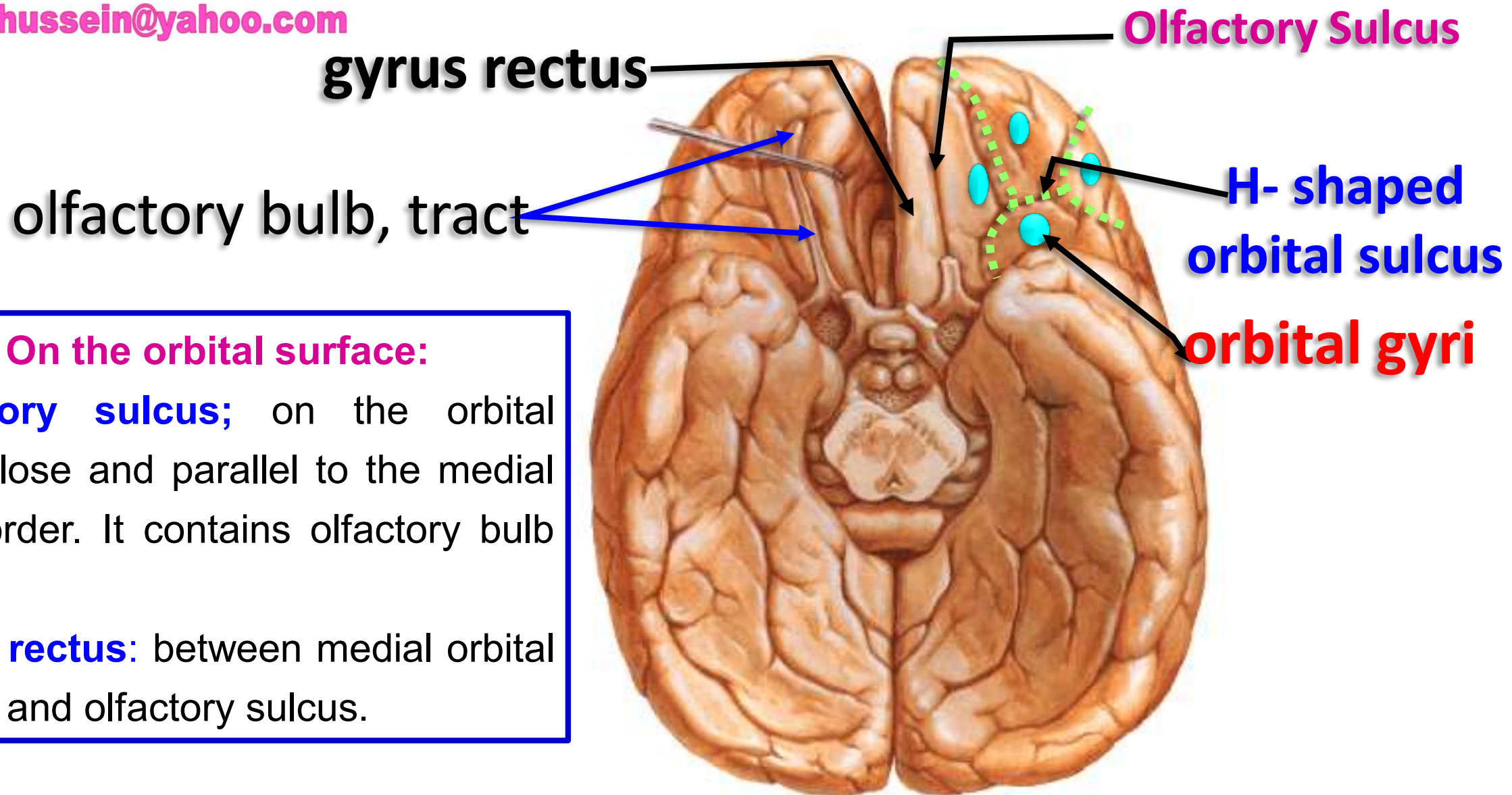
- It lies on the depth of calcarine sulcus
- It receives visual sensation from the lateral geniculate body (**LGB**) via the optic radiation..
- Damage of the primary visual area causes **blindness**.

3- secondary Visual (association) area (area 18, 19):

- It lies in the occipital lobe surrounding the primary visual area.
- Damage of this area causes **visual agnosia** (people can not identify the objects).



dr_youssefhussein@yahoo.com



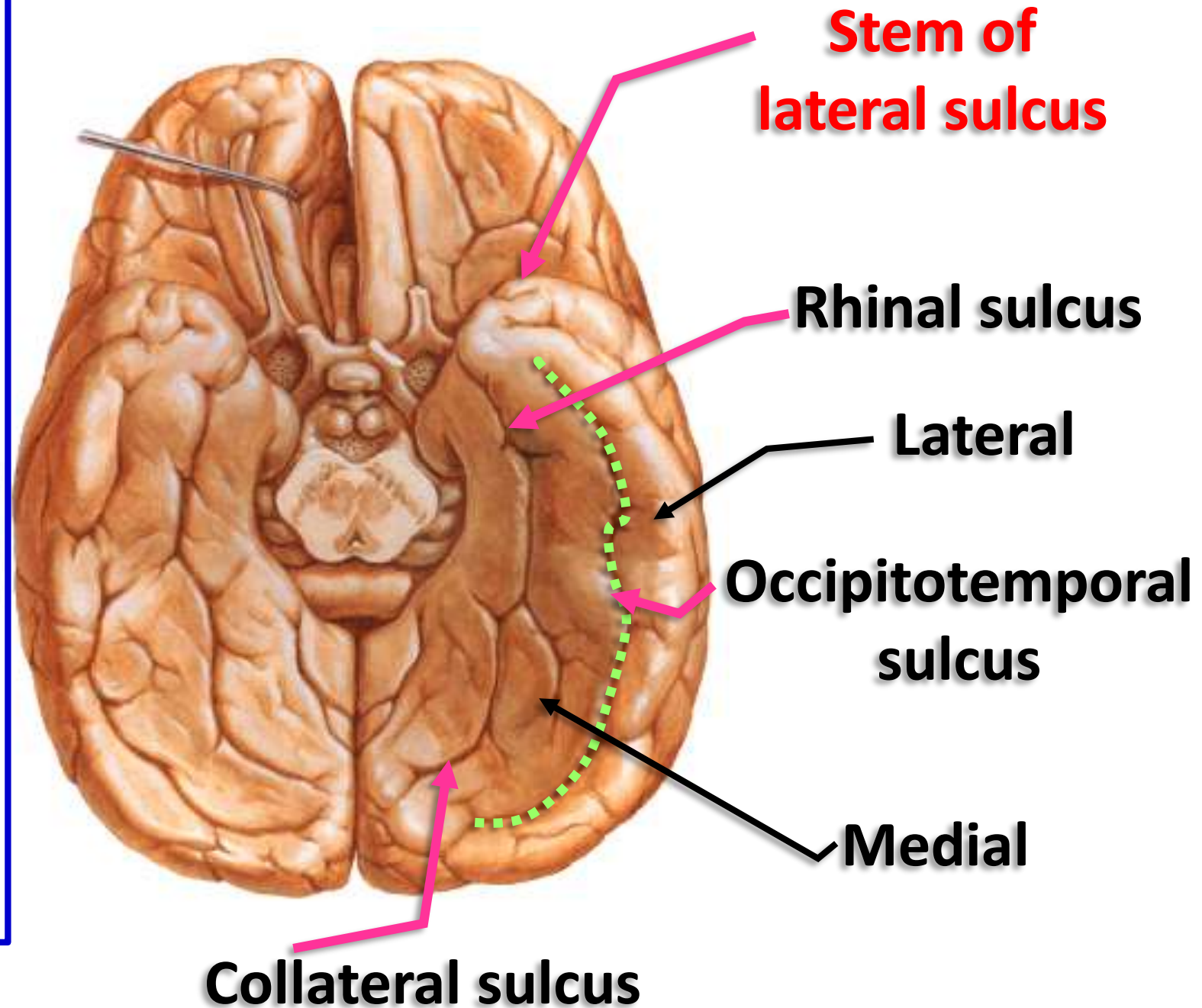
- **On the orbital surface:**

- **Olfactory sulcus;** on the orbital surface close and parallel to the medial orbital border. It contains olfactory bulb and tract.
- **Gyrus rectus:** between medial orbital border and olfactory sulcus.

- **Orbital sulcus:** is H shaped sulcus lateral to the olfactory sulcus.
- **Anterior, posterior, lateral and medial orbital gyri:** on the orbital surface.

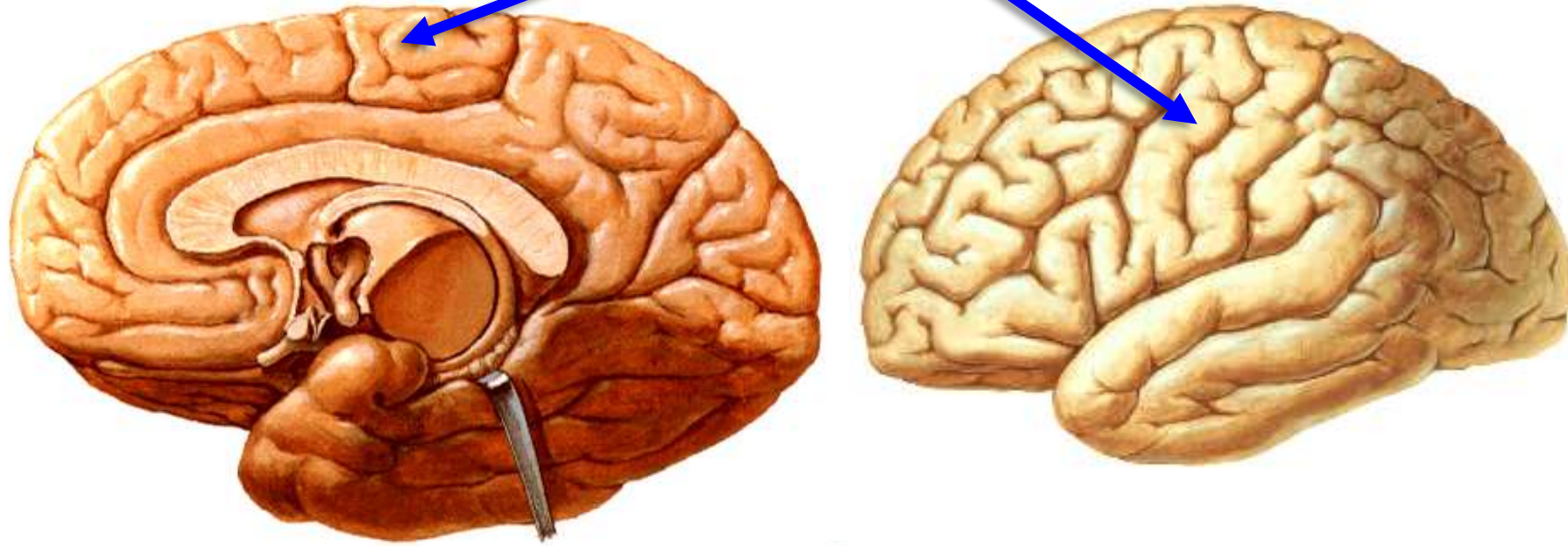
- On the tentorial surface:

- 1- Stem of lateral sulcus** between the frontal and temporal lobes.
- 2- Occipito-temporal sulcus:** from occipital pole to temporal pole.
- 3- Medial and Lateral occipitotemporal gyrus:** medial and lateral to occipitotemporal sulcus.
- 4- Rhinal sulcus:** extends from the temporal pole.
- 5- Collateral sulcus:** begins close to the posterior end of the rhinal sulcus to the occipital pole.



Motor area 4

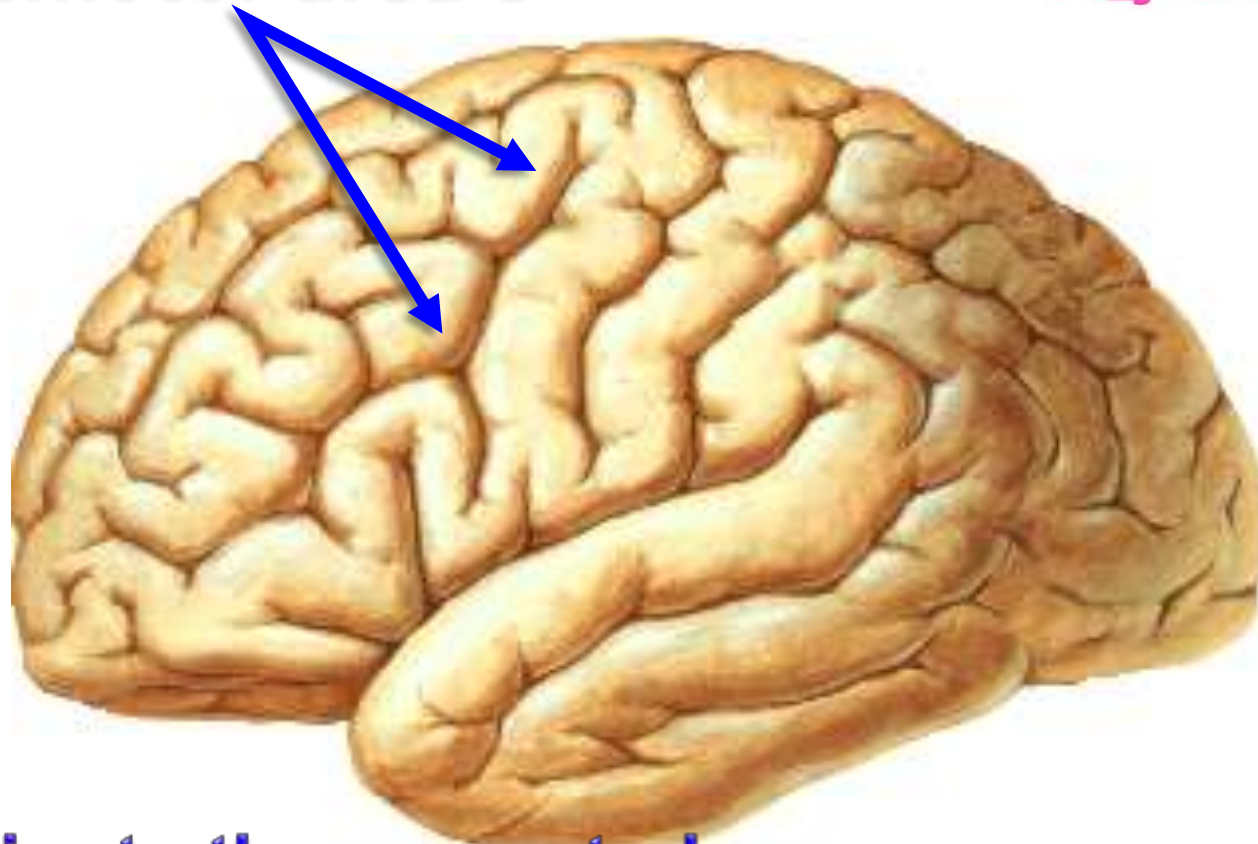
dr_youssefhussein@yahoo.com



- **Primary motor area** corresponds to the precentral gyrus (area 4), anterior part of the paracentral lobule **Controls motor functions**

Premotor area 6

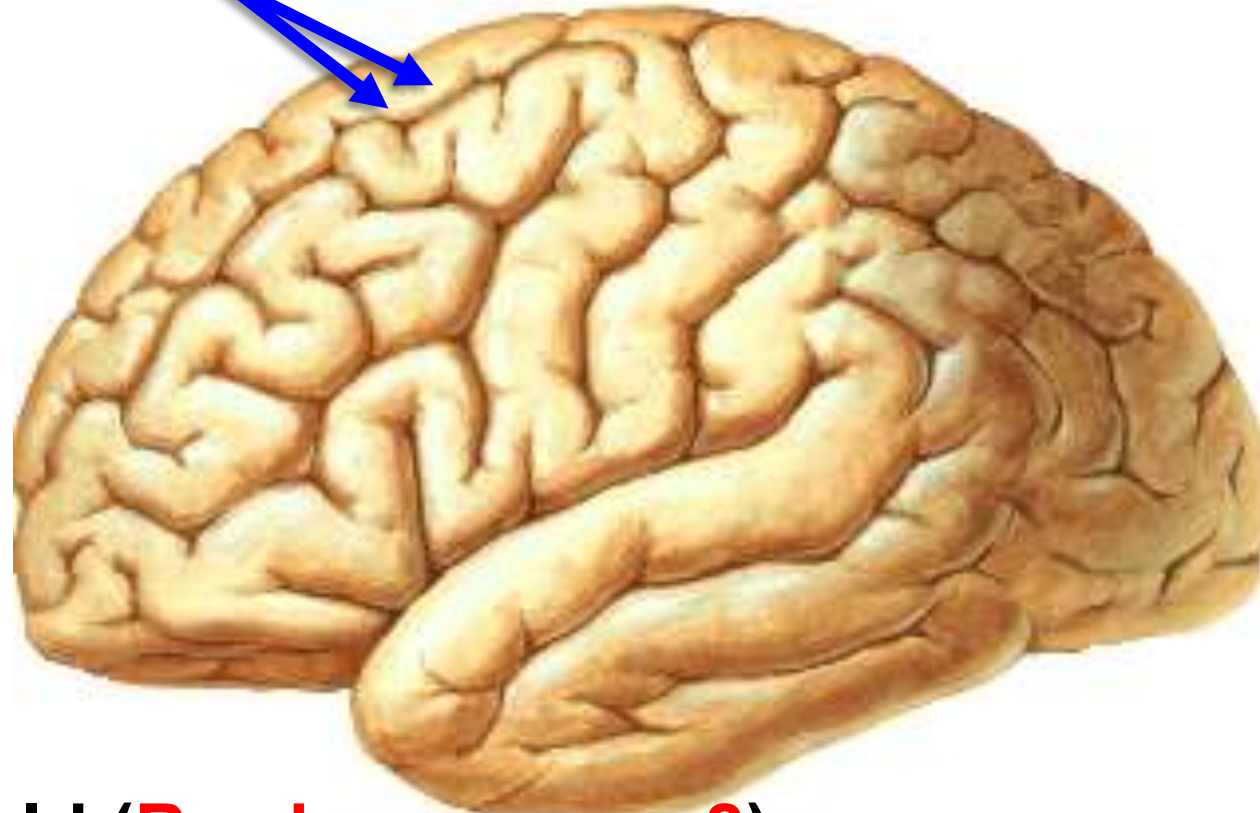
dr_youssefhussein@yahoo.com



- **Located anterior to the precentral gyrus**
- **It is the origin of extrapyramidal fibers**
- **Controls more complex movements**
- **Involved in the *planning* of movements** and storage of the learned movements to bring them later on.

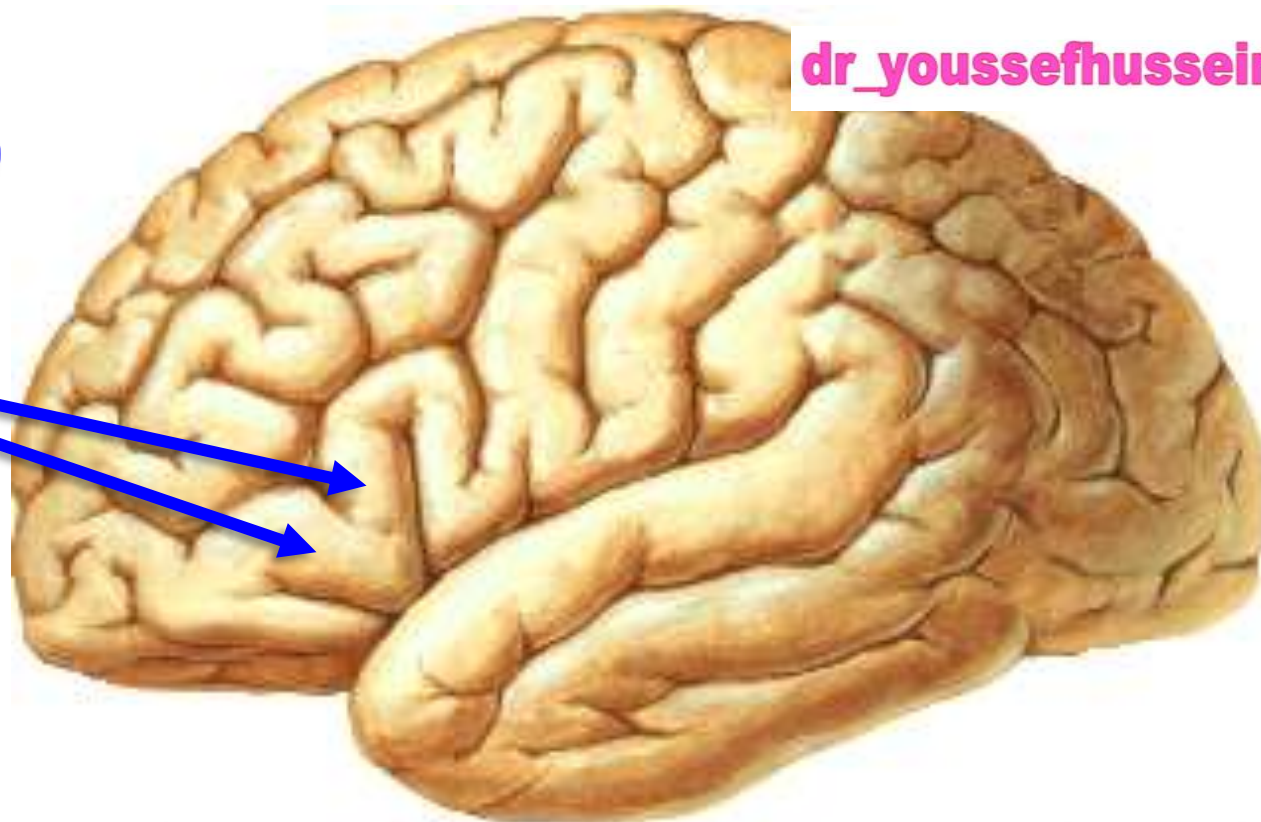
Frontal eye field area 8

dr_youssefhusseini@yahoo.com



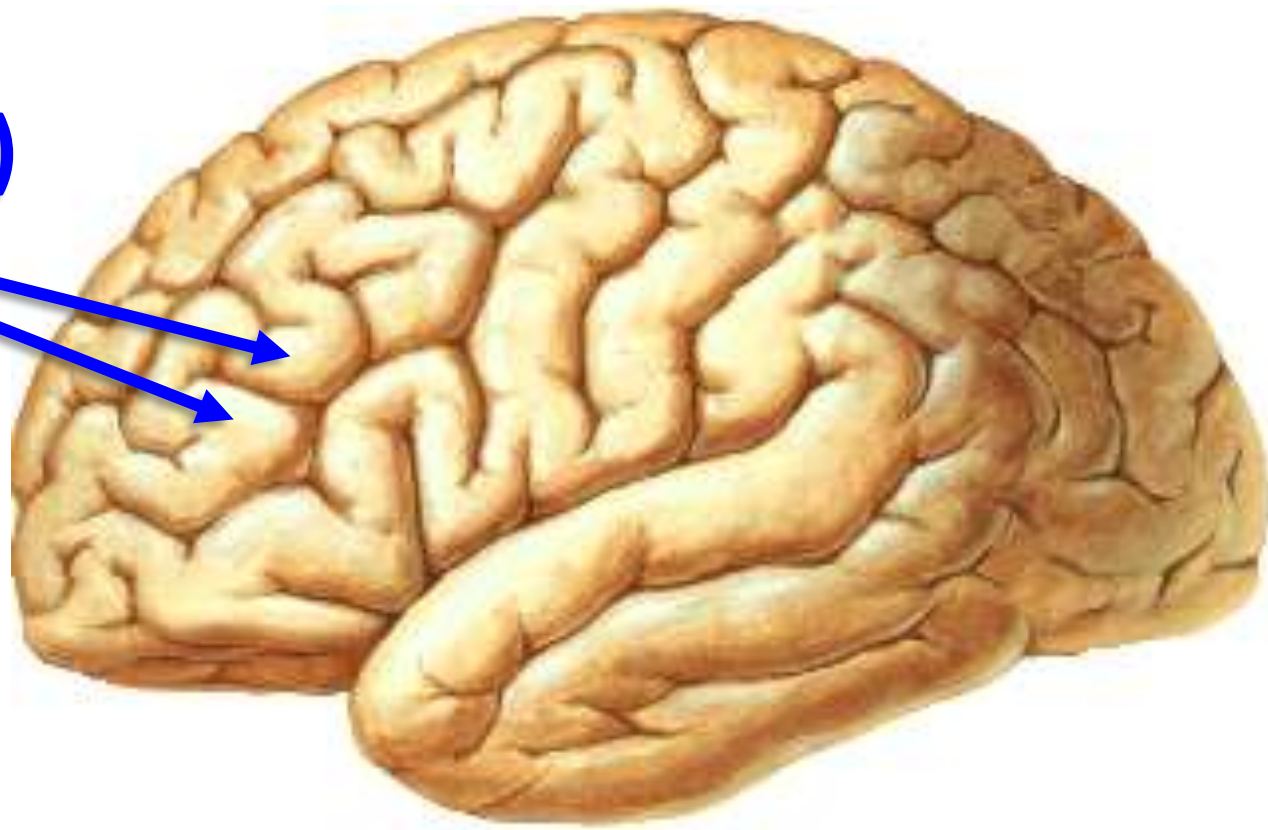
- **Frontal eye field (Brodmann area 8):**
 - It lies anterior to the premotor cortex in the superior frontal gyrus
 - **It controls movements of the eyes when eyes follow a moving target.**

(Broca's area)
44, 45



- **Motor speech (Broca's) area (areas 44, 45)** is located in inferior frontal gyrus between the anterior and ascending rami (triangular area) of the lateral sulcus of the dominant hemisphere (95%).
- It brings about the formation of words by its connections with the adjacent primary motor areas; the muscles of the speech.
- Lesion in this area produces **motor aphasia** (loss of speech).

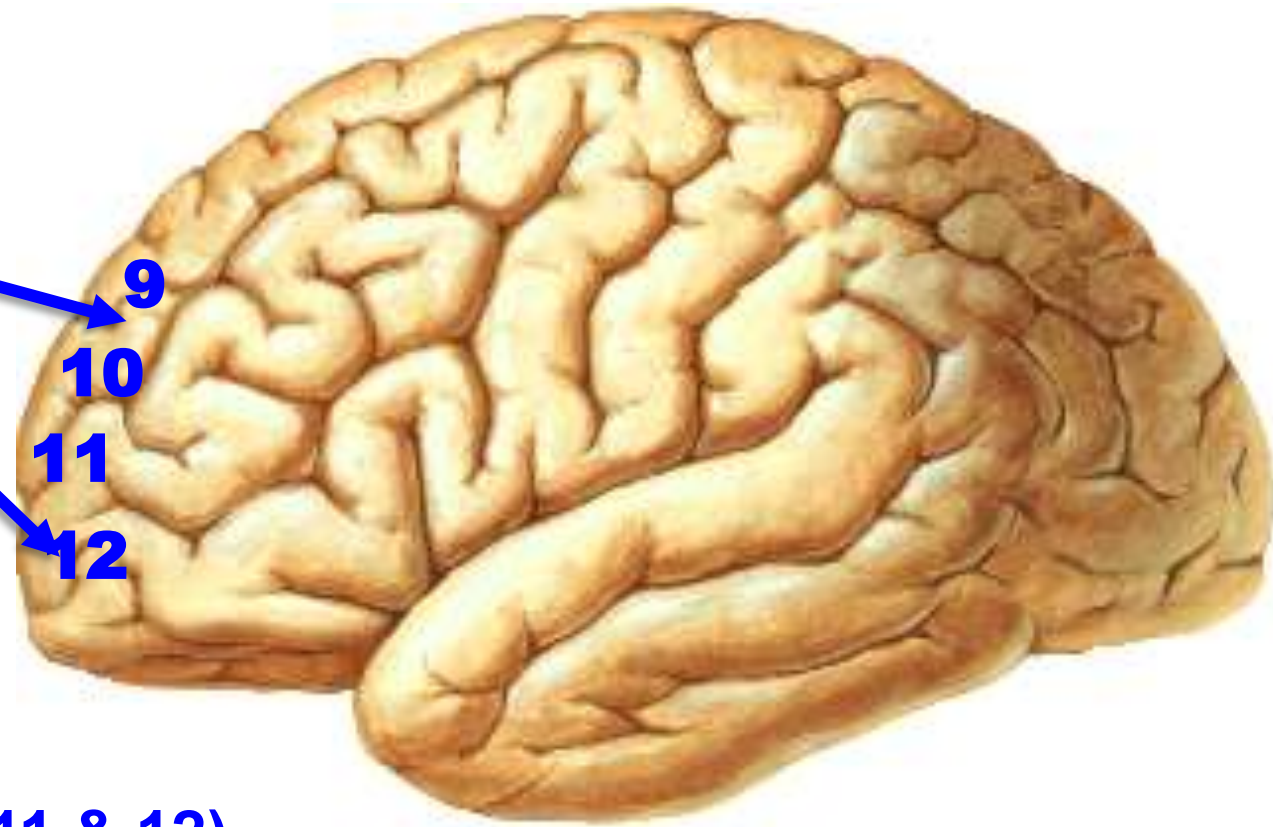
(Writing area)



- **Writing area (Exner's area);**
 - It lies in the middle frontal gyrus.
 - The person able to express himself in written words
 - Lesion leading to **Agraphia** (loss of ability to write)

dr_youssefhussein@yahoo.com

Prefrontal areas



Prefrontal area (areas 9,10,11,& 12)

- It lies in the most anterior part of the frontal lobe.

- **It is responsible for:**

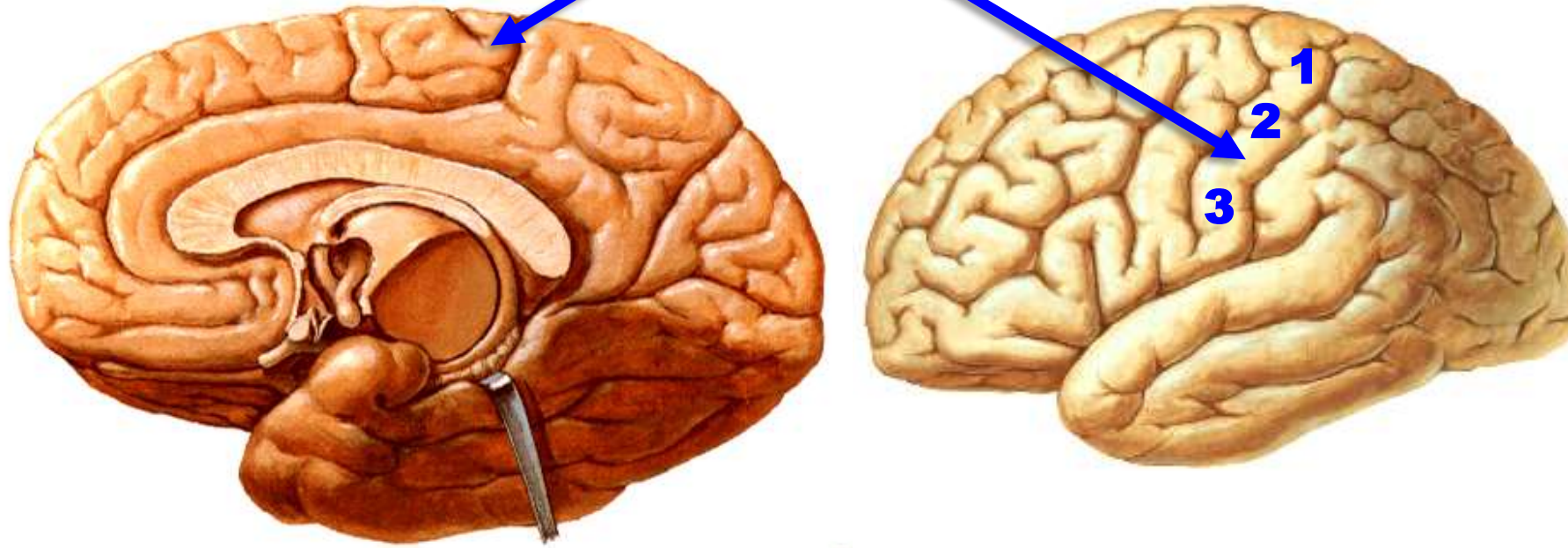
A- Planning, thinking, remember and problem solving

B- Motivating, emotions, good & sinful behavior, mood, psychological activities.

C- Telling of lies and truth

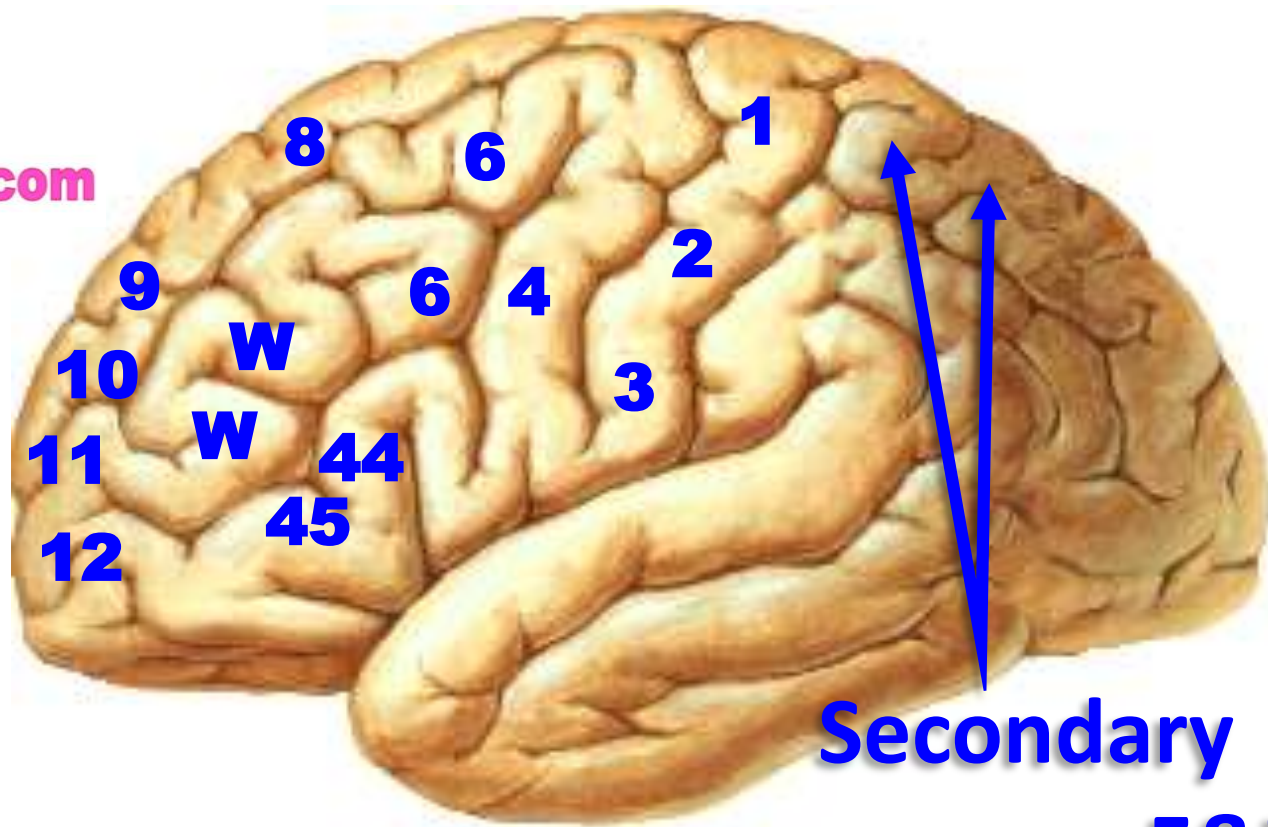
Somatosensory area 1,2,3

dr_youssefhussein@yahoo.com



- Somatosensory (**Primary sensory**) cortex corresponds to postcentral gyrus (**areas 1,2,3**), posterior part of paracentral lobule
- It receives sensations from opposite side of body.
- The body represented upside down
- Lesion in this area leads to **loss of sensation** in opposite side of the body.

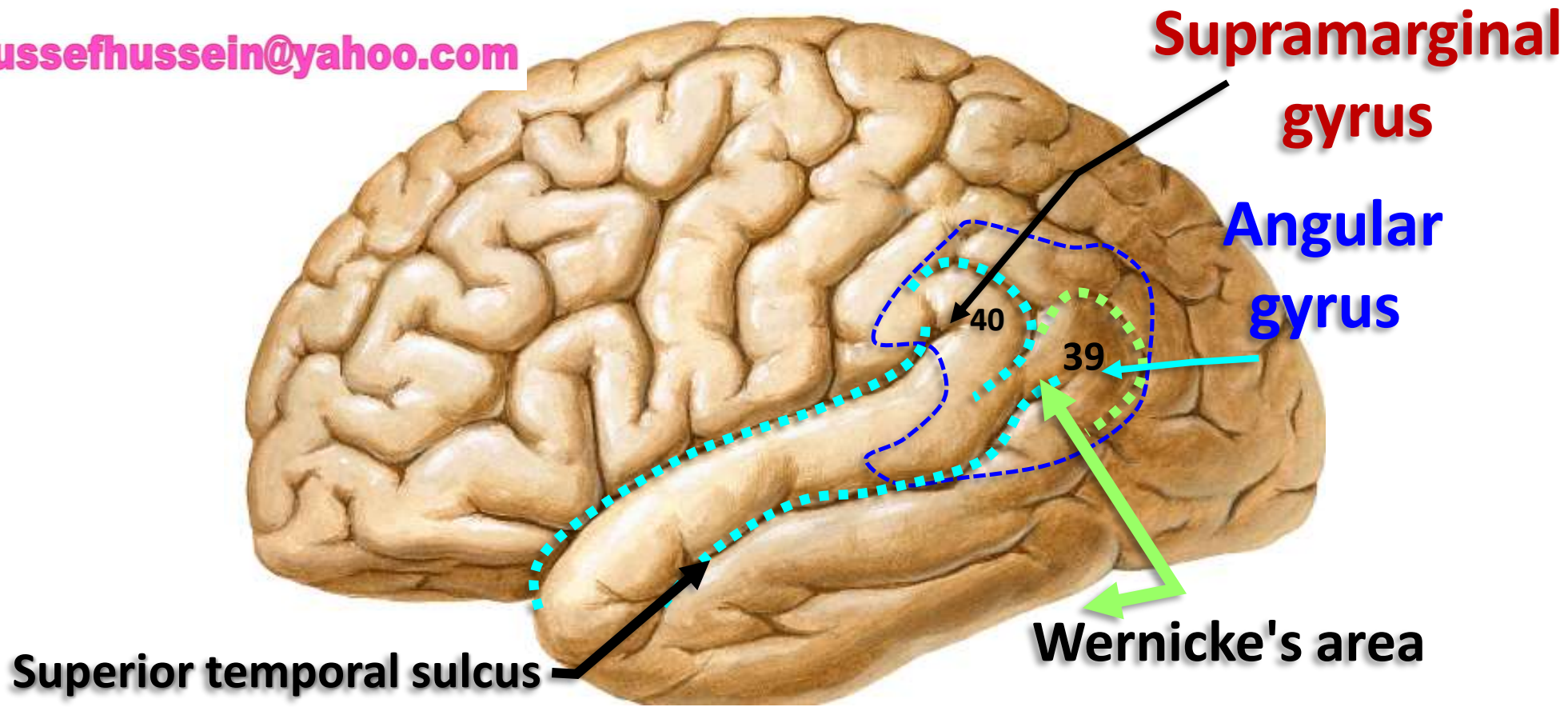
dr_youssefhussein@yahoo.com



Secondary
sensory 5&7

Secondary (Association) sensory area (area 5, 7);

- It occupies the superior parietal gyrus.
- Function, **stereognosis** (ability to identify the familiar objective manually in the absence of visual and auditory information) **shape, roughness, size of objects**
- Lesion results in **asteriognosis**

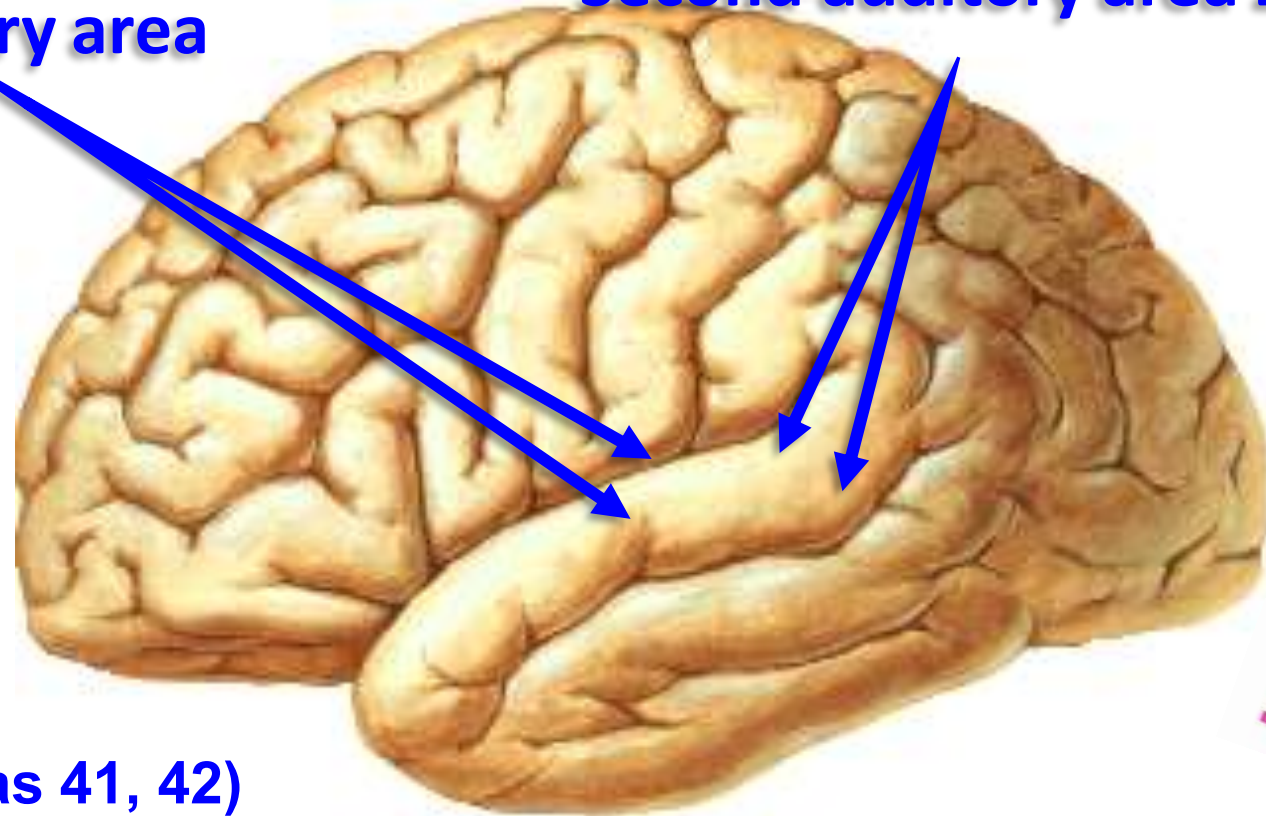


- **Sensory speech area (Wernicke's- area 39, 40).**

- It lies in inferior parietal gyrus extending to superior temporal gyrus, angular and marginal gyri.
- It is connected to motor speech area, auditory area and visual area.
- It is responsible for understanding spoken and written words.
- Lesion in this area produces **sensory aphasia** (can not understanding spoken and written words.).

**Primary auditory area
41&42**

Second auditory area 22

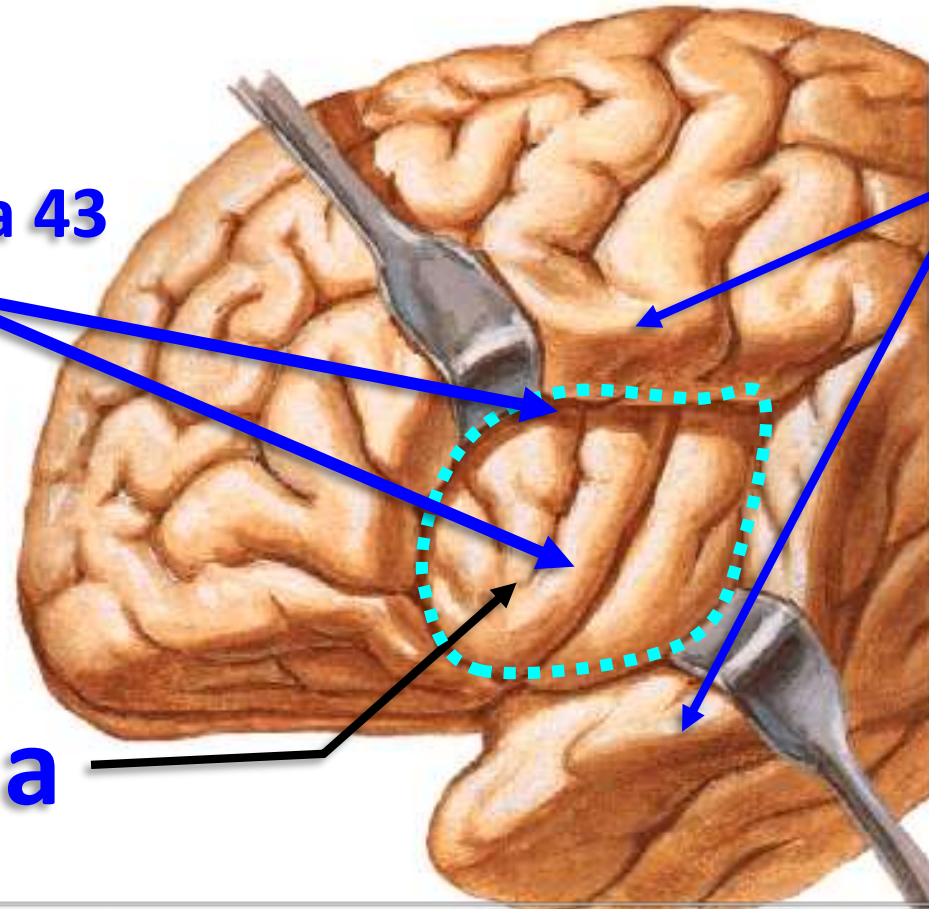


dr_youssefhussein@yahoo.com

- **Primary auditory area (areas 41, 42)**
 - It is present in the floor of the posterior ramus of the lateral sulcus and the middle part of the superior temporal gyrus (**Heschl's gyrus**).
 - It receives auditory radiation from the medial geniculate body (MGB).
 - Lesion of this area leads to **diminished hearing**.
- **Auditory association area (Secondary) (area 22):** behind the primary auditory area.
 - It is responsible for recognition and interpretation of the sounds.

Gustatory area 43

Insula



the lips of the
lateral sulcus
are
separated

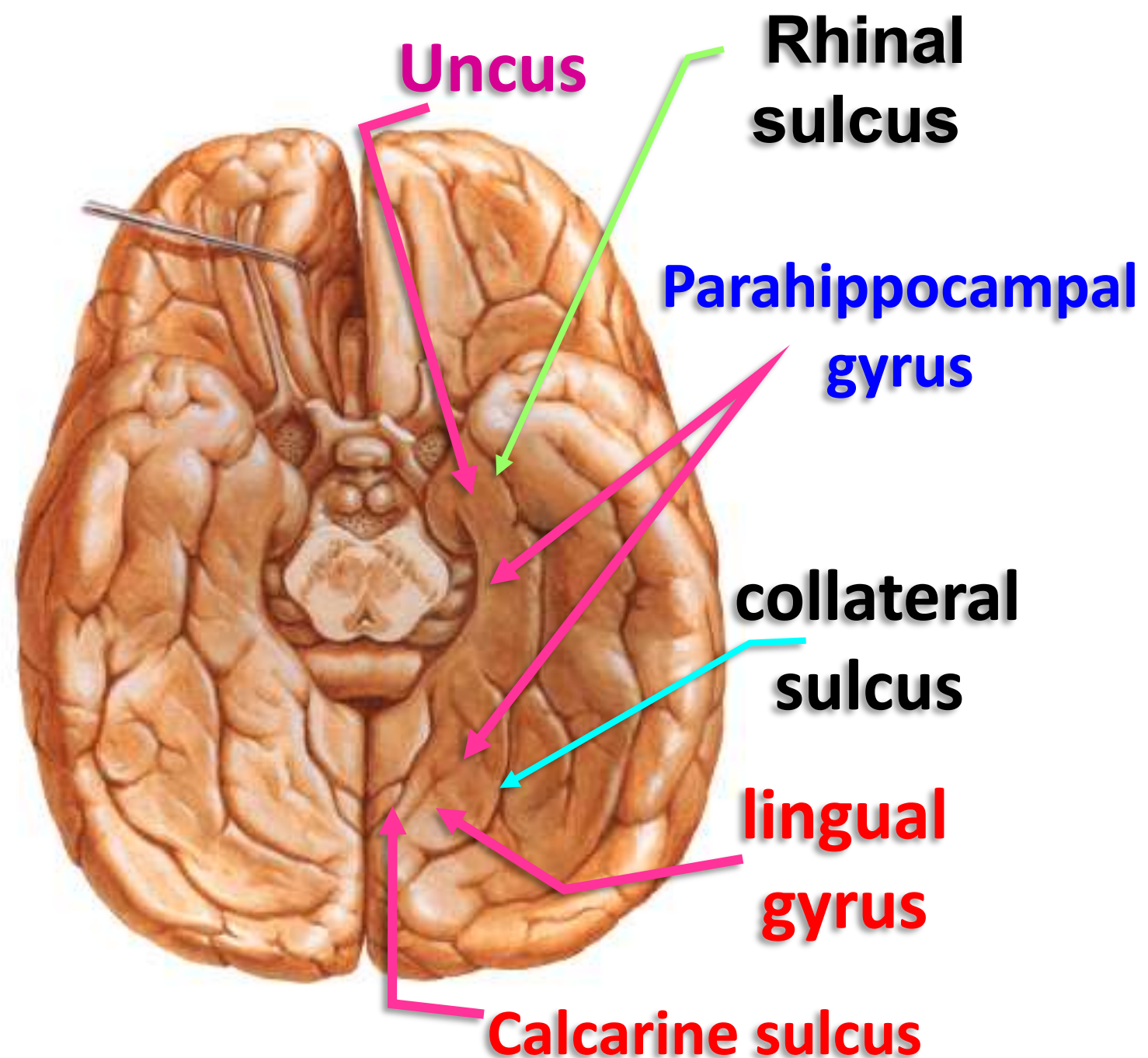
dr_youssefhussein@yahoo.com

- **Gustatory area** (area 43): lies in the insula .
- It is concerned with the recognition of the taste sensation.
- **Insula** lies at the bottom of the deep lateral sulcus and cannot be seen from the surface unless the lips of the sulcus are separated.

On the tentorial surface:

- **Lingual gyrus** between collateral sulcus and calcarine sulcus
- **Para hippocampal gyrus** anterior to the lingual gyrus (**Limbic system**)

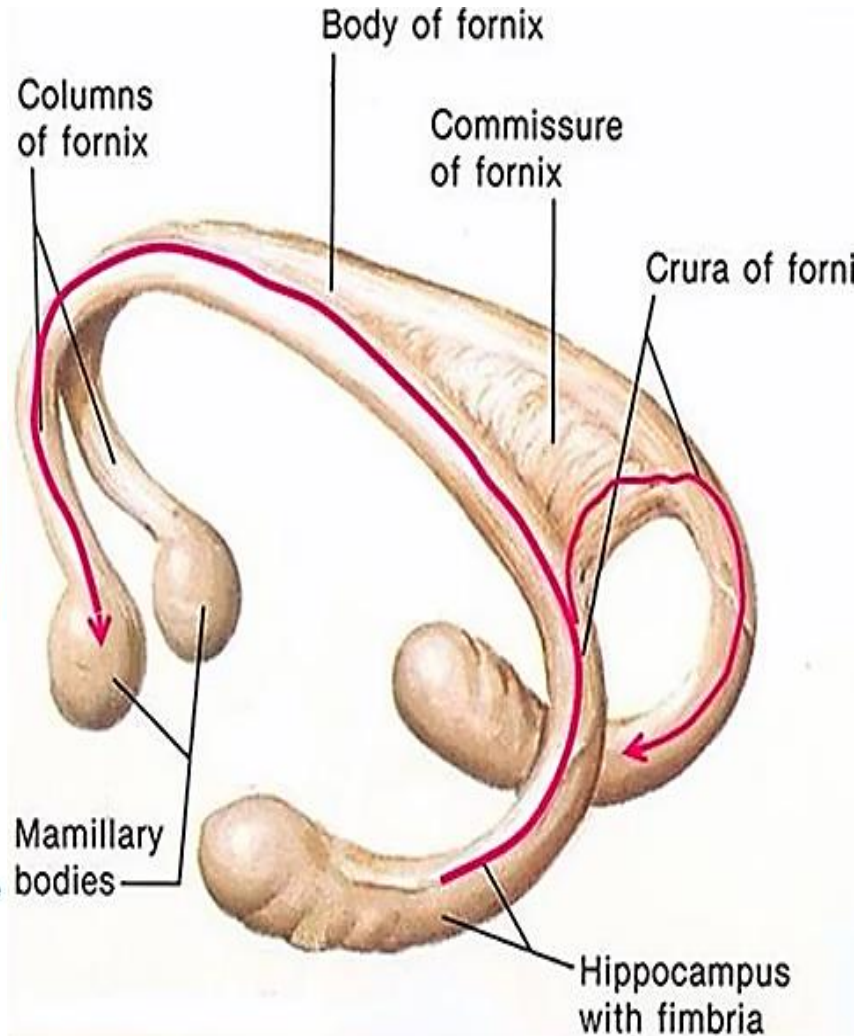
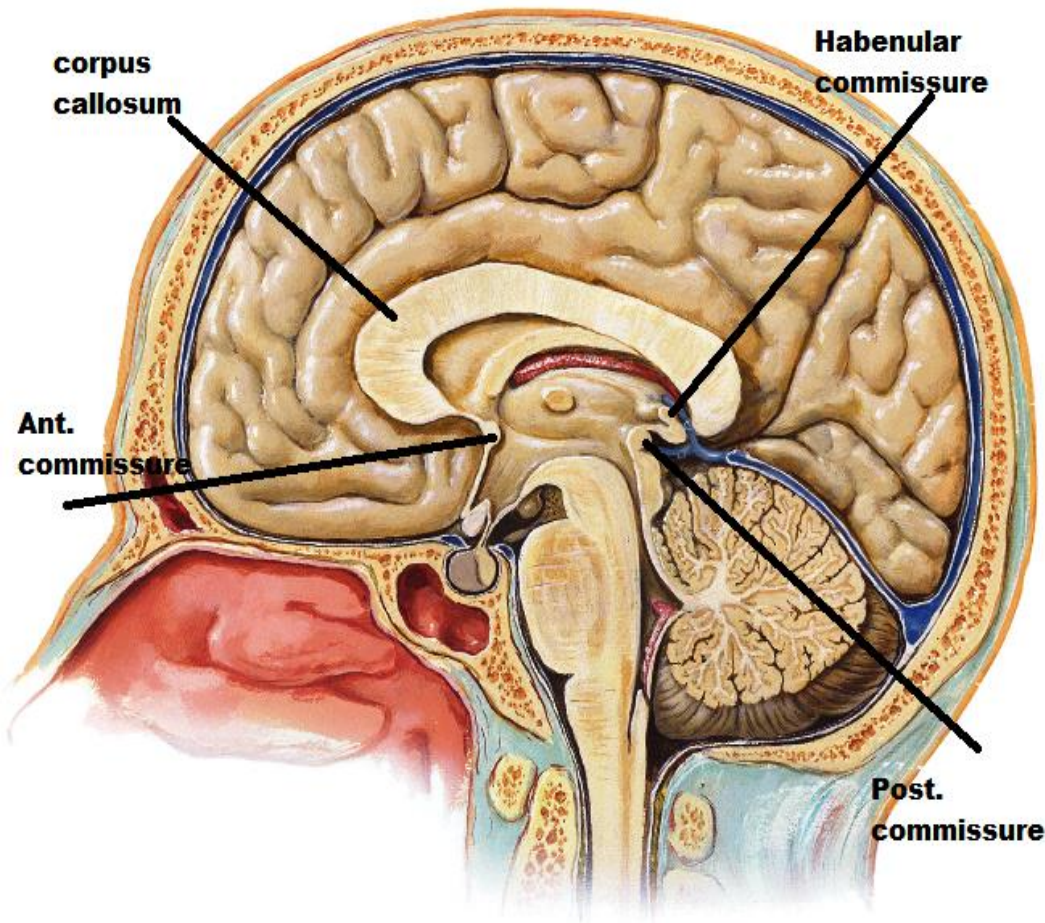
- **Uncus** anterior to Para hippocampal gyrus, a hook-shaped convolution close to the temporal pole medial to the rhinal sulcus. **Center of the olfactory**



COMMISSURAL FIBERS

Types

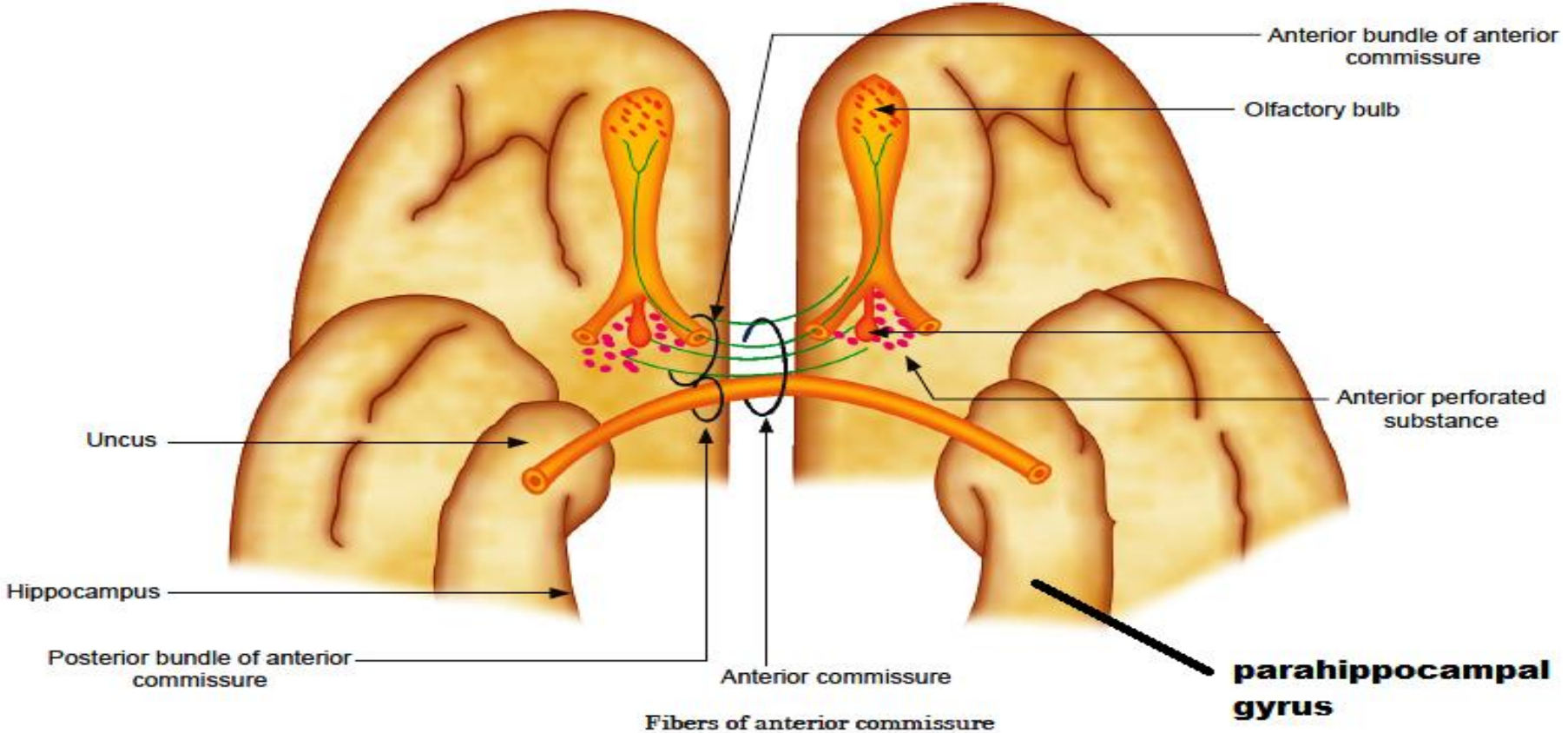
1. Corpus callosum
2. Anterior commissure
3. Habenular commissure
4. Posterior commissure
5. Hippocampal commissure.



COMMISSURAL FIBERS

1-anterior commissure:

- it is a small rounded bundle embedded in the upper end of lamina terminalis, just in front columns of fornix
- connects olfactory structures of both sides :olfactory bulb, ant. perforated substance, uncus & ant. part of parahippocampal gyrus



COMMISSURAL FIBERS

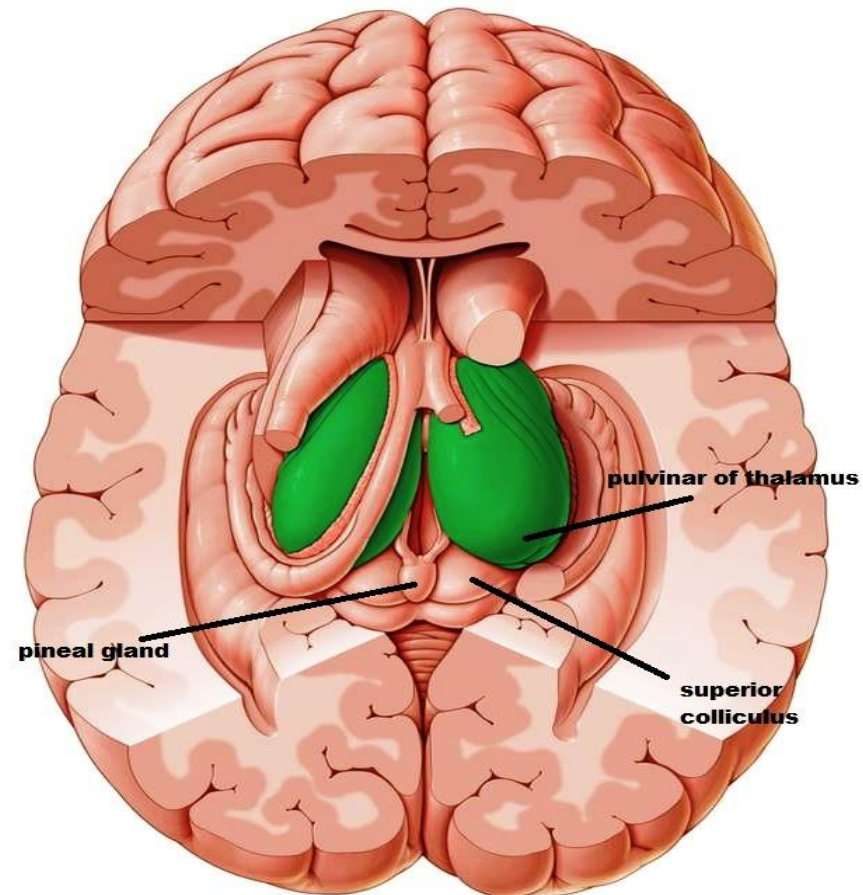
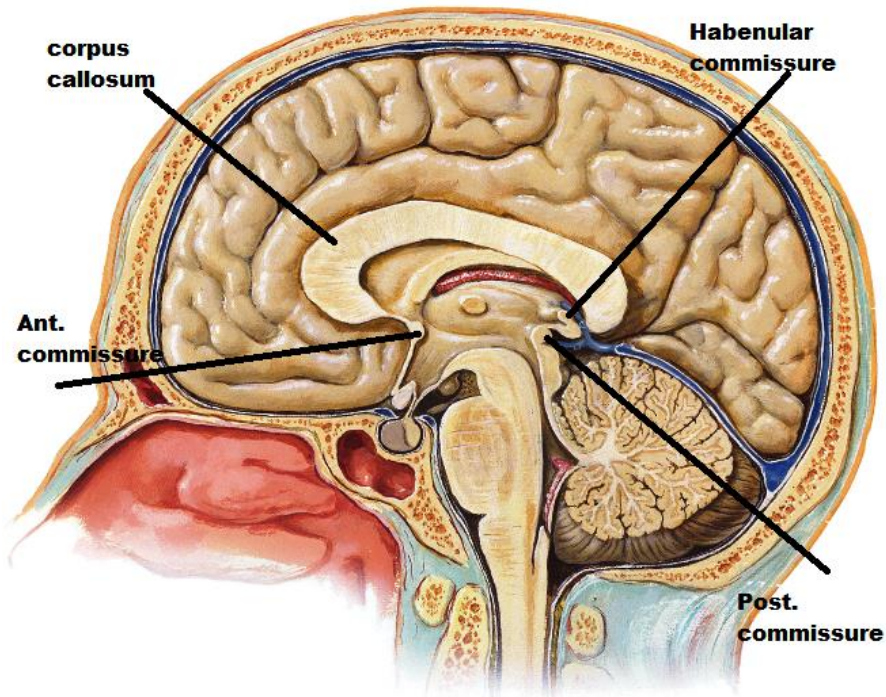
2-post. commissure (midbrain commissure)

- in inferior part of pineal stalk, above the upper end of cerebral aqueduct
- it connects the following structures on both sides:

Midbrain nuclei

Pulvinar of thalamus

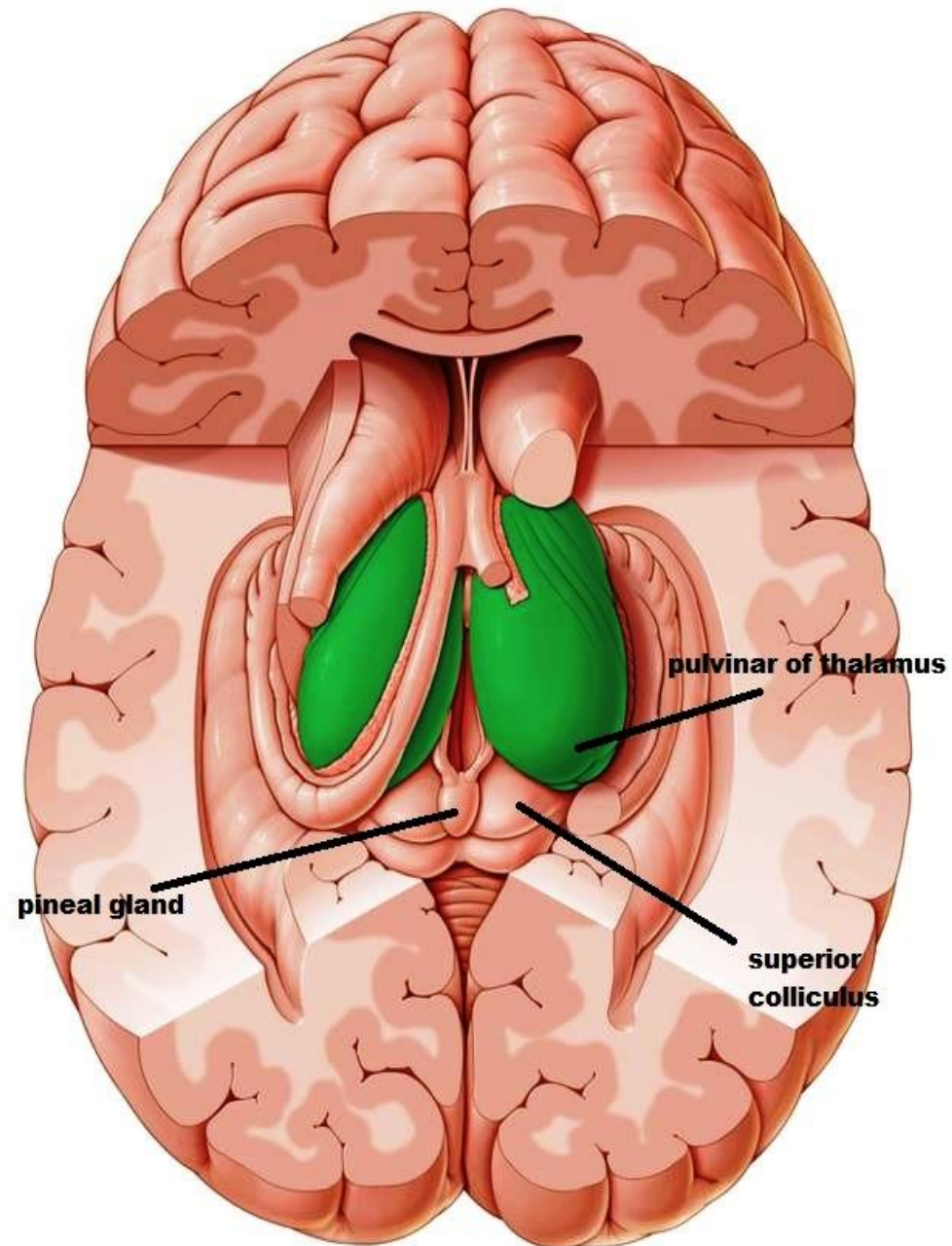
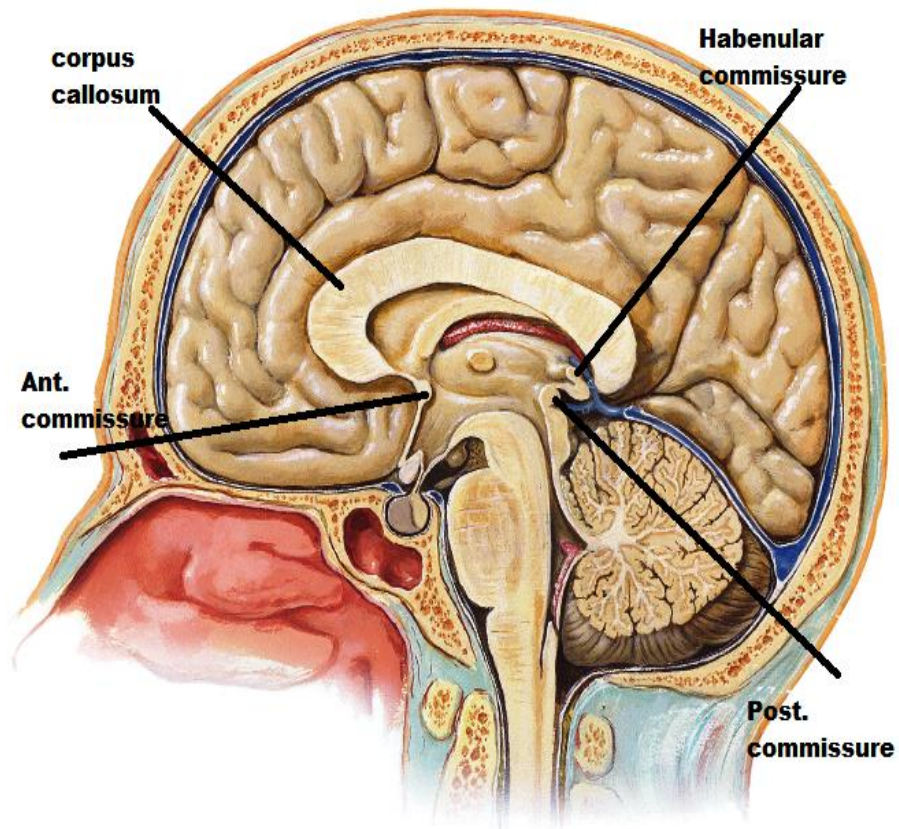
superior colliculus



COMMISSURAL FIBERS

3-habenular commissure:

- in superior lamina of pineal stalk
- it connects habenular nuclei of both sides of epithalamus



COMMISSURAL FIBERS C.C.

parts:

1-rostrum:

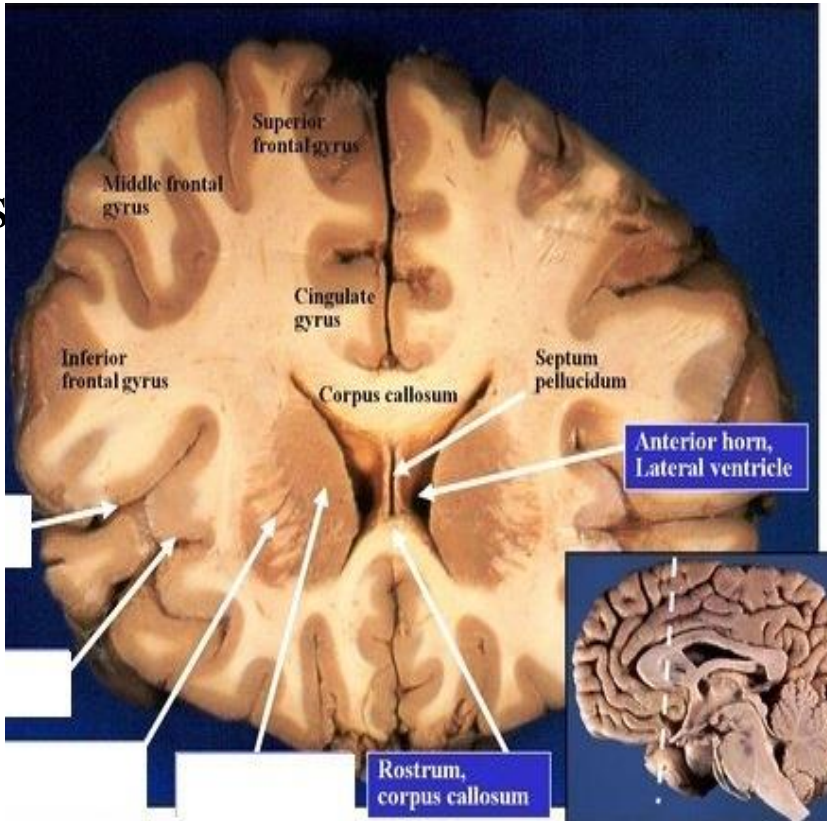
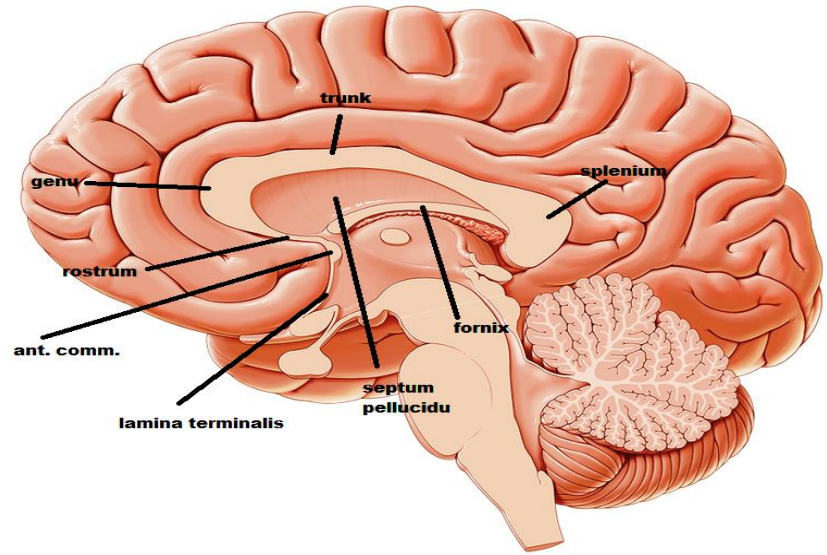
in sagittal section

It is thinnest part of corpus callosum .

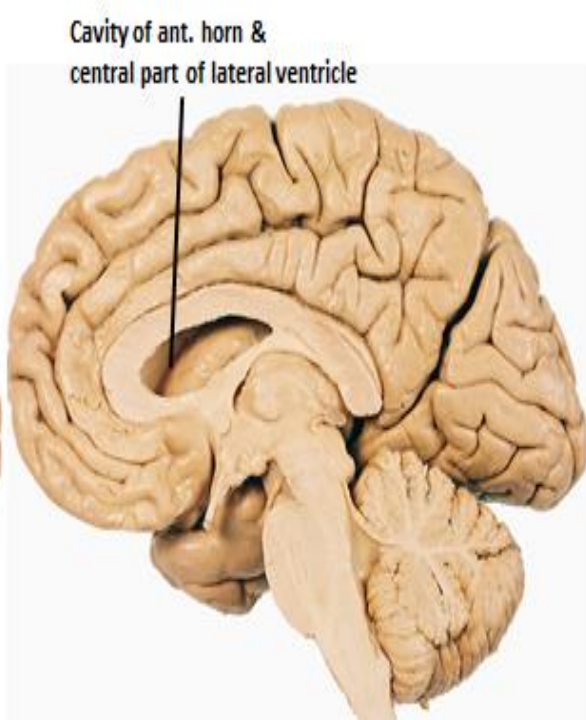
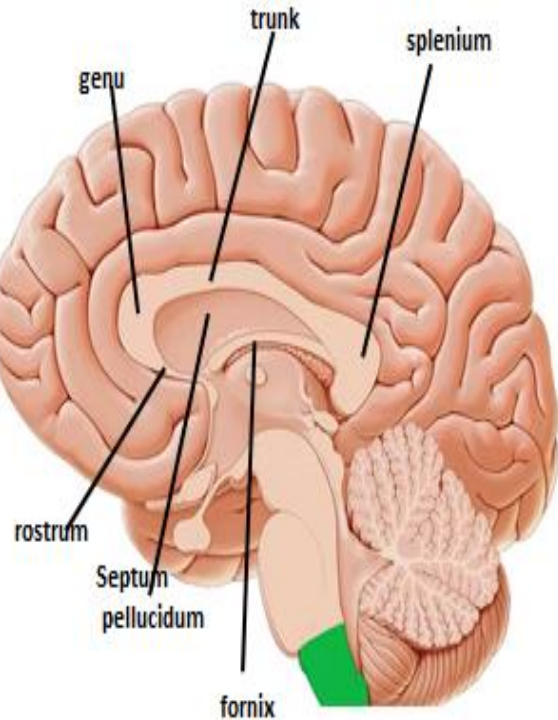
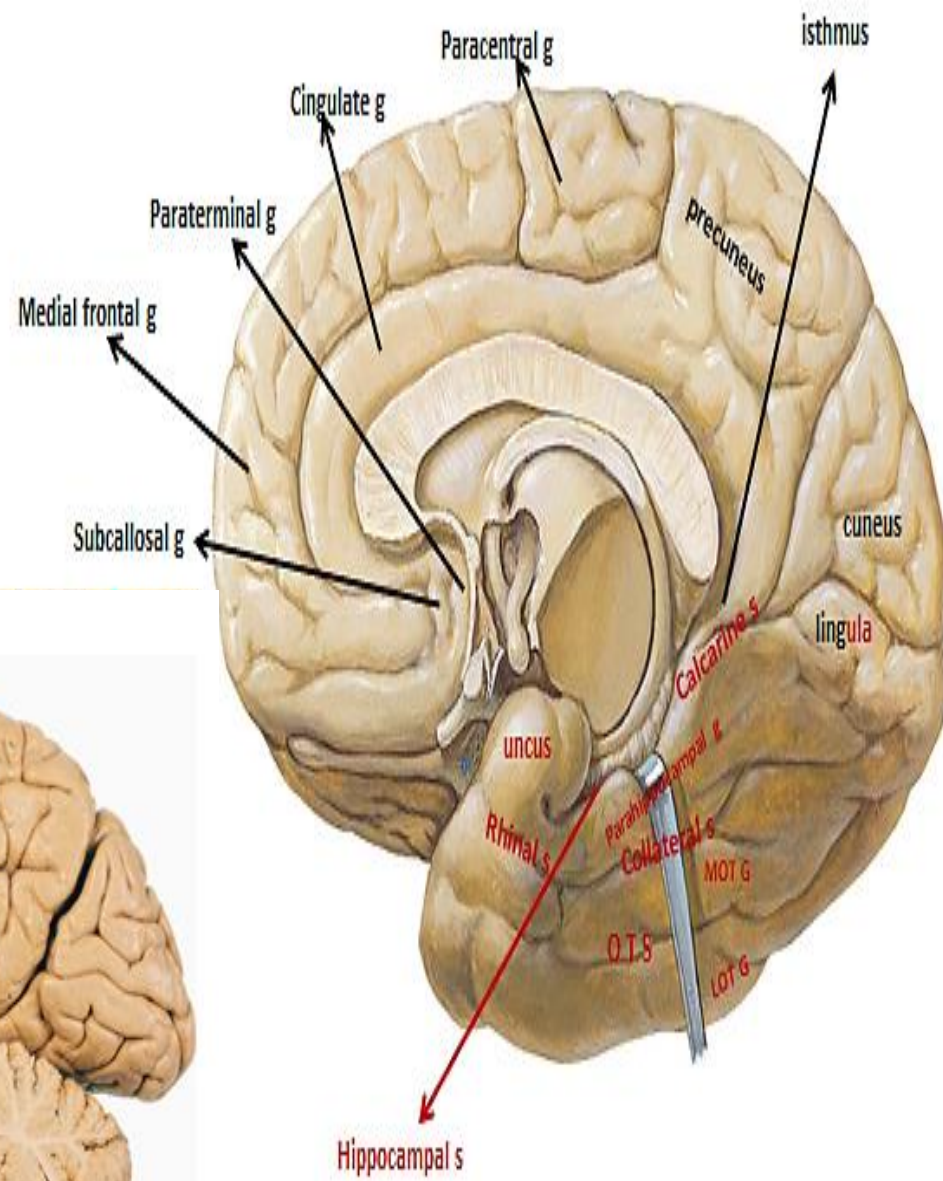
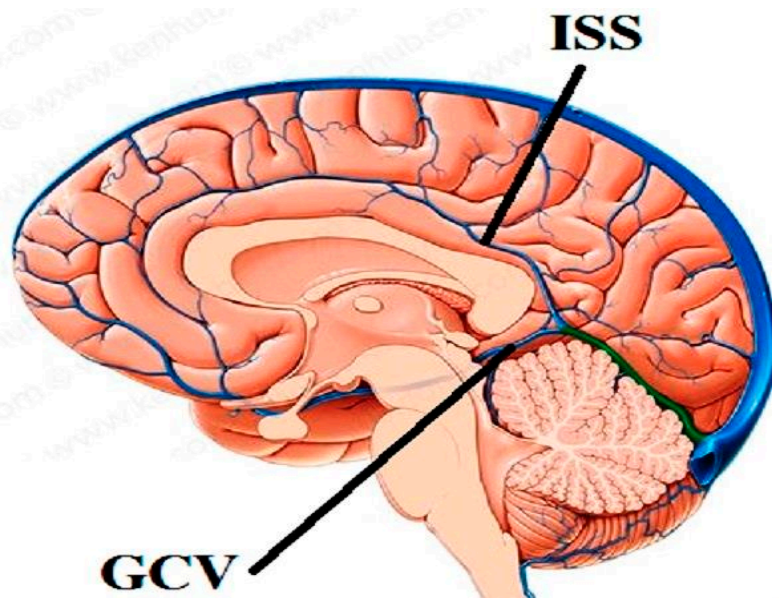
From the genu it directs backwards and downwards to end at the level of ant. Commissure to be continued with lamina terminalis

in coronal section: inverted V shape,

its fibers connect the orbital surfaces of frontal lobes on both sides



COMMISSURAL FIBERS C.C.



PROJECTION FIBERS

Def.:-afferent(ascending) and efferent (descending) fibers to and from cerebral cortex

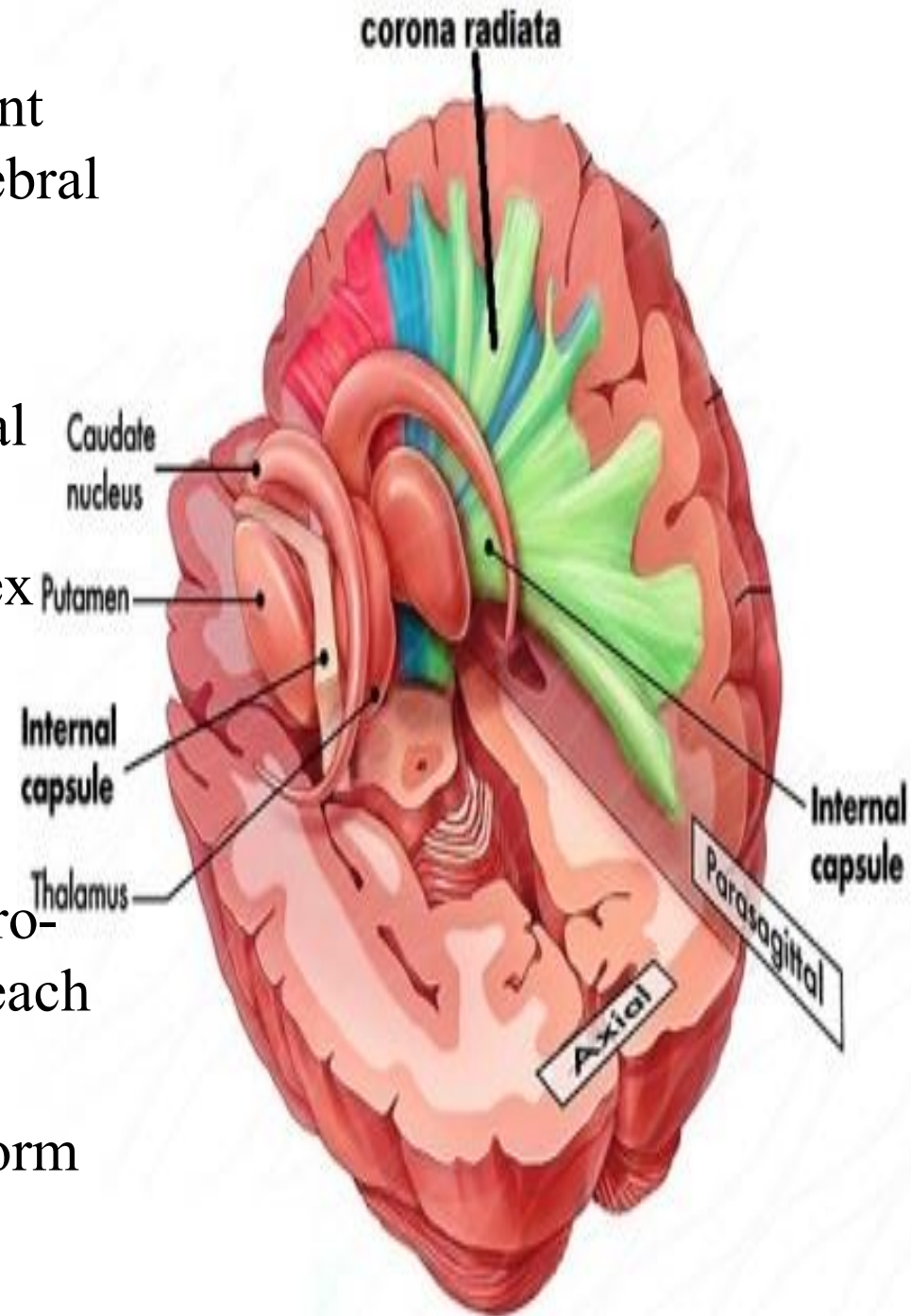
It includes

-the projection fibers of hippocampal formation (Fornix)

-the projection fibers of rest of cortex (corona radiata & internal capsule)

1-corona radiata

- Fan shaped sheet
- Superiorly its fibers diverge antero-posteriorly and transversely to reach the cerebral cortex
- inferiorly its fibers converge to form internal capsule

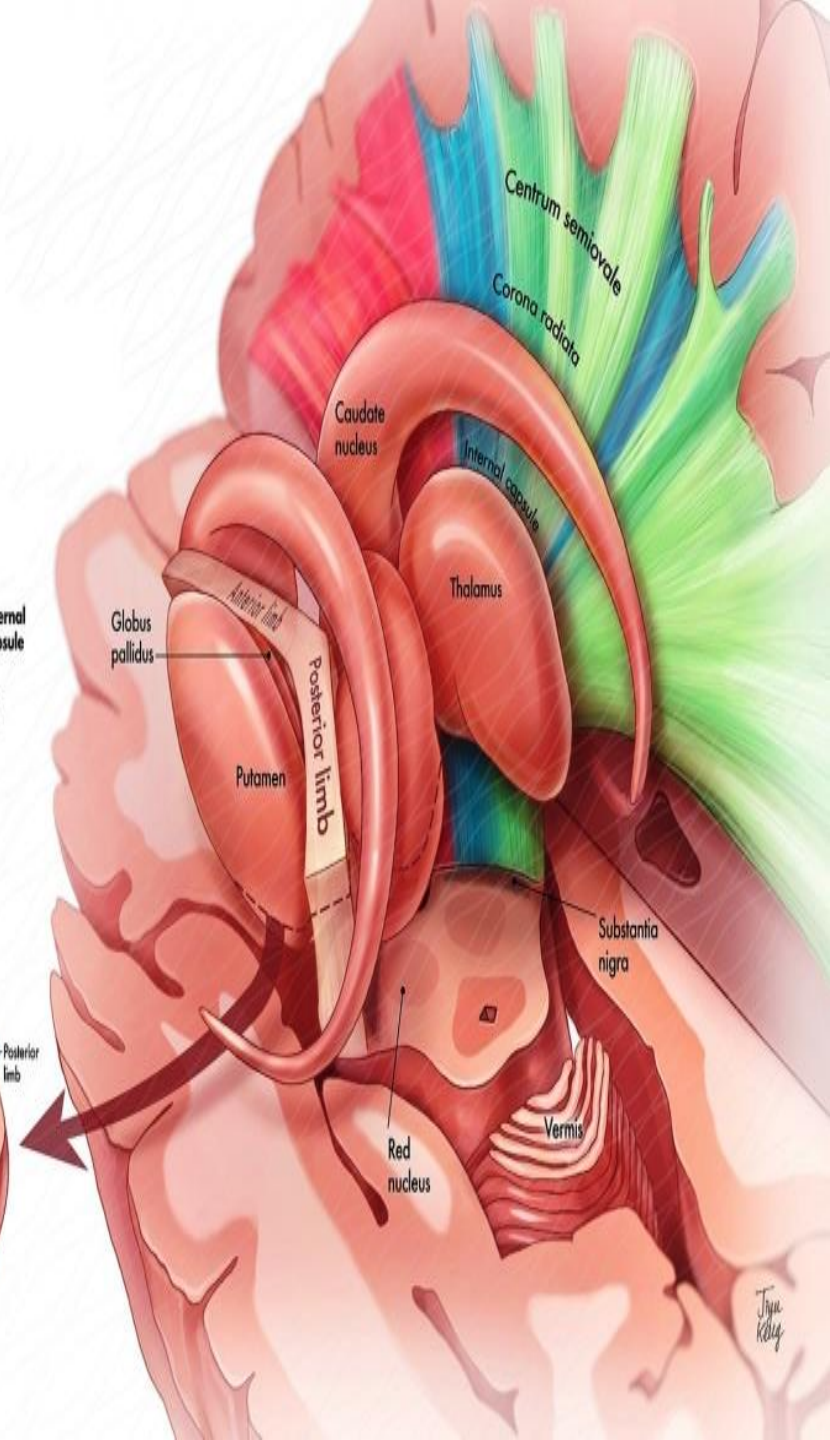
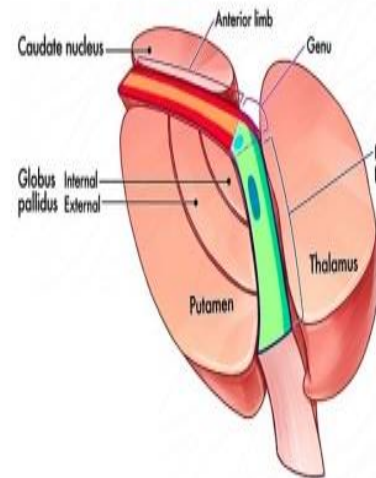
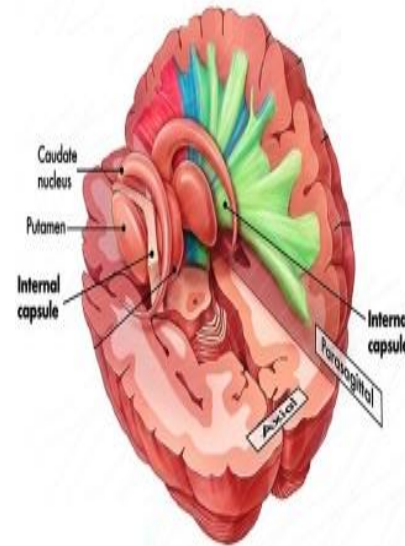


PROJECTION FIBERS

2-internal capsule

Def. & site:

It is the fibers of corona radiata after being collected on the medial side of lentiform nucleus, lateral to head of caudate and thalamus



PROJECTION FIBERS

2-internal capsule

Shape & Parts & relations:

in coronal section:

L shaped

with post. limb & 5-sublenticular part which lies below post. end of lentiform N.

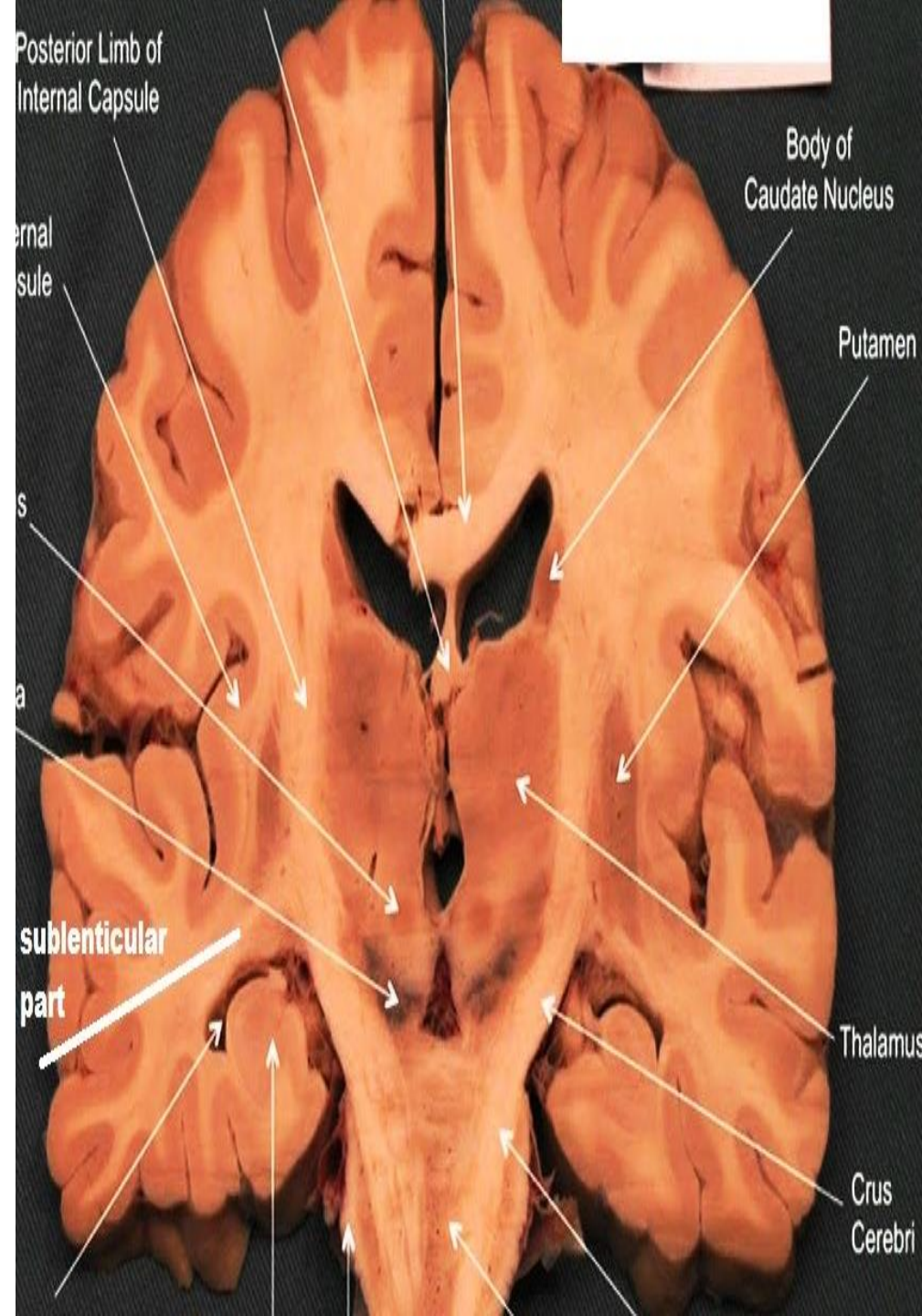continuity:

superiorly:

continuous with corona radiata

inferiorly:

continuous with crus cerebri



BASAL NUCLEI

Lentiform

Shape

biconvex lens,
with ant. and pos. ends,
convex lateral and medial surfaces

Parts

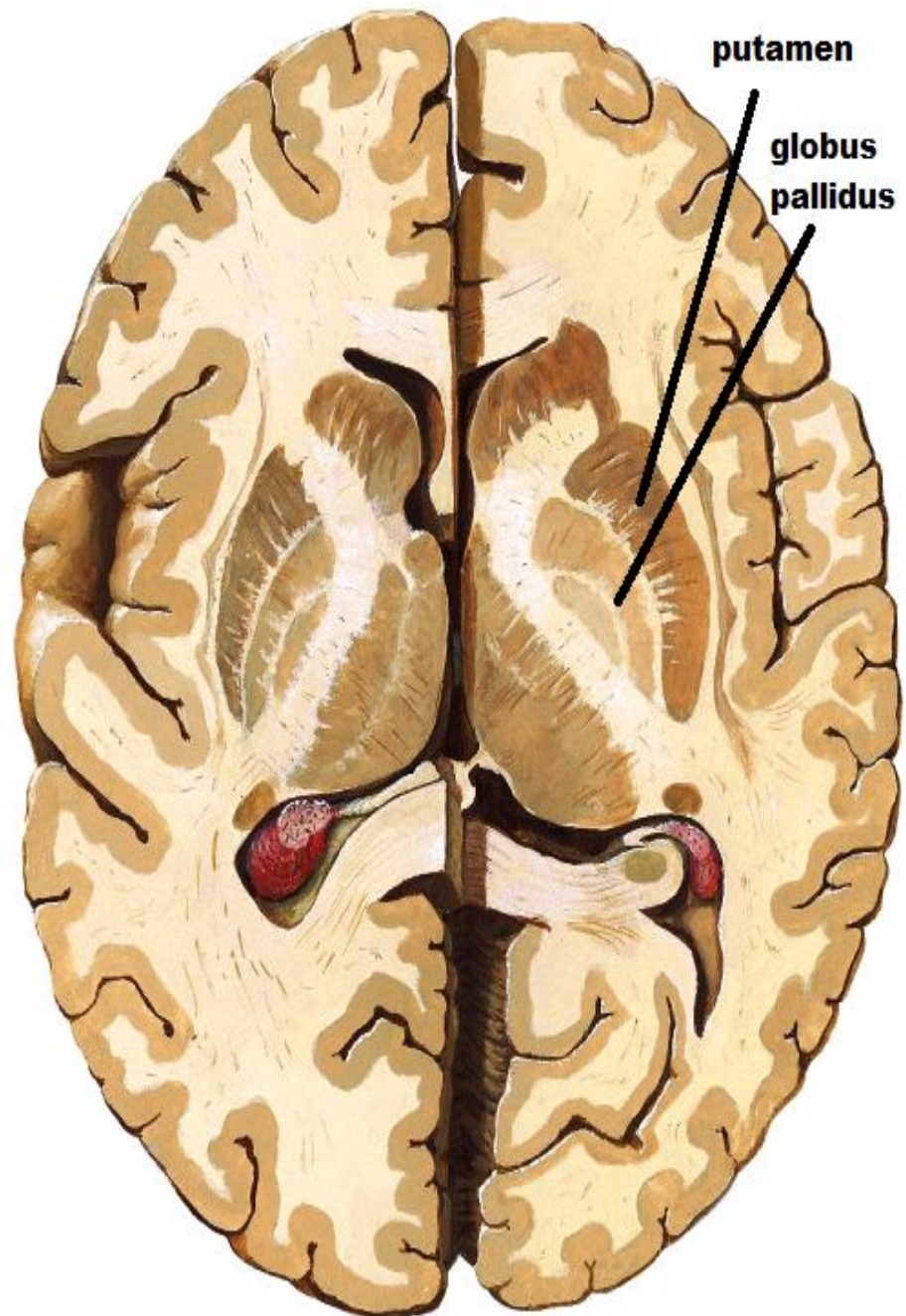
as seen in sections, it is two parts:
putamen , globus pallidus

1-putamen:

Larger-Lateral-darker(multiple small cells)-the afferent part

2-globus pallidus:

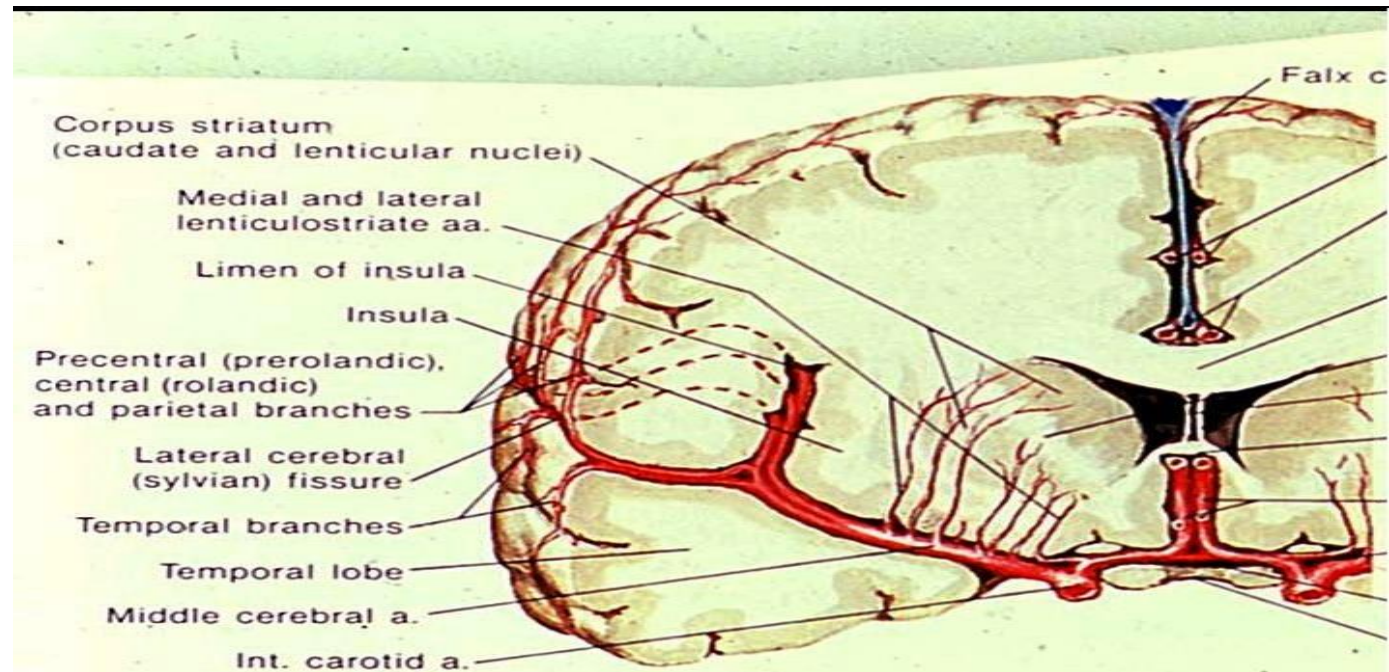
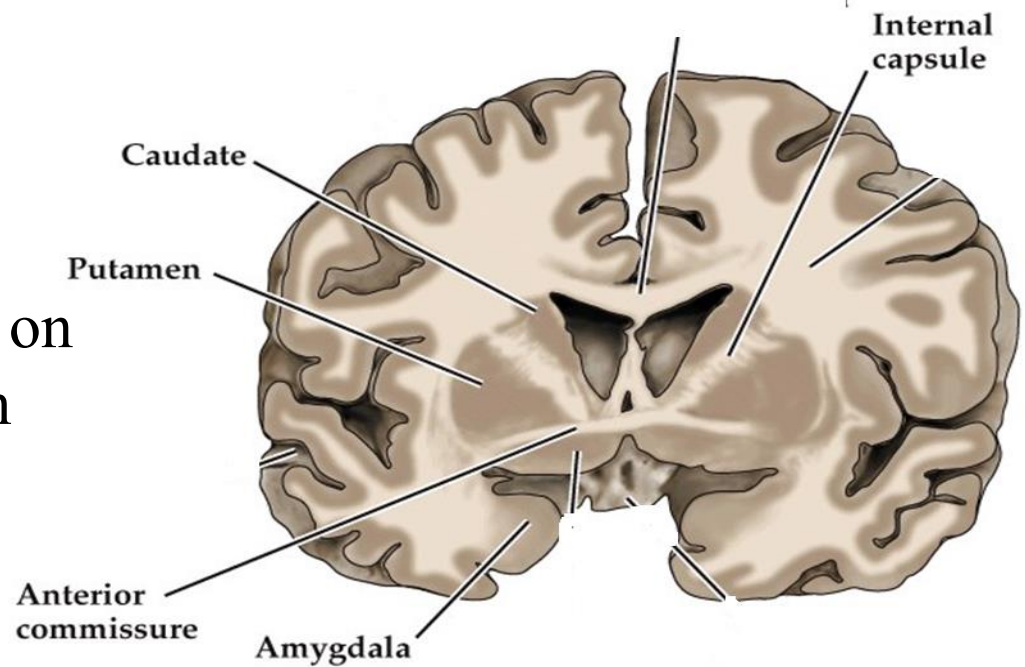
Smaller-medial-paler-(fewer larger cells)-the efferent part



BASAL NUCLEI

Relations of lentiform inferiorly:

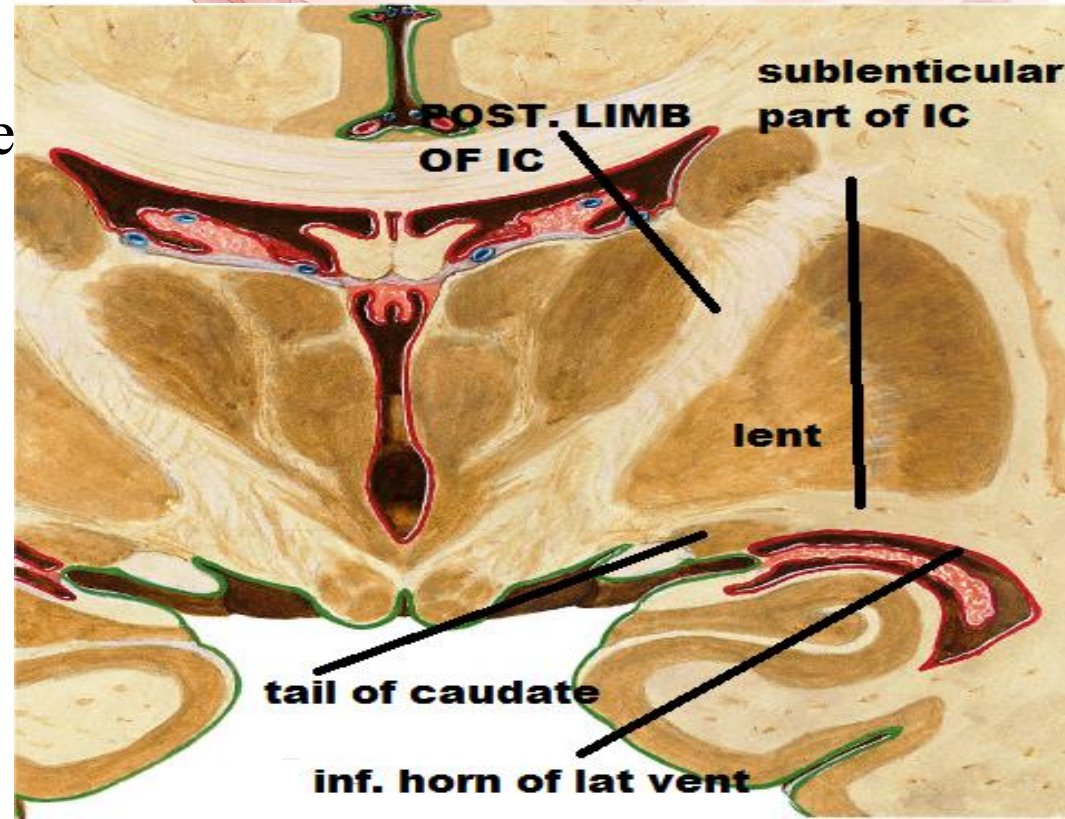
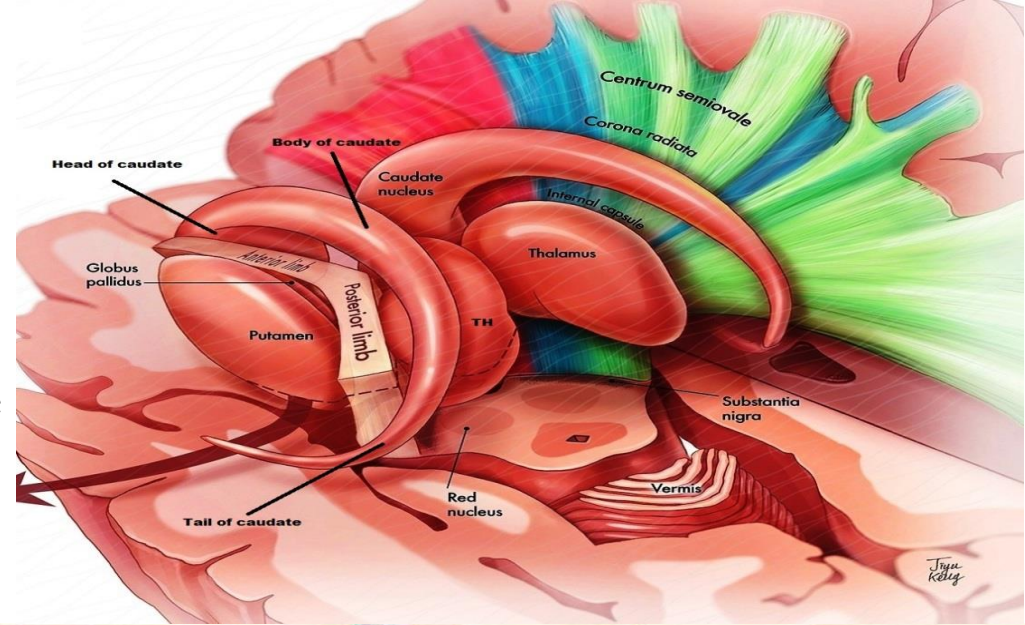
- ant. commissure: form groove on the inferior surface of lentiform nucleus
- ant. perforated substance:
- pierced by striate arteries.
- amygdaloid



BASAL NUCLEI

Relations of lentiform inferiorly:

- sublenticular part of int. capsule that separate the lentiform from
- stria terminalis
- tail of caudate
- inferior horn of lateral ventricle



BASAL NUCLEI

Relations of caudate

body

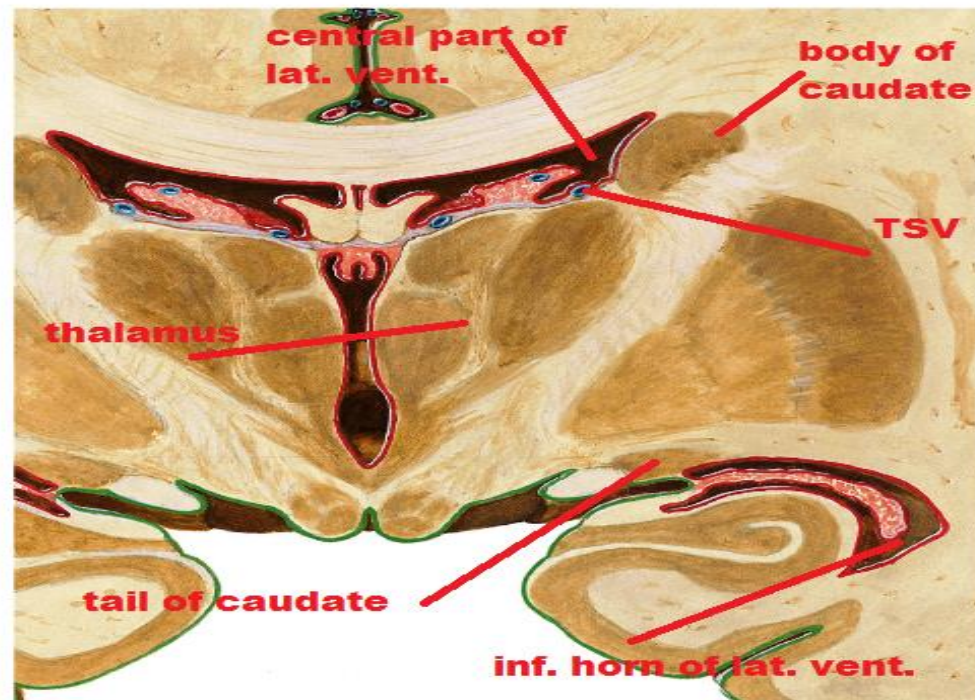
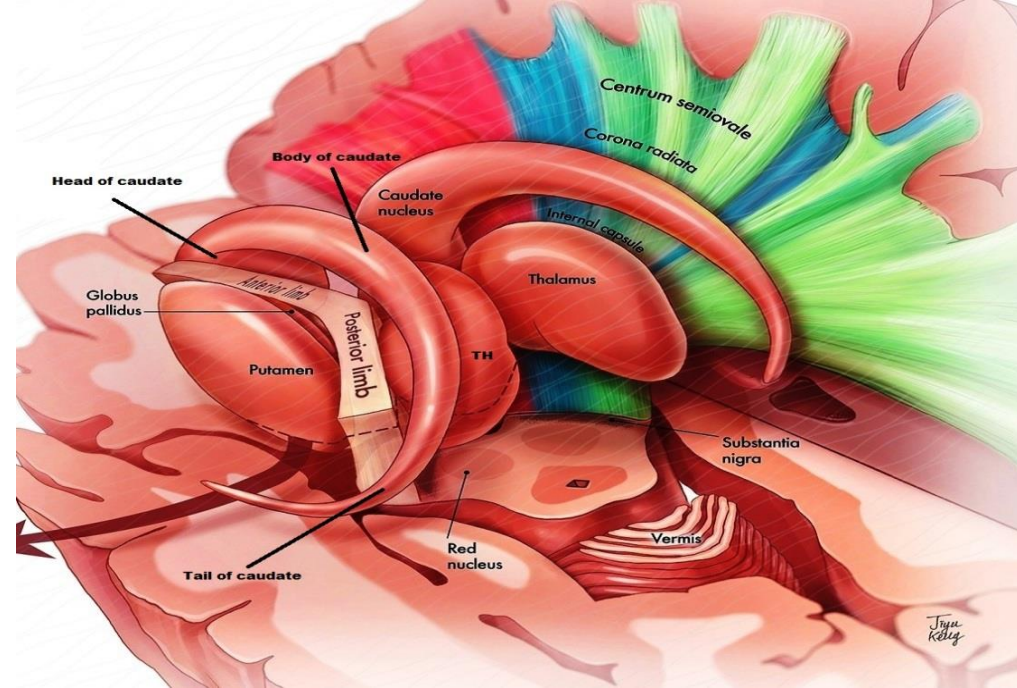
seen in middle coronal section with the following relations:

-it lies superolateral to thalamus separated from it by groove that contain stria terminalis & thalamostriate v.

-forms the most lateral structure in floor of central part of lateral ventricle

tail

form part of the roof of inferior horn of the lateral ventricle



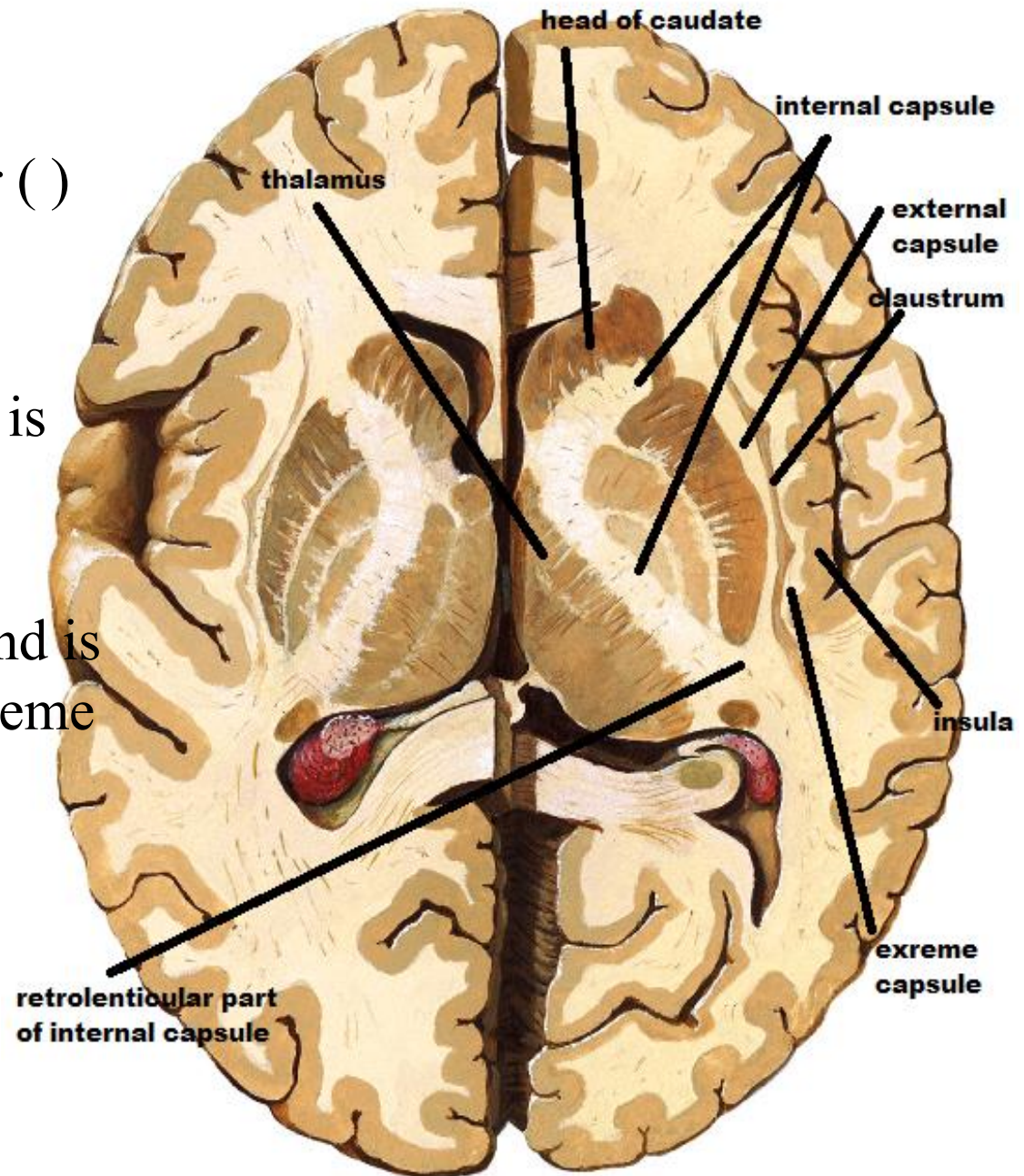
BASAL NUCLEI

Clastrum

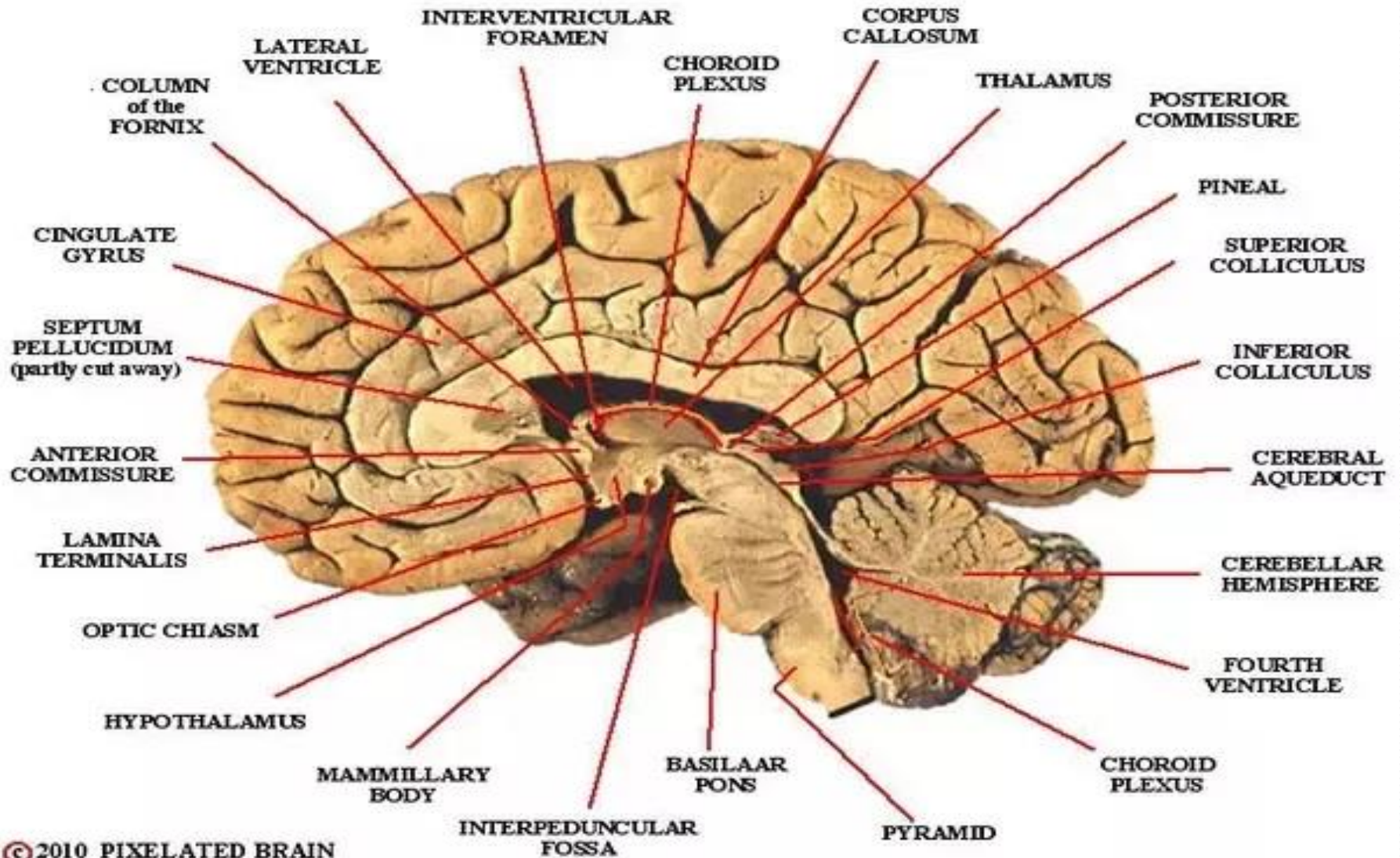
Site: thin plate of grey matter ()
lentiform nucleus & insula

Shape & relations:

- medial surface is smooth & is separated from putamen of lentiform by external capsule
- lateral surface is irregular and is separated from insula by extreme capsule



DIENCEPHALON



Diencephalon

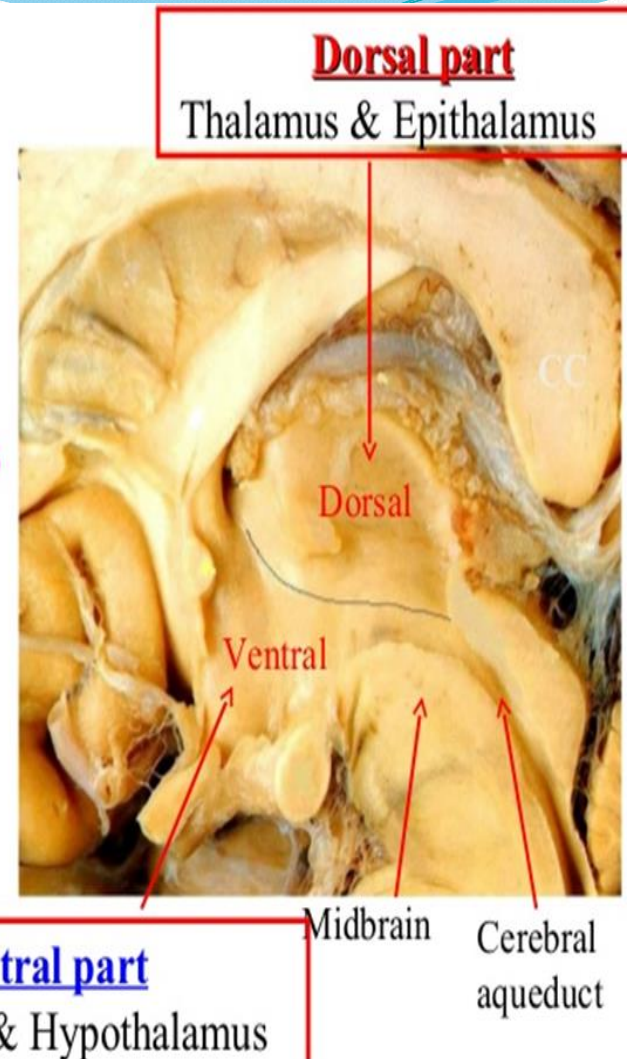
Site:- It is the part of the forebrain which lies above the midbrain, between the lower parts of the 2 cerebral hemispheres.

• It consists of:

1. **Thalamus**:-the large oval mass of grey matter
2. **Subthalamus**:- it lies directly above midbrain
3. **Hypothalamus**: lies in front of subthalamus
4. **Metathalamus**: formed by lateral & medial geniculate body
5. **Epithalamus**: Formed of pineal body, 2 habenular nuclei & posterior commissure.

The third ventricle lies between the 2 halves of the diencephalon.

- On the medial surface, the diencephalon is subdivided, by **hypothalamic sulcus** (indicated by black line) into:
 - **Dorsal part**:
 - **Ventral part**:



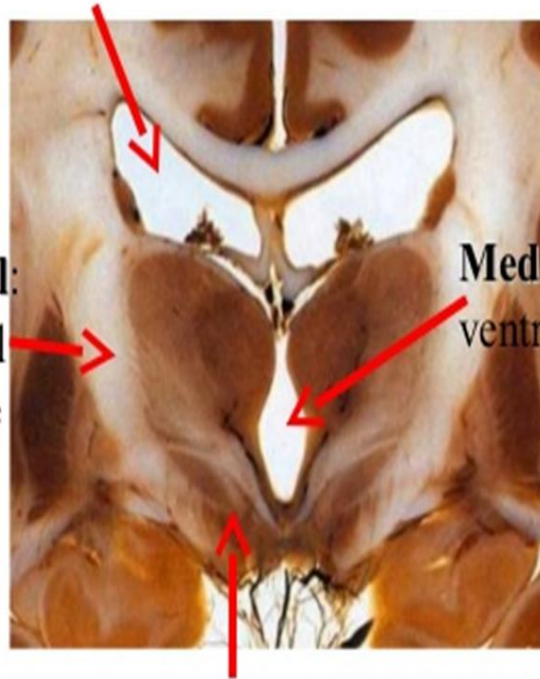
1. Thalamus

- **Def.:** oval mass of grey matter situated on each side of the 3rd ventricle . 4 cm long and 1.5 cm broad.
- **Two ends:** Anterior and posterior.
- **Four surfaces:** Superior, inferior, medial and lateral.

Relations

Dorsal: lateral ventricle

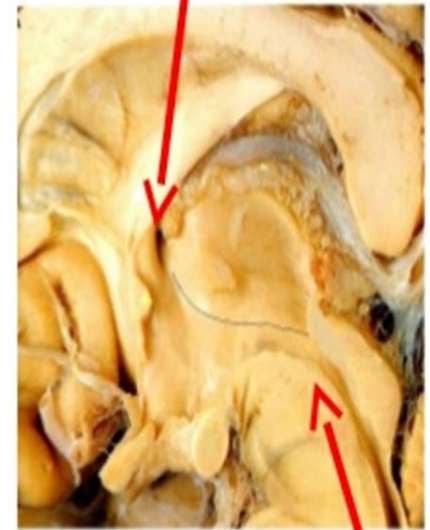
Lateral:
Internal capsule



Medial: 3rd ventricle

Ventral: Subthalamus & Hypothalamus

Rostrally
interventricular
foramen

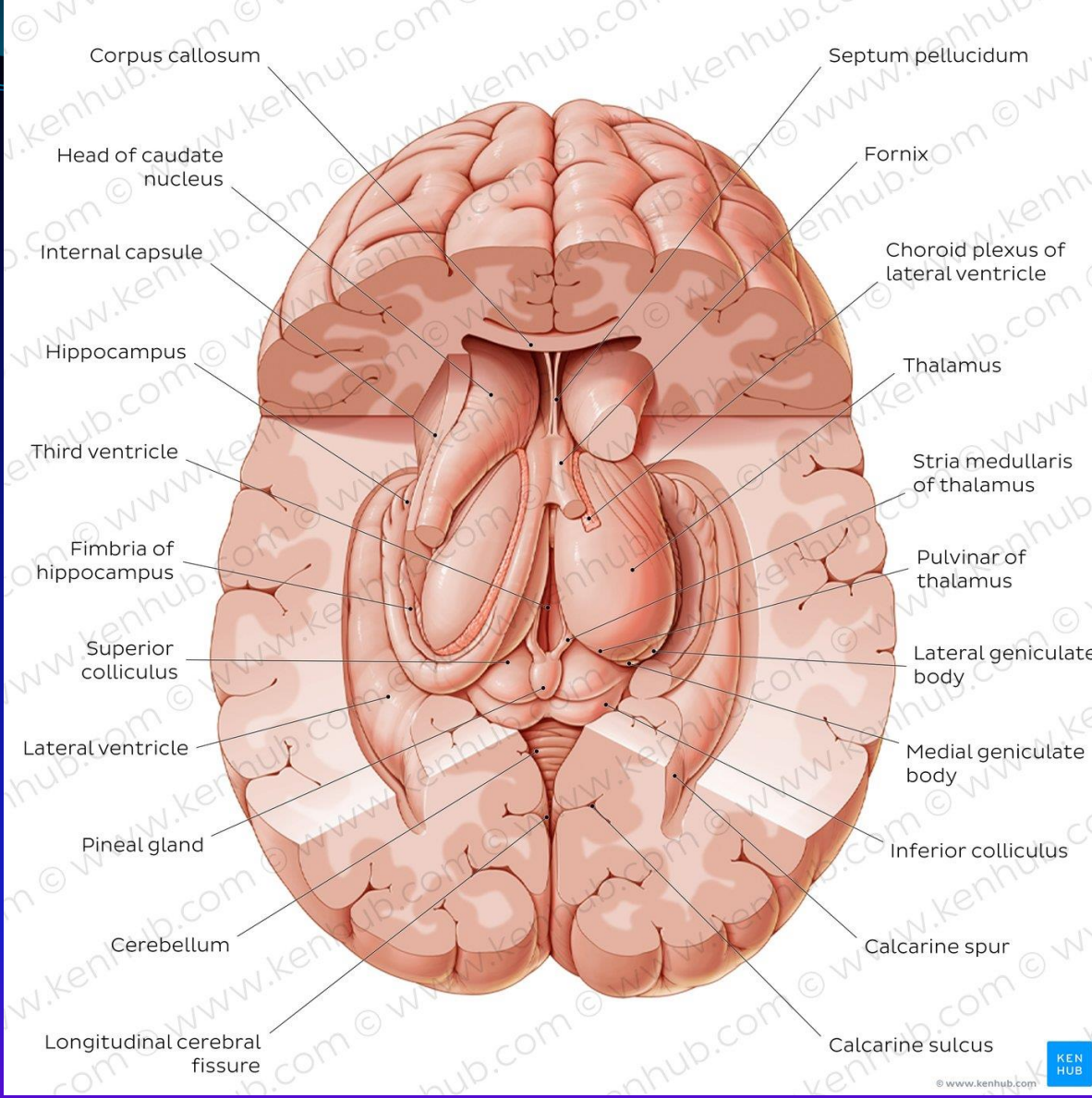


Caudal: midbrain

• Relations :

• **Anterior end:** It is narrow and lies near the median plane forming the posterior boundary of the interventricular foramen.

• **Posterior end:** (pulvinar). Expanded It is directed dorsally and laterally overhanging the superior colliculus and its brachium.

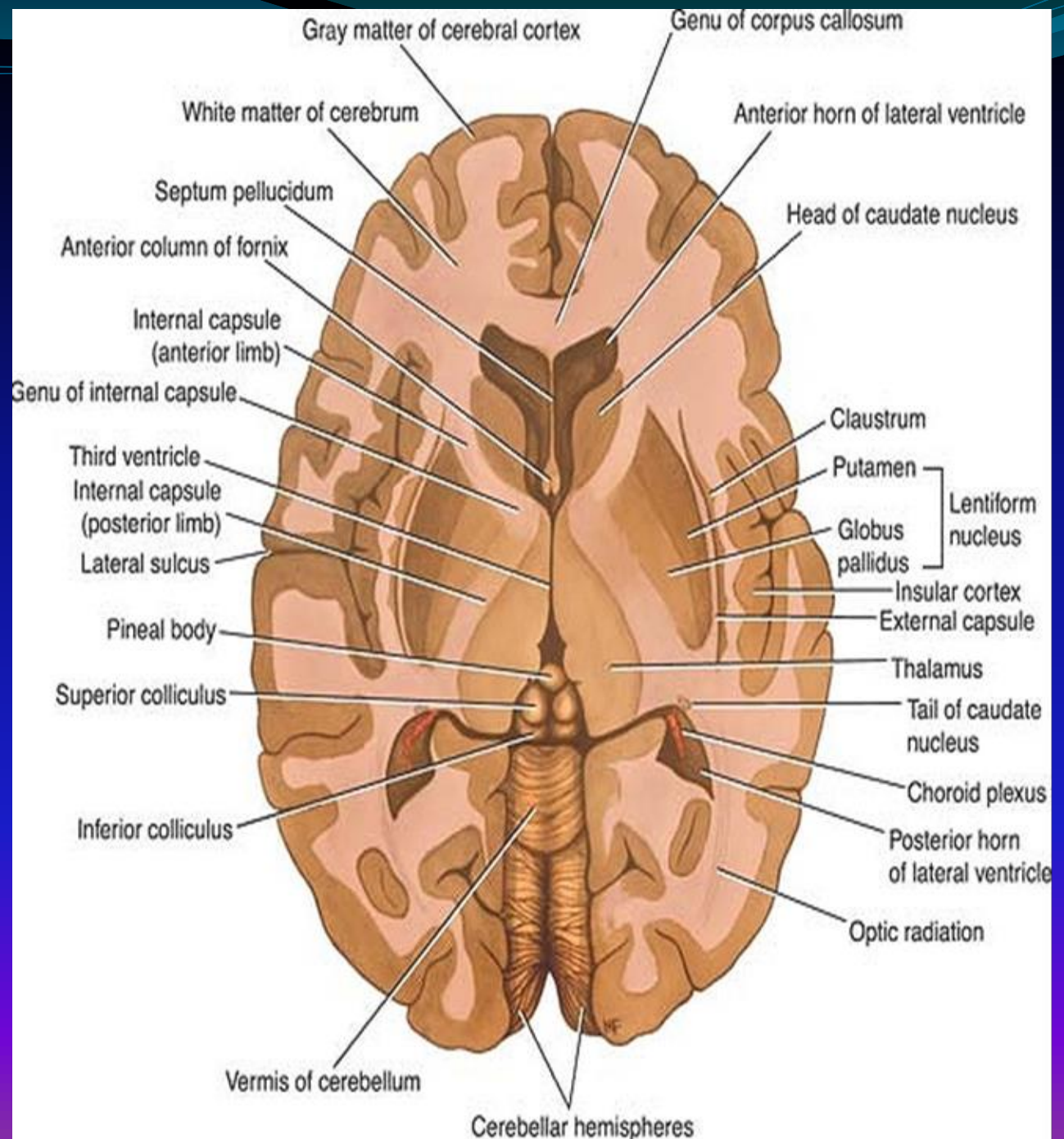


- Lateral surface:** It is related to the posterior limb of the internal capsule which separates it from the lentiform nucleus.

- Medial surface:** This surface is related to the cavity of the 3rd ventricle.

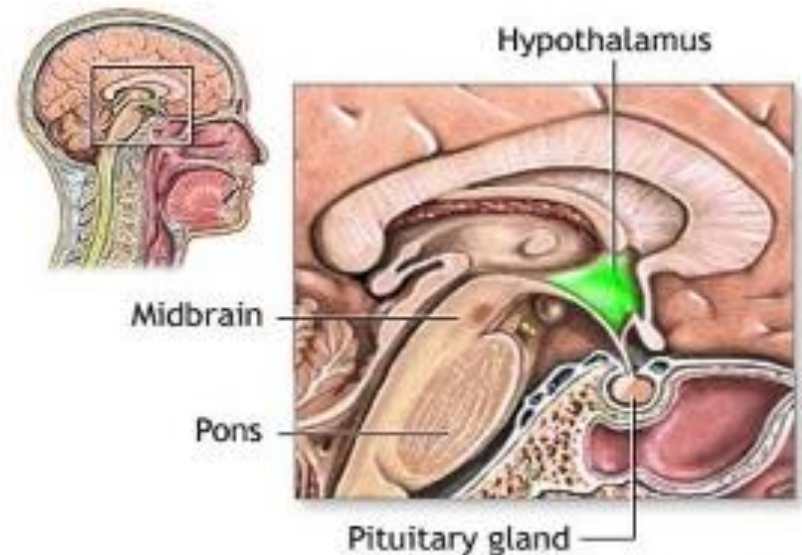
- The upper edge of this surface is related to a band of white matter called stria medullaris thalami (or stria habenularis).

This surface is connected to the corresponding surface of the opposite thalamus by a band of grey matter called inter-thalamic adhesion.

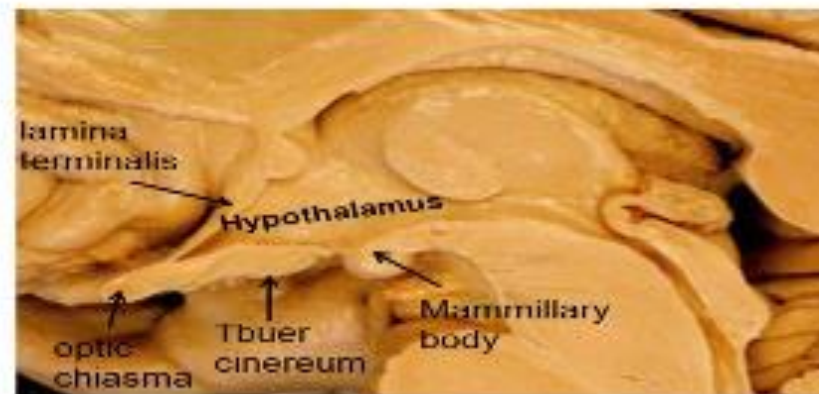


Hypothalamus

- The hypothalamus is the part of the diencephalon forming the floor and the lower part of the lateral wall of the third ventricle. It extends from the region of the optic chiasma to the caudal border of the mammillary bodies.

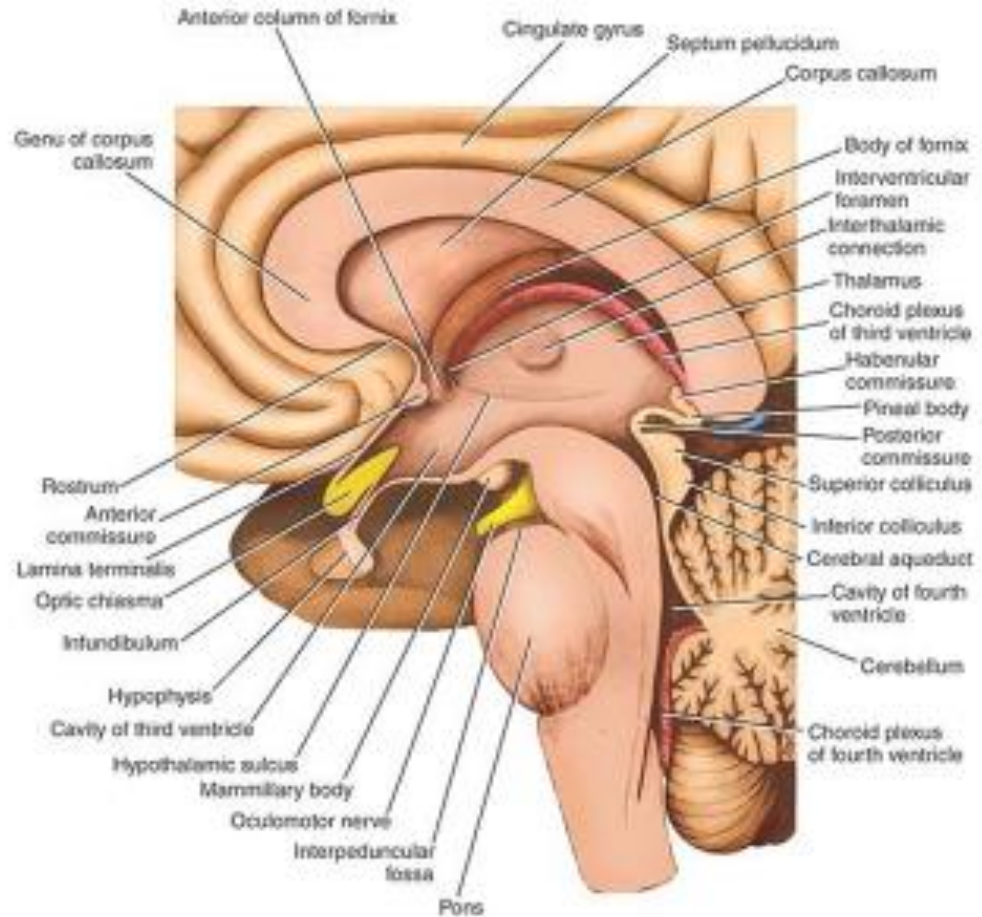


- **Relations**
- Above: the thalamus.
- Below: the hypothalamus merges into the tegmentum of the midbrain.
- Laterally: the internal capsule



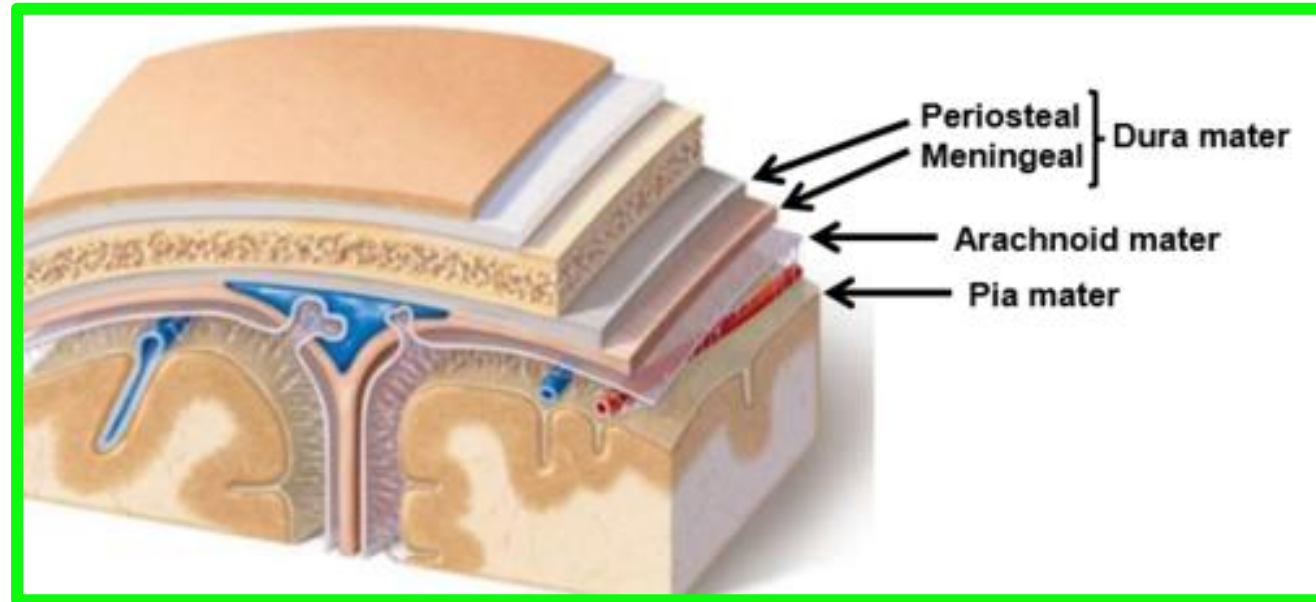
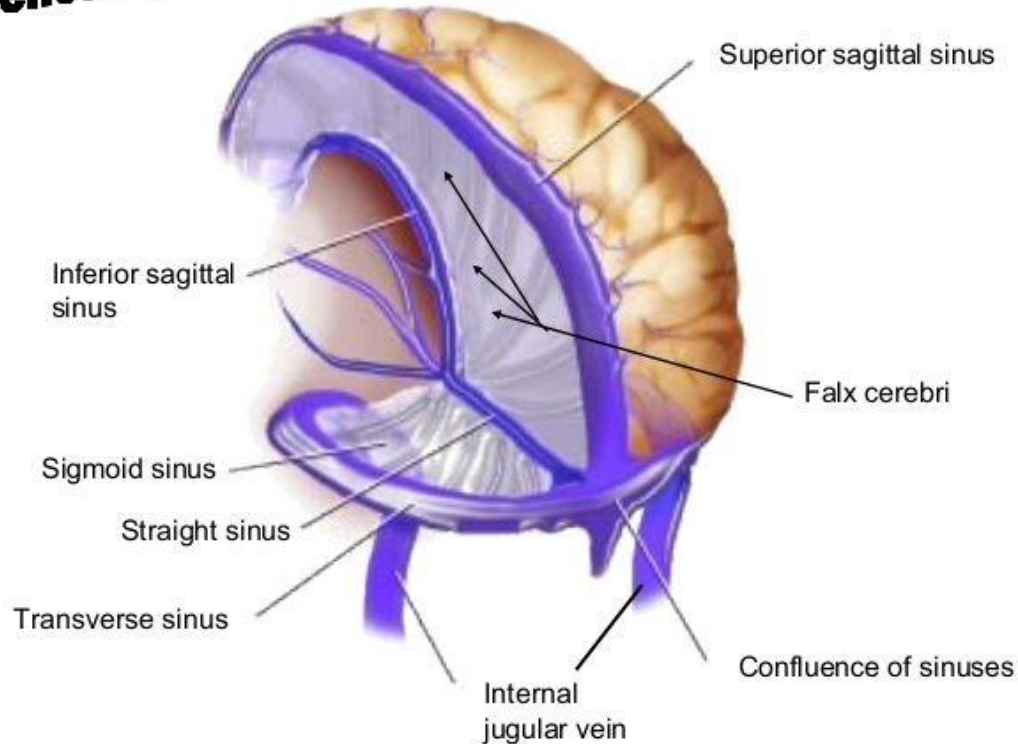
Position & Relations

- The hypothalamus extends from the lamina terminalis to a vertical plane caudal to the mammillary bodies, and from the hypothalamic sulcus to include the structures in the ventral side wall and floor of the 3rd ventricle; i.e., it includes the contents of the interpeduncular fossa, and thus the hypothalamus consists of:
- The optic chiasma region.
- The tuber cinereum with its eminence and the stalk of the pituitary gland.
- The mammillary bodies.
- The posterior perforated substance (not usually included in the hypothalamus).



- ❖ The dura mater of the brain is conventionally described as **two layers**: the **endosteal layer** and the **meningeal layer**
- ❖ These are closely united except along certain lines, where they separate to form **venous sinuses**.

venous sinuses



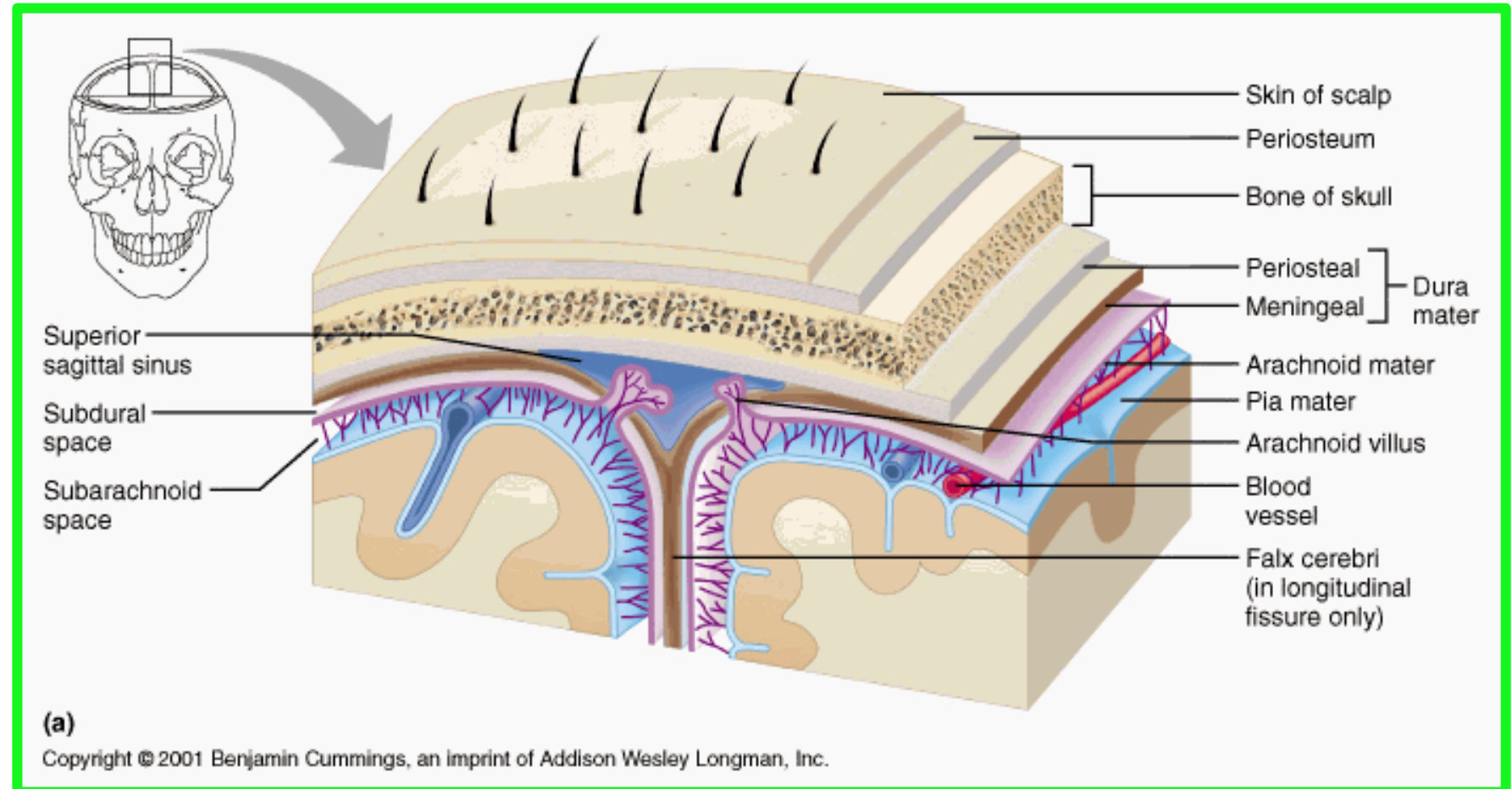
Dura Mater

□ The meningeal layer

- ❖ is the **dura mater proper**. It is a **dense, strong fibrous membrane** covering the brain
- ❖ is continuous through the foramen magnum with the dura mater of the spinal cord.

❖ It provides **tubular sheaths for the cranial nerves** as the latter pass through the foramina in the skull.

❖ Outside the skull, the sheaths fuse with the **epineurium of the nerves**

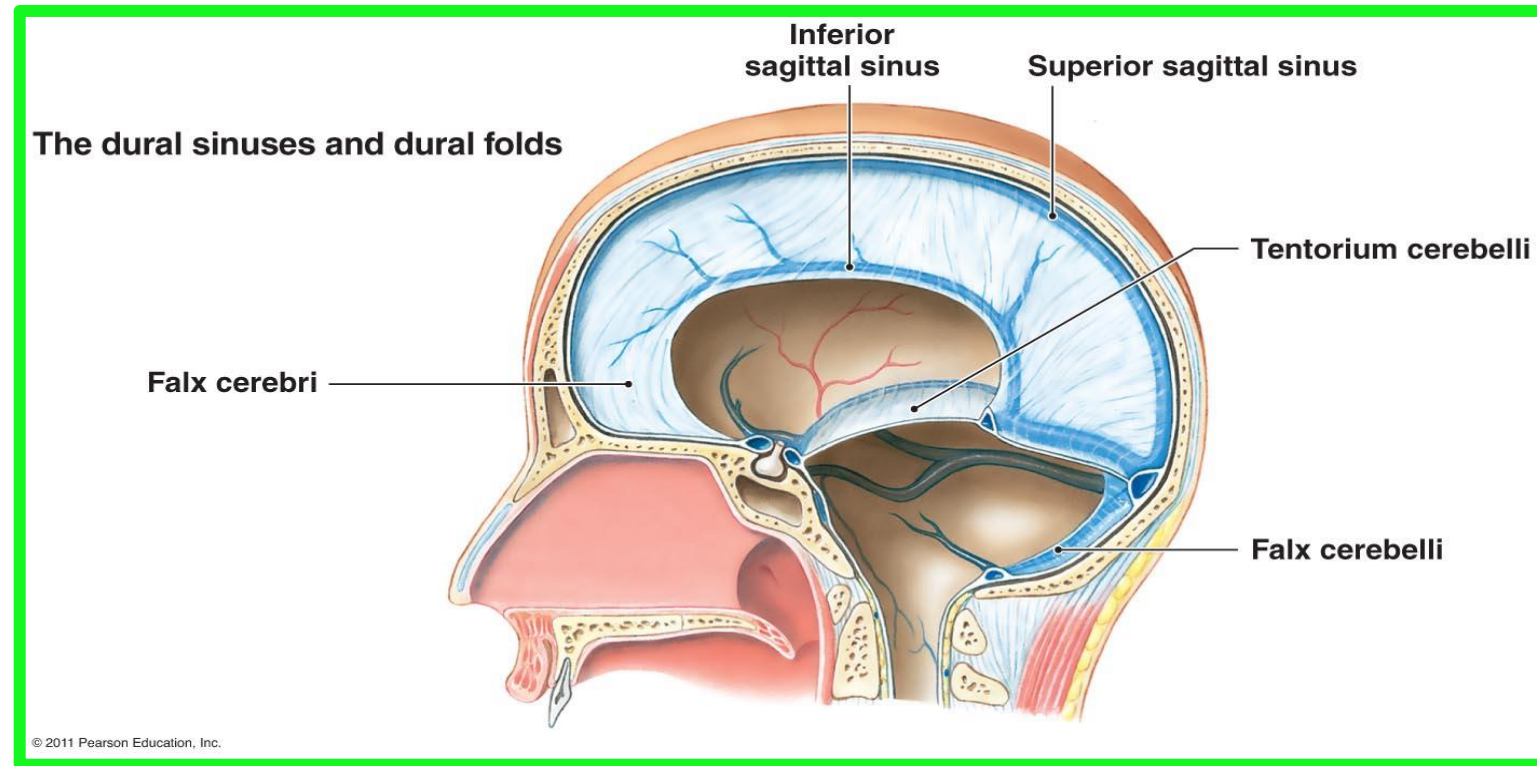


❑ 1. The falx cerebri is a **sickle-shaped fold of dura mater** that lies in the midline between the **two cerebral hemispheres**

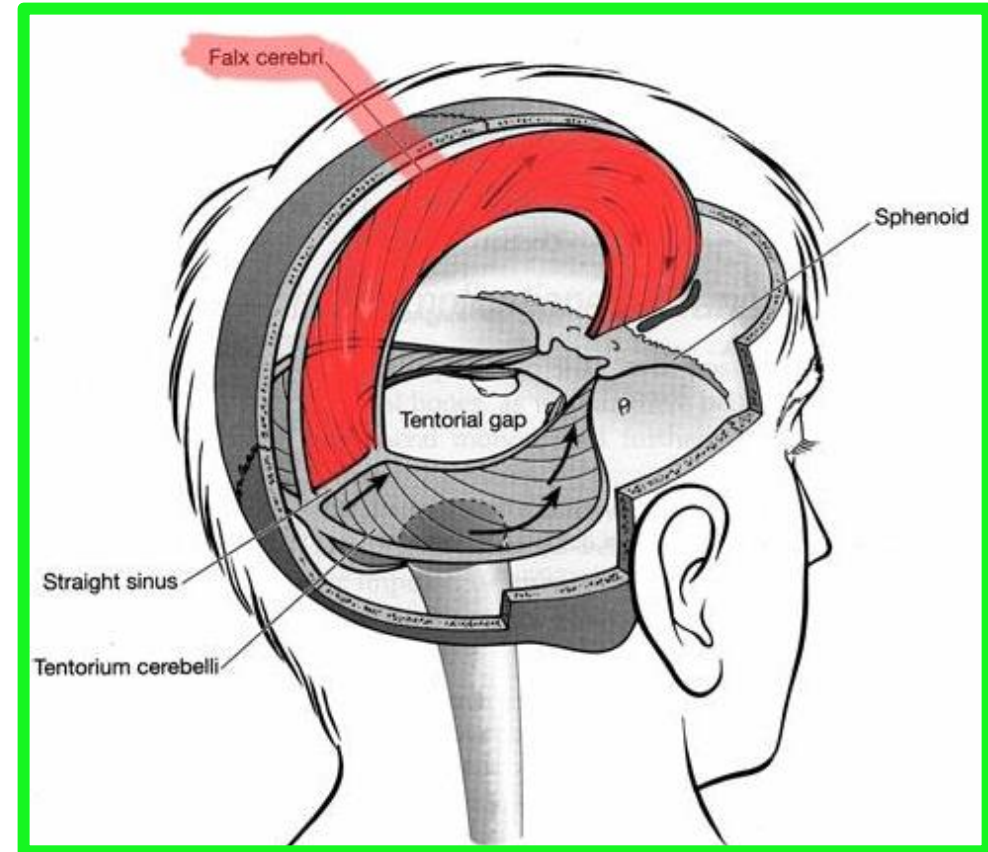
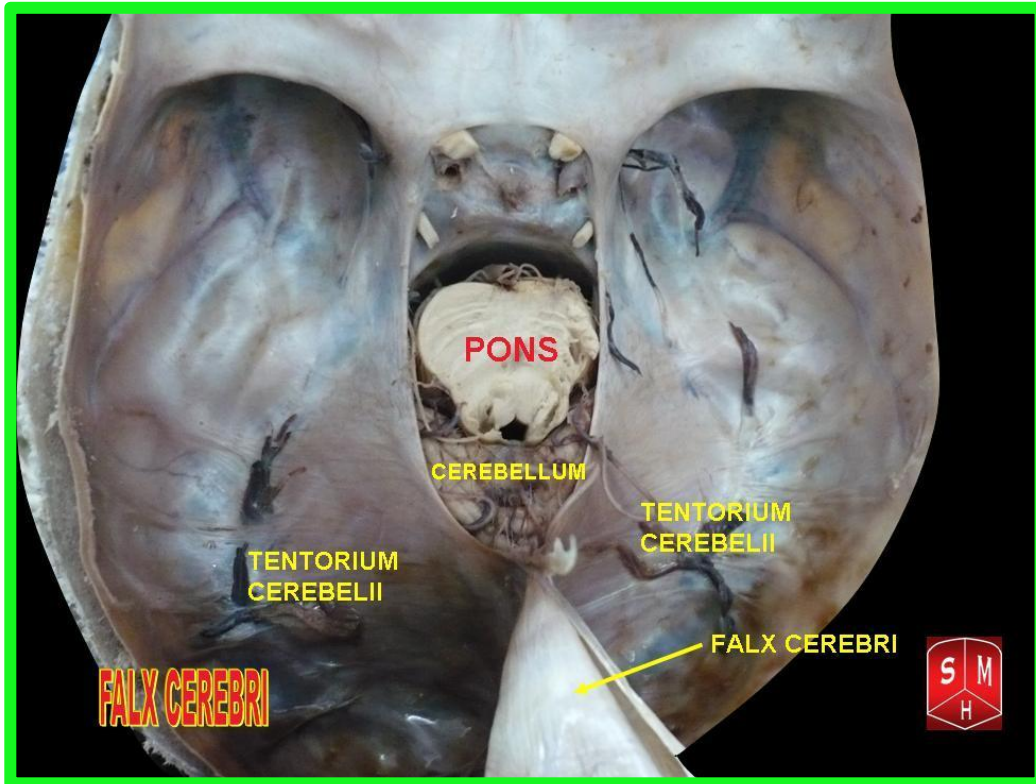
✓ Its narrow anterior end is attached to the **internal frontal crest** and the **crista galli**.

✓ Its broad posterior part blends in the midline with the **upper surface of the tentorium cerebelli**.

✓ The **superior sagittal sinus** runs in its upper fixed margin, the **inferior sagittal sinus** runs in its lower concave free margin, and the **straight sinus** runs along its attachment to the **tentorium cerebelli**



- **2. The tentorium cerebelli** is a **crescent-shaped fold of dura mater** that roofs over the posterior cranial fossa
- It covers the **upper surface of the cerebellum** and **supports the occipital lobes of the cerebral hemispheres.**

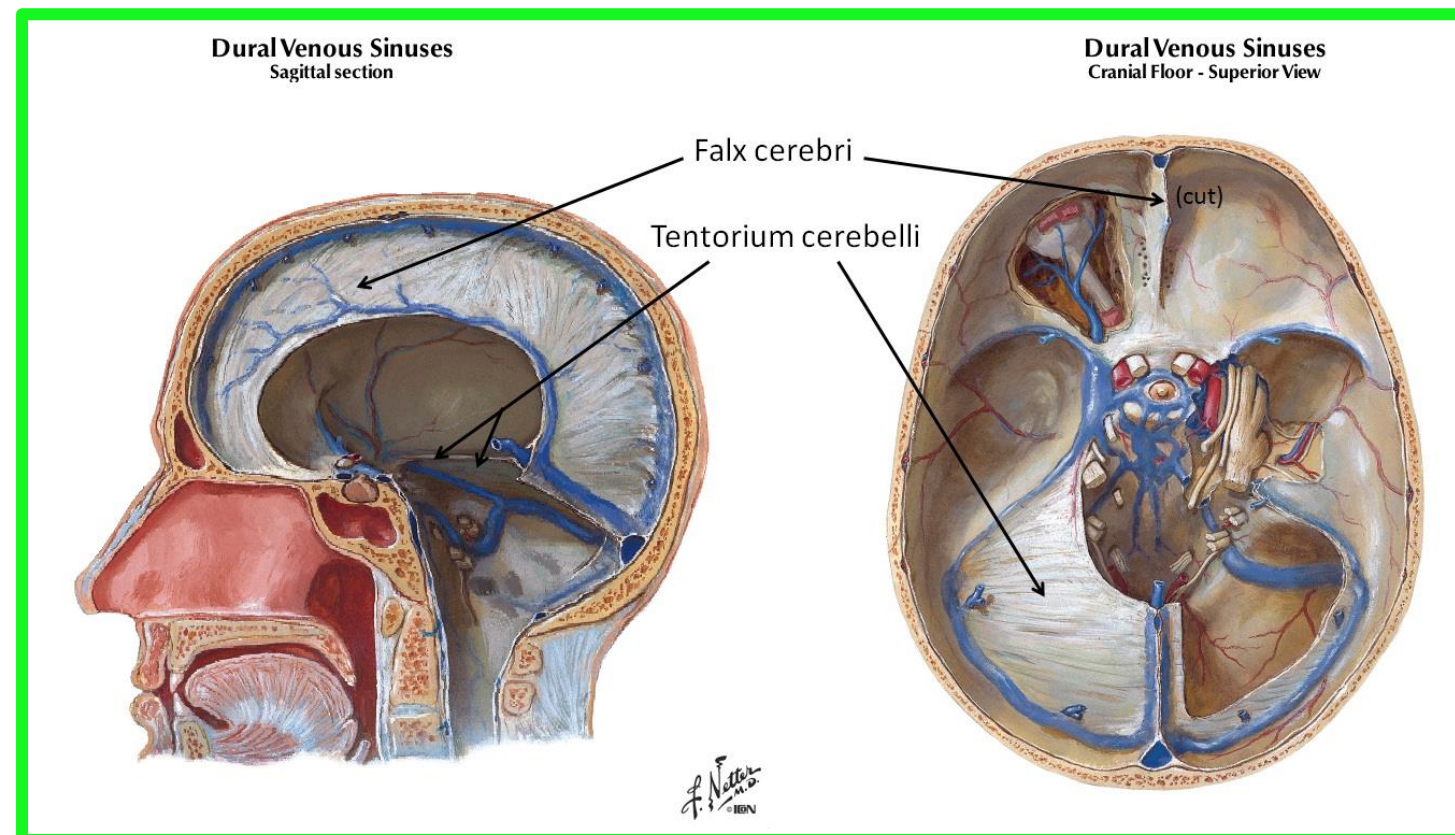
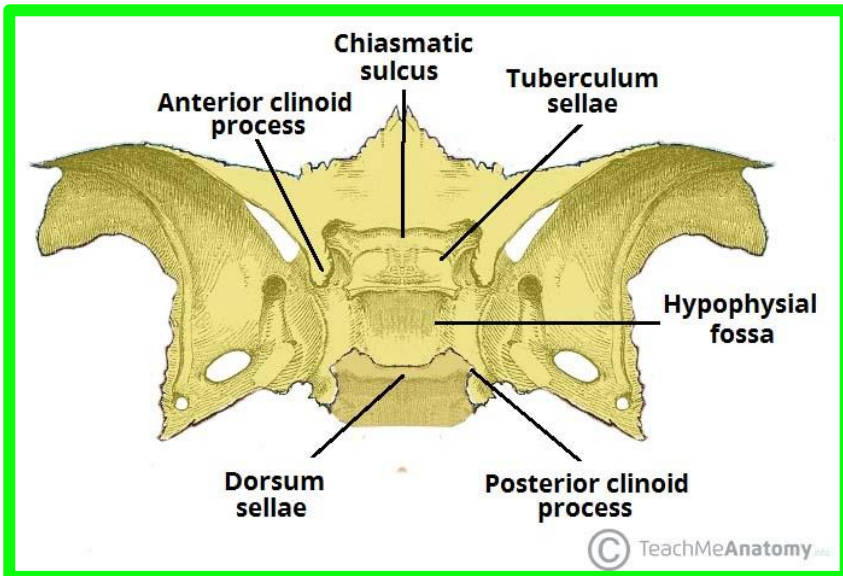


- In the anterior edge **there is a gap, the tentorial notch**, for the passage of **the midbrain** which produces an **inner free border** and an **outer attached or fixed border.**

❑ The **fixed border** is attached to **the posterior clinoid processes**, the superior borders of the petrous bones, and **the margins of the grooves for the transverse sinuses on the occipital bone**.

❑ The **free border** runs forward at its two ends, crosses the attached border, and is affixed to **the anterior clinoid process** on each side.

✓ At the point where the two borders cross, the **third and fourth cranial nerves** pass forward to enter the lateral wall of **the cavernous sinus**

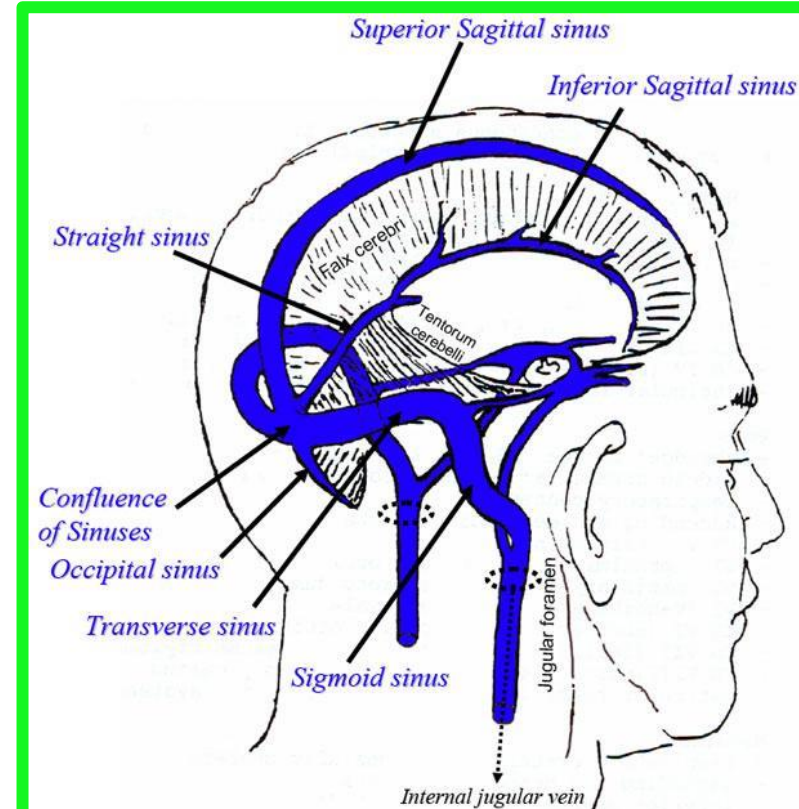
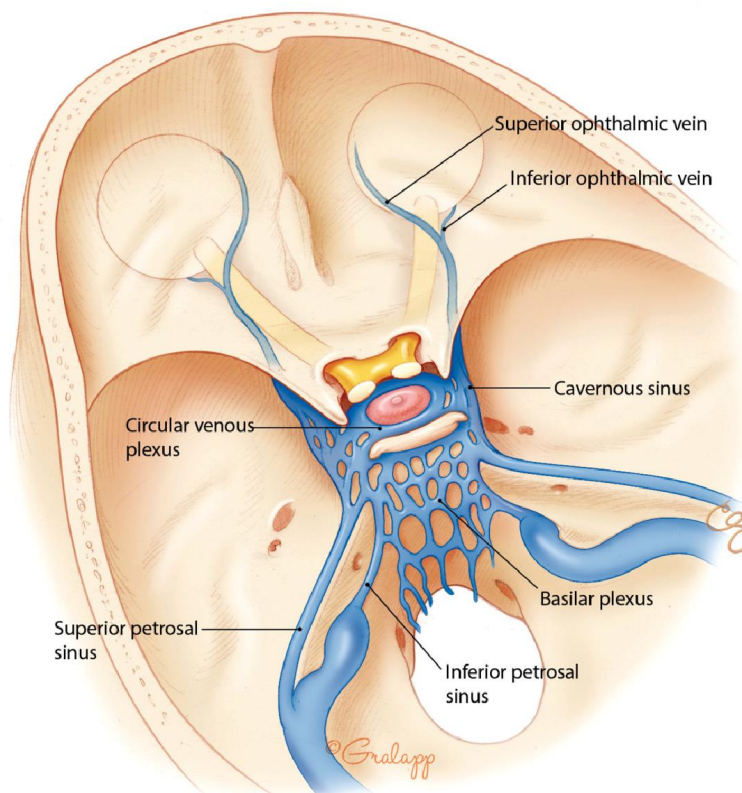
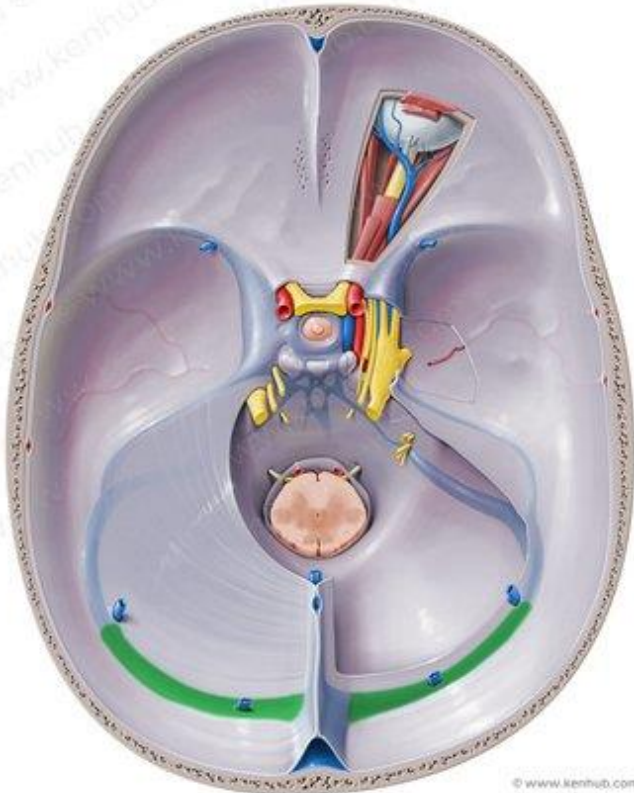


The **falx cerebri** and the **falx cerebelli** are attached to the upper and lower surfaces of the **tentorium**, respectively.

The **straight sinus** runs along its attachment to the **falx cerebri**,

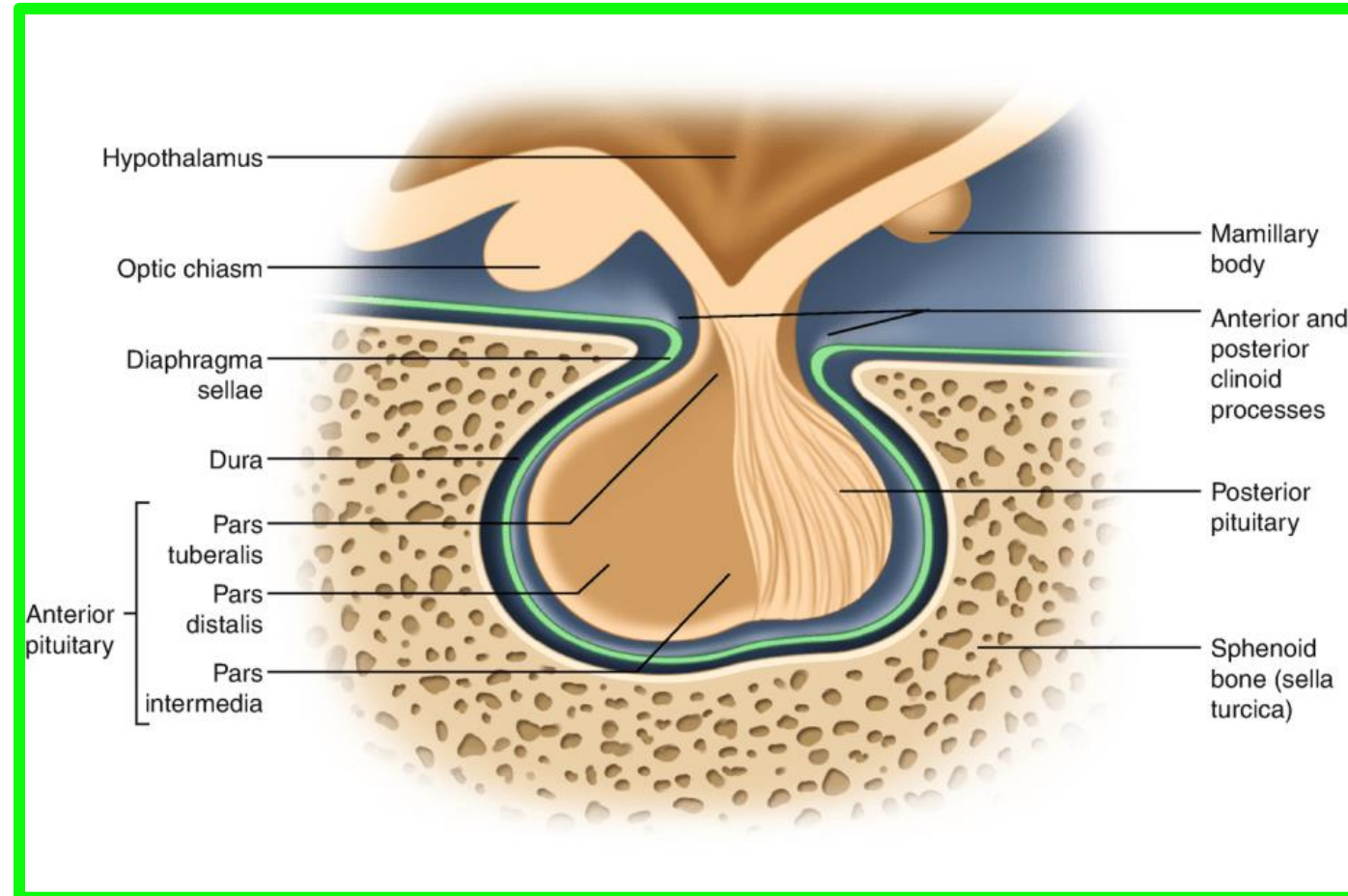
The **superior petrosal sinus** runs along its attachment to the **petrous bone**, and

The **transverse sinus** runs along its attachment to the **occipital bone**



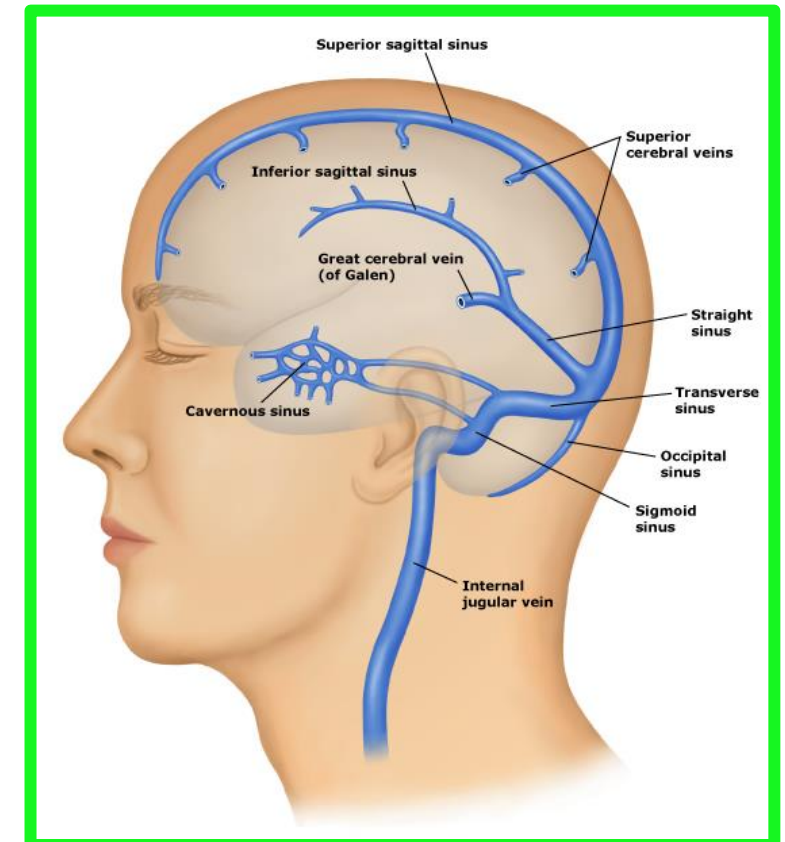
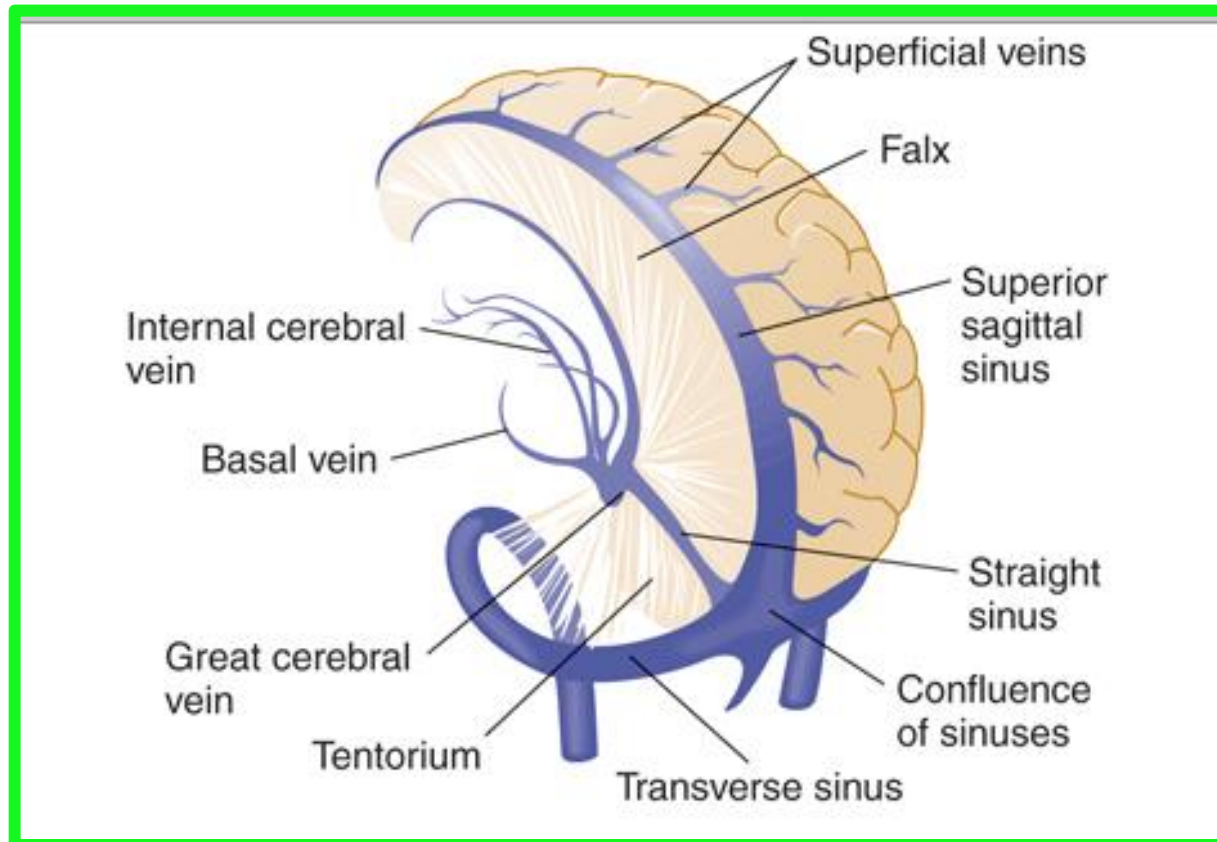
□4. The diaphragma sellae is a **small, circular fold of dura mater** that forms the roof for the sella turcica

A small opening in its center allows passage of the stalk of the **hypophysis cerebri**



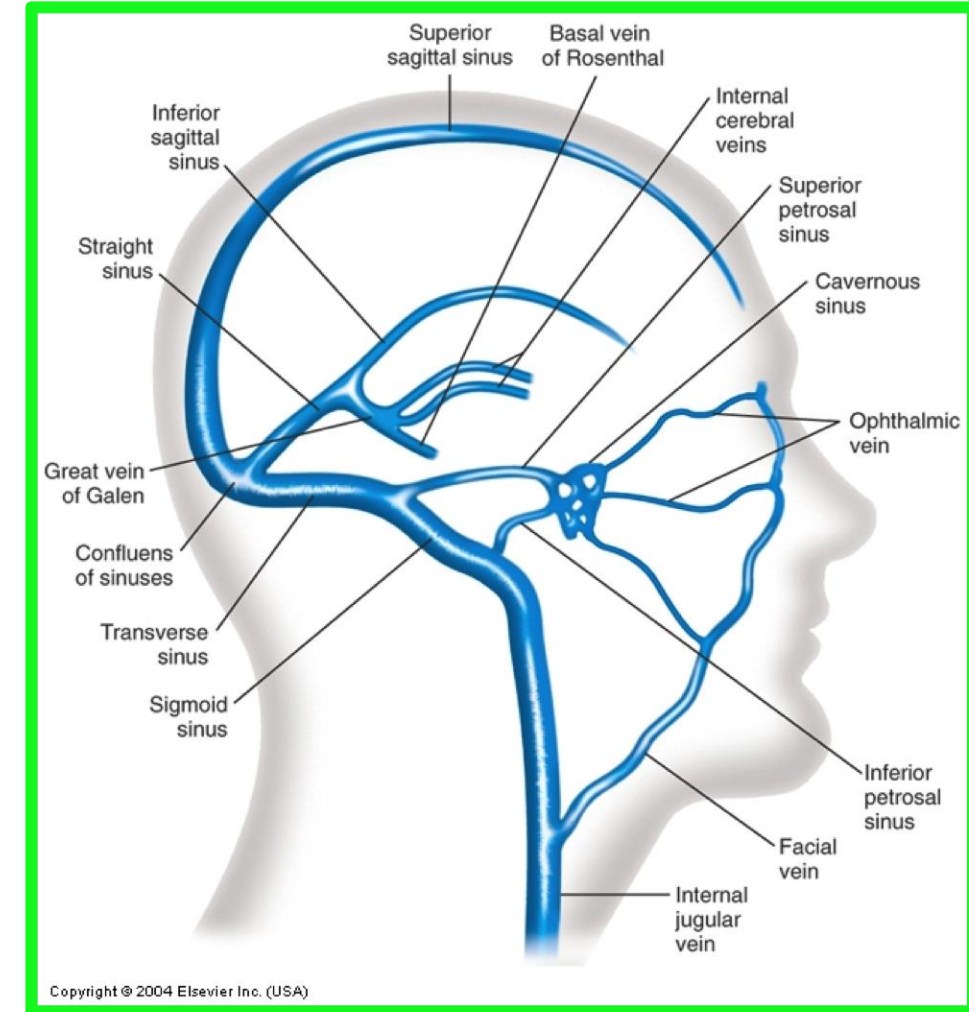
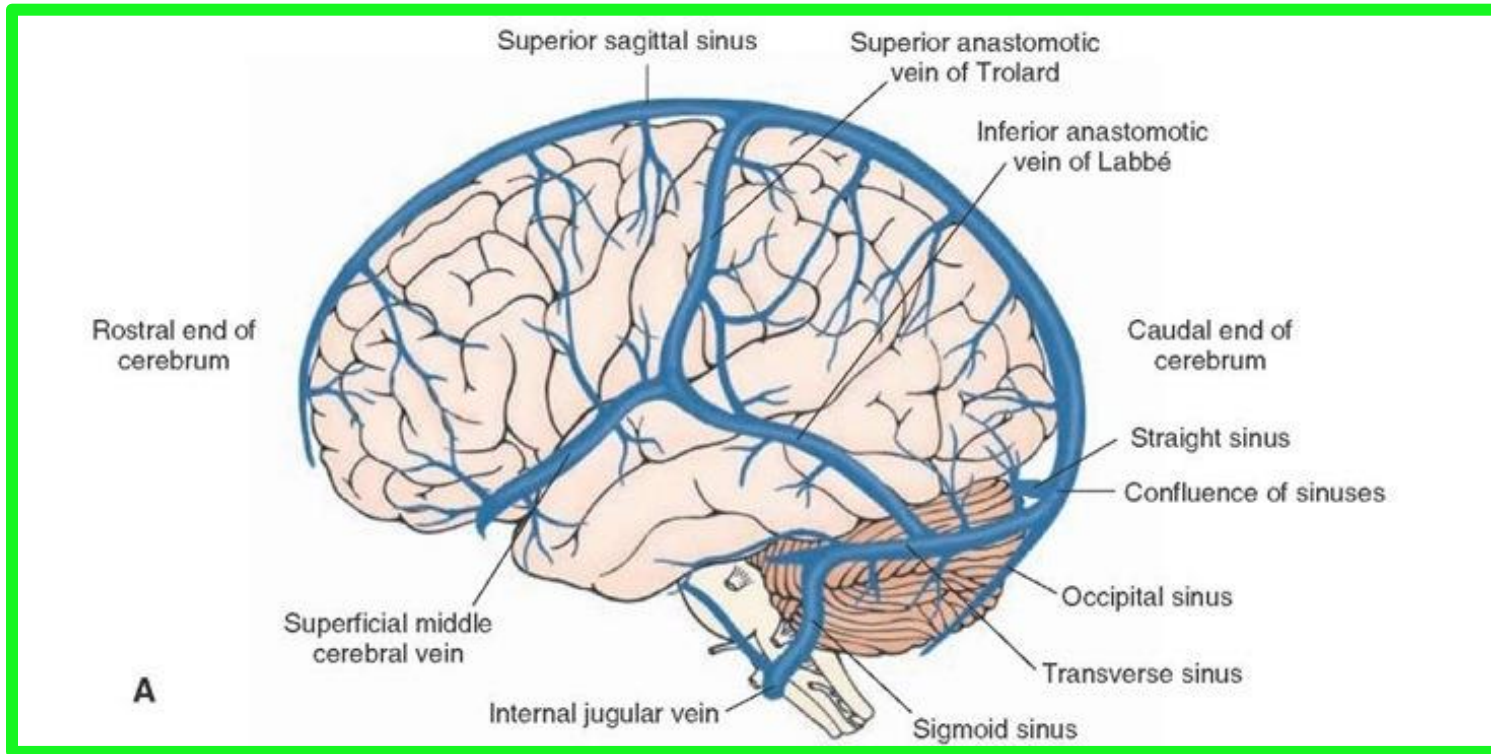
Dural Venous Sinuses

- ✓ The venous sinuses of the cranial cavity are situated **between the layers of the dura mater**
- ✓ Their main function is to receive blood from the brain through **the cerebral veins** and **the cerebrospinal fluid** from **the subarachnoid space** through the **arachnoid villi**
- ✓ The blood in the dural sinuses ultimately drains into the internal jugular veins in the neck.



Dural Venous Sinuses

The transverse sinuses receive the superior petrosal sinuses, the inferior cerebral and cerebellar veins, and the diploic veins. They end by turning downward as the sigmoid sinuses

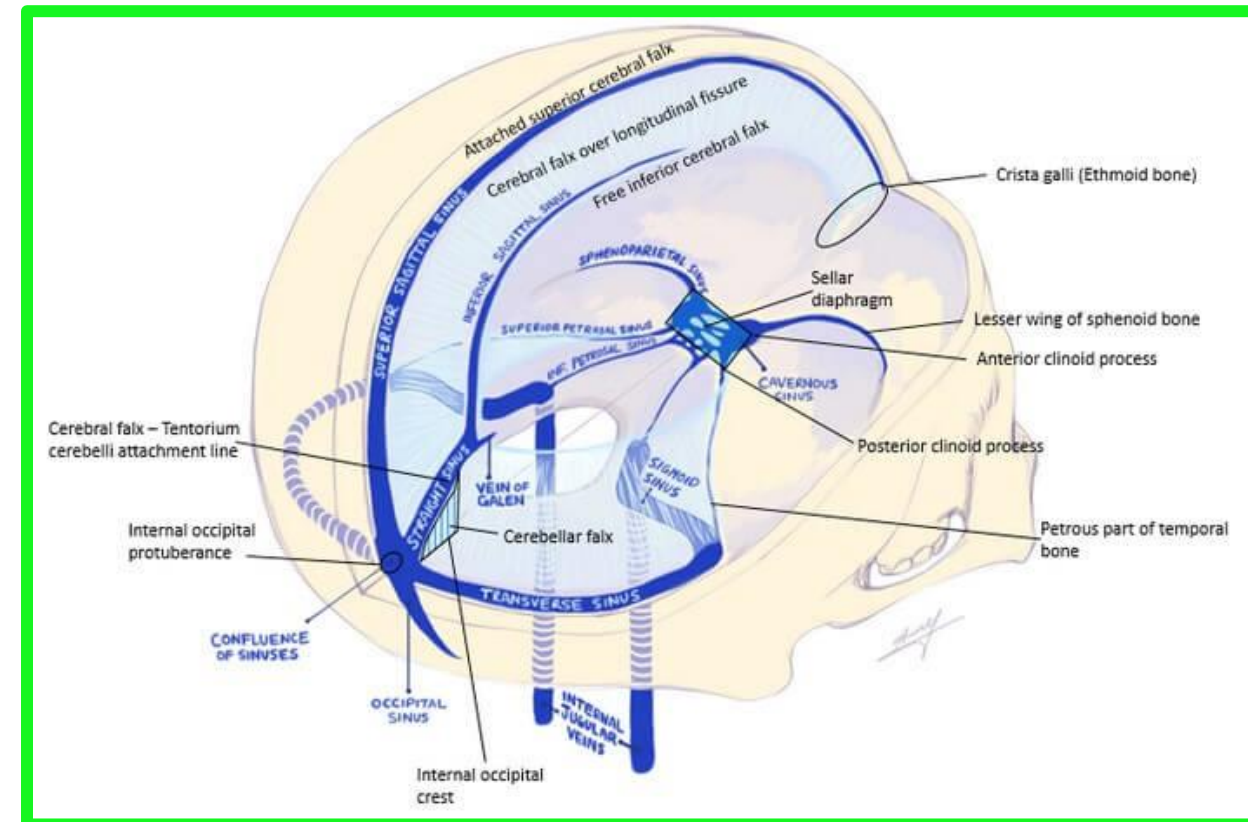
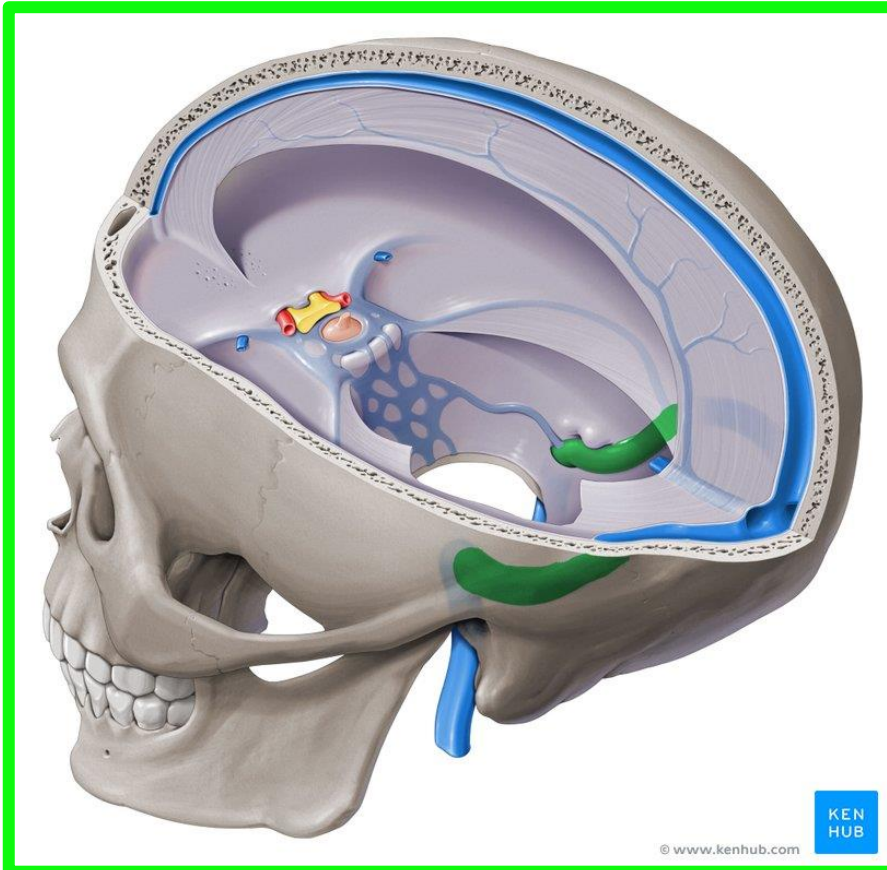


Dural Venous Sinuses

21

Dr. Aiman Qais Afar
Tuesday 27 December 2022

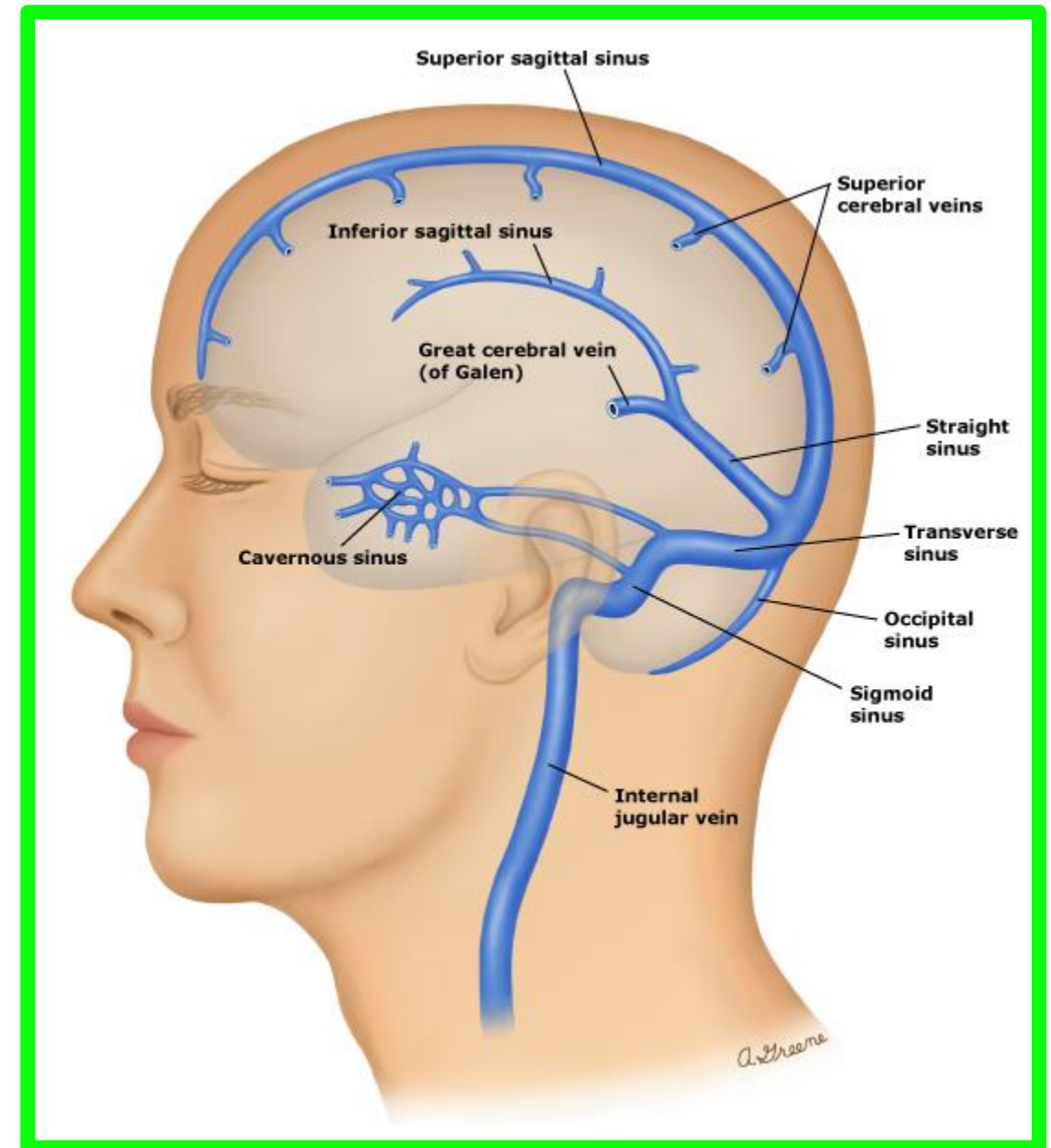
- ❑ The sigmoid sinuses are a direct continuation of the transverse sinuses.
- ✓ Each sinus turns **downward and medially** and grooves **the mastoid part of the temporal bone**
- ✓ The sinus then turns **forward** and then **inferiorly** through the posterior part of the **jugular foramen** to become continuous with the **superior bulb of the internal jugular vein**.



Dural Venous Sinuses

The **occipital sinus** is a small sinus occupying the **attached margin of the falx cerebelli**.

It commences near **the foramen magnum**, where it communicates with **the vertebral veins** and drains **into the confluence of sinuses**

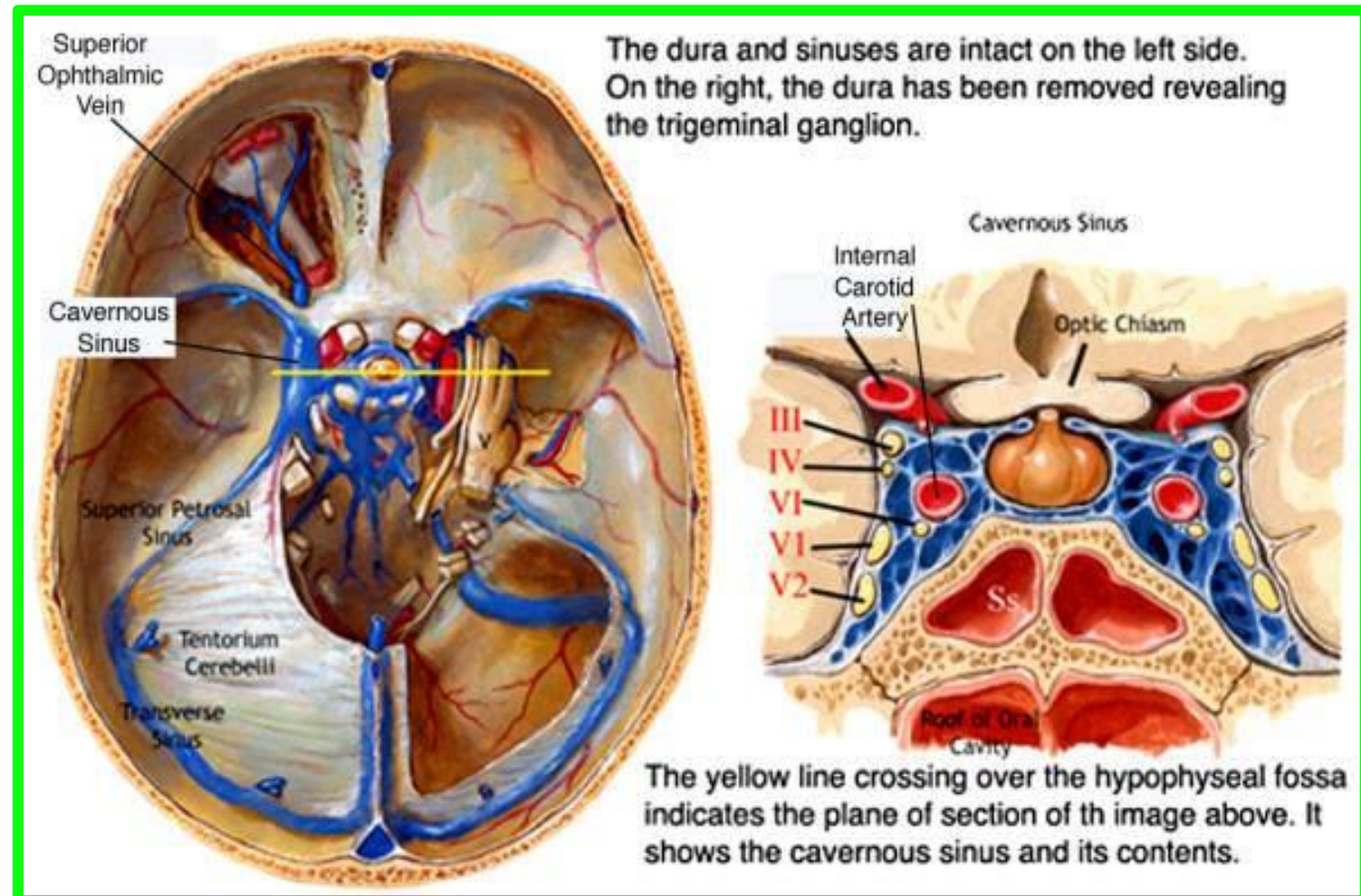


Dural Venous Sinuses

□ The cavernous sinuses are situated **in the middle cranial fossa** on each side of the body of the sphenoid bone

❖ Numerous trabeculae cross their interior, giving them a spongy appearance, hence the name.

❖ Each sinus extends from **the superior orbital fissure** in front to **the apex of the petrous part of the temporal bone** behind.



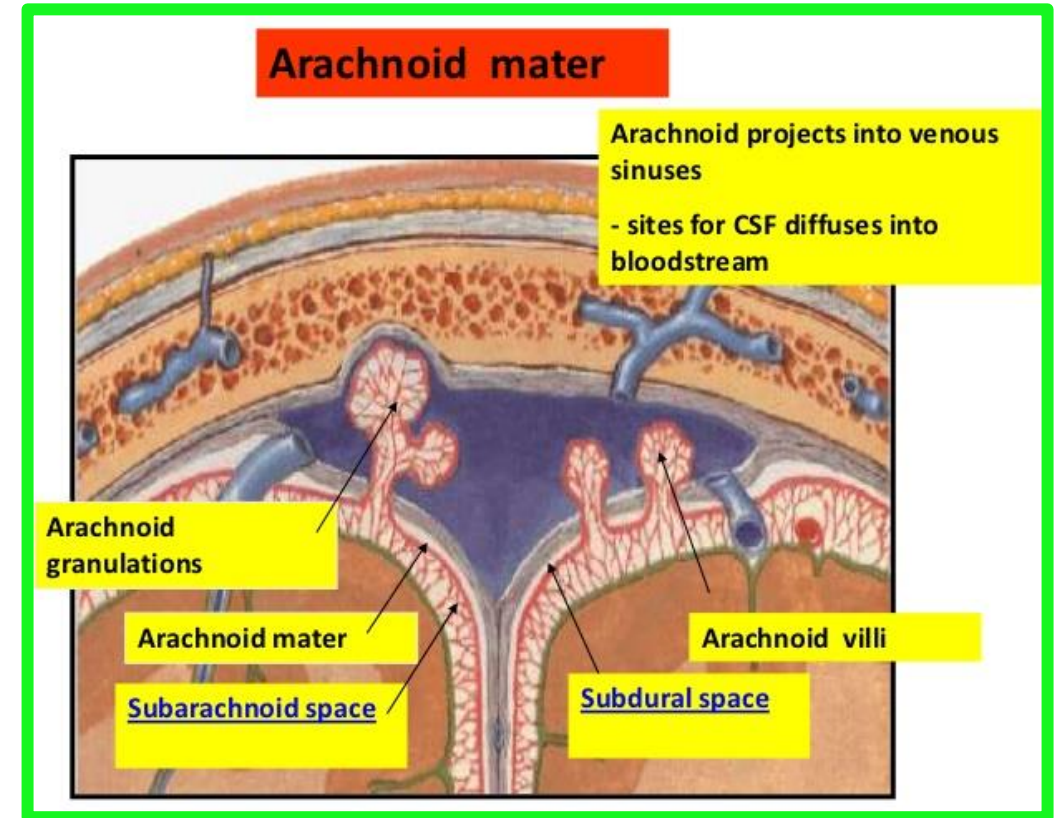
Arachnoid Mater

In certain areas, the arachnoid projects into **the venous sinuses** to form **arachnoid villi**.

The **arachnoid villi** are most numerous along **the superior sagittal sinus**.

Aggregations of arachnoid villi are referred to as **arachnoid granulations**

Arachnoid villi serve as sites where the cerebrospinal fluid diffuses into the bloodstream.

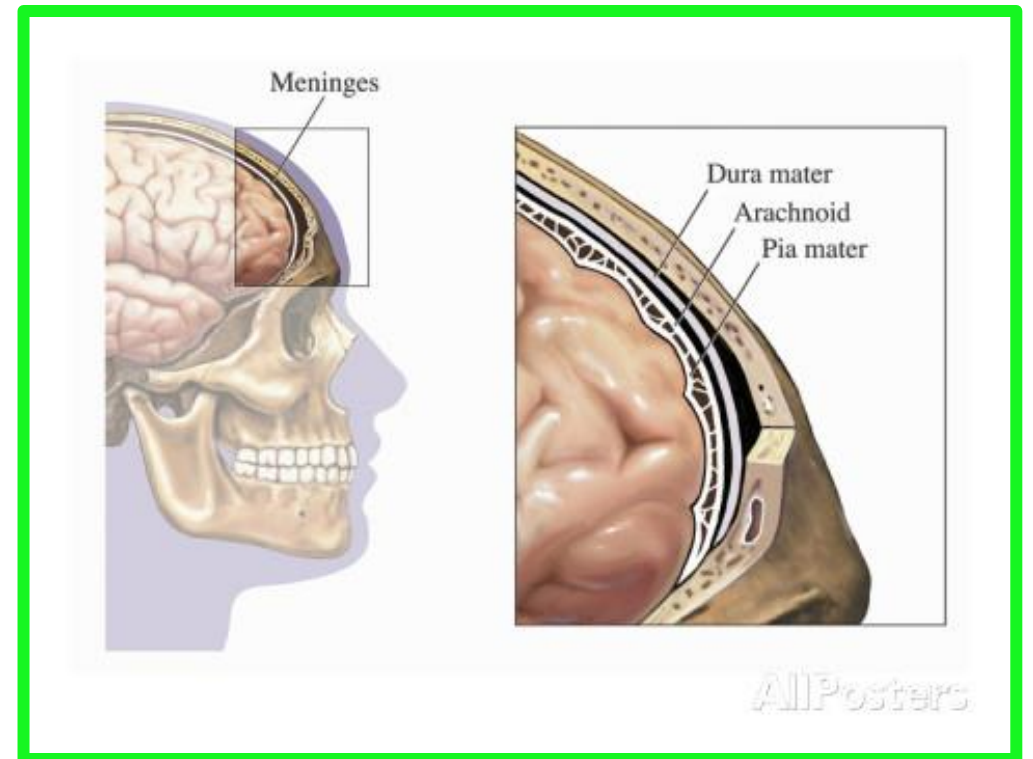
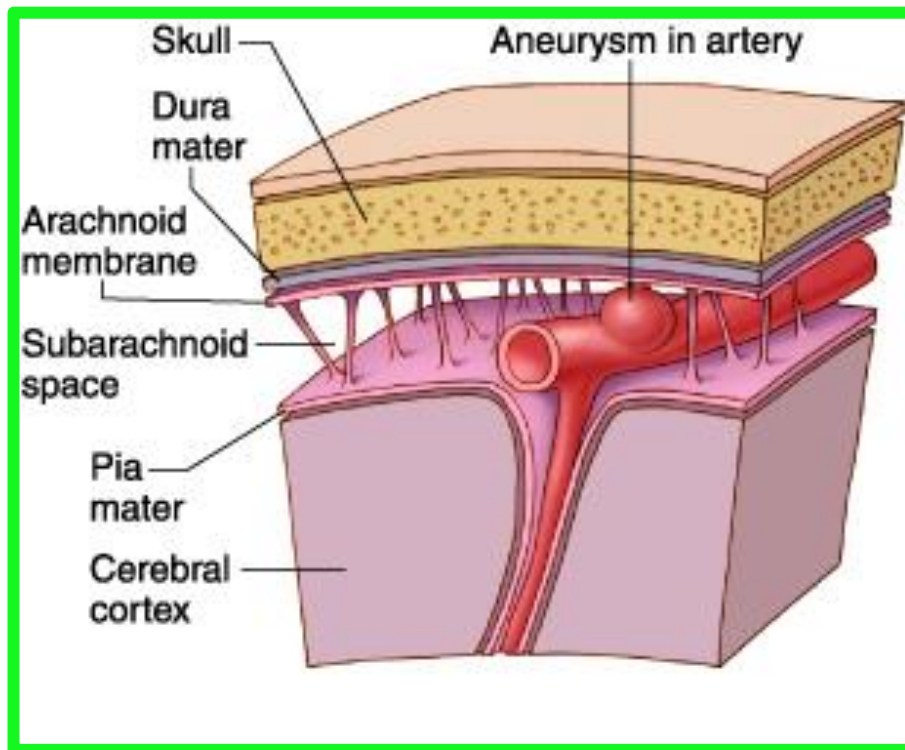


The arachnoid is connected to the pia mater across the fluid-filled **subarachnoid space** by **delicate strands of fibrous tissue**.

Pia Mater

The pia mater **is a vascular membrane** covered by flattened mesothelial cells. It closely invests the brain, covering the gyri and descending into the deepest sulci

It extends out over the cranial nerves and fuses with their epineurium. **The cerebral arteries entering the substance of the brain carry a sheath of pia with them.**



LATERAL VENTRICLE

Def.: cavity of cerebral hemisphere. It is lined by ependyma

Communication:

with 3rd ventricle by the interventricular foramen of Monro

shape & part: C- shape has

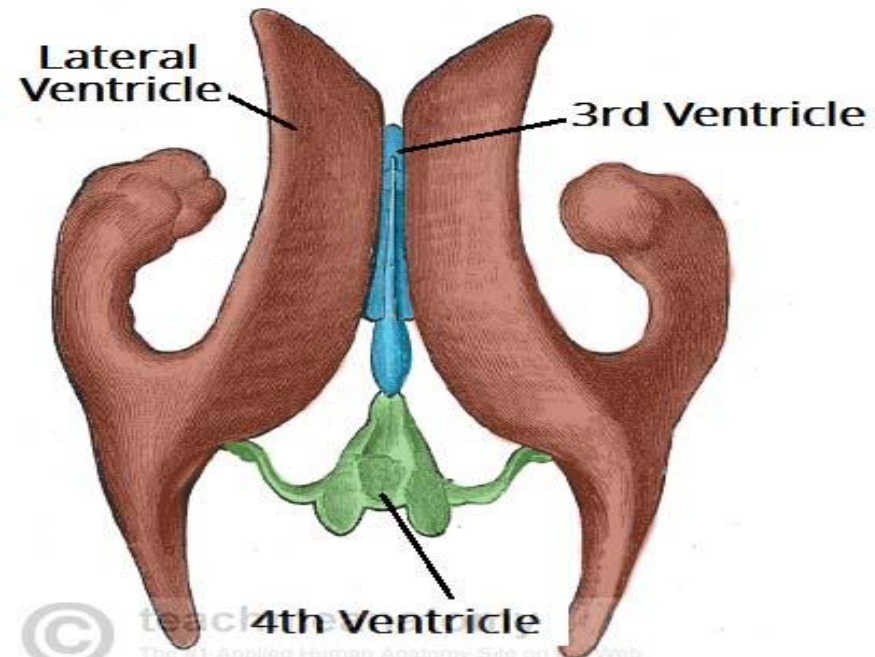
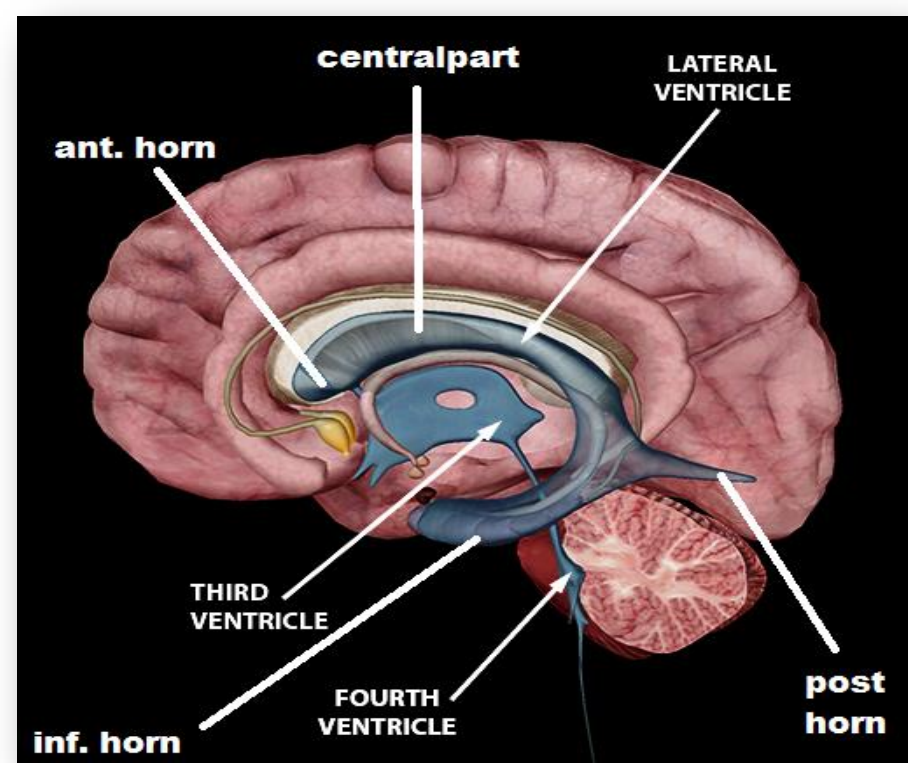
ant. horn :-cavity of frontal lobe

extends from interventricular foramen forward to genu of CC

central part(body):cavity of parietal lobe. extends from interventricular foramen to splenium

post. horn: cavity of occipital lobe extends from splenium backward into occipital lobe

Infer. horn:-cavity of temporal lobe extends from splenium, downward behind thalamus then forward in temporal lobe to end at uncus.

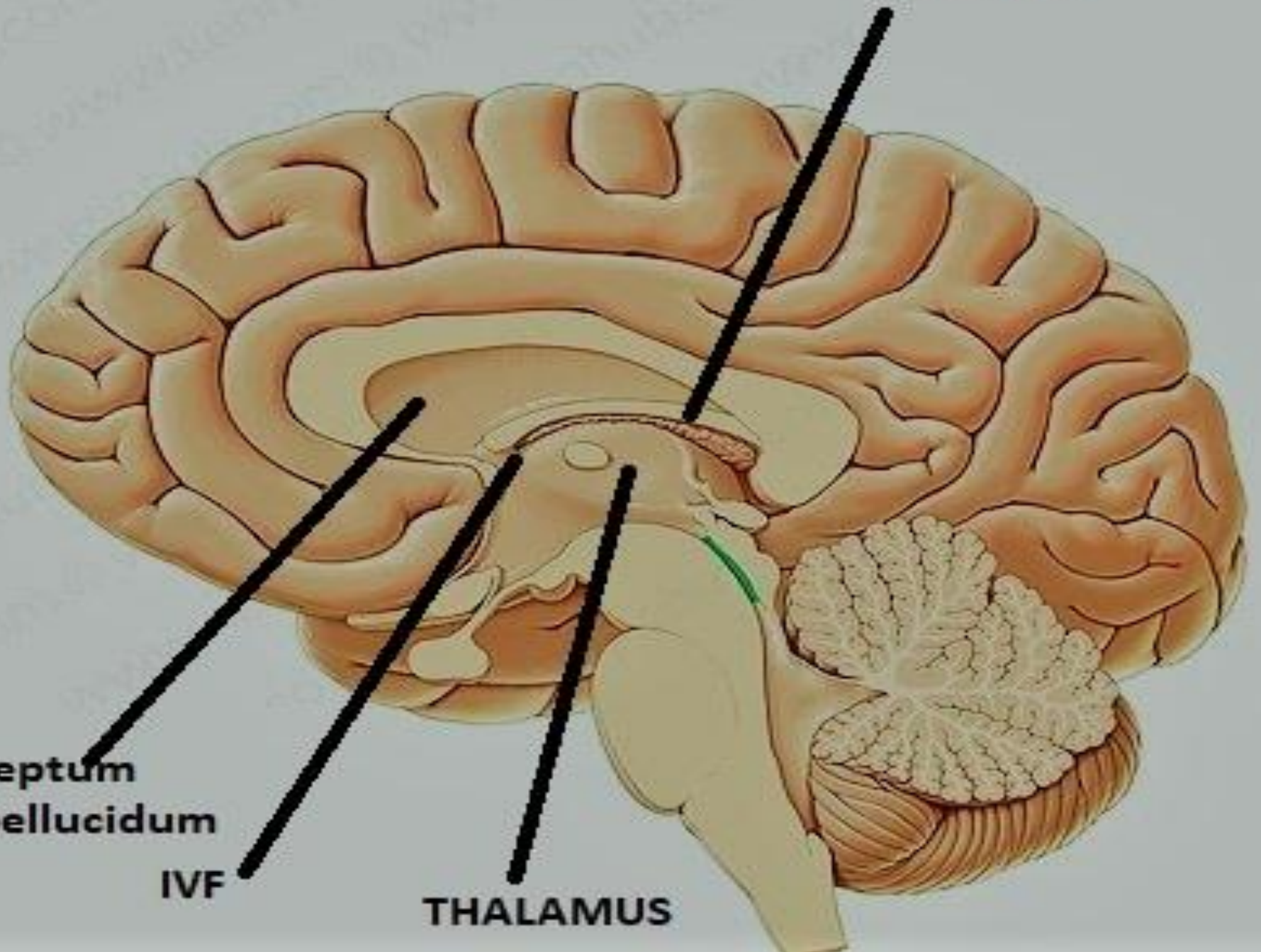


FORNIX

**septum
pellucidum**

IVF

THALAMUS



LATERAL VENTRICLE

boundaries, walls:

ant. horn: in ant. coronal section, it appear triangular

roof: trunk of corpus callosum

medial wall: septum pellucidum

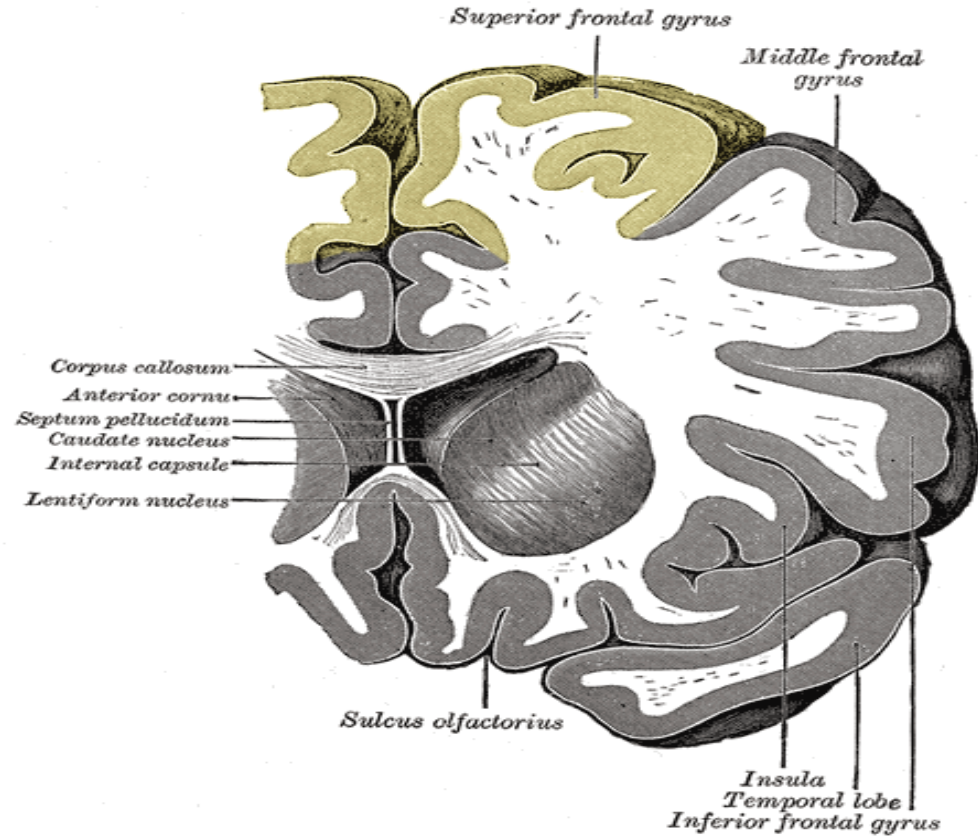
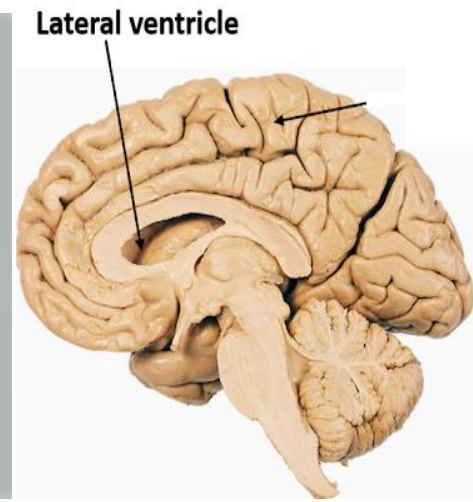
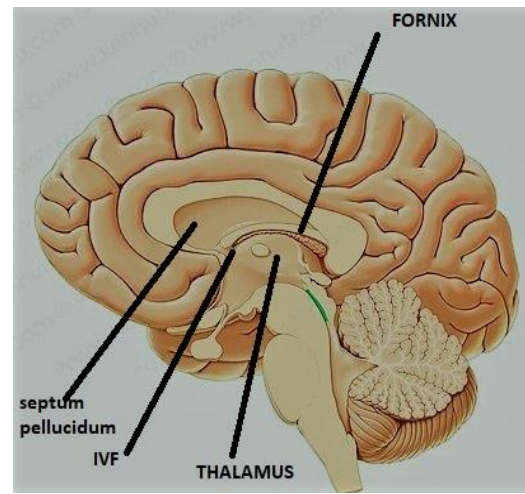
inferolateral wall:

head of caudate

rostrum of corpus callosum.

ant. end: genu of corpus callosum.

N.B: identified by: U shaped mass of striatum.



LATERAL VENTRICLE

boundaries, walls:

Central part: in middle coronal section, it appear triangular

roof: trunk of corpus callosum.

medial w:

septum pellucidum (above)

body of fornix. (below)

Floor :body of caudate

stria terminalis(medial to caudate)

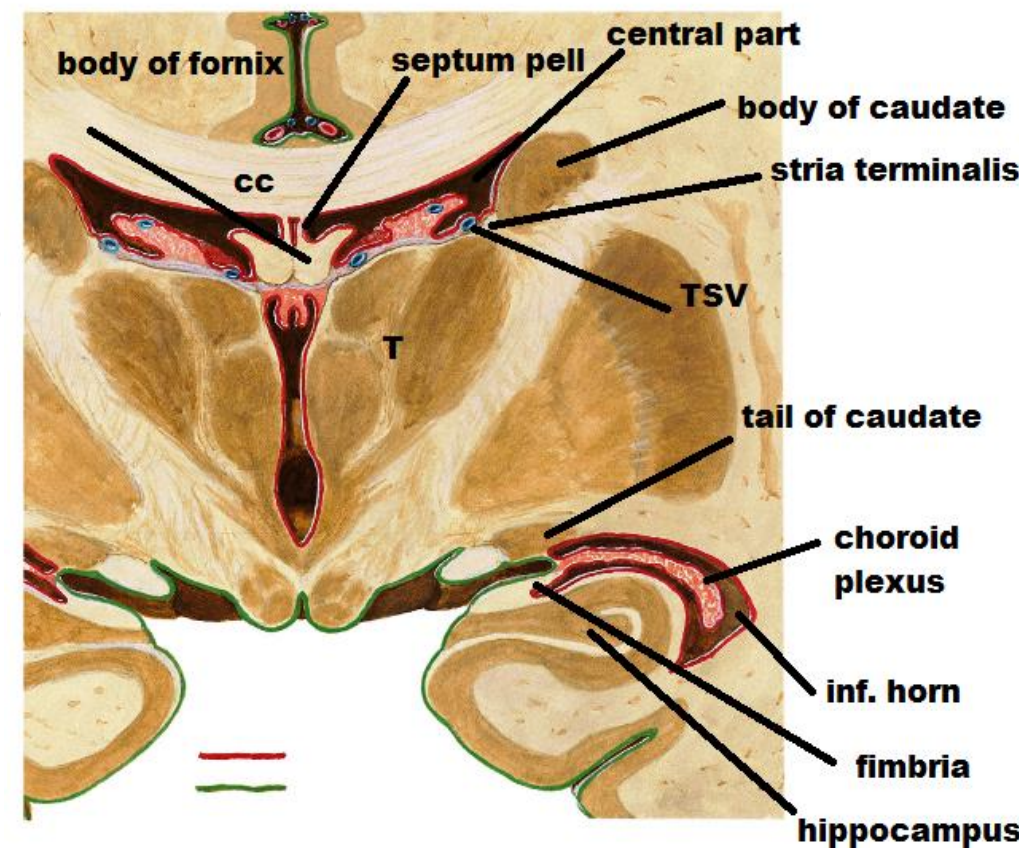
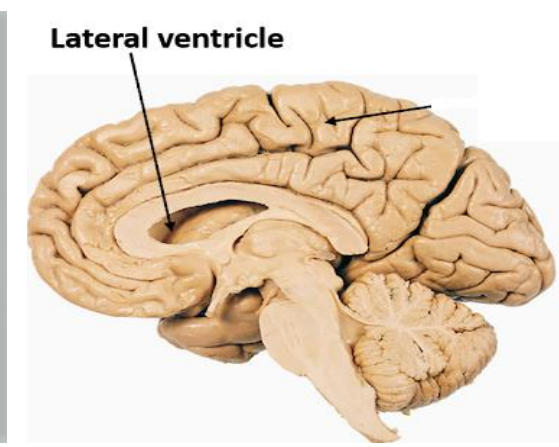
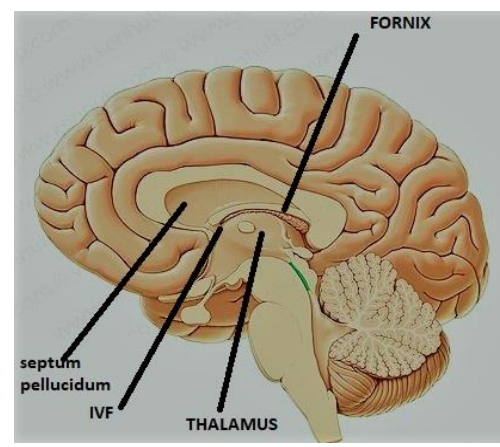
thalamo striate v.

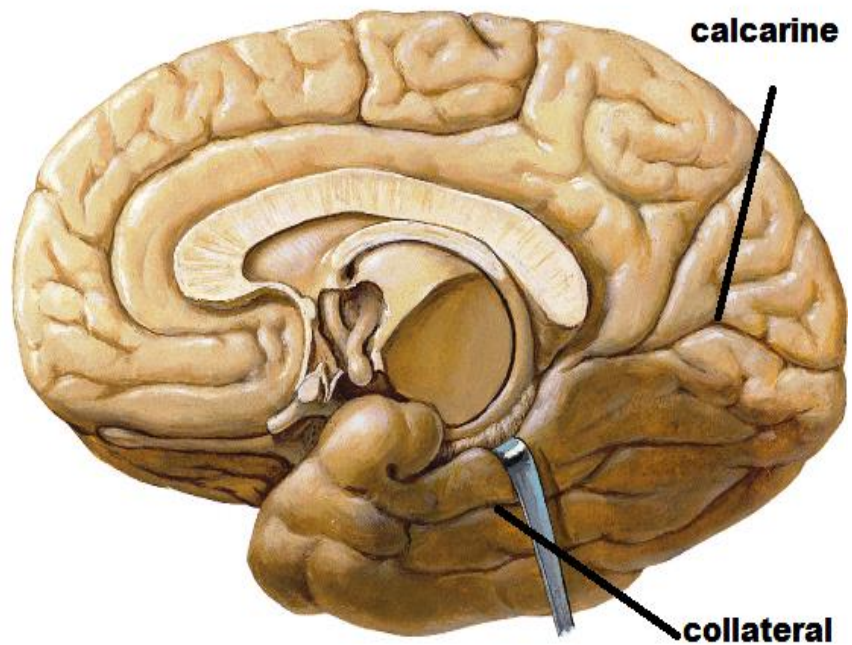
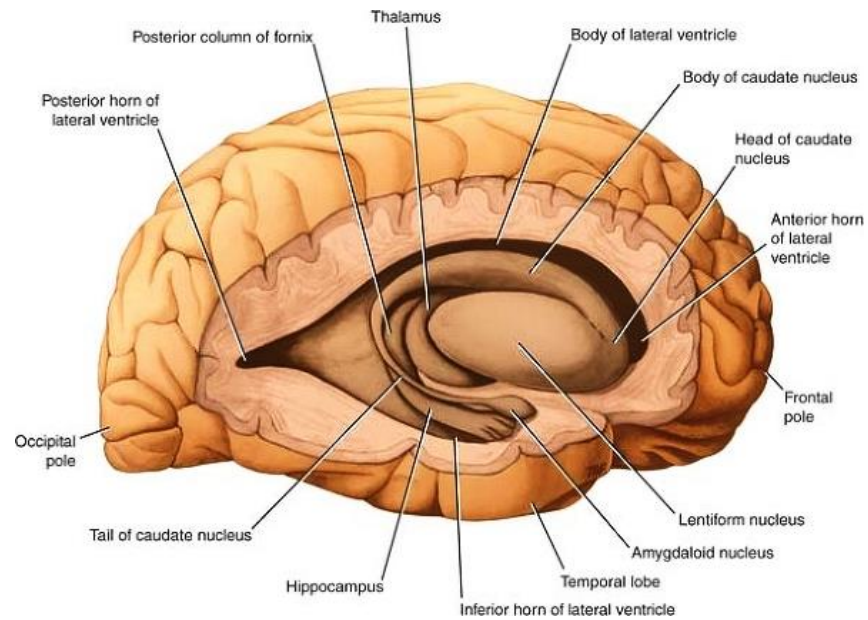
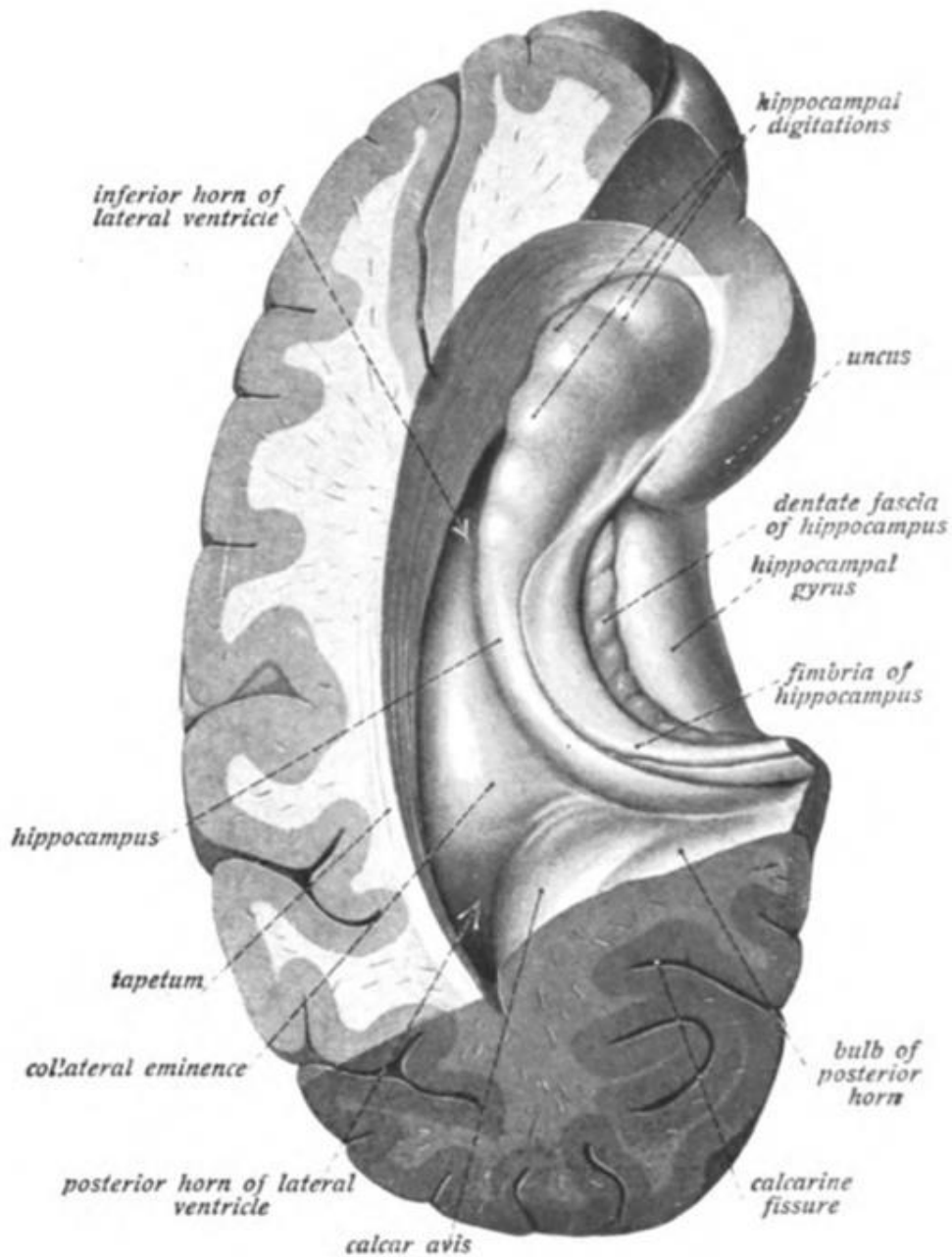
thalamus

choroid plexus in choroid fissure

() fornix & thalamus

N.B: identified by: thalamus





LATERAL VENTRICLE

boundaries, walls:

inferior horn:

Roof stria terminalis

tail of caudate

lateral w: tapetum of trunk of CC

Floor

collateral eminence produced

by collateral sulcus

hippocampal gyrus

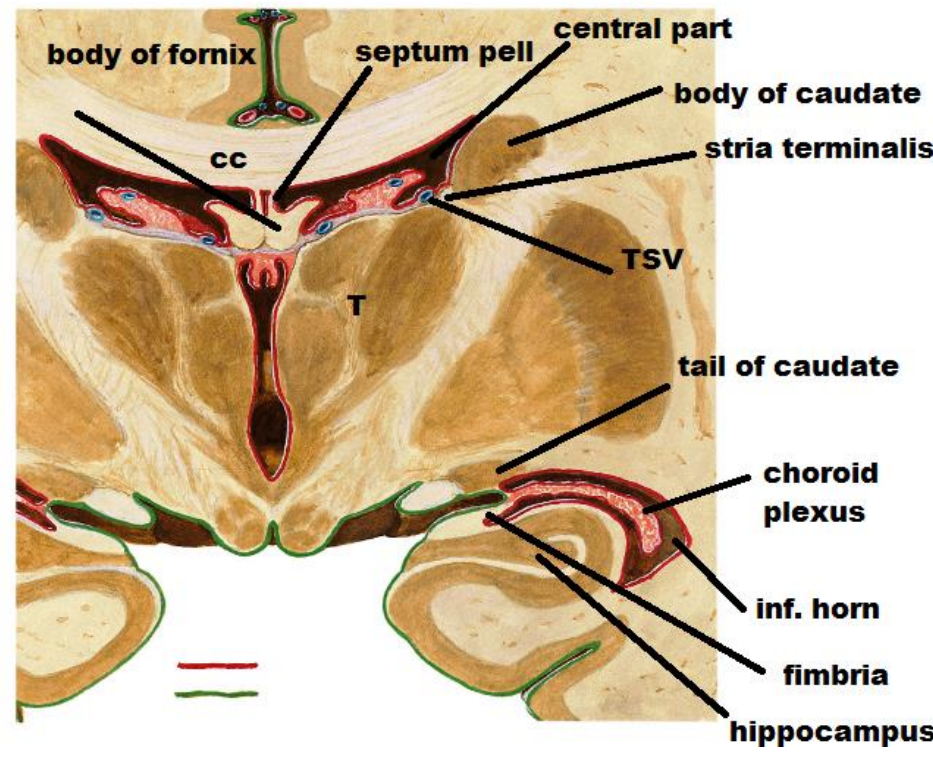
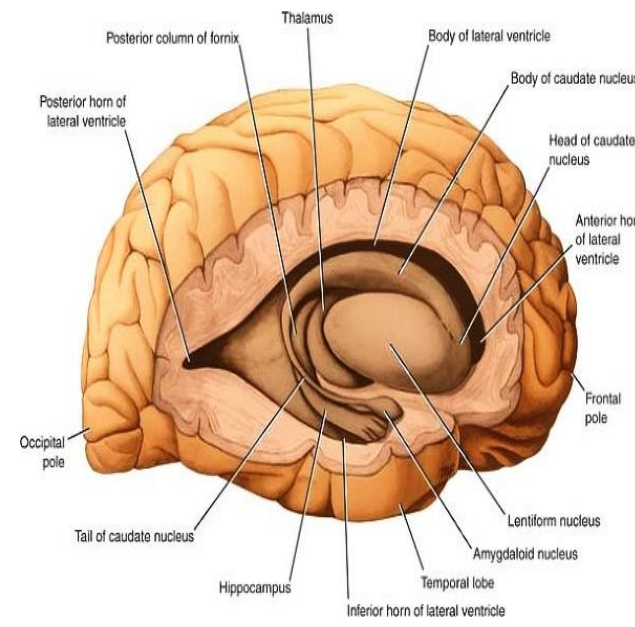
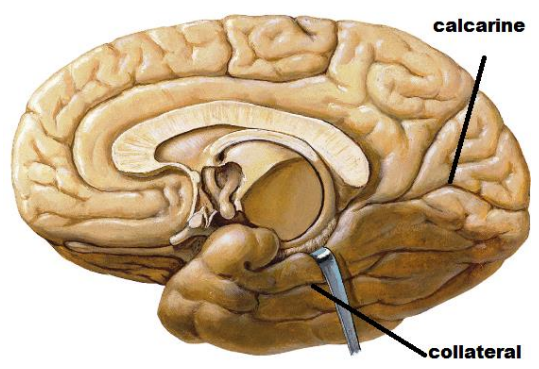
fimbria of hippocampus

medial w

choroid plexus in choroid fissure

between stria terminalis and

fimbria



LATERAL VENTRICLE

boundaries, walls:

post. horn:

Roof tapetum

lateral w

tapetum of post. Horn

optic radiation

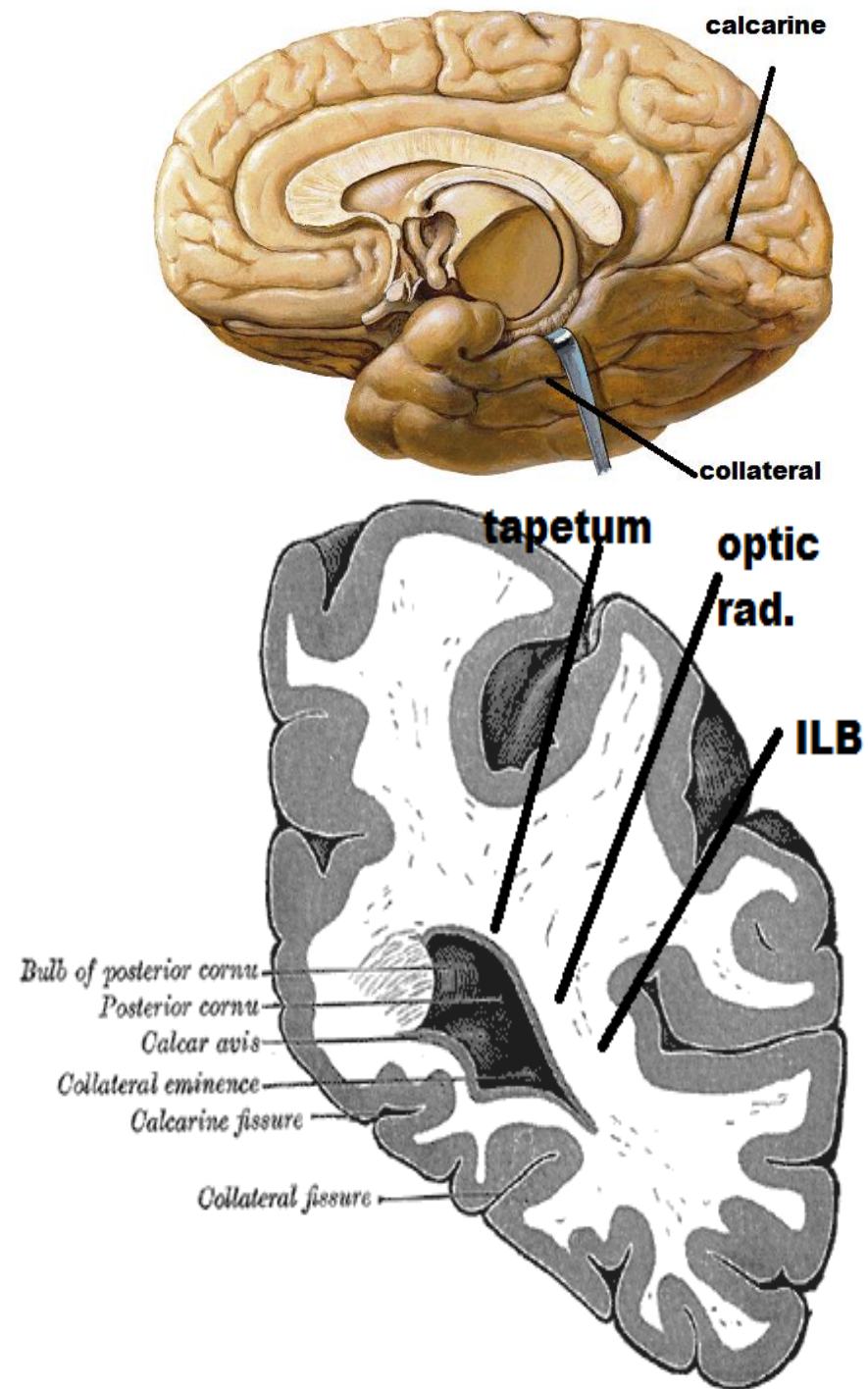
inferior longitudinal bundle

medial w collateral eminence

calcar avis

bulb of splenium by forceps major

N.B: identified by: absence of grey matter from walls:

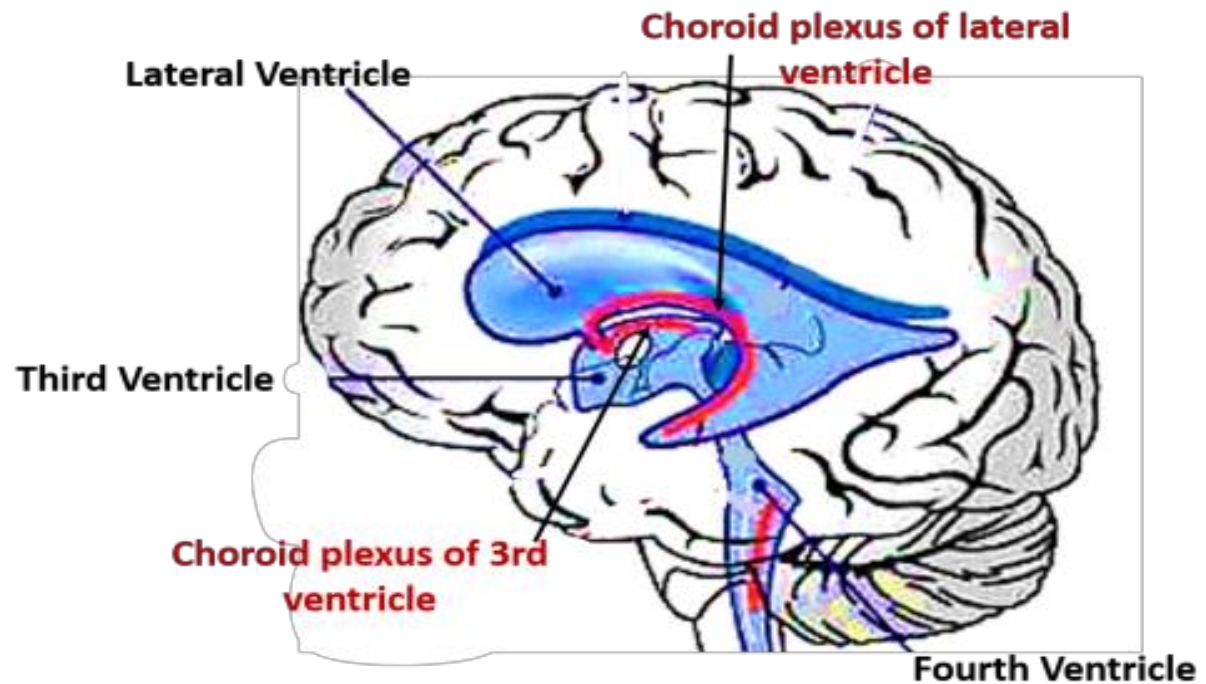
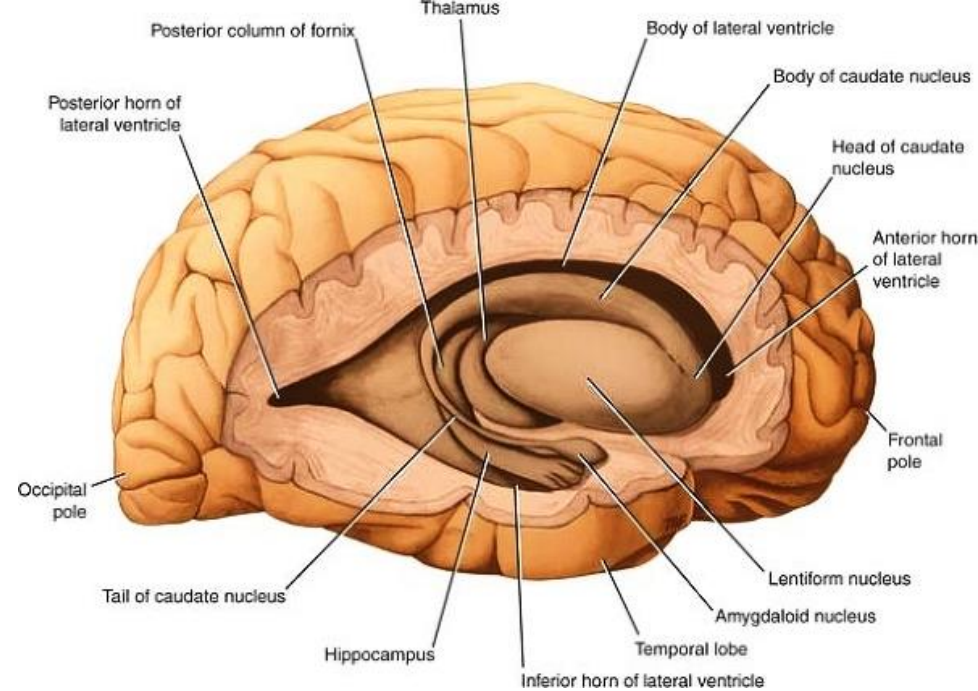


LATERAL VENTRICLE

trigone:

-wide area () central part, inferior & post horns.

-It Contain glomus choroideum(largest tuft of choroid plexus)



LATERAL VENTRICLE

Choroid fissure

shape & site: c shaped, on the medial aspect of central part & inferior horn

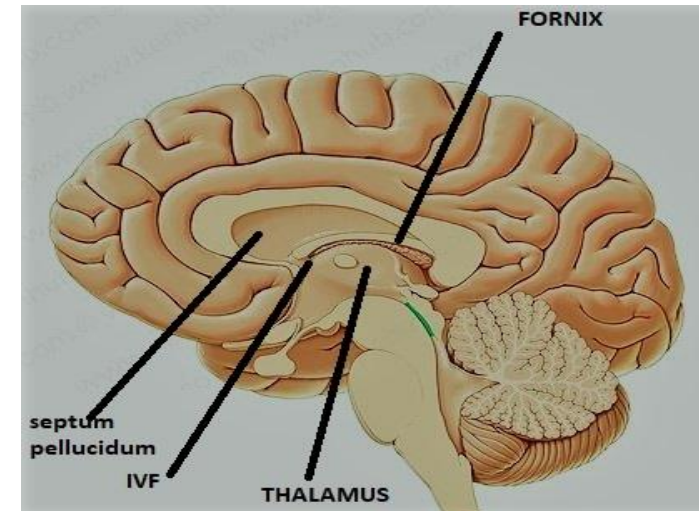
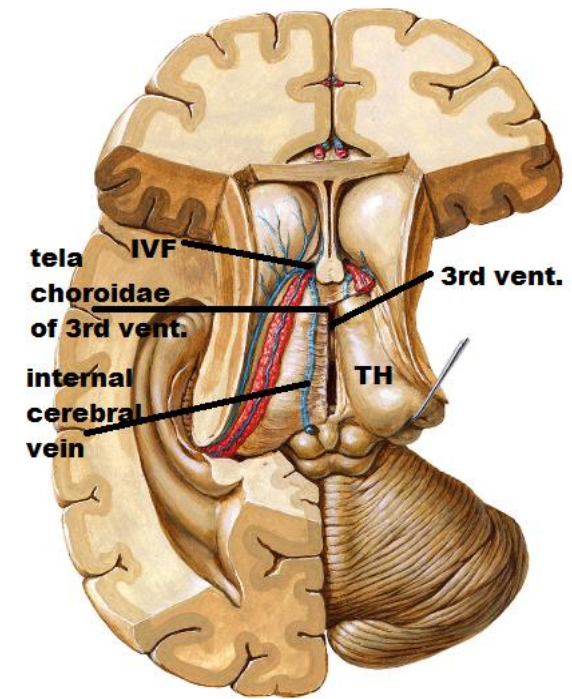
content : tela choroidae of lat. vent.

boundries:

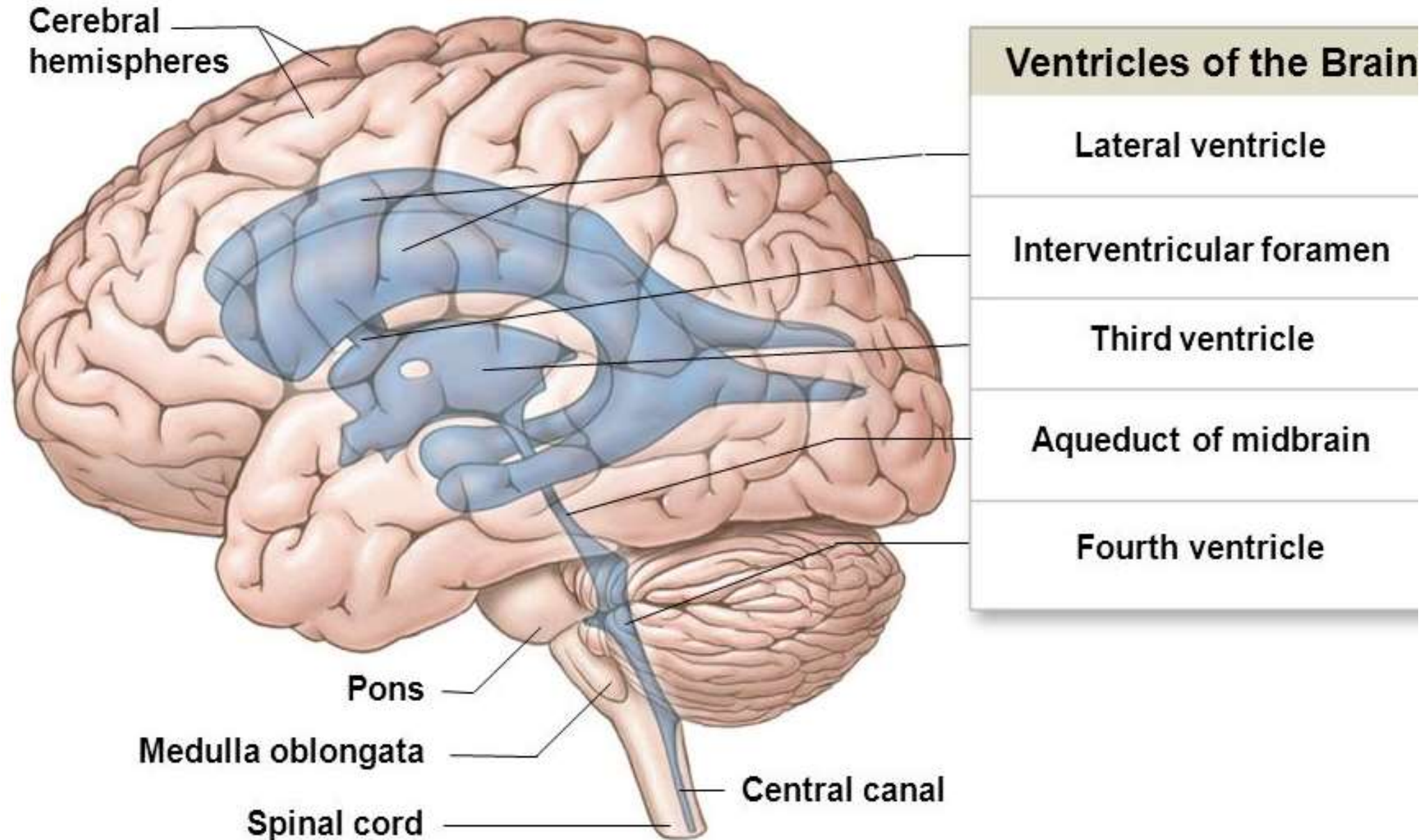
-outer concave margin :

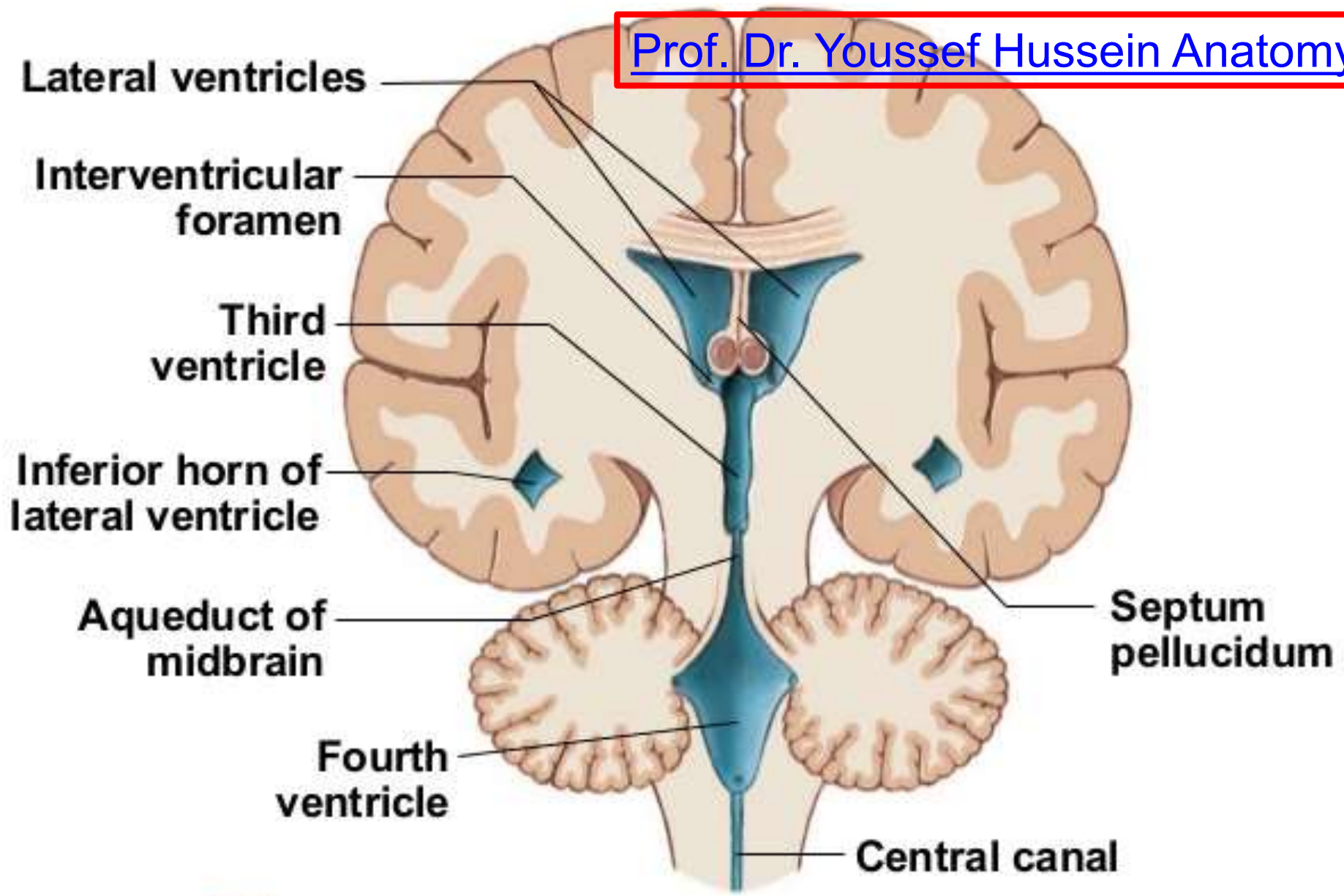
fimbria & fornix

-inner convex margin: thalamus



Ventricular system (lateral view)





d Diagrammatic coronal section showing the interconnections between the ventricles

Roof

Body of fornix

**Tela choroida &
choroid plexus**

**Anterior
commissure**

**Habenular
commissure**

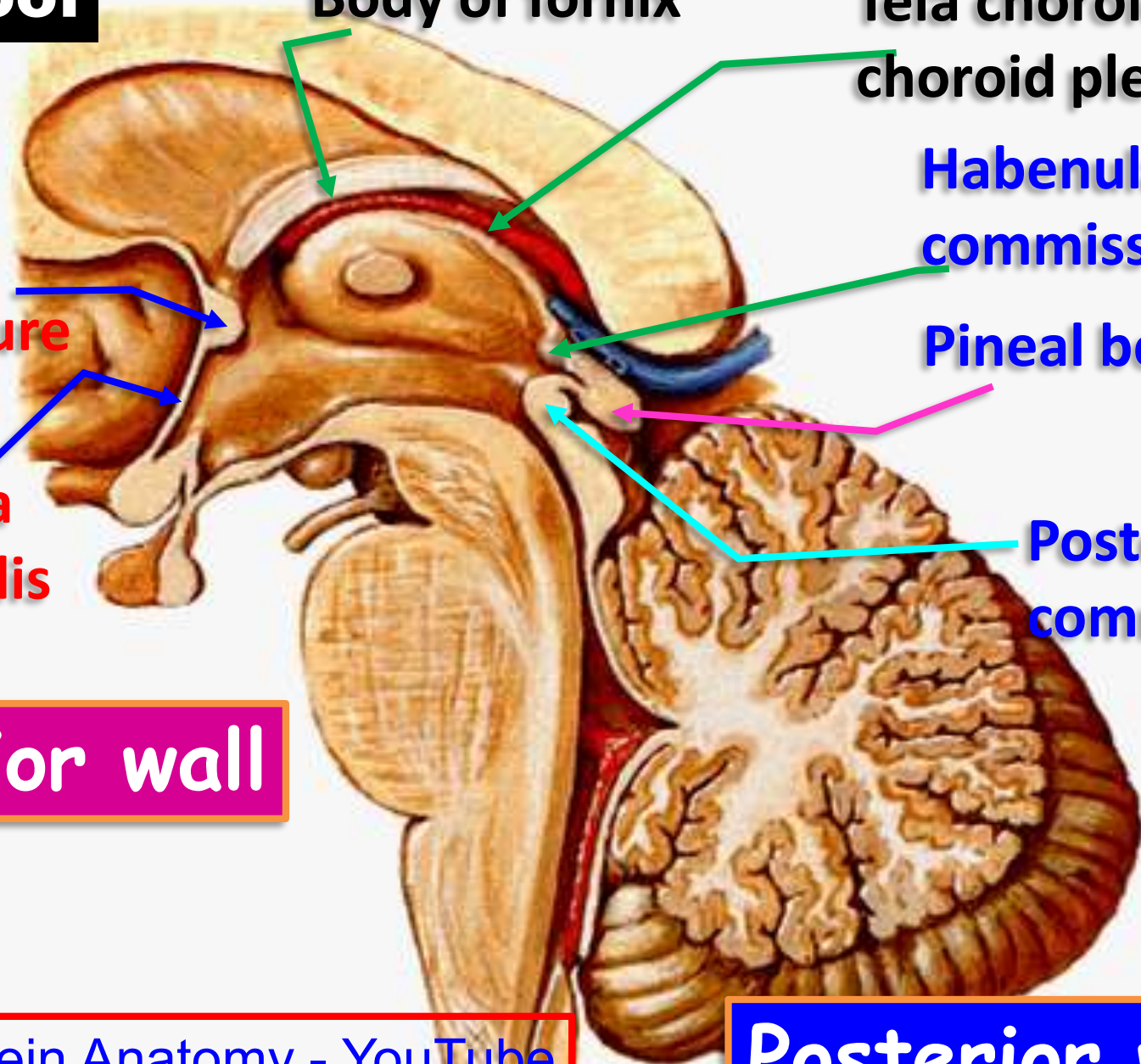
**Lamina
terminalis**

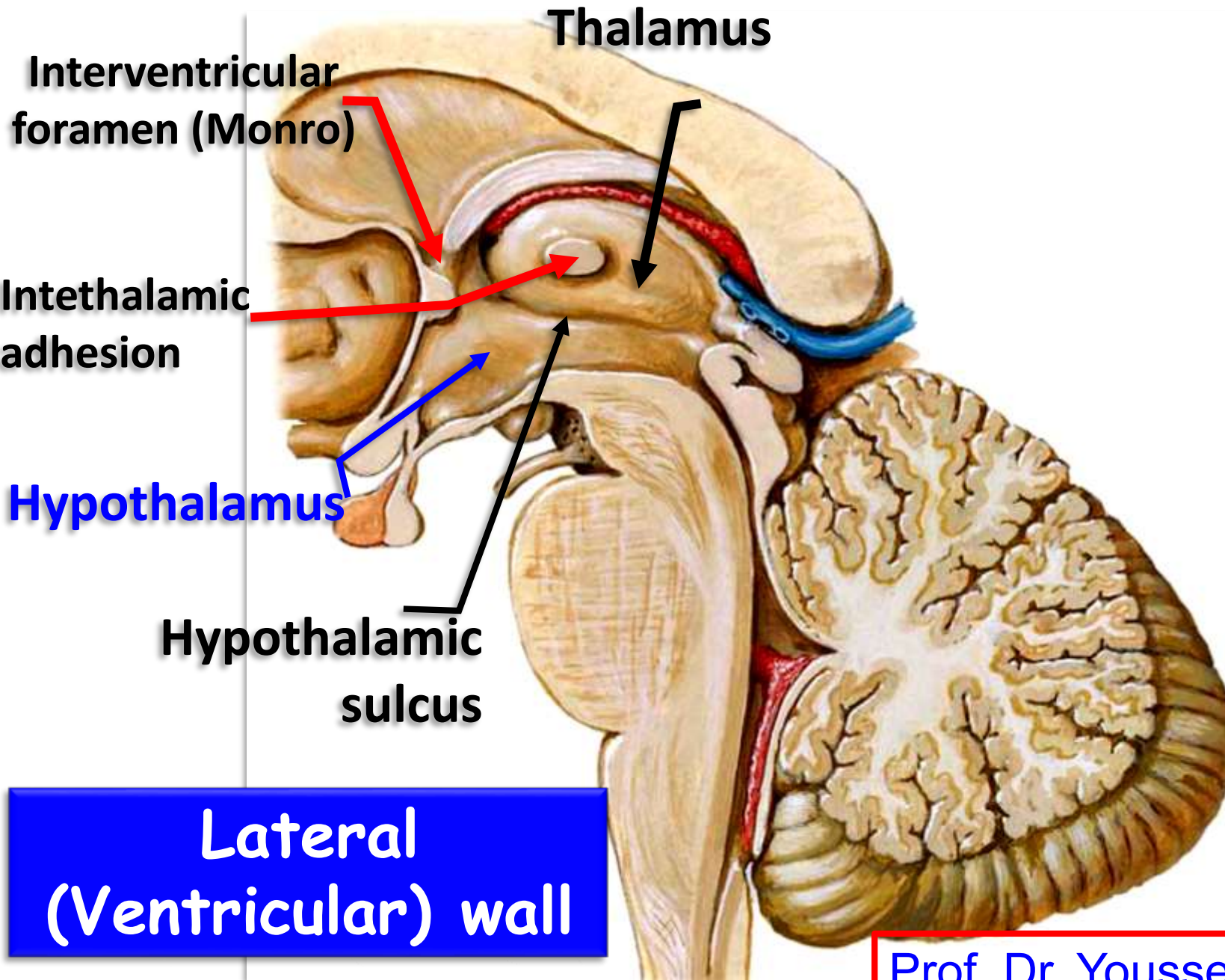
Pineal body

**Posterior
commissure**

Anterior wall

Posterior wall



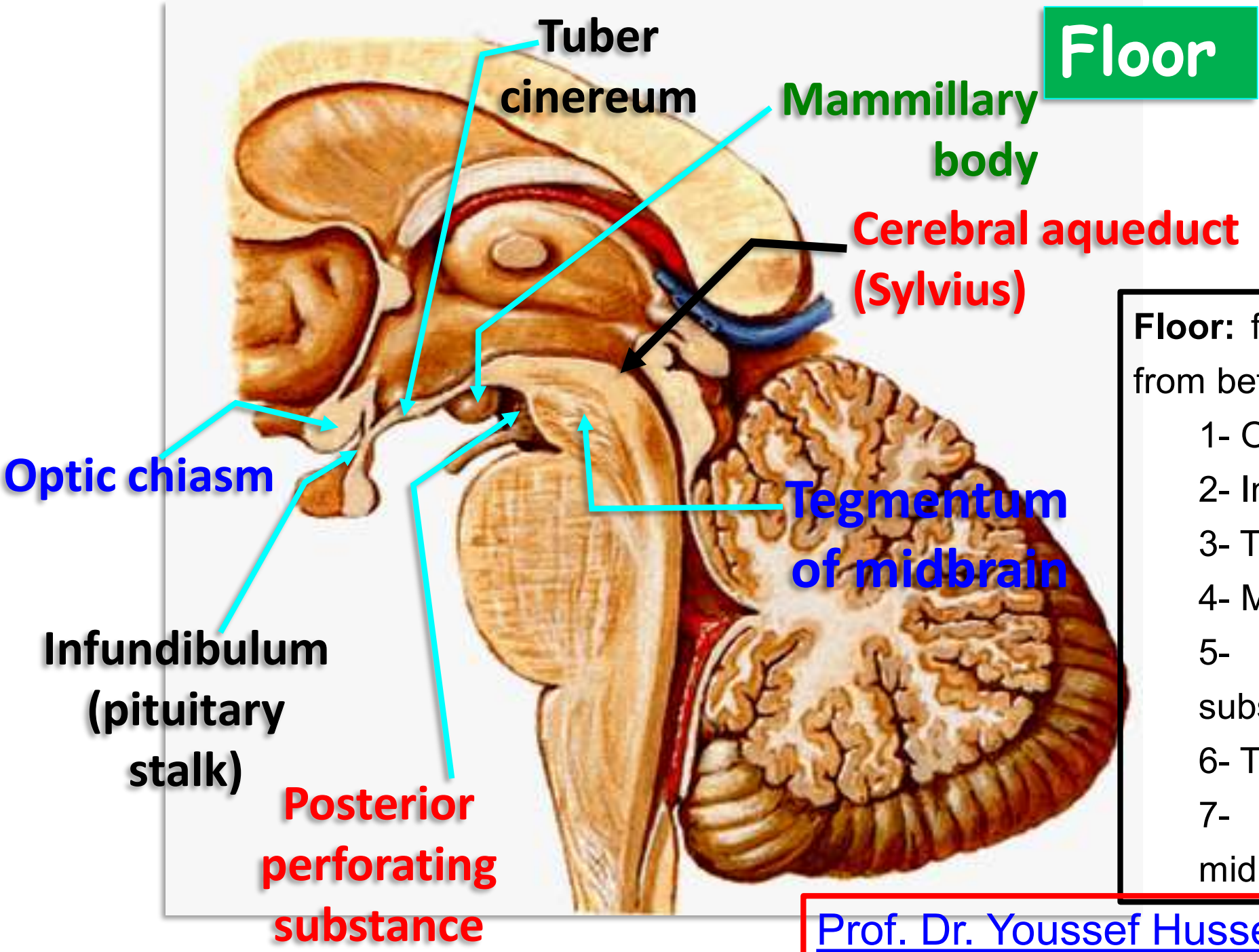


Lateral wall; if formed by;

- Upper part; Thalamus.
- Middle part; hypothalamic sulcus.
- Lower part; hypothalamus.
- Interventricular foramen (foramen of Monro) in the anterior part.

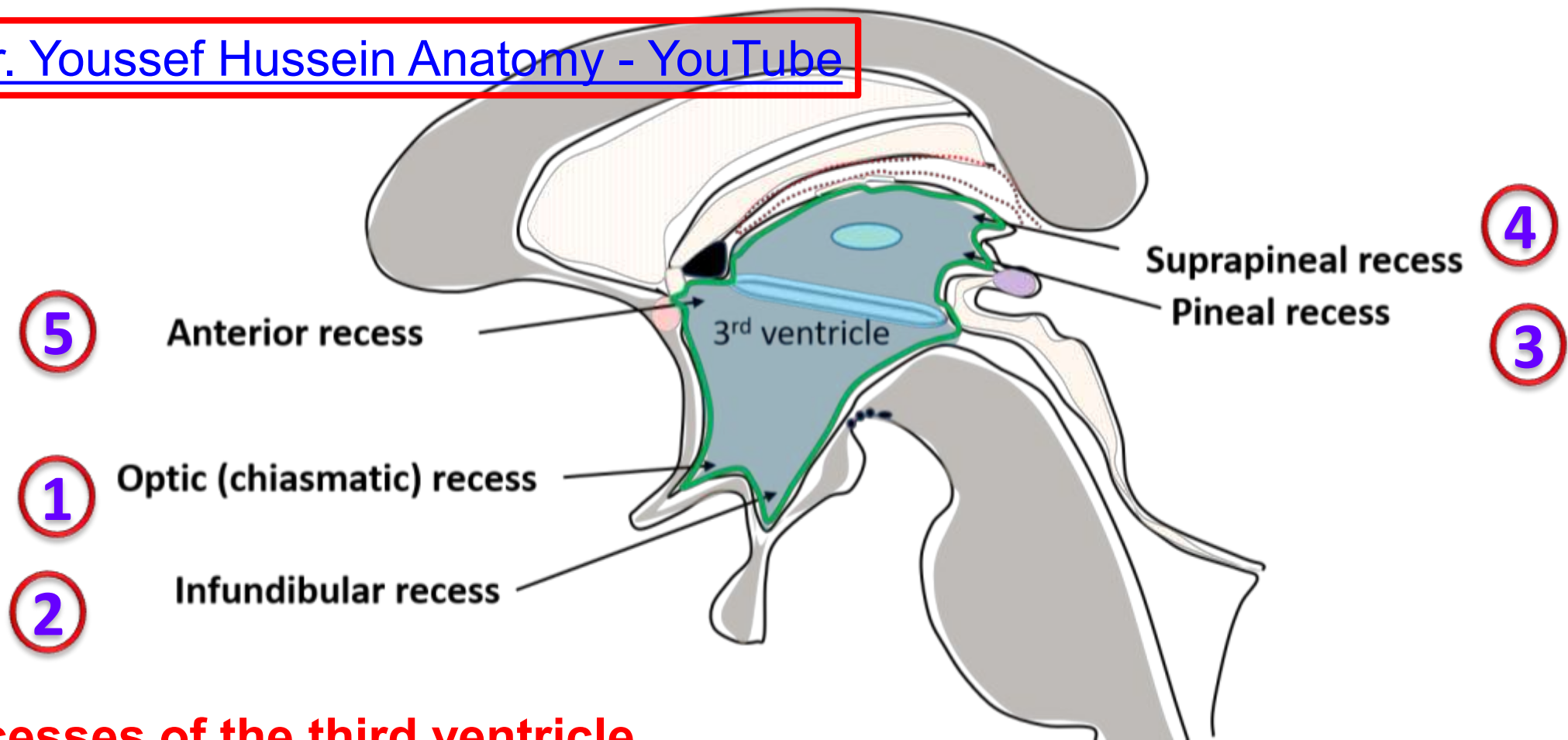
N.B; The two lateral walls are interconnected by the **interthalamic adhesion** across the cavity of the 3rd ventricle

Lateral (Ventricular) wall



Floor: following structures arranged from before backward;

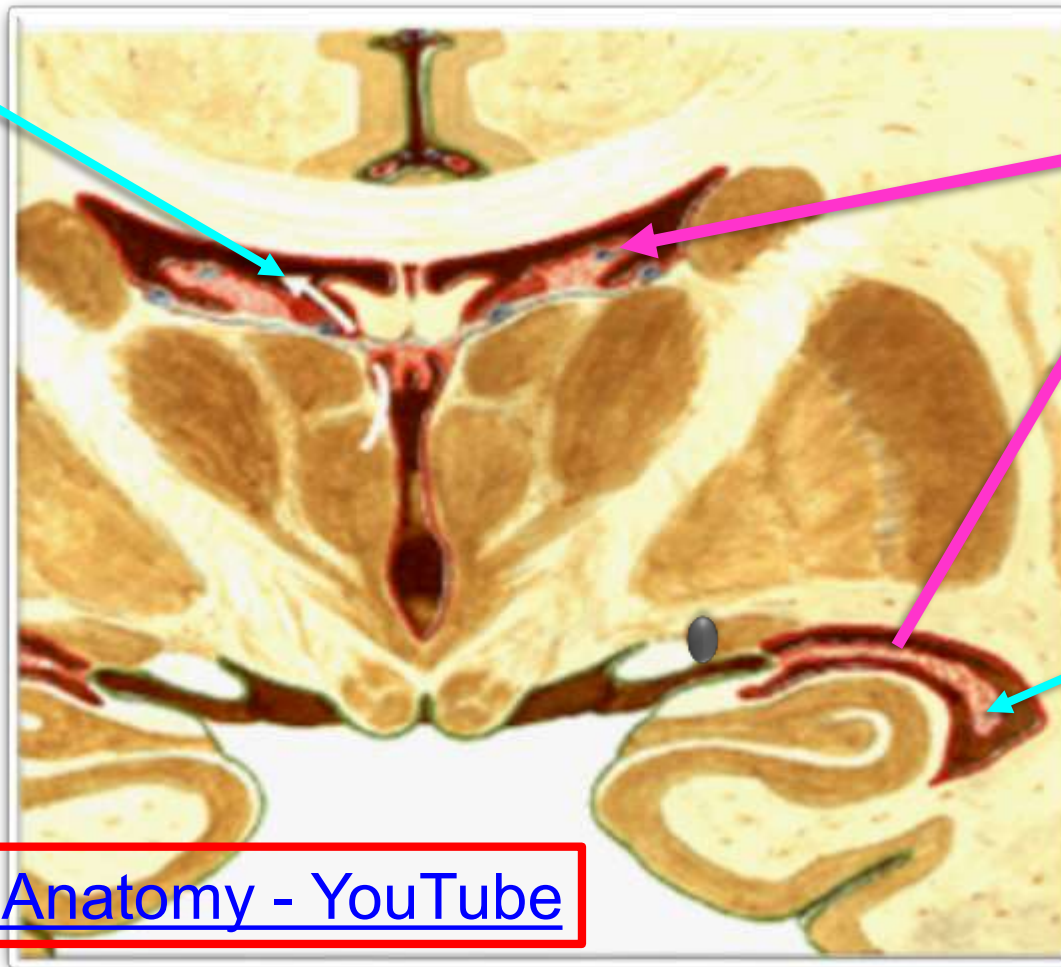
- 1- Optic chiasma.
- 2- Infundibulum.
- 3- Tuber cinereum.
- 4- Mammaillary bodies.
- 5- Posterior perforated substance.
- 6- Tegmentum of the midbrain.
- 7- Cerebral aqueduct of the midbrain.



- **Recesses of the third ventricle**

- 1- Supraoptic recess; above the optic chiasma.
- 2- Infundibular recess; into the upper part of the infundibulum.
- 3- Pineal recess; into the pineal stalk.
- 4- Suprapineal recess; above the pineal stalk.

**The central part
of the lateral
ventricle**



**Choroid Plexus of
the Lateral
Ventricle**

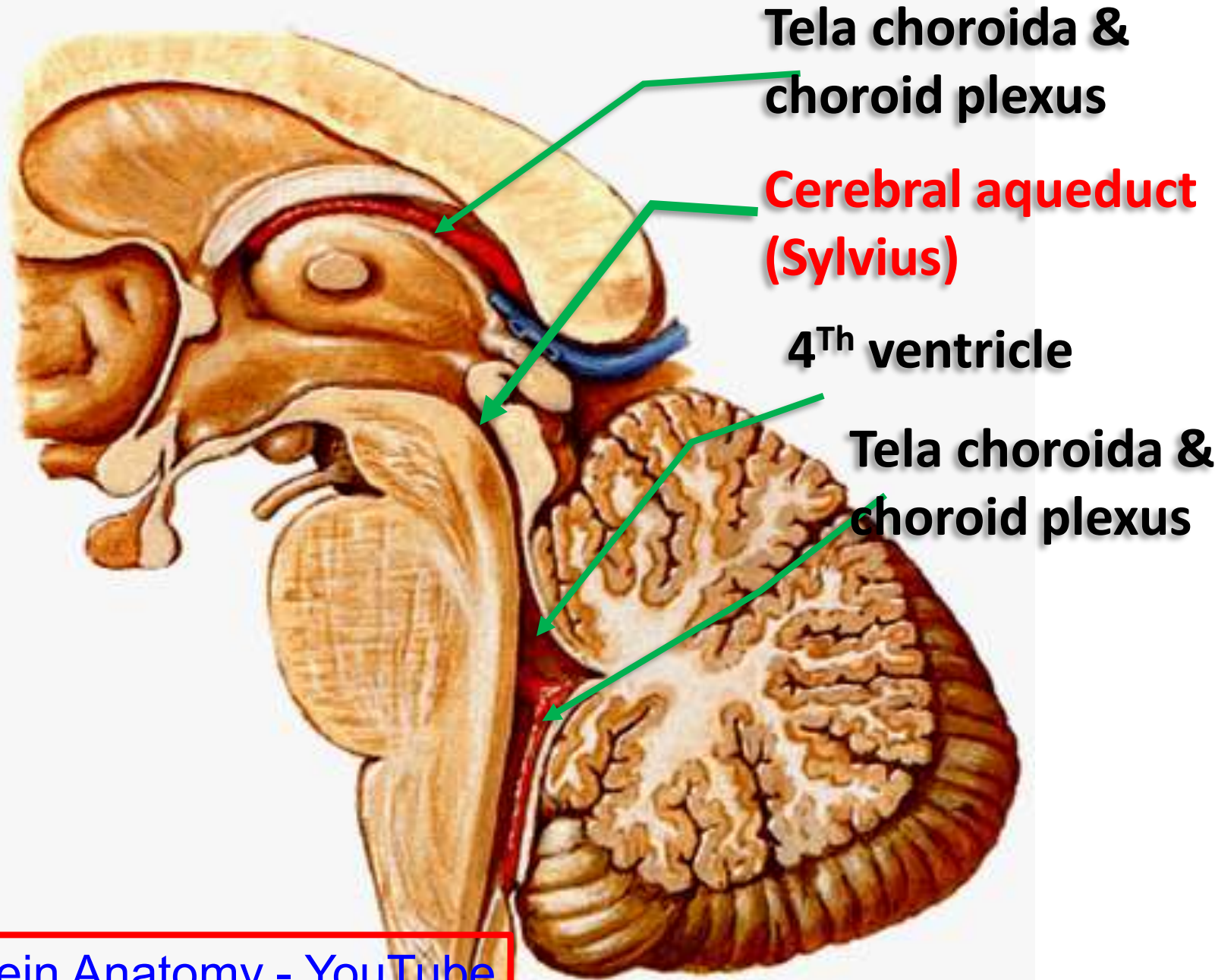
**Choroid plexus
of the lateral
ventricle**

**The inferior horn
of the lateral
ventricle**

[Prof. Dr. Youssef Hussein Anatomy - YouTube](#)

- **Tela choroidea**; double-layer of pia matter contains choroid plexuses
- **Choroid plexus** in **central part** is formed by **posterior choroidal branches of posterior cerebral artery**.
- **Choroid plexus** in **inferior horn** is formed by **anterior choroidal branches of internal carotid artery**.

- **Choroid plexuses** of 3rd ventricle is formed by **posterior cerebral artery**.
- **Choroid plexuses** of 4th ventricle is formed by **posterior inferior cerebellar arteries**



Cingulate gyrus

Indusium griseum

Septum pellucidum

dr_youssefhussein@yahoo.com

Fornix

CC

Fimbria of Hippocampus

Olfactory bulb

Dentate gyrus

Mammillary body

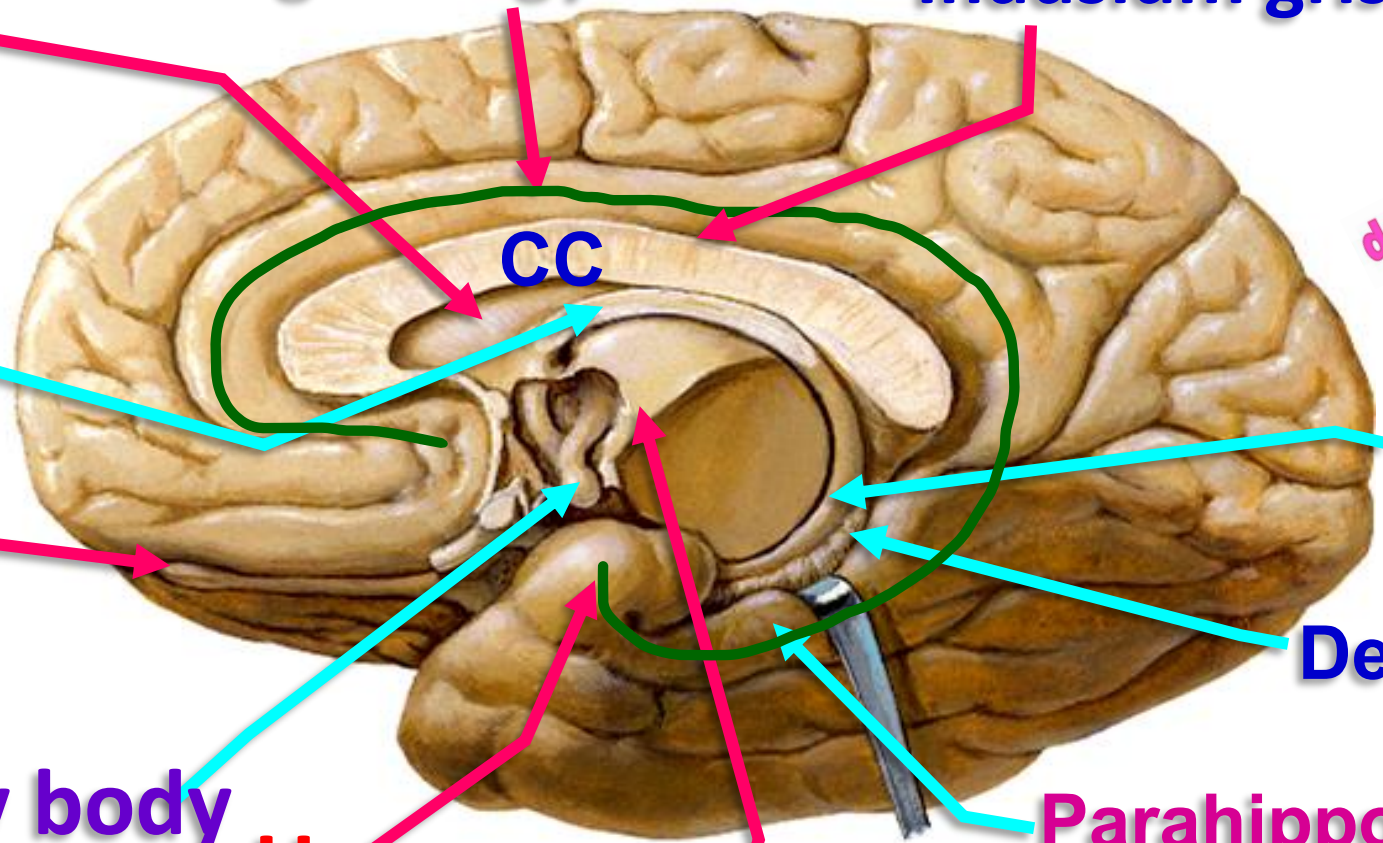
Parahippocampal gyrus

Uncus

Anterior nucleus of Thalamus

Parts of limbic system

اليوثيوب د. يوسف حسين



body of the fornix

Commissural fibres

Anterior columns of the fornix

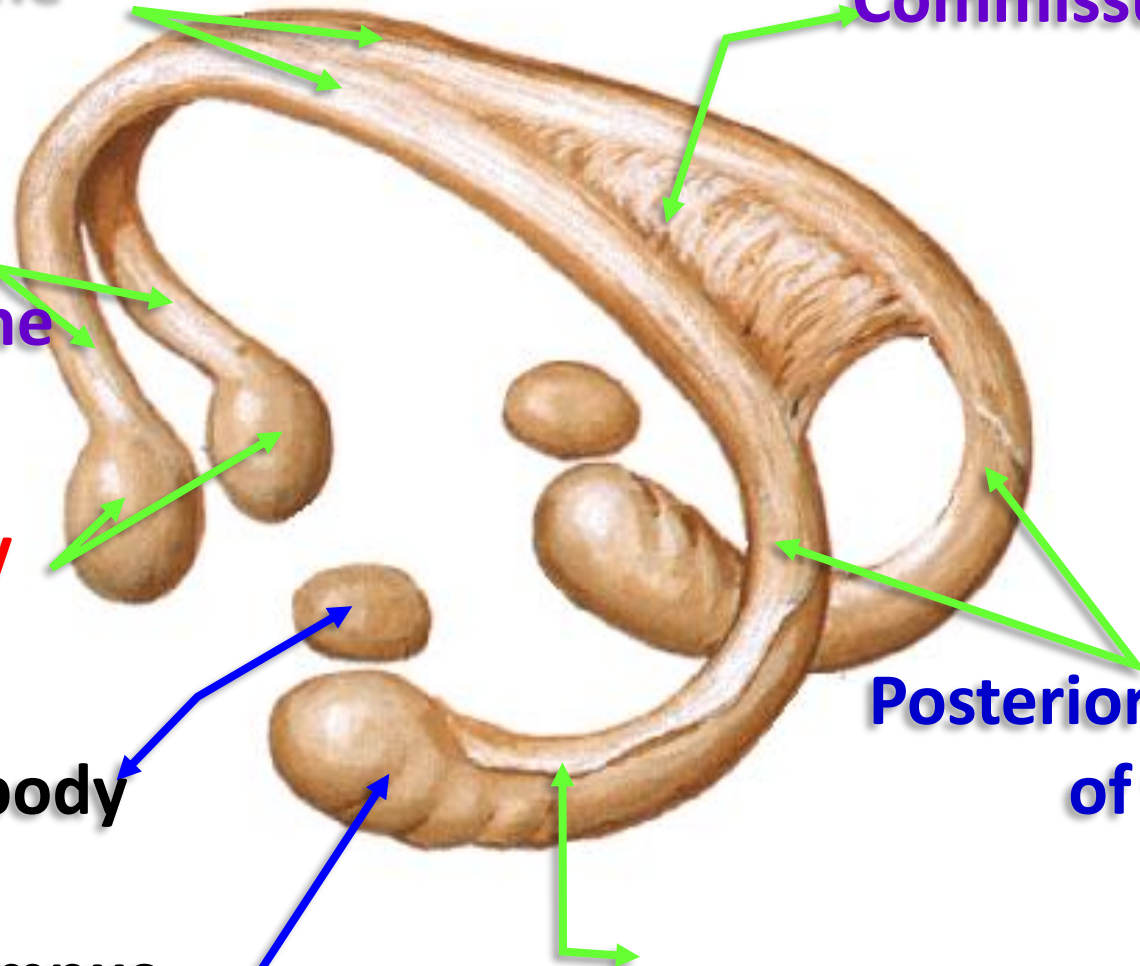
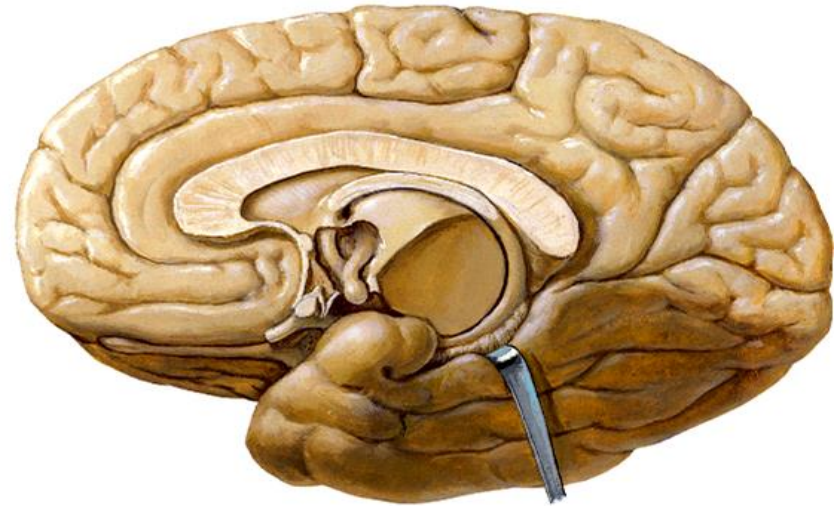
Mammillary bodies

Posterior crura (columns) of the fornix

Amygdaloid body

hippocampus

Fimbria of hippocampus



The fornix

اليوثيوب د. يوسف حسين



Fimbria of Hippocampus

Fornix

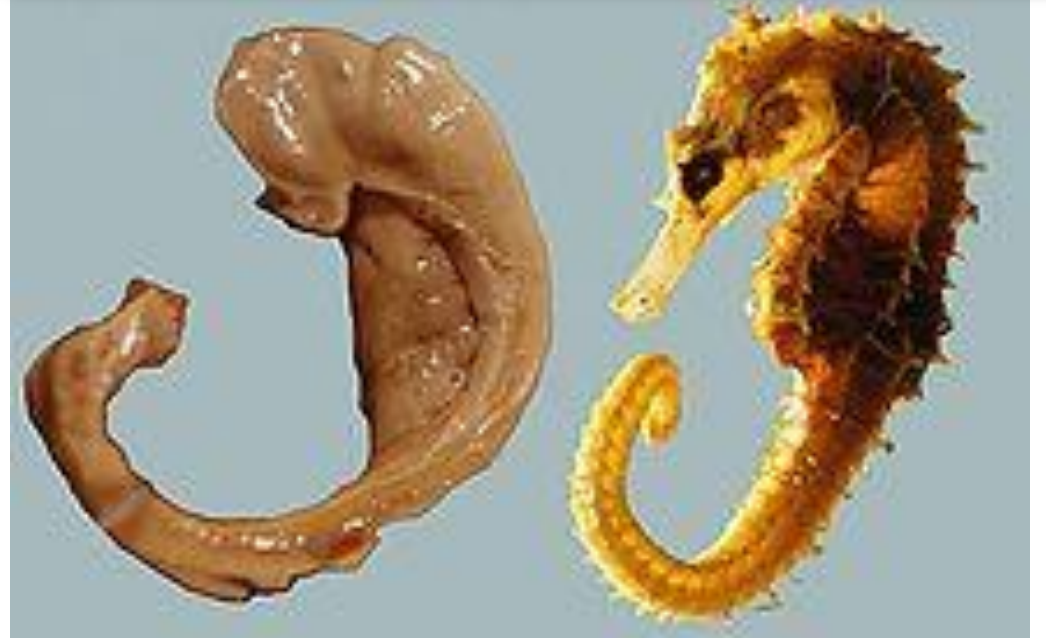Mammillary
body

Uncus

Hippocampus

Dentate gyrus

HIPPOCAMPUS

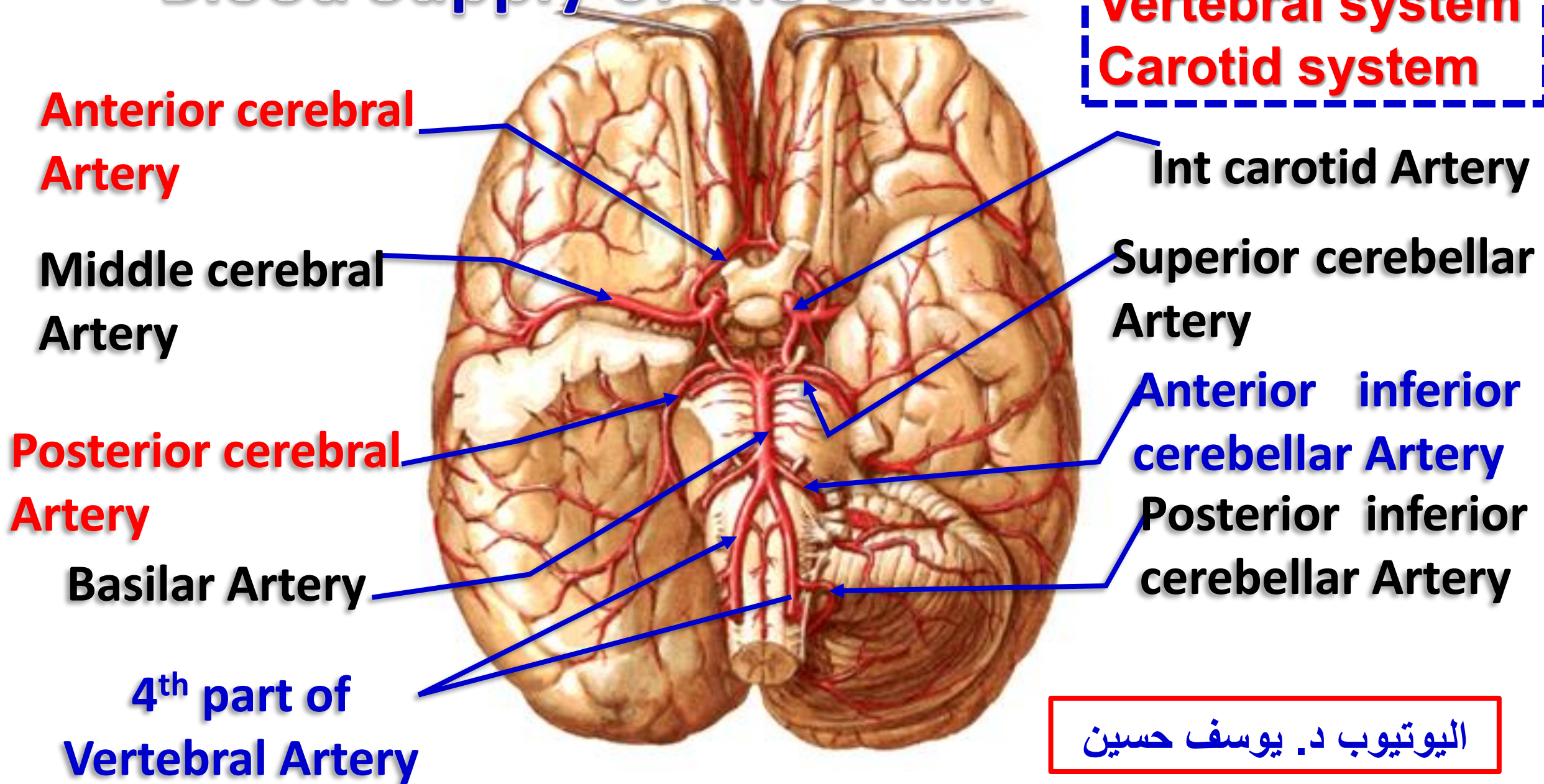


اليوتيوب د. يوسف حسين

- A **hippocampal formation** is located in **temporal lobe (medial)** of each cerebral cortex, medial to the inferior horn of the lateral ventricle.



Blood Supply of the Brain



اليوتيوب د. يوسف حسين

Anterior communicating Artery

Anterior cerebral Artery

Optic nerve

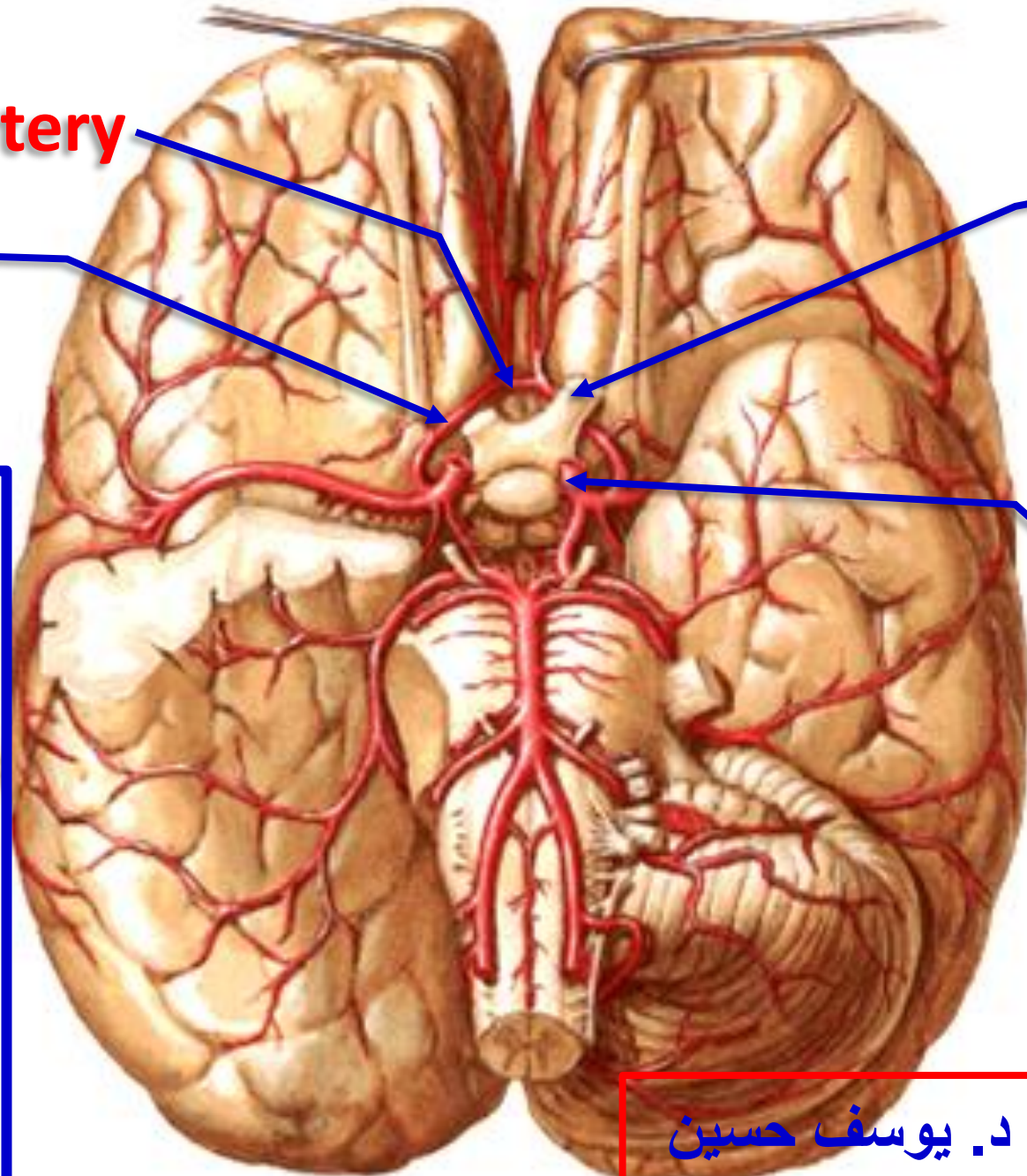
Internal carotid Artery

- **Anterior Cerebral Artery**

** **Origin:** one of 2 terminal branches of internal carotid artery.

** **Course:**

- It passes medially above optic nerve to median longitudinal fissure.
- It communicates with the opposite side by anterior communicating artery.

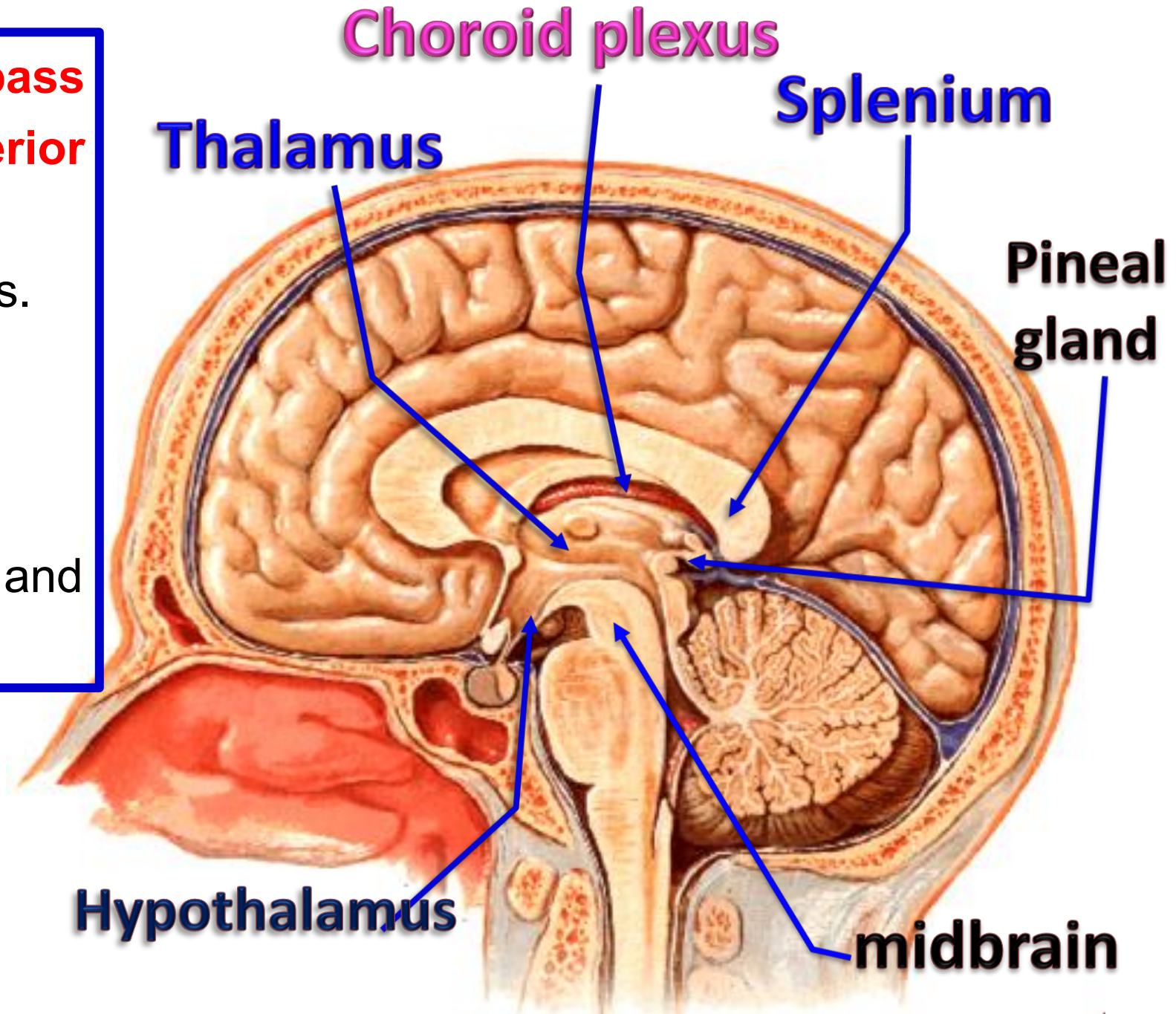


اليوتيوب د. يوسف حسين

- **Central branches; pass through the posterior perforated substance**

- a) Thalamus and hypothalamus.
- b) Midbrain and Pineal body.
- c) Splenium of the corpus callosum.
- d) Choroid plexuses of the 3rd and lateral ventricles.

اليوثيوب د. يوسف حسين



Circle of Willis

**Ant. communicating
Artery**

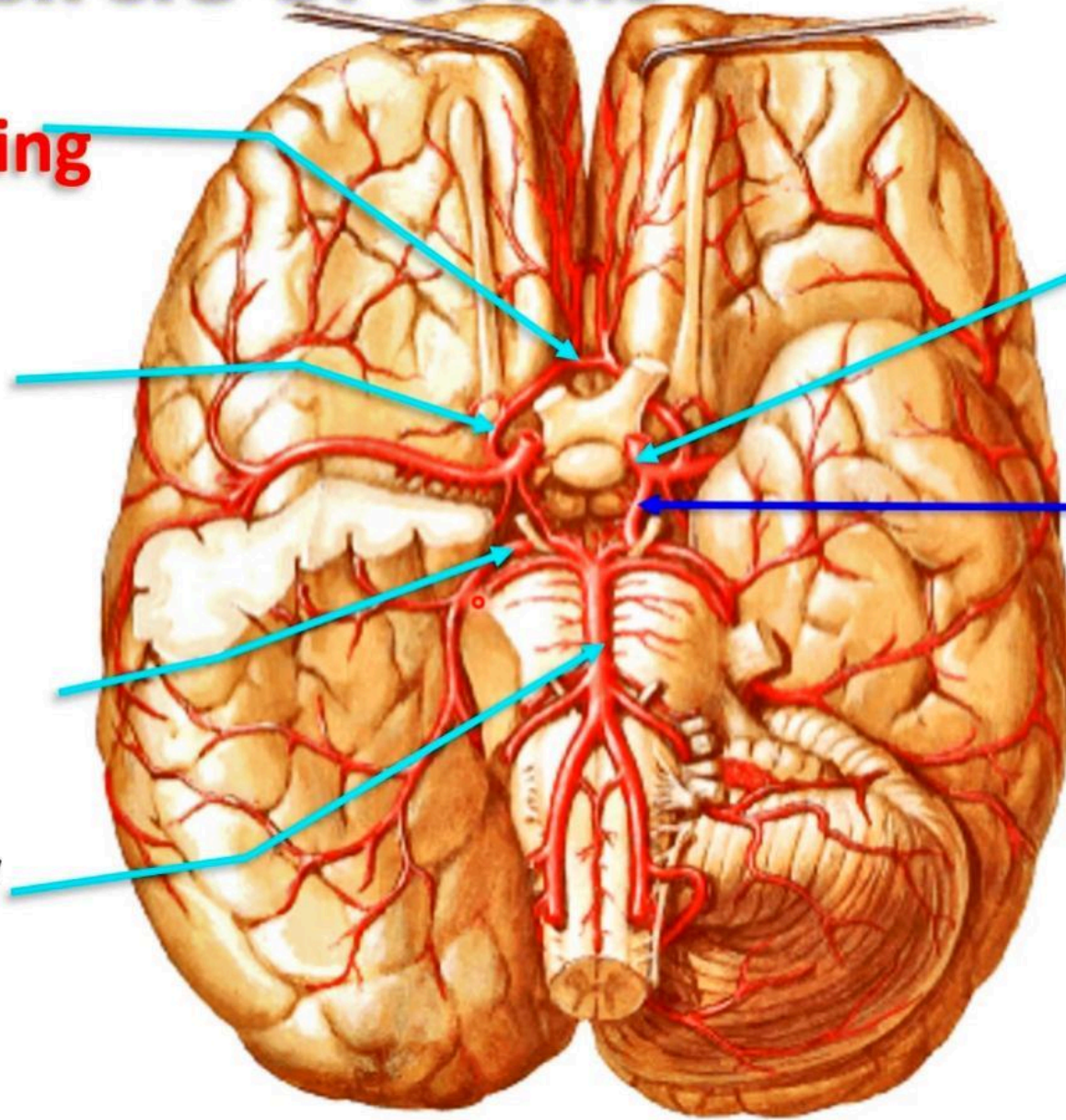
**Ant. cerebral
Artery**

**Post. cerebral
Artery**

Basilar Artery

**Int carotid
Artery**

**Post.
Communicating
artery**





محمّد
الشيخ



Collected by Baraiah