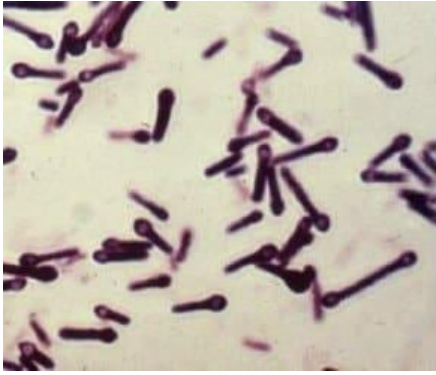
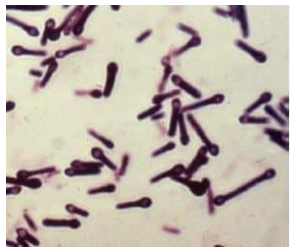
Clostridium tetani

Presented by

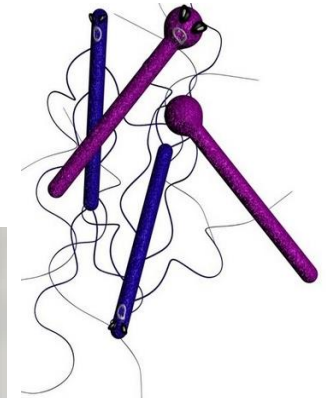
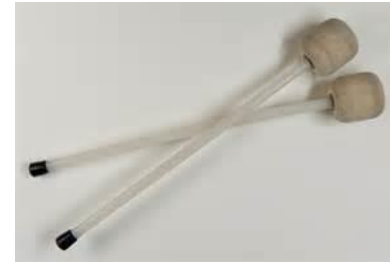Associate Professor Dina Abou Rayia



Morphology

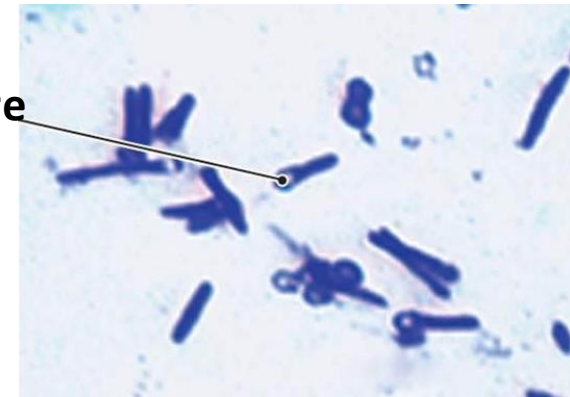

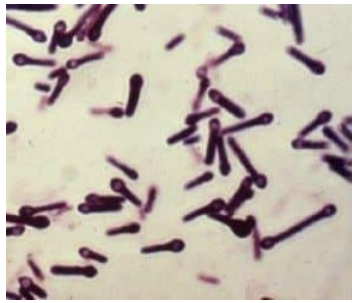- ❖ Slender gram-positive rods, non-capsulated
- ❖ Motile by flagella
- ❖ Endospores forming at the end giving the rods a drumstick appearance
- ❖ The organism is sensitive to heat, but spores are very resistant to heat and the usual antiseptics. They are also relatively resistant to phenol and other chemical agents.
- ❖ The spores are widely distributed in soil and the intestines of animals



Clostridium tetani

Endospore





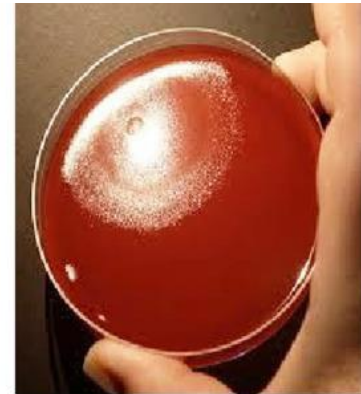Culture and biochemical reaction



- ❖ The organism is obligatory anaerobe and can't grow in the presence of oxygen
- ❖ It grows well on cooked meat broth and on blood agar incubated anaerobically, they form a thin film
- ❖ The organism ferments no sugar



A



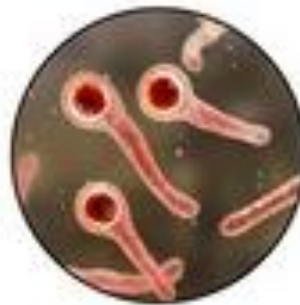B



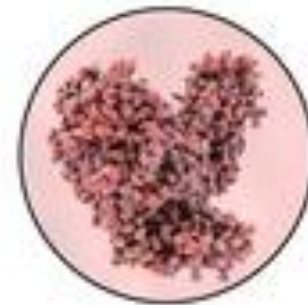Tetanus



Contaminated wound



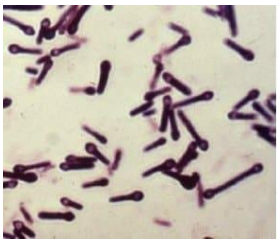Clostridium tetani bacteria



Tetanus neurotoxin



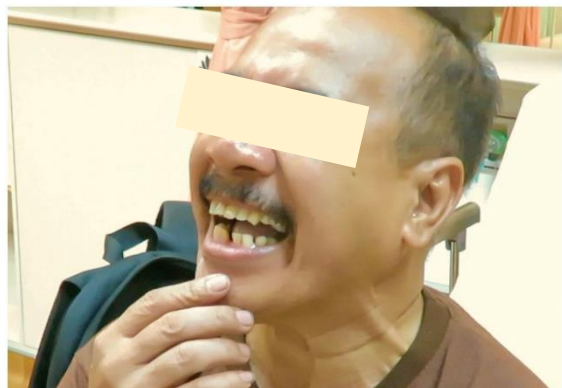
Severe hyperextension and spasticity caused by neurotoxin of *C. tetani*



Tetanus (Lock jaw)



- A serious disease caused by *C. tetani* and characterized by generalized muscle spasms, hyperreflexia, and seizures.

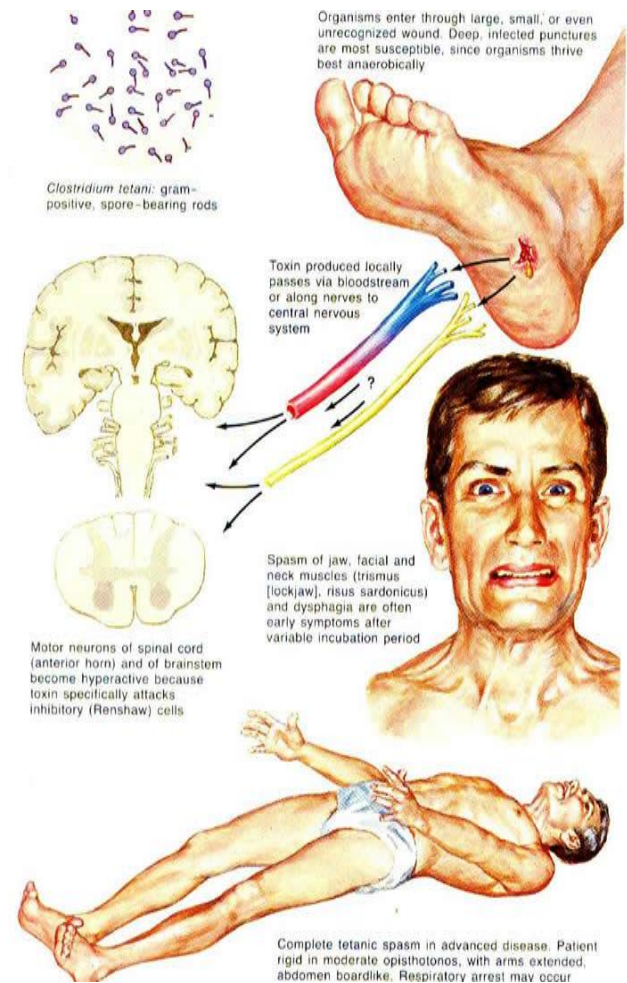


❖ Mode of transmission

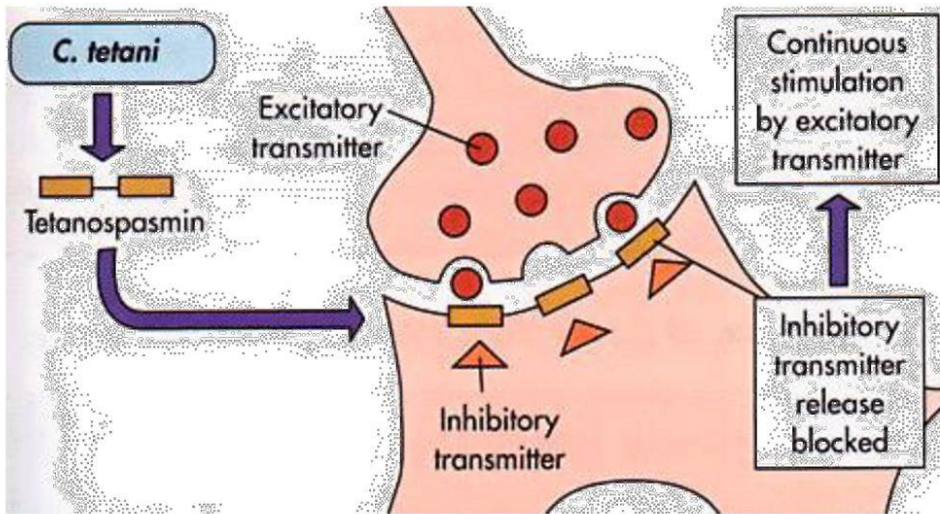
- The spores of *C. tetani* are commonly found in the soil, dust, and manure.
- They enter through skin breaks such as cuts (major or minor) or puncture wounds by a contaminated object, may follow burn, animal bite, otitis media, etc.....
- It is not transmitted from person to person (**not contagious**)

❖ Pathogenesis:

- The spores that contaminate wounds in the presence of anaerobic condition will germinate, multiply and produce two types of toxins:
 - ***Tetanolysin***: has no relation with tetanus
 - ***Tetanospasmin*** neurotoxin
- Tetanospasmin reaches the CNS via the blood and retrograde spread occurs also through nerve axons until reaching the motor nuclei of cranial nerves or ventral horn of the spinal cord

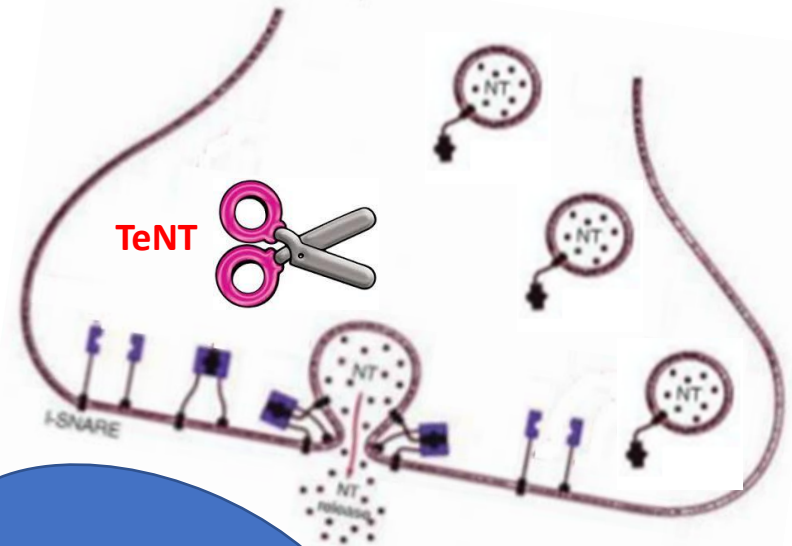


Mechanism of Action of Tetanus Toxin



Tetanospasmin cleaves the synaptobrevin which is required for the fusion of vesicles containing inhibitory neurotransmitters (e.g. GABA) with the membrane resulting of neurotransmitter release inhibition

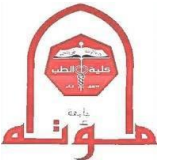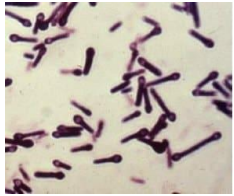
Interneurone



Motor neuron

NT: neurotransmitter

TeNT: tetanospasmin neurotoxin

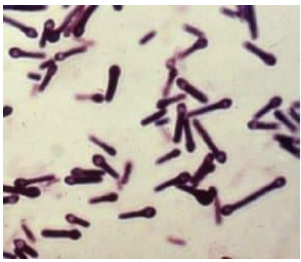


- **Wound associated aerobic bacterial infection**

effect on *C. tetani*

??





Clinical picture of tetanus

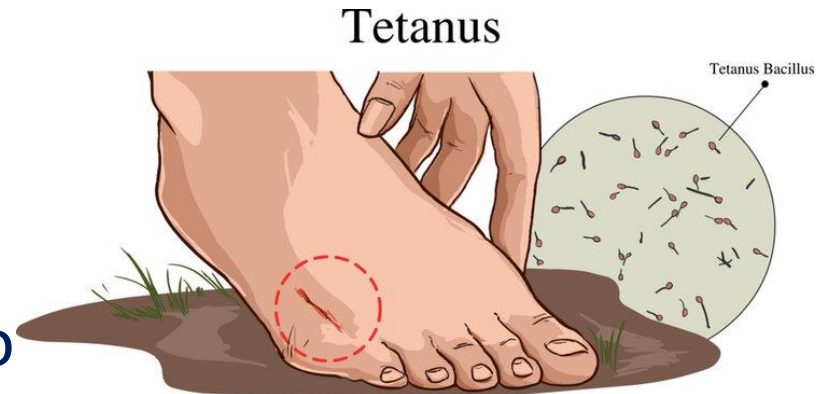


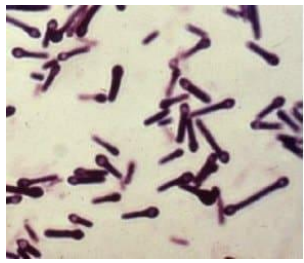The incubation period:

- ❑ Ranges from 3 to 21 days (average 8 days)

Tetanus has two different forms based on the clinical findings:

1. Local (including cephalic).
2. Generalized (including neo



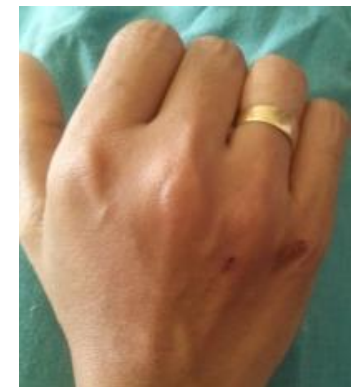
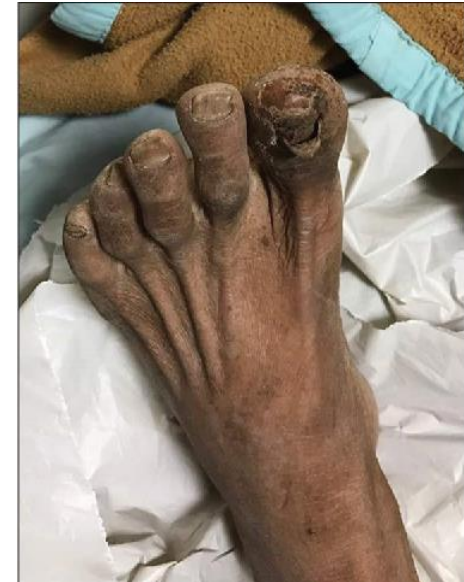
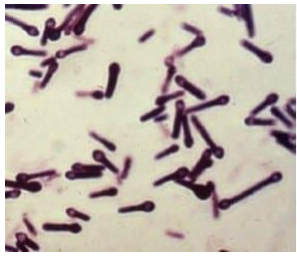
Forms of tetanus



❖ Local tetanus

- Is an uncommon form of the disease, in which patients have persistent contraction of muscles in the same anatomic area **(at the site of injury)**
- These contractions may persist for many weeks before gradually subsiding.
- Local tetanus may precede the onset of generalized tetanus.
- **Only about 1% of cases are fatal.**



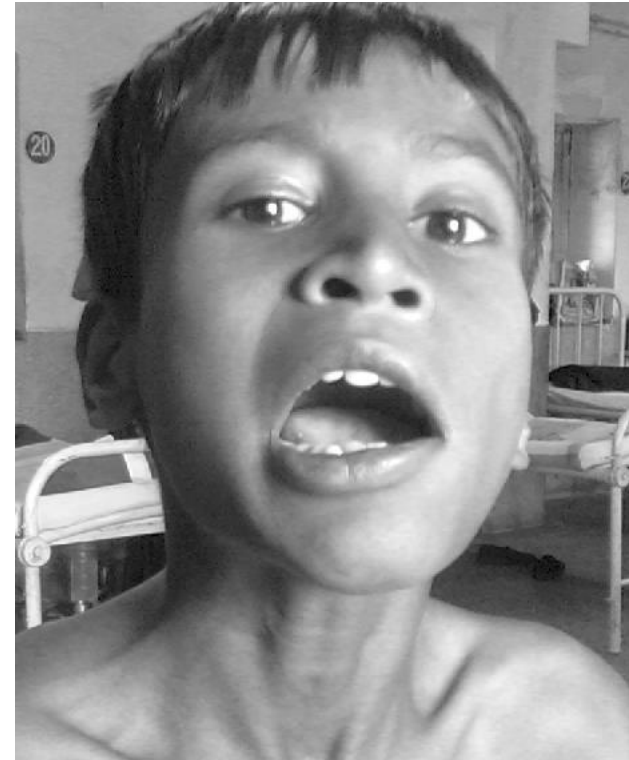

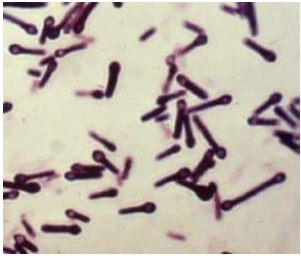
Forms of tetanus



❖ Cephalic tetanus

- Is a rare form of the disease (type of localized tetanus)
- Occasionally occurring with otitis media, ear infections, or following injuries to the head
- There is an involvement of the cranial nerves, especially in the facial area.
- If the cranial nerves are involved in localized cephalic tetanus, the pharyngeal or laryngeal muscles may spasm, with consequent aspiration or airway obstruction, and the **prognosis may be poor.**



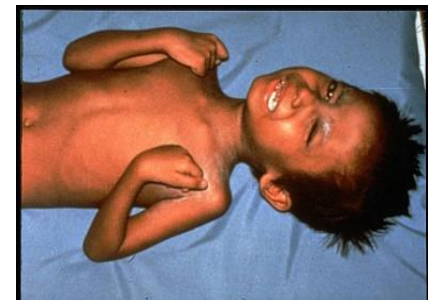

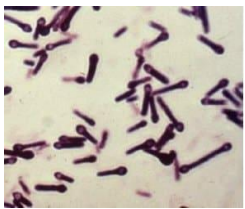
Forms of tetanus



❖ Generalized tetanus

- The most common type (about 80% of reported tetanus)
- The first sign is trismus or lockjaw, followed by stiffness of the neck, difficulty in swallowing, and rigidity of abdominal muscles.
- Other symptoms include elevated temperature, sweating, elevated blood pressure, and episodic rapid heart rate.
- Spasms may occur frequently and last for several minutes. Spasms continue for 3–4 weeks.
- Complete recovery may take months.





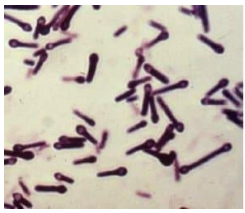Forms of tetanus



❖ Neonatal tetanus (*Tetanus neonatorum*)

- Is a form of generalized tetanus that occurs in newborn infants.
- Neonatal tetanus occurs in infants born without protective passive immunity because the mother is not immune
- It usually occurs through **infection of the unhealed umbilical stump**, particularly when the stump is cut with an unsterile instrument
- Neonatal tetanus is common in some developing countries
- Neonates show signs of being generally irritable, muscle spasms, and poor ability to take in liquids (poor sucking response), usually seen in neonates about 7-10 days old

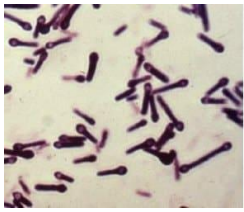




Complications



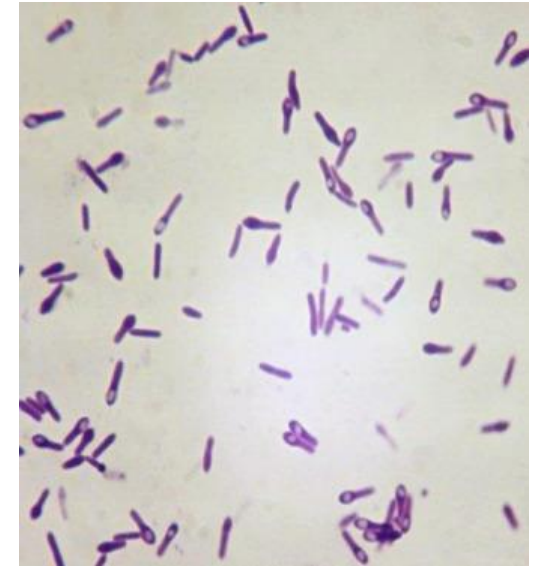
- **Laryngospasm** (spasm of the vocal cords) and/or spasm of the muscles of respiration leads to interference with breathing.
- **Fractures** of the spine or long bones may result from sustained contractions and convulsions.
- Hyperactivity of the autonomic nervous system may lead to **hypertension** and/or an **abnormal heart rhythm**.
- Cases most likely to be **fatal** are those occurring in persons 60 years of age and older (18%), and unvaccinated persons (22%).

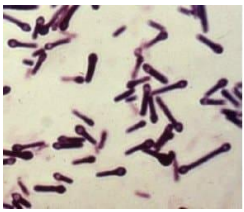


Diagnosis

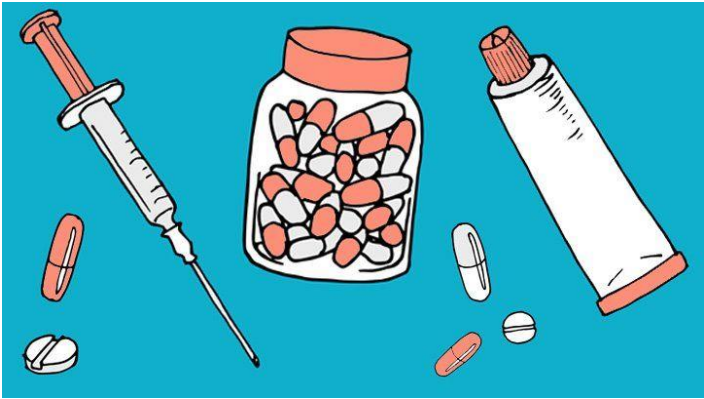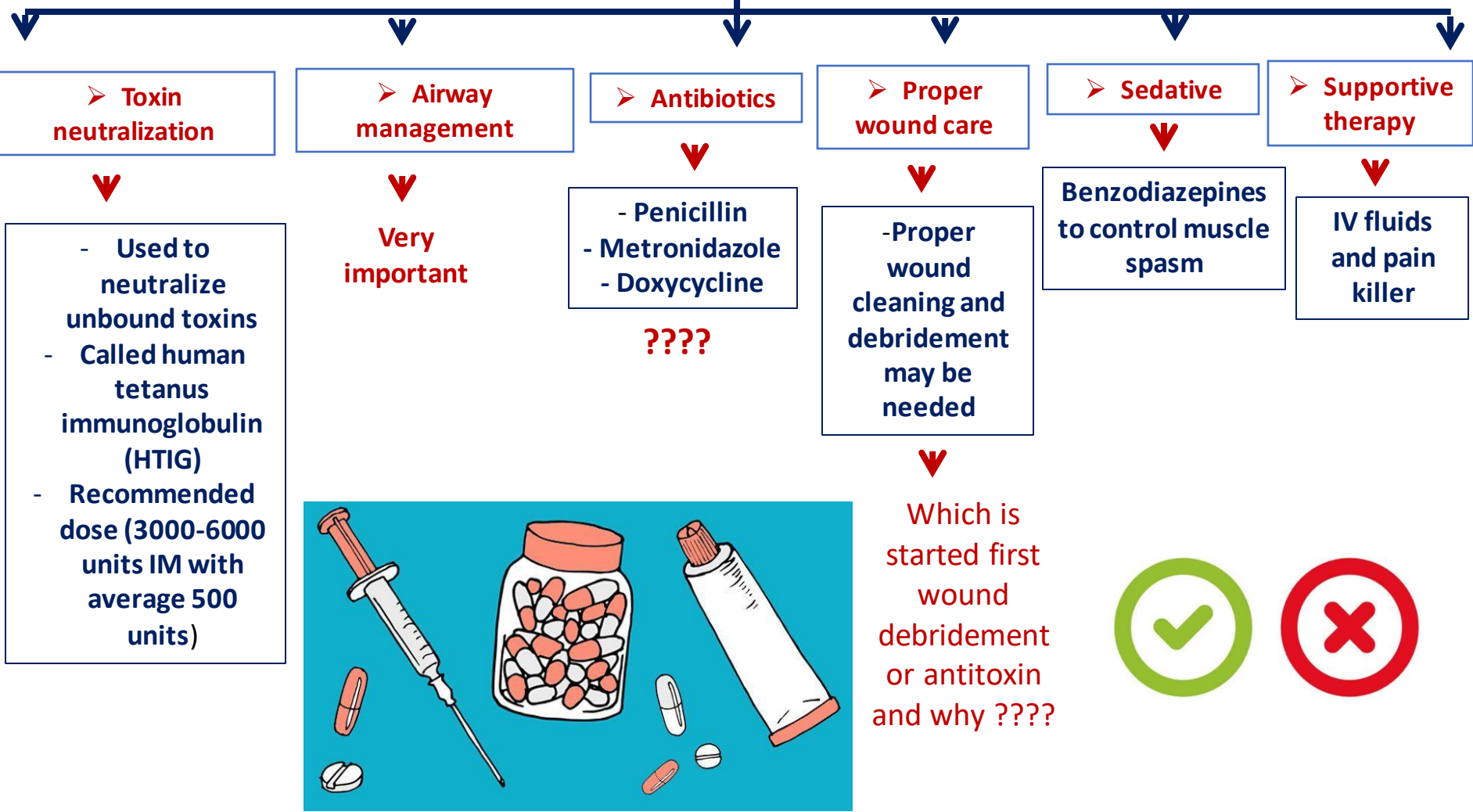


- **History**
- **Clinical picture**
- **Laboratory:**
 - **Specimen:** swab from the lesion
 - **Culture** on blood agar incubated anaerobically ??
 - **Biochemical reaction ??**
 - **Animal pathogenicity**



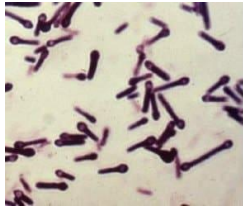

Treatment



Which is started first
debridement or antitoxin
and why ????





Prophylaxis



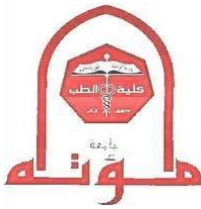➤ Active immunization

- Tetanus toxoid is given with diphtheria toxoid and pertussis vaccine as DPT at the age of 2, 4, 6 months
- Booster dose at 1 year and school entry
- Booster dose of DT is given every 10 years
- **Individuals wounded with previous history of vaccination 5 or more years should receive a booster dose**
- **Booster dose for pregnant women**

➤ Passive immunization

- **Individual wounded without previous history of vaccination or vaccinated more than 10 years ago should receive HTIG (250-500 units IM) and this passive immunization should be accompanied with active immunization**

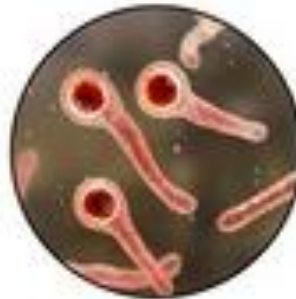When to seek tetanus medical care???



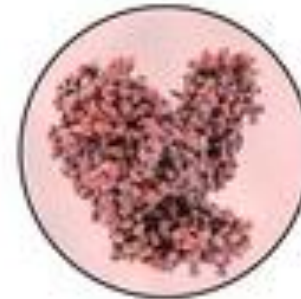- If the wound is large, contains crushed tissues, or is heavily contaminated
- If individuals have a recent injury and are starting to experience muscle cramps or spasms at or near the injury
- If individuals have trouble swallowing or have muscle spasms in the facial muscles



Contaminated wound



Clostridium tetani bacteria

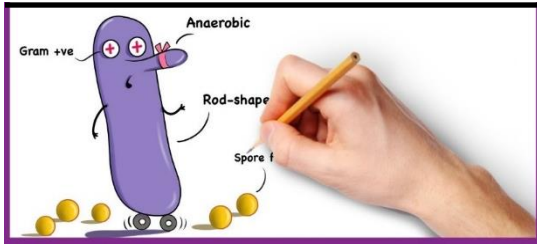


Tetanus neurotoxin



Severe hyperextension and spasticity caused by neurotoxin of *C. tetani*

SUMMARY

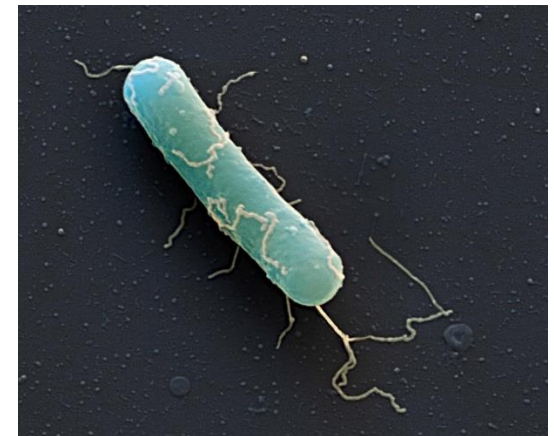
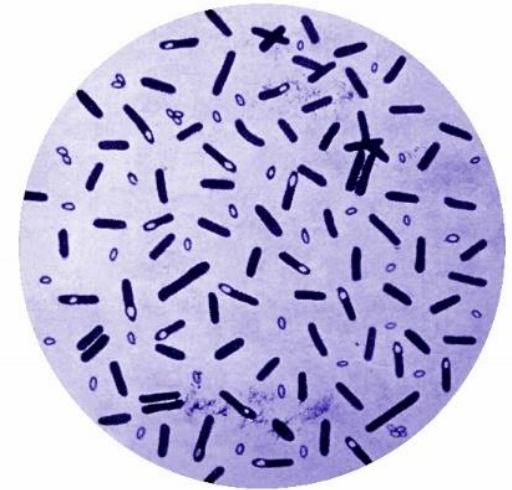


Clostridium botulinum

Morphology



- **Gram-positive large straight rods, motile, non-capsulated**
- **Spore-forming which is oval, central, or subterminal**
- **Found in the soil and domestic animal intestines**
- **Obligatory anaerobe**



Botulinum toxin



❖ Botulinum toxins

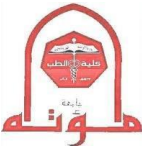- Seven different types of neurotoxins: A to G
- Four of these (types A, B, E, and rarely F) cause human botulism. Types C, D, and E cause illness in other mammals, birds, and fish.
- All cause flaccid paralysis
- Only a few nanograms can cause illness
- The most lethal known toxin
- Destroyed by boiling

Botox is a commercial preparation of exotoxin A used to remove face wrinkles

❖ Mode of action

Neurotoxin production > stomach absorption > circulation > Neuromuscular junction (NMJ) > inhibition of acetylcholine release at the neuromuscular junction > flaccid descending motor paralysis

Clinical forms of botulism



➤ Food-borne botulism

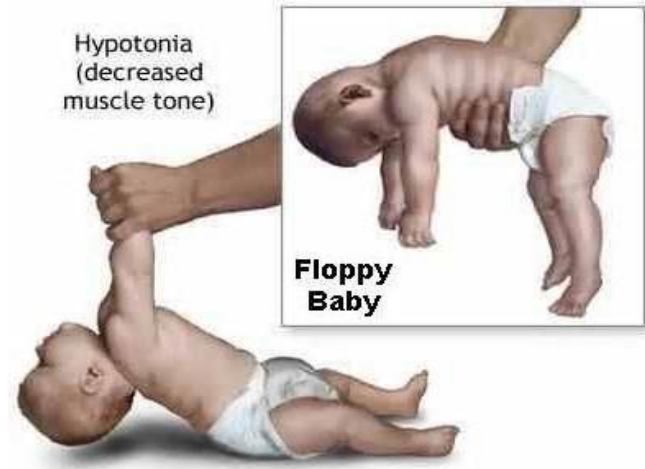
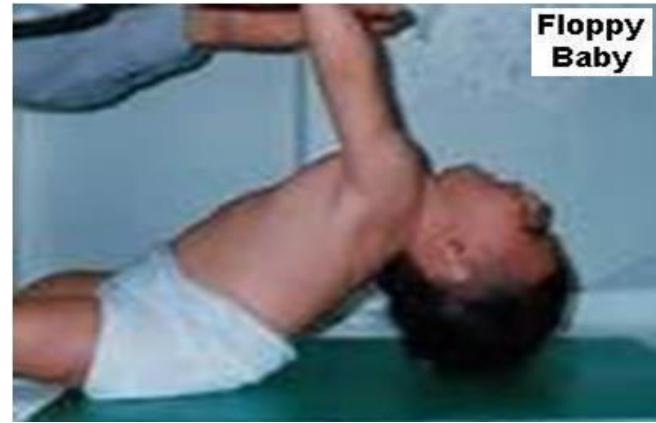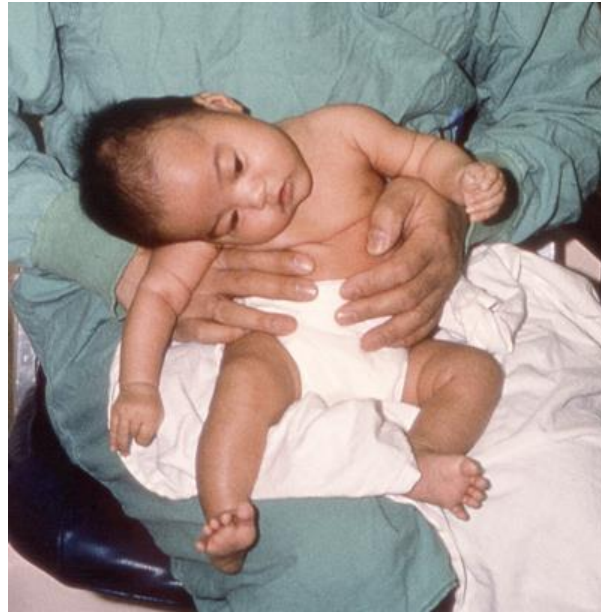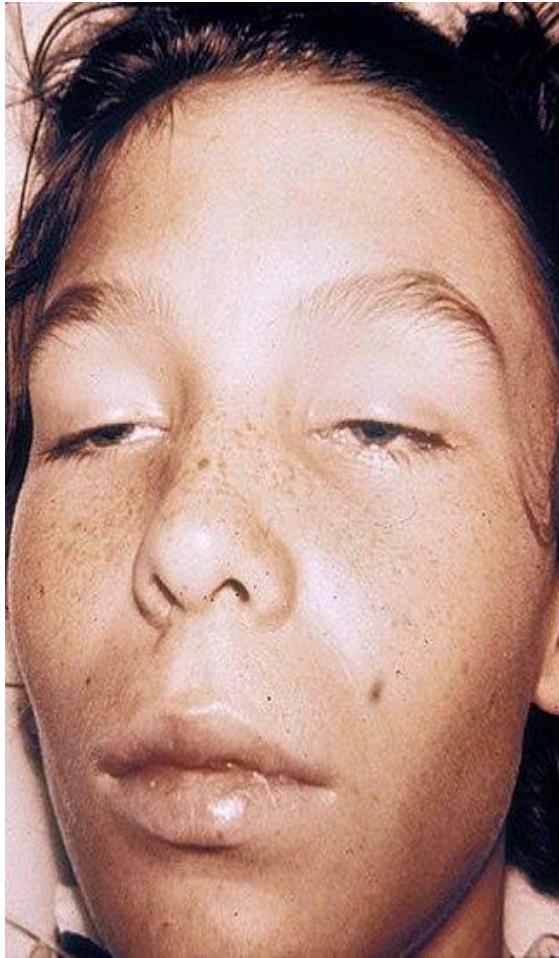- Occurs when *C. botulinum* grows and **produces toxins in food prior to consumption**
- Food commonly responsible include home-canned food, canned green beans, mushrooms, and tuna fish
- No fever may be nausea and vomiting
- Muscle paralysis leads to **diplopia, dysphagia, and respiratory muscle paralysis**

➤ Wound botulism

- Wound botulism is rare
- Caused by contamination of wounds with *C. botulinum* spores, subsequent spore germination, and toxin production.
- This form of the disease has been associated with substance abuse, particularly when injecting black tar heroin.
- The symptoms are similar to foodborne botulism but may take up to 2 weeks to appear.

➤ Infant botulism

- Occurs due to ingestion of spores in baby's food where they germinate in the gut and produce the toxin (intestinal flora not well developed yet)
- Affects infants below 1 year (94% below 6 months) causing **floppy child syndrome**
- They develop **constipation**, poor feeding, muscle weakness, and finally muscle paralysis



Diagnosis



- **History ??**
- **Clinical ??**
- **Laboratory:**
 - **Toxin detection in patient serum, food remnants, or bowel contents by immunological tests (e.g., ELISA) or animal inoculation.**
 - **Culture to detect organisms is rarely done.**

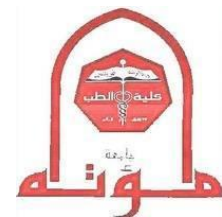Treatment



- **Once botulism is suspected, treatment should be started immediately.**
- **Trivalent antitoxin (types A, B, and E) is given.**
- **Respiratory support**
- **Wound care**

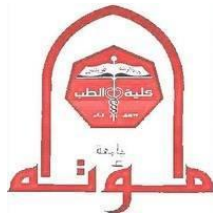Prevention

- **Proper cooking and heating of food**
- **Avoid suspicious canned food (swollen cans)**
- **Proper processing, preservation, and canning of food**



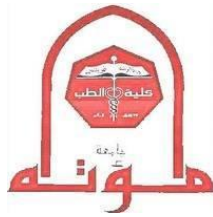QUIZ TIME





❖ Case 1

- A 4-year-old boy presented to the hospital with a one-week history of general malaise, and progressive anorexia. Three days prior to hospital presentation, he had started to refuse all food and fluids, accompanied by progressive dysphagia and difficulty in opening the mouth.
- **History:** revealed that the boy had recently injured his left big toe. This had resulted in a small local hematoma and loose toenail
- **Physical examination:** afebrile, irritable and anxious boy gently playing at the table, with trismus and mild dehydration. After being asked to walk, he showed muscle spasms of the back and thighs evidently worsening during examination



❖ Case 2

A twenty-one-year girl student had spent a day with her grandparents. During her drive back to the campus, her vision became blurry, and she was forced to pull over to the side of the road. As she sat in her car, her vision worsened. She opened the car hood in hope of attracting aid and tried to relax. In a short time, a highway officer pulled over and approached her. By this time, she was having trouble swallowing and speaking clearly. The officer took her to the emergency hospital.

- **History:** The girl described that she ate with her grandparents and that all the food was homemade and canned by her grandmother.
- **Physical examination:** the patient was lethargic and unable to breath