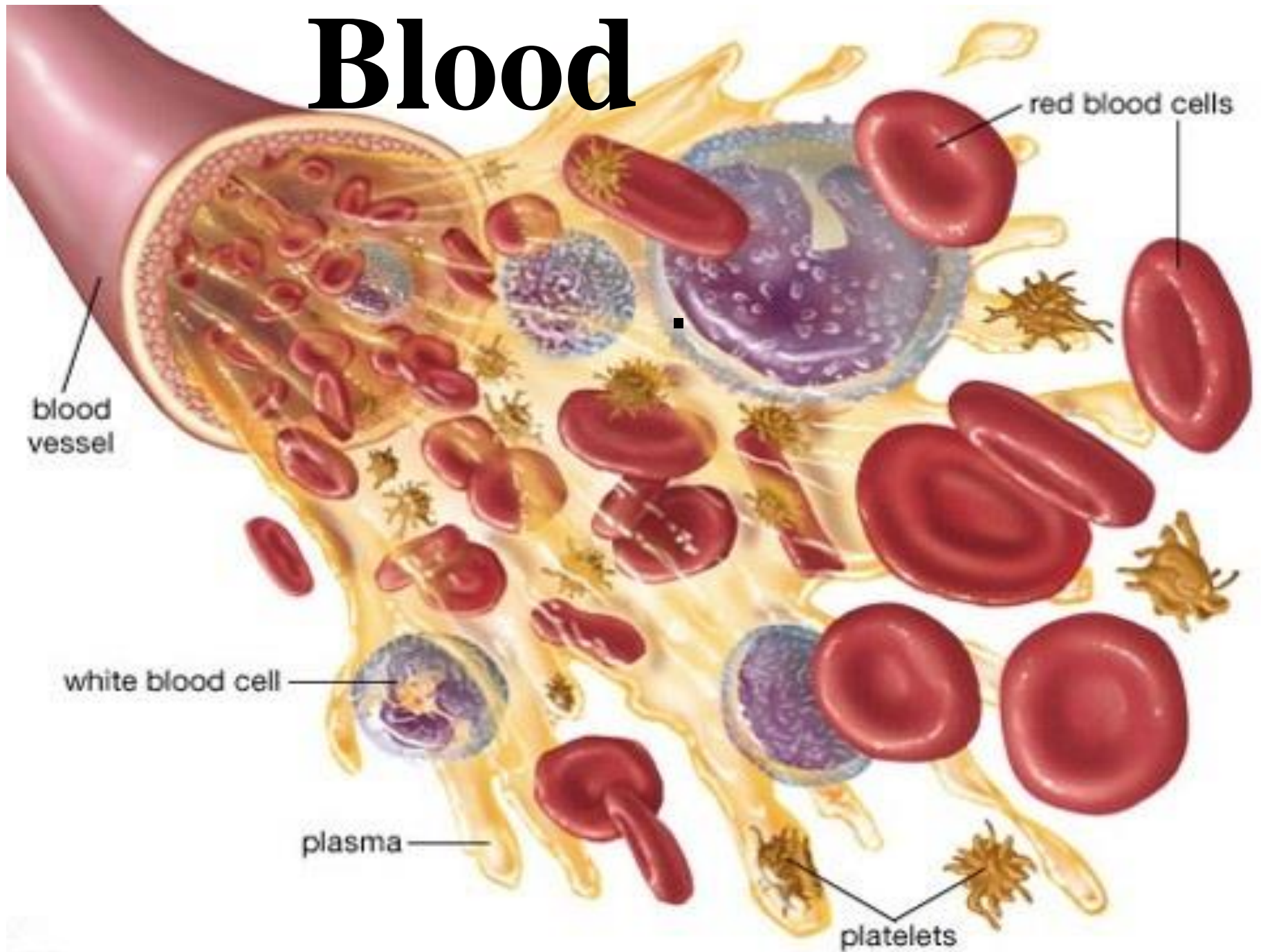


Blood



Connective Tissue



C.T. proper

- Loose C.T.
- Adipose C.T.
- Reticular C.T.
- Dense C.T.
- Elastic C.T.
- Muroid C.T.



Modified C.T.

Ground substance is modified

- Solid nature** = supporting C.T.
 - Cartilage (firm)
 - Bone (hard)
- Fluid nature** (plasma)
 - Blood

Blood


Modified CT

- ❑ Adult has ~ **5.5 -6 L**
- ❑ Circulate in **CVS**
- ❑ Considered **modified** connective tissue :

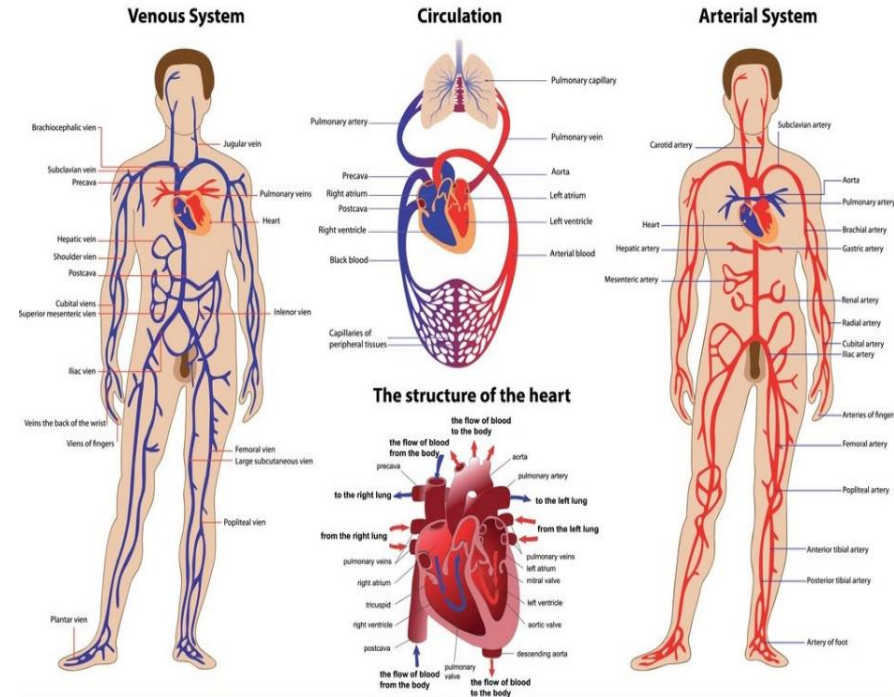
➤ Mesodermal in origin

➤ cells

➤ liquid ground substance (called plasma)

➤ dissolved protein fibers (fibrinogen)  fibrin

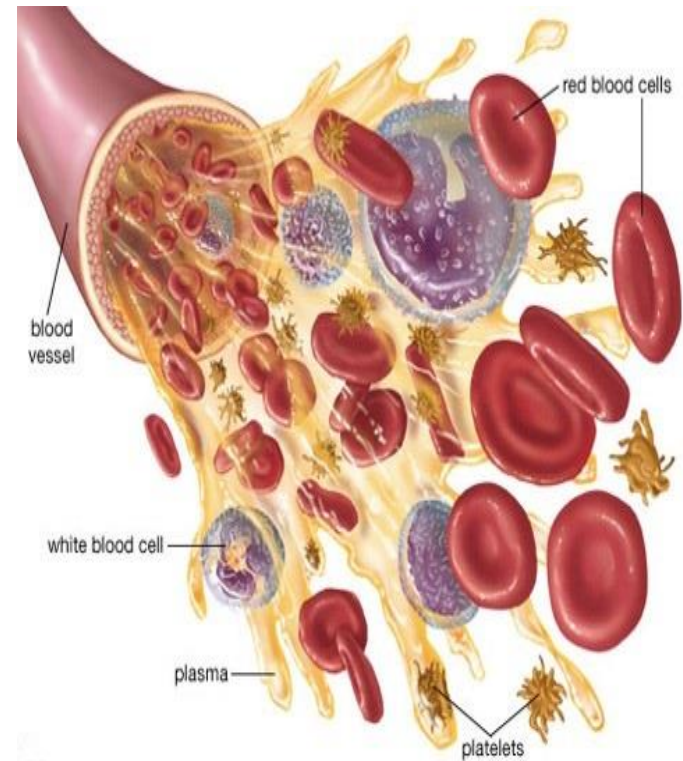
CARDIOVASCULAR SYSTEM

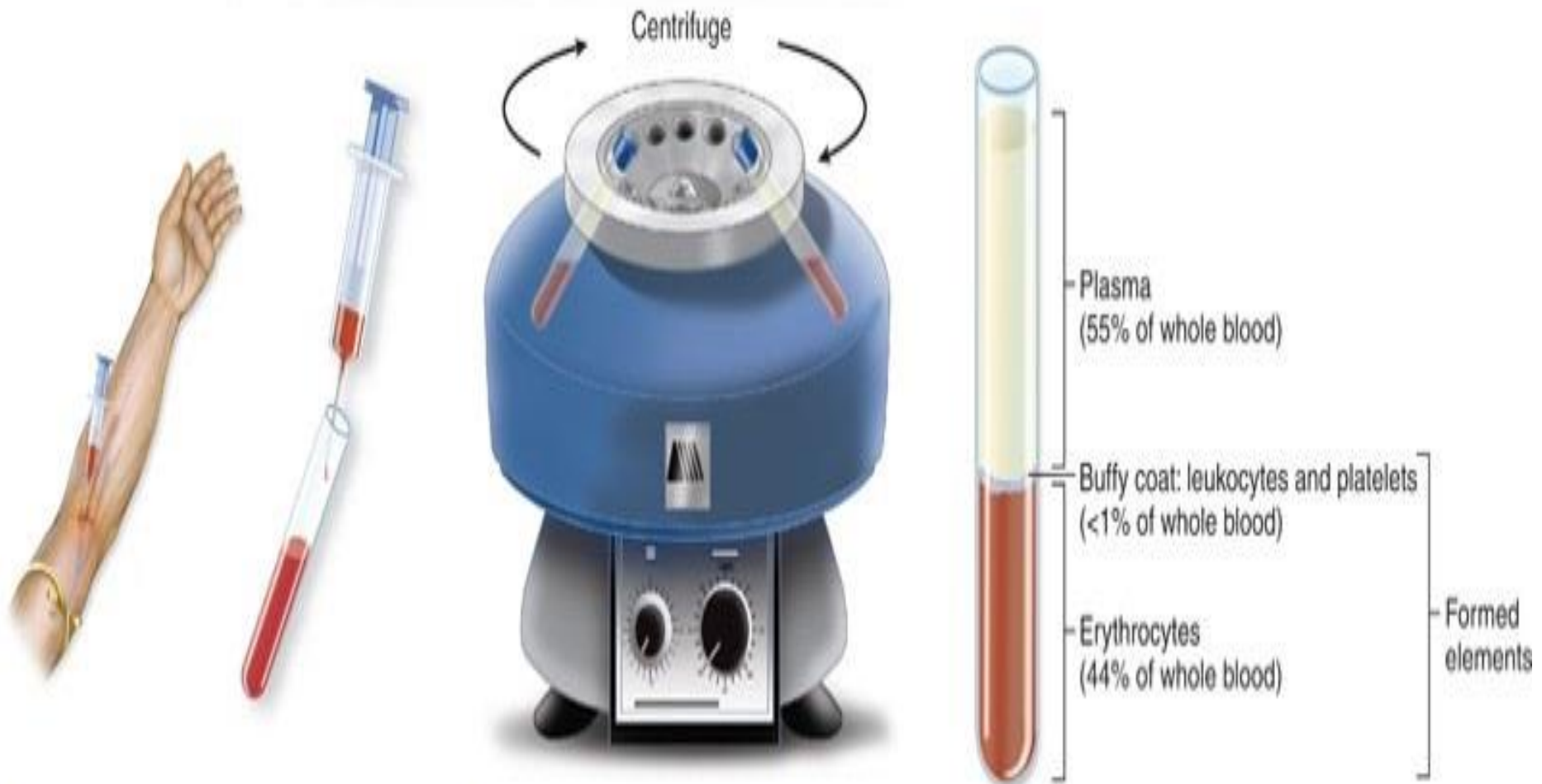

BLOOD

Consists of **liquid** and **cellular** components by a machine called a **centrifuge**.

- ❑ **Plasma: 55%**
- ❑ **Cells = Formed Blood elements 45%**
 - **Originate in the red bone marrow**
 - **Blood formation = hematopoiesis**
- ❑ **No aberrant fibers.**

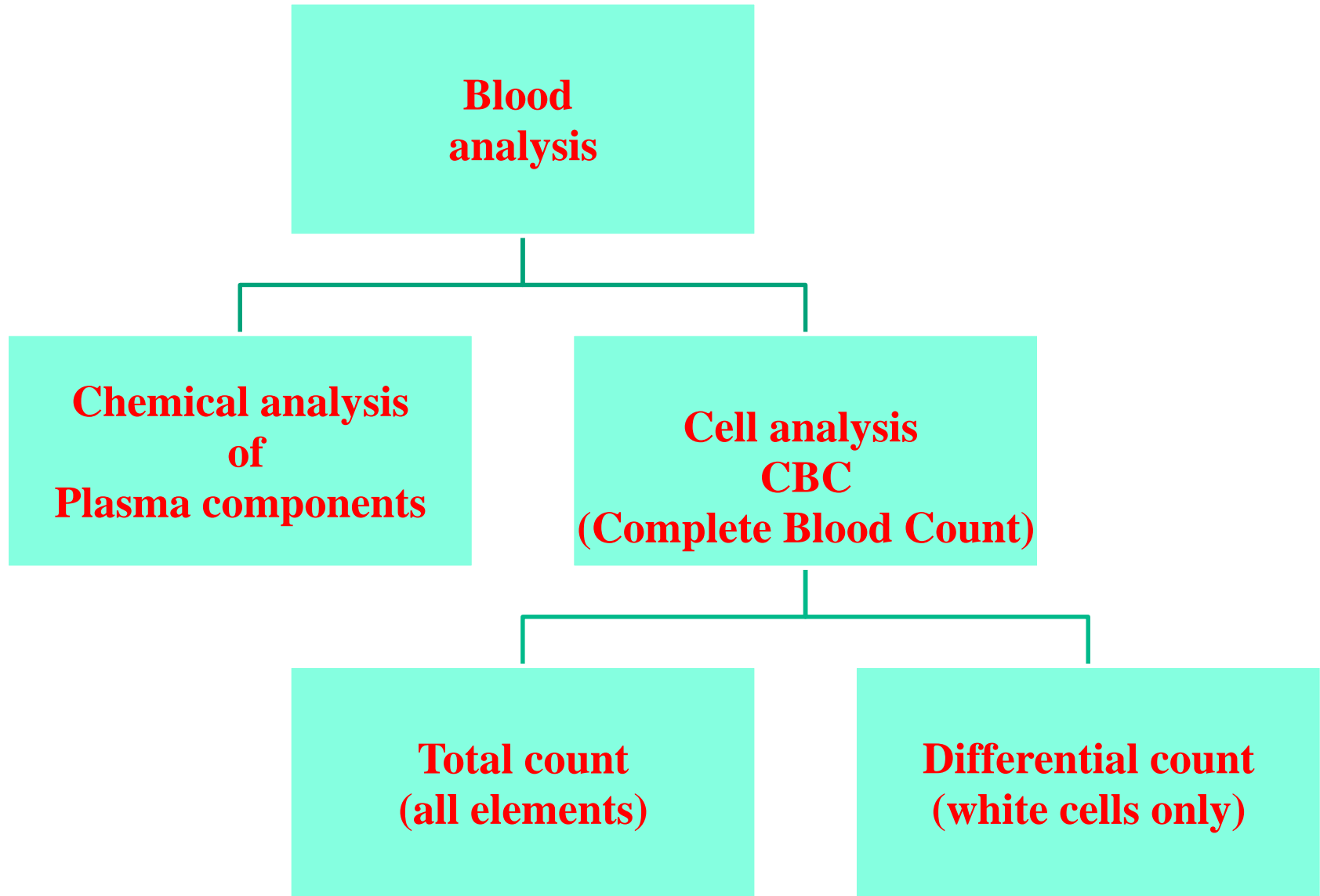




① Withdraw blood into a syringe and place in a glass tube.

② Place the tube into a centrifuge and spin for about 10 minutes.

③ Components of blood separate during centrifugation to reveal plasma, buffy coat, and erythrocytes.



Plasma

55% of blood volume:

❑ **Water 92%.**

❑ **Organic substances:7 %**

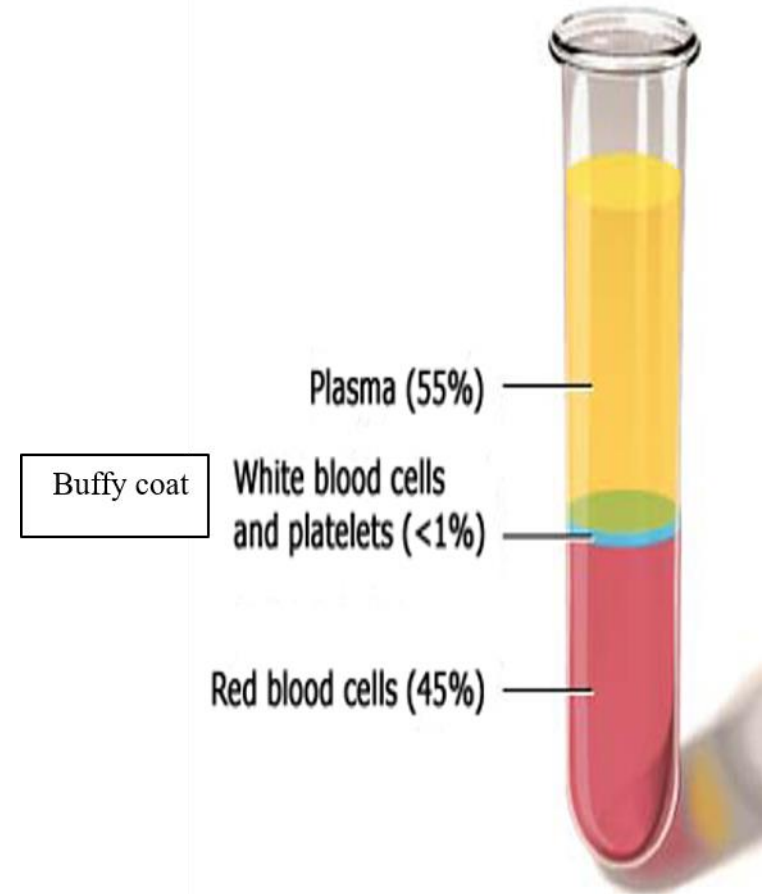
➤ plasma proteins

(albumin, globulin, prothrombin and **fibrinogen**)

➤ Hormones & enzymes.

❑ **Inorganic salts 1%**

(Na Cl, Bicarbonates, phosphates & calcium)



The Blood Film= Smear

Preparation of blood for laboratory study

- Why do we do a blood film ?
 - 1.To study blood elements.
 - 2.To make differential leukocytic count.

Steps :

- Put a small drop of blood
- Spread into a thin film
- Stain with Leishman or Giemsa stain
(methylene blue +eosin)

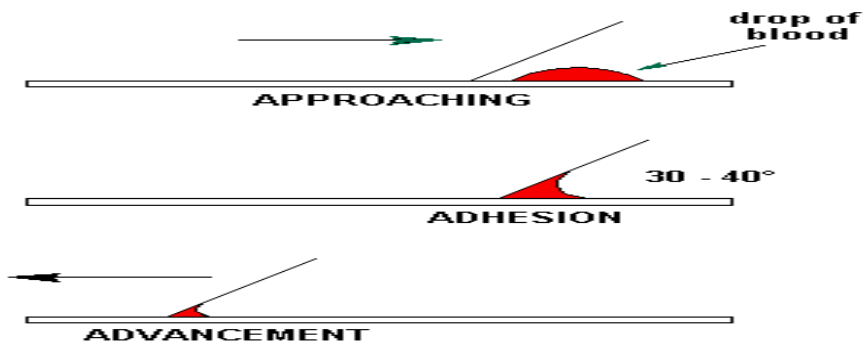
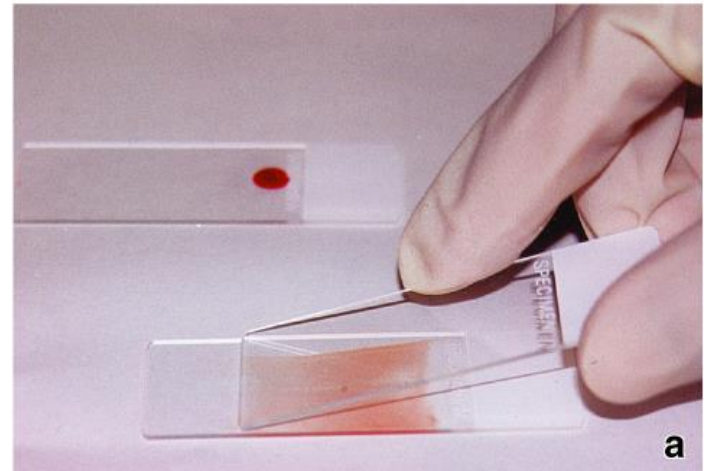


Fig. 7 - How to prepare a blood smear



Blood film

Why do we do a blood film ?

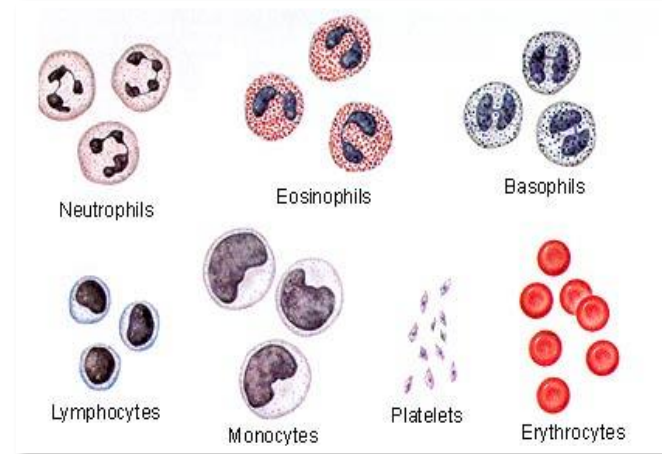
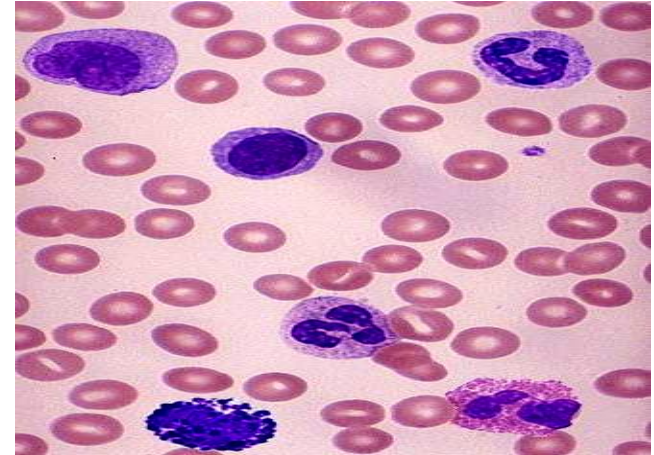
- 1.To study blood elements.
- 2.To make differential leucocytic count.

Steps :

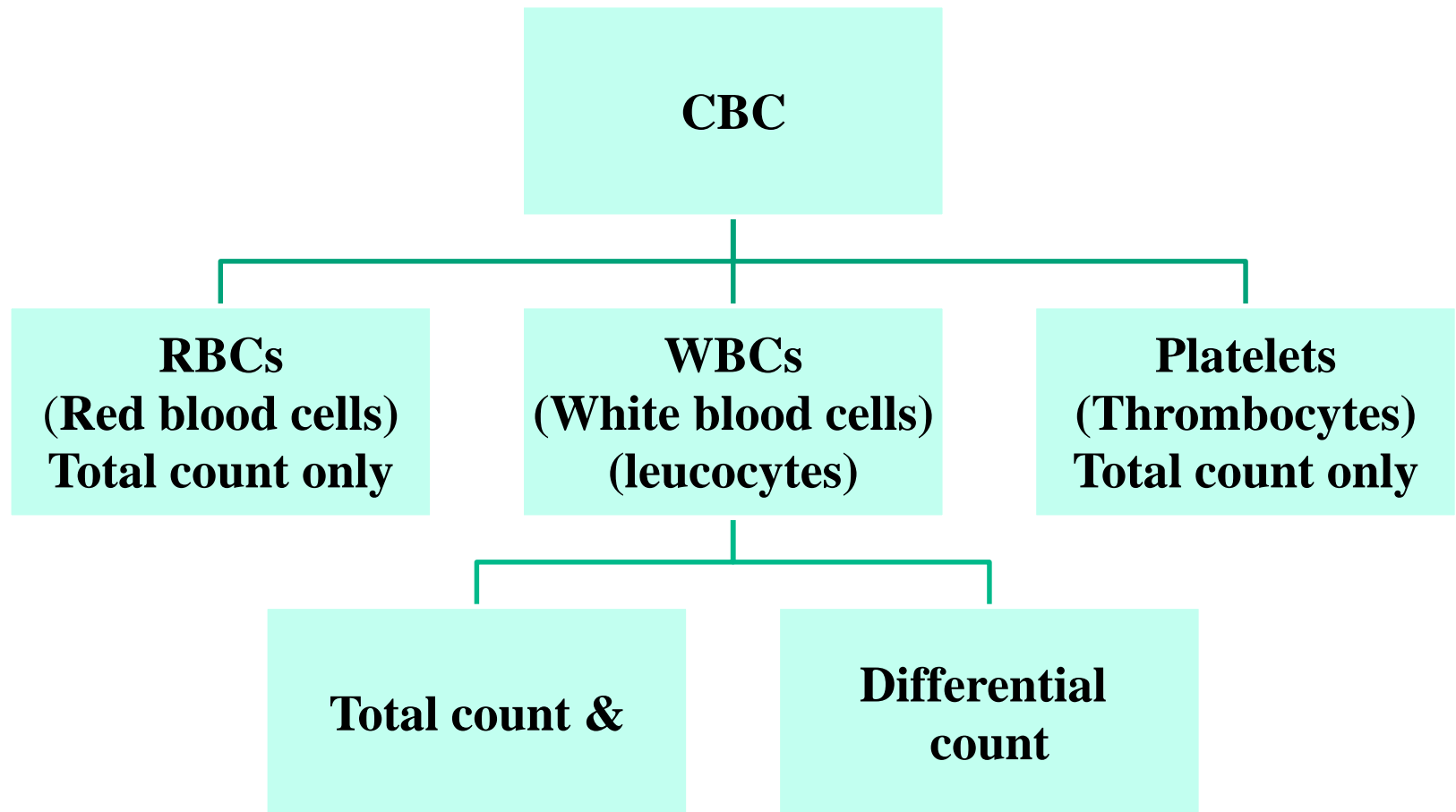
- Put a small drop of blood
- Spread into a thin film
- Stain with Leishman or Giemsa stain
(methylene blue +eosin)

Giemsa's / Leishman's = methylene blue + eosin

- ▶ basophilic (violet)
- ▶ eosinophilic (pink)
- ▶ azurophilic (red purple)



Complete blood count (CBC)



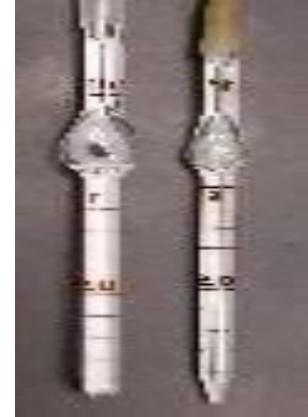
Complete blood count (CBC)

1-Total count :

It is the total number of blood elements (RBCs, WBCs, or Platelets) per cubic millimeter

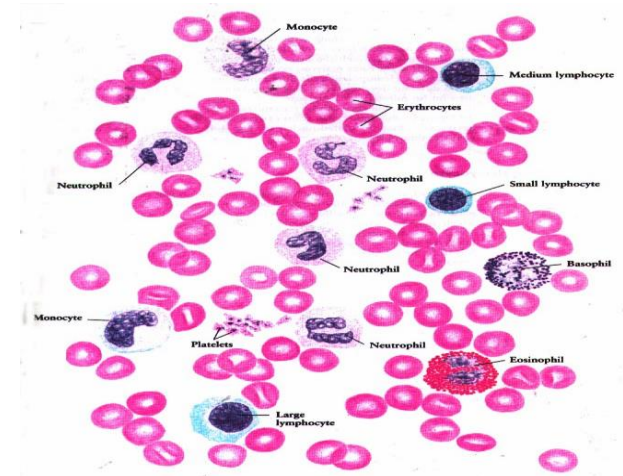
Measured by

- Hemocytometer
- Or Automatic counter



2-Differential leukocytic count

- the percentage of each type of leucocytes to the total count



Blood cell count=CBC


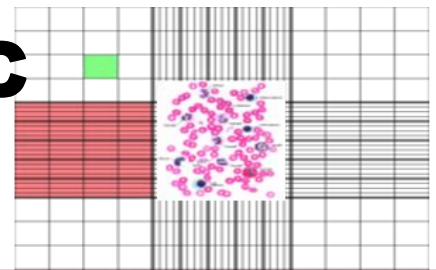
- **Manual method= Conventional**
=Hemocytometer= counting chamber.

- **Electronic method**
= automated hematology analyzer.

Total count

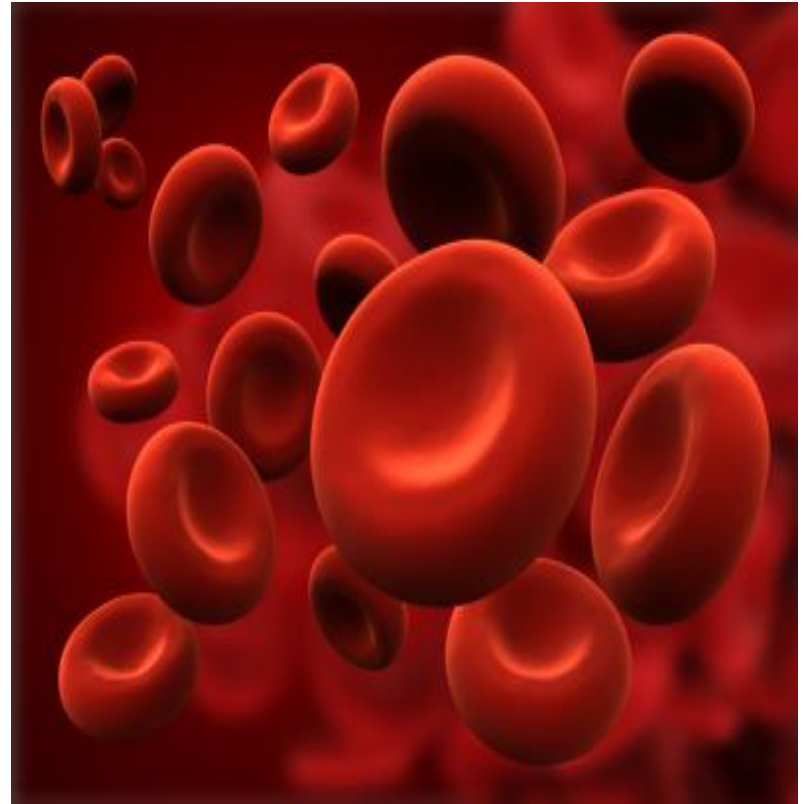
- ❑ RBC count 4.5-5 million/mm³ in female
- ❑ Total leukocytic count 4,000-11,000/mm³
- ❑ Platelet count 250,000- 350,000/mm³

Differential leukocytic count



Blood cells

1. Total or Differential count
2. Shape & size
3. Structure (nucleus + granules)
4. Function
5. Life span
6. Abnormalities



Red Blood corpuscles

Normal RBCs total count:

- In males ♂ 5- 5.5 millions / mm³ blood
- in females ♀ 4.5-5 millions / mm³ blood

LM of RBCs:

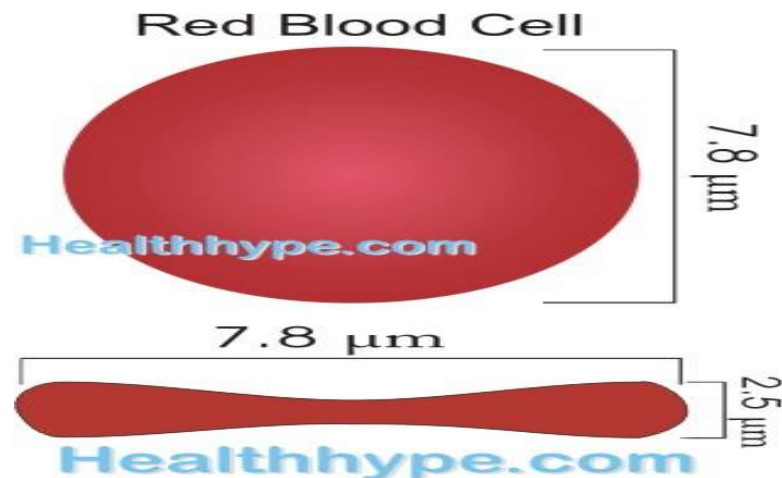

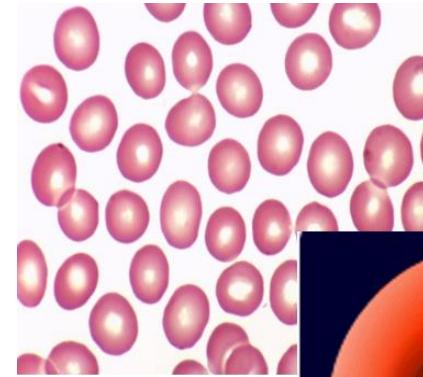
- ❖ Shape: - Biconcave discs.
- Mature RBCs are membrane- bound corpuscle.

❖ Size:

- -Diameter 7.5 μm
- -Thickness 1 μm

❖ Nucleus: Anucleate.

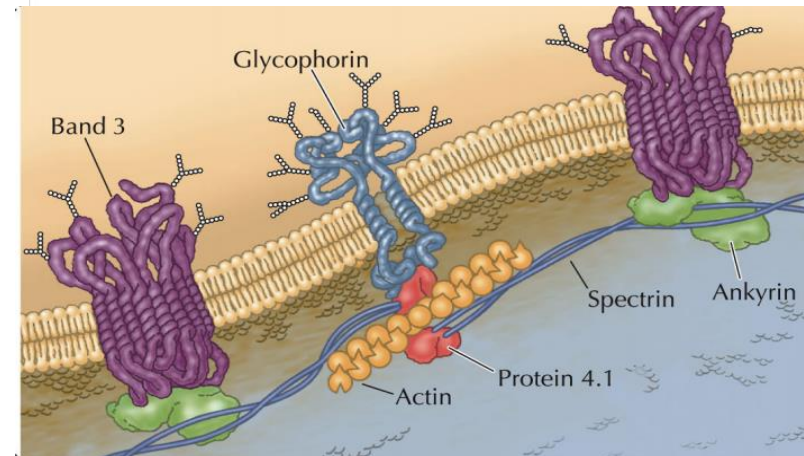
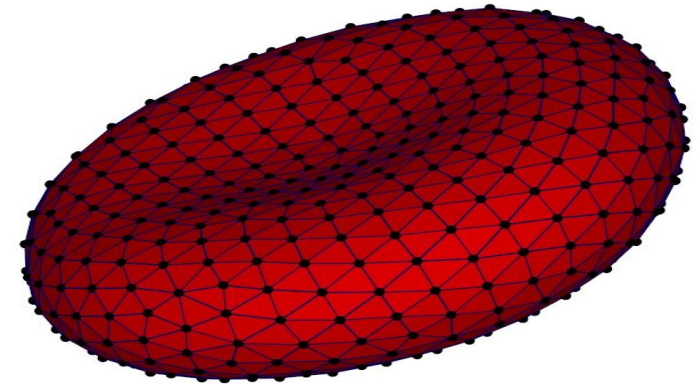
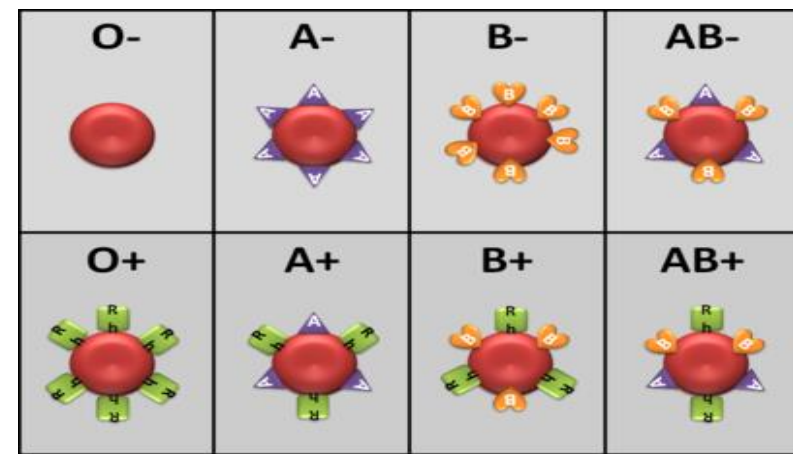
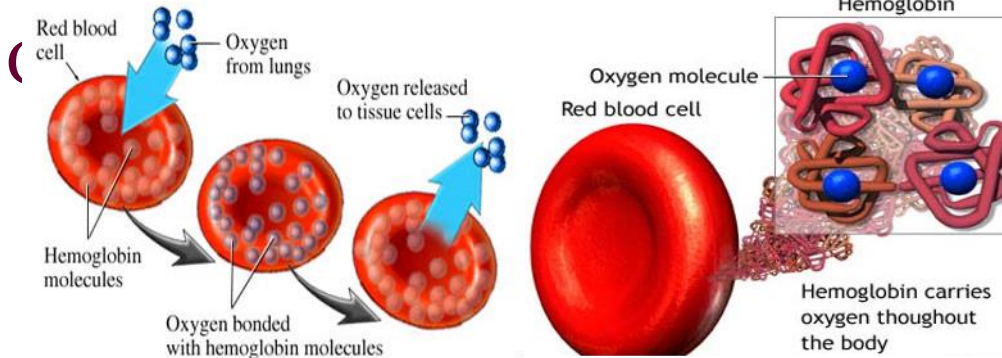
- ❖ Cytoplasm **33%** of the corpuscular volume is Hemoglobin = heme “Fe”+ Globin ‘protein’



EM picture of RBCs:

- **Glycocalyx**
- responsible for the **ABO/ Rh** blood group.
- **No** nucleus, **No** typical organelles.
- Only few mitochondria
- subplasmalemmal **cytoskeleton**
- (**actin, spectrin & ankyrin**) responsible for the flexibility of RBCs.

➤ **Function of RBCs**



life span:

- **100-120 days**

Then removed by Macrophages of spleen and liver sinusoids

Adaptation to function

1. **Glycocalyx well developed**

2. ▲ surface area (Biconcave)

3. ▲ amount of HB

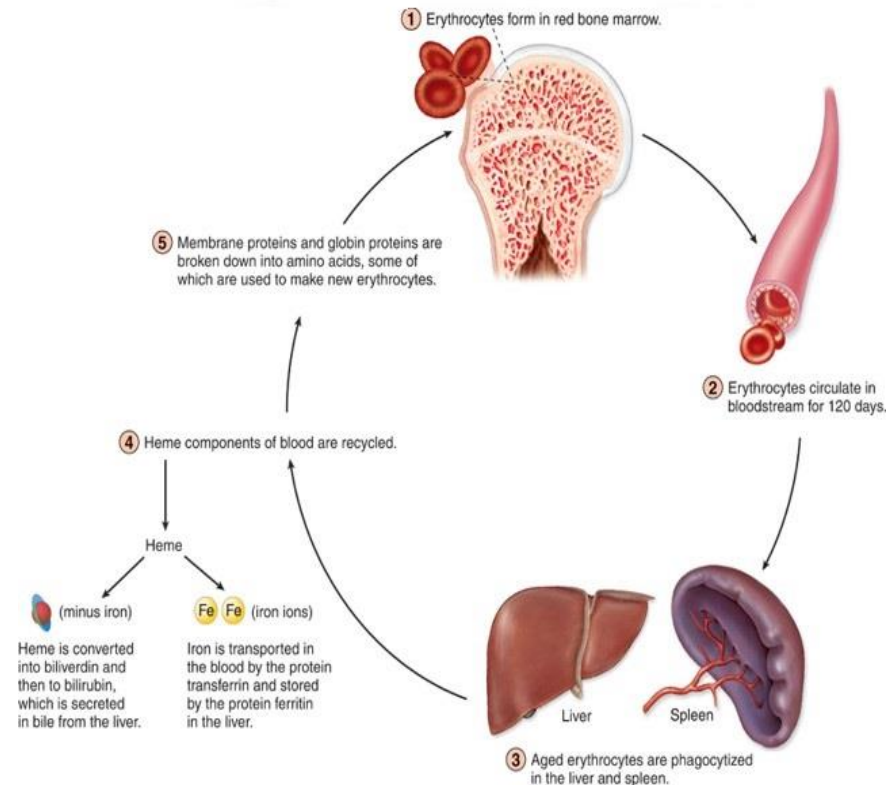
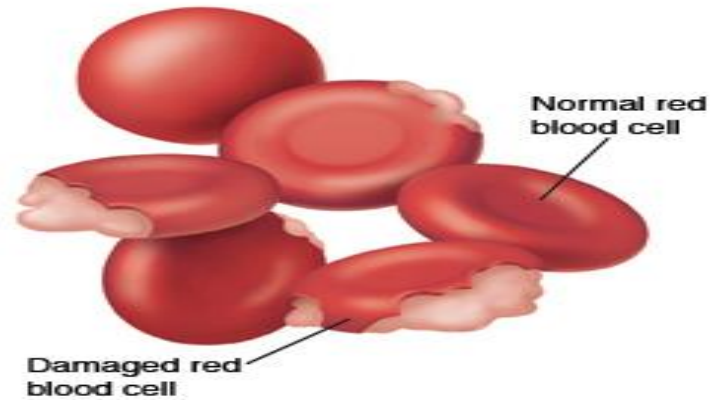
(no nucleus/ organelles)

4. ▲ ▲ HB at the periphery

5. Selective permeability

6. Carbonic anhydrase

7. ▲ flexibility to squeeze without damage (cytoskeleton)



Abnormalities of RBCs

Abnormalities of RBCs in **number**

□ **Anaemia:**

Decrease ??? in the total number of RBCs.

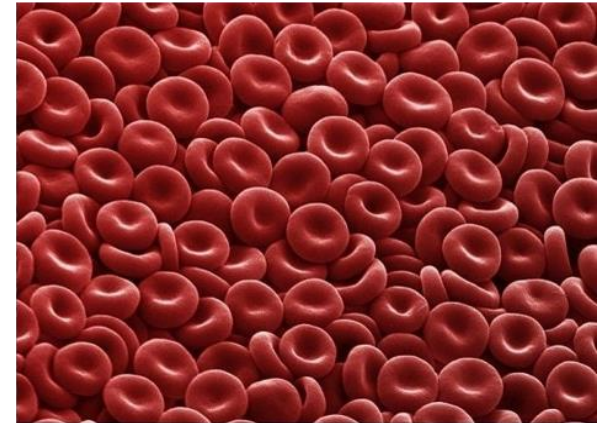
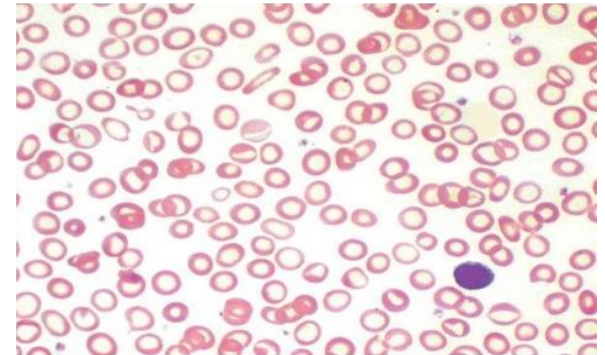
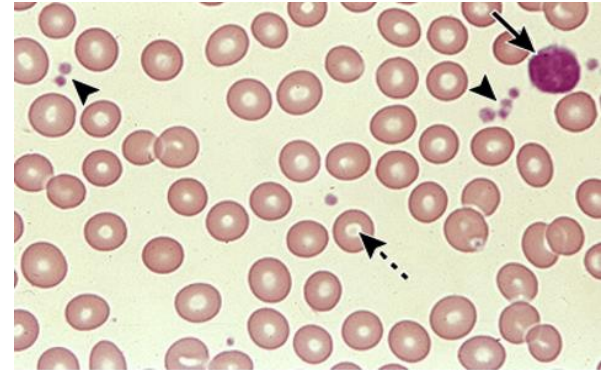
□ **Polycythaemia:**

increase in the total number of RBCs.

Causes: (decreased oxygen tension)

Physiological: newborns ,high altitude

Pathological: chronic lung and heart diseases.



Abnormalities of RBCs in size

□ Microcytosis:

diameter of RBCs is **less than $6\mu\text{m}$** .

(Microcytic anaemia)

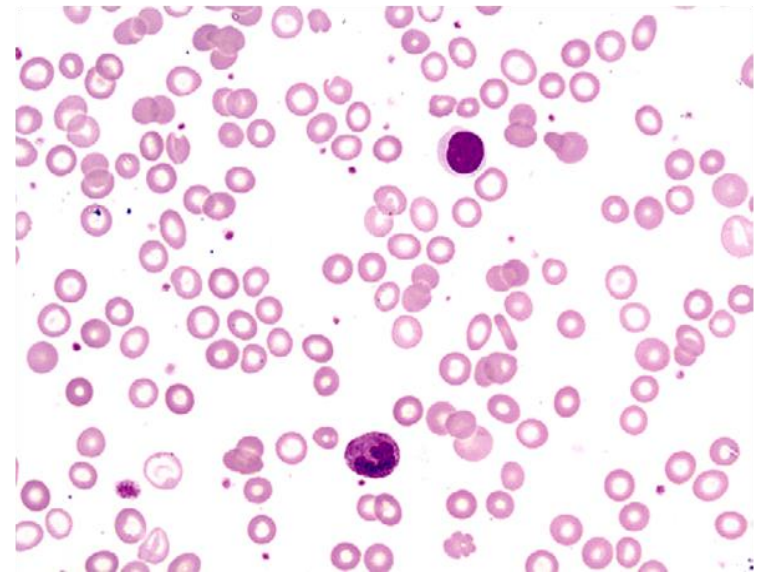
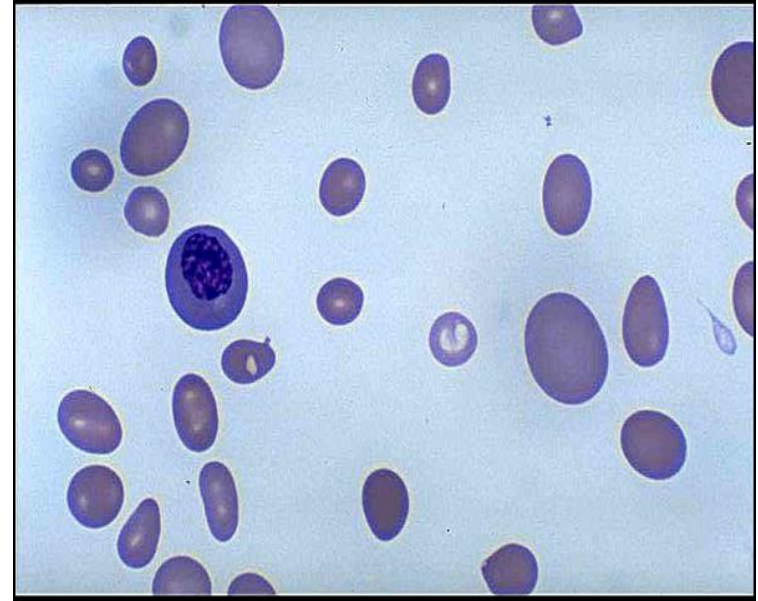
□ Macrocytosis

diameter of RBCs is **more than $9\mu\text{m}$** .

(Macrocytic anaemia)

□ Anisocytosis

Variable in size



Abnormalities of RBCs in shape

1. Rouleaux formation

In slow circulation

2. Poikilocytosis

Variable in shape

3. In hypertonic solution

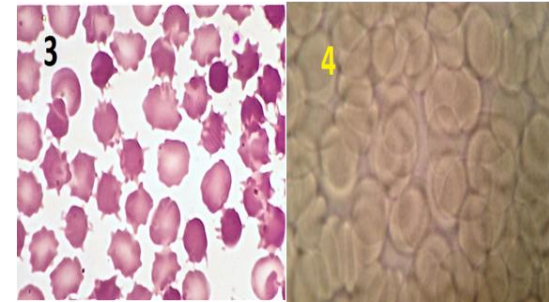
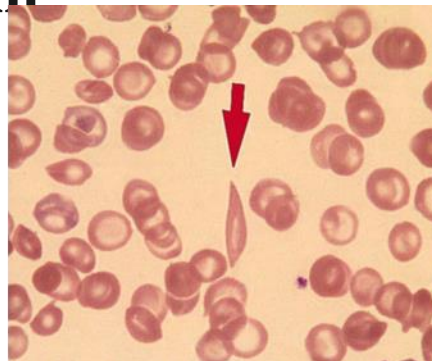
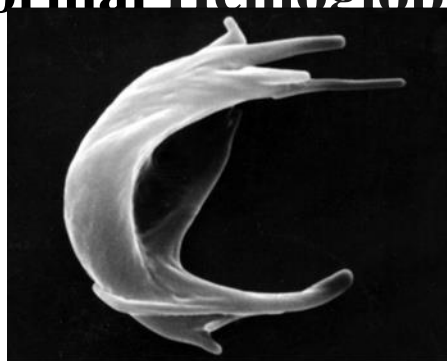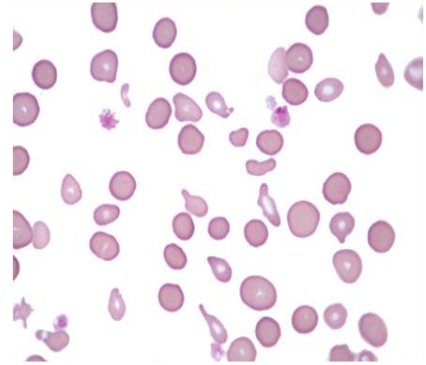
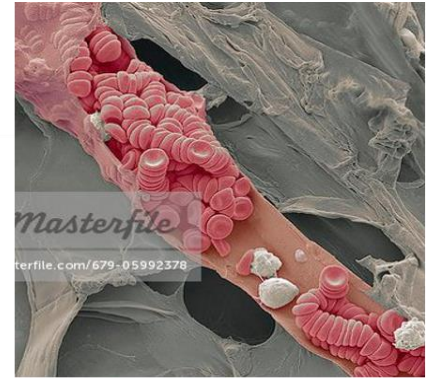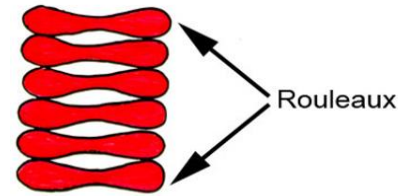
▶ echinocytes(crenation)

4. In hypotonic solution= swelling

▶ Ghosts

5. Sickle Cell Anemia

(abnormal Hemoglobin



Reticulocytes = immature RBCs

- Reticulocytes represent 1% of all RBCs in normal blood film.
- Nucleated → No nucleus

differ than mature RBCs

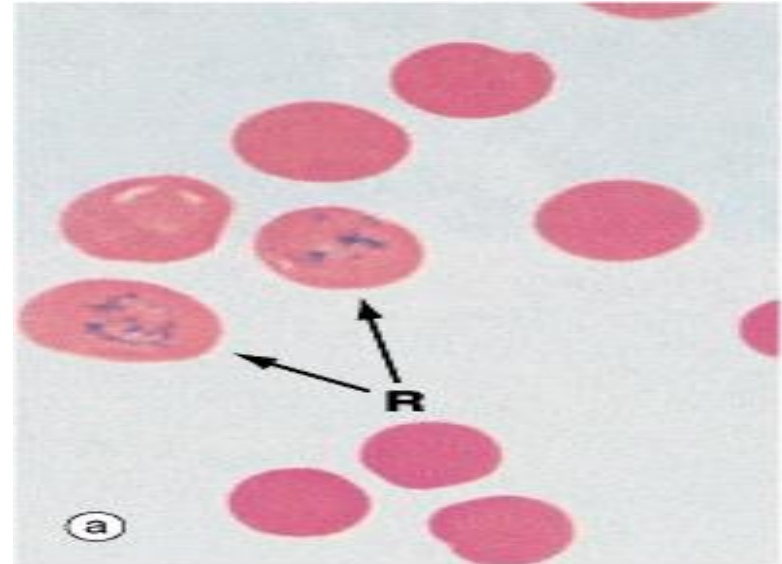
- slightly larger (8 μ m).
- Cytoplasm contains remnants of ribosomes.
- On staining with **cresyl blue** form a reticulate pattern.

Clinical significance:

An increase in this percentage indicates an

- accelerated rate of erythropoiesis.

To compensate for anemia or severe hemorrhage.



BLOOD PLATELETS

Origin: from megakaryocyte in the bone marrow.

- Cell fragments of megakaryocyte.
- Thrombocytes.
- Thromboplastids

❖ **Normal Platelet Count**

250,000-350,000/ mm³
(200,000-400,000)

Structure (L. M) :

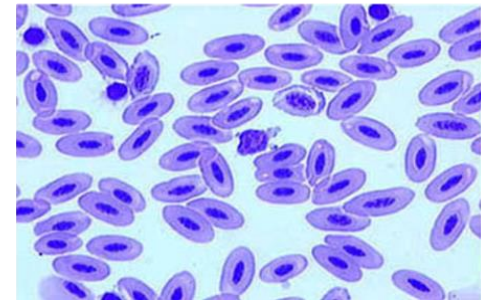
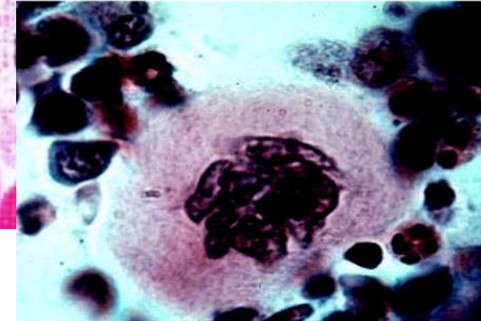
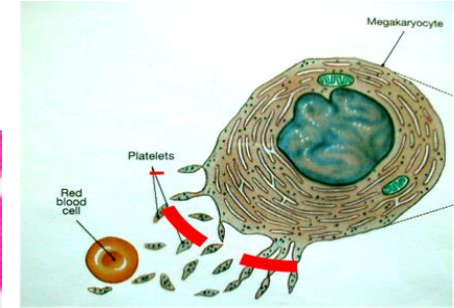
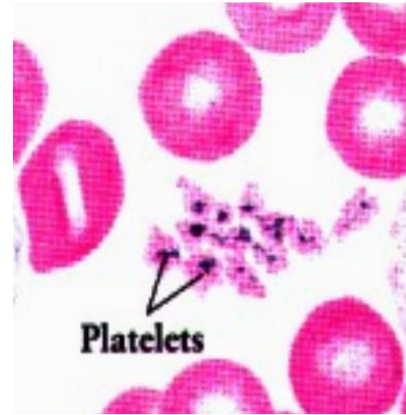
- **Shape:** Anucleate, biconvex discs.
- **Diameter** :2-3 μm.

central granular zone (**granulomere**)

Granulomere, granular central region

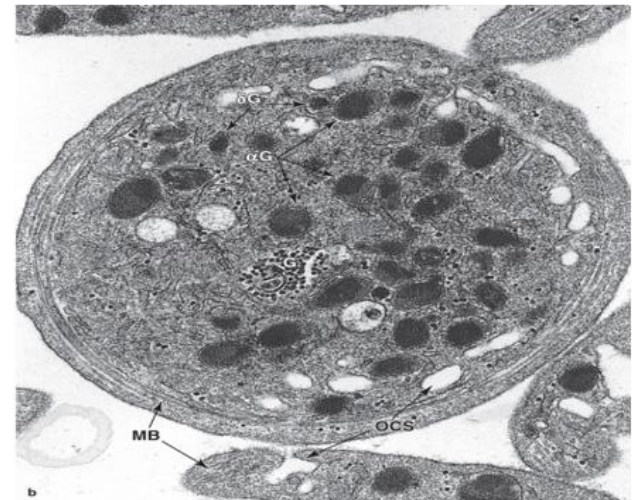
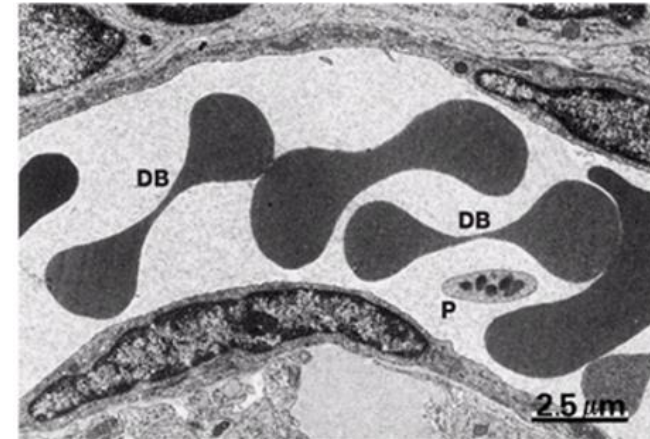
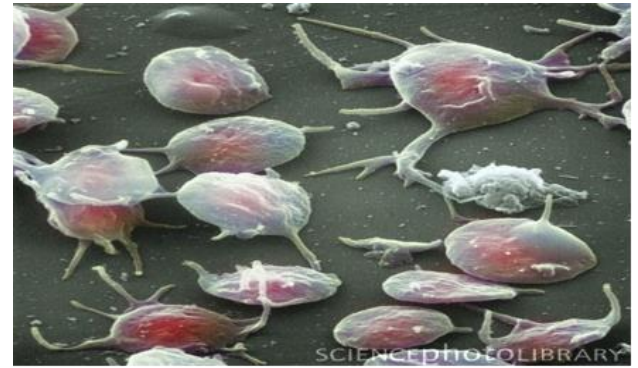& peripheral clear zone (**hyalomere**)

Hyalomere at the periphery, there is a pale basophilic zone



EM of the platelet :

- Shape: Irregular, Pseudopodia.
- Diameter :2-3 μm .
- Shape: Anucleate, biconvex discs.
- Platelet membrane:
 - ▲▲ well developed cell coat glycoprotein for:
 - **Adhesion**
 - **Aggregation**
- **Hyalomere &granulomere**



Granulomere

- few mitochondria & ribosomes.
- scattered glycogen particles.
- 3 types of granules:

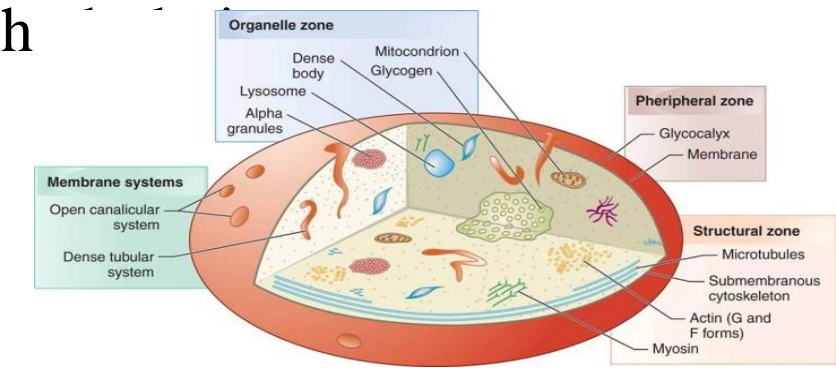
❑ Alpha (α) granules:

- Large, abundant, PD-GF, coagulation factors.

❑ Delta granules:

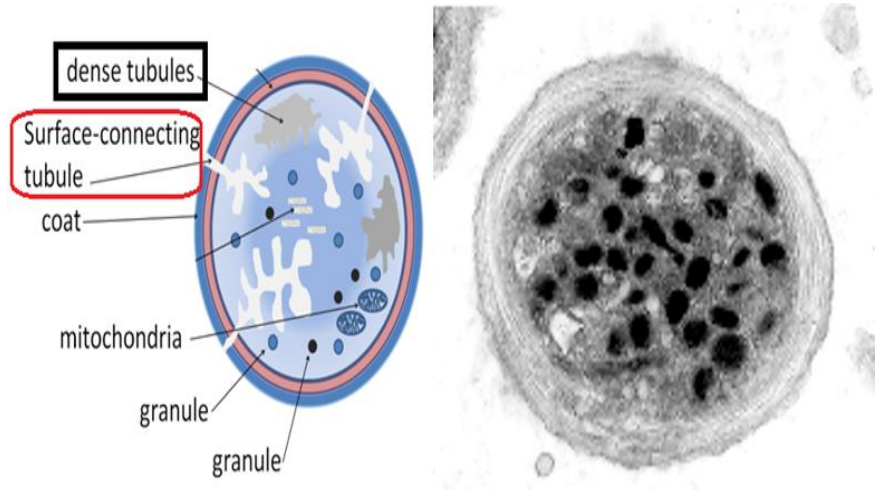
- Medium size, ATP, ADP, serotonin.

❑ Lambda (λ) granules:



Hyalomere

- Electron- lucent.
- Lacks organelles.
- It contains:
 - **circumferential bundle of 10-15 microtubules** ▶ ▶ discoid shape
 - **Actin & myosin** ▶ ▶ motility + clot retraction
 - **Canalicular system =tubular**



Functions of platelets

- Platelet aggregation → white thrombus
- Local blood coagulation → red thrombus
- Serotonin → Vaso-constriction
- **Clot retraction** → by microfilaments
- Clot removal → by **proteolytic enzymes**

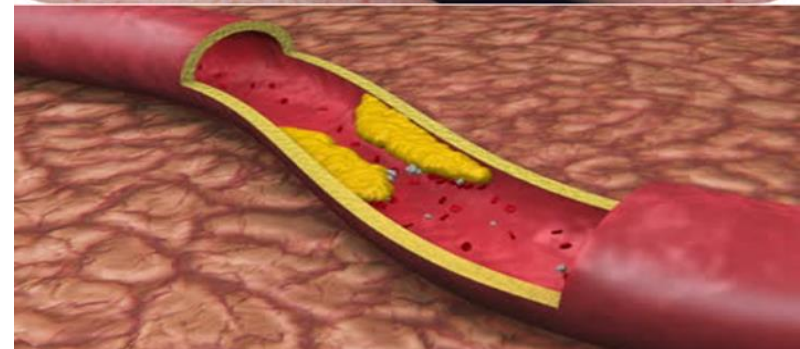
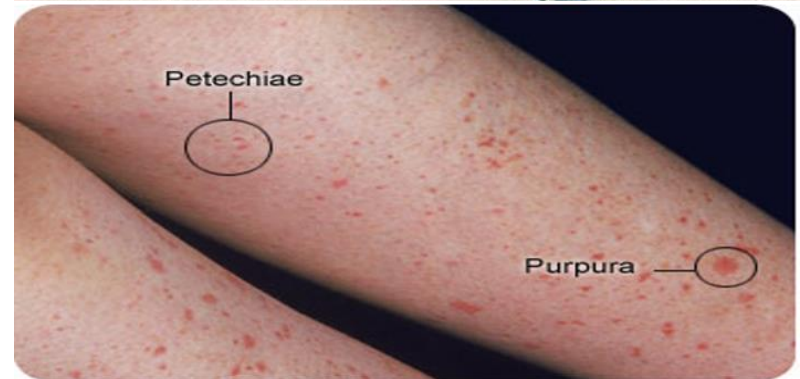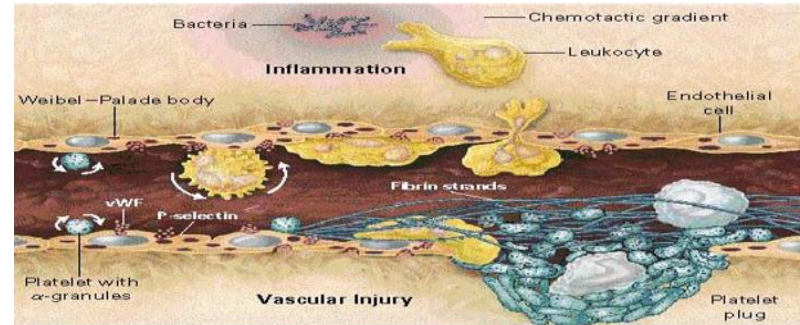
Life span: 10- 14 days in blood

Abnormality of the platelets :

Thrombocytopenia ▼ ▼ ▼

Thrombocytopenia (purpura)

▲ ▲ ▲ **Thrombocythemia**



RBCs

Red blood corpuscle

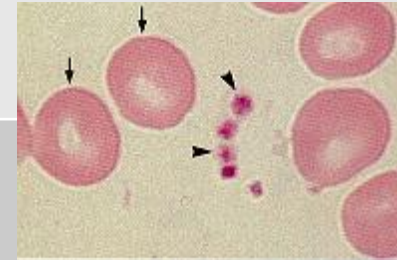
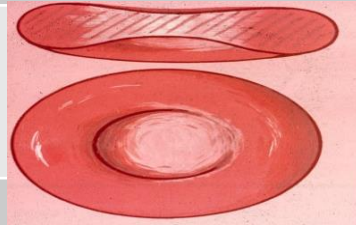
Erythrocytes – Greek: “Red

Platelets

Thrombocytes

Thromboplastides

Number	<u>males</u> is 5 - 5.5 millions / mm ³ <u>females</u> it is 4.5-5 millions / mm ³ blood.	250,000-350,000/mm ³ 200,000- 400,000
Size	7.5–8.5 μm Macrocytes > 9 μm, Microcytes < 6 μm Anisocytosis = variation in si	3μm 2-5 μm diameter
Shape	biconcave disc	Biconvex
Structure	no nuclei & other organelles only few mitochondria Bag of Haemoglobin	Fragments of megakaryocyte Not true cell (Non-nucleated) Granulomere & Hyalomere
Life span	100-120 days..	10- 14 days in blood
Function	Carry O ₂ & Co ₂	- the process of thrombus formation (blood clotting) in response to any vascular endothelial injury to prevent excessive blood loss. - clot retraction and removal of the blood clot after healing of the vessel wall to re-establish the flow of the blood.
Abnormality	Polycythaemia: i.e. increase in the total number of R.B.Cs. Anaemia: i.e. decrease in the total number of R.B.Cs. Sickle Cell Anemia	INCREASE → Thrombosis Decrease → Bleeding





Lecture 2
Granular leucocytes

The formed blood elements

Stains of blood film

Giemsa's / Leishman's

= methylene blue+ eosin

- ▶ basophilic (**violet**)
- ▶ eosinophilic (**pink**)
- ▶ azurophilic (**red purple**)

Blood cells = 45 % of blood volume

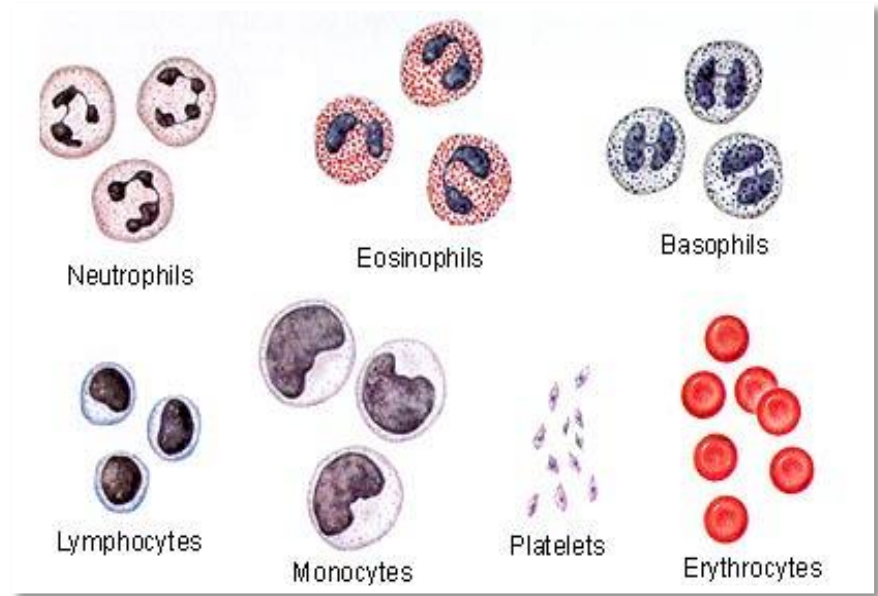
- ❑ Red blood **corpuscles** =Erythrocytes (RBCs)
- ❑ Blood platelets = Thrombocytes
- ❑ White blood **cells** =Leukocytes (WBCs):

➤ Granular leucocytes

(neutrophils, eosinophils, basophils)

➤ Agranular leucocytes

(lymphocytes, monocytes)



Leukocytes (WBCs)

Normal total Count

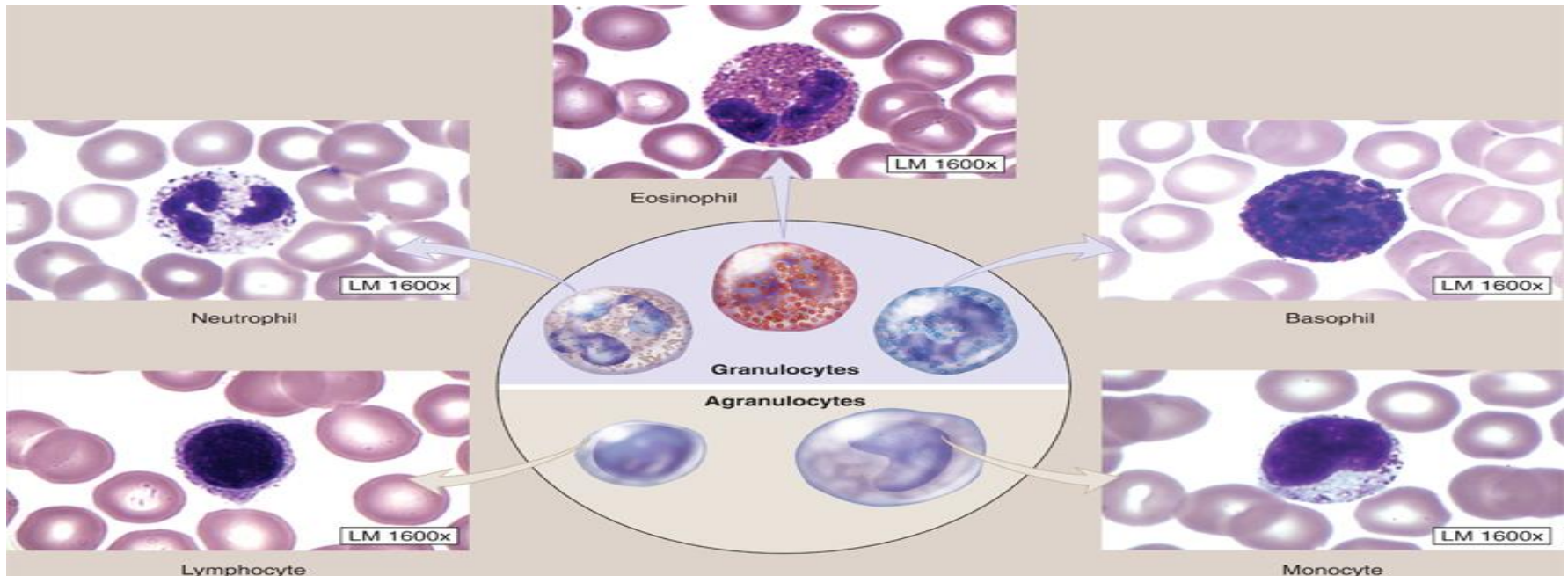
4000-11,000 / mm³ blood.

I-Granular leukocytes:

- Neutrophils. 60-70-%
- Eosinophils. 1- 4%
- Basophils. 1/2- 1%

Agranular leukocytes:

- lymphocytes.20-30%
- Monocytes. 3-8%



Difference between RBCs & WBCs

RBCs

- 4,5- 5million / mm³
- Biconcave
- No nuclei. / no organelles
- Bag filled with hemoglobin
- Life span=120 days
- No amoeboid movement
- Function : carry O₂&CO₂

WBCs

- 4000-11000/ mm³
- Rounded
- Contain (nuclei+ organelles)
- No hemoglobin
- Life span= from **days** to **years**
- Amoeboid movement
- Defense & immunity

Neutrophils= Microphage (polymorphnuclear leukocytes)

Differential count **60-70%**

Size = **10-12** microns

Shape: rounded

LM:

Nucleus : **multilobulated** = 2-8 lobes

Barr body ?? Condensed chromatin
inactive **X- Chromosome in females**

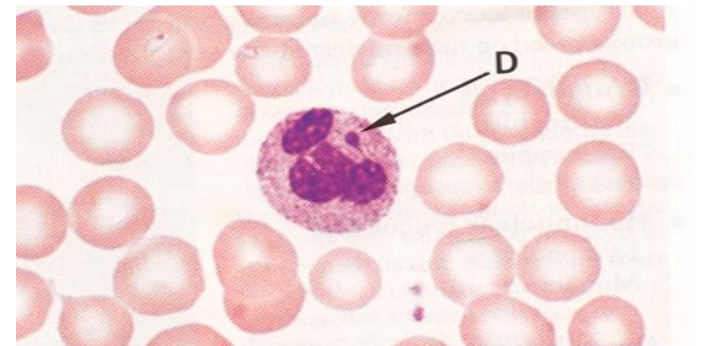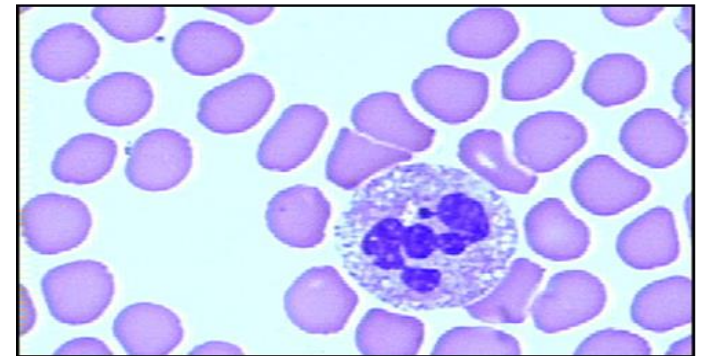
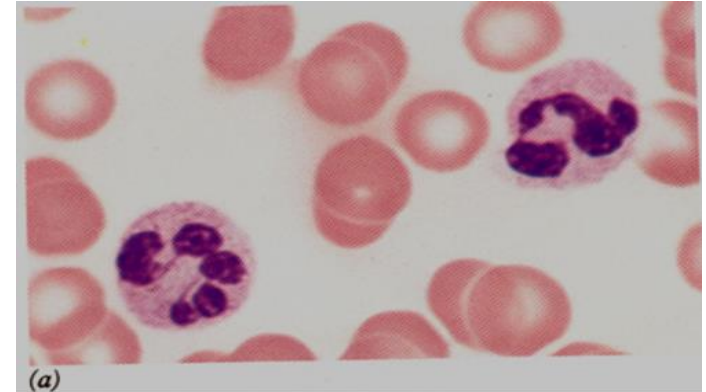
Cytoplasm: contains

❑ **Specific granules**

(neutral & small)

❑ **Non specific:**

azurophilic granules (few
& large ,stained by **azure**)



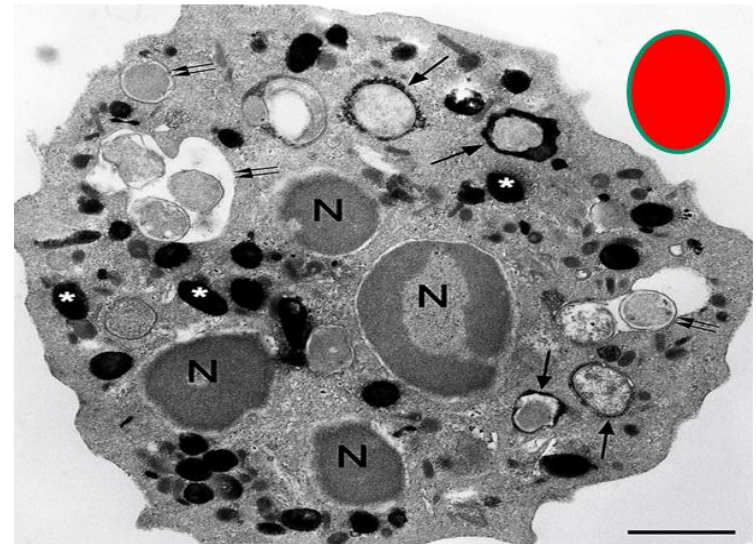
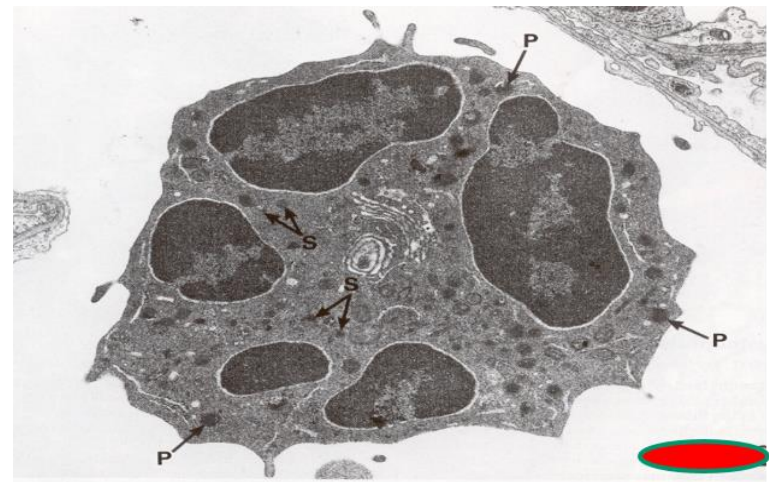
EM of Neutrophils

- Shape: irregular. When active
- Cytoplasm : Few organelles.
- **Granules:**
specific granules
Small , Numerous , Rice grain
appearance , **functional enzymes**
e.g. Collagenase

Non specific (Azurophilic)

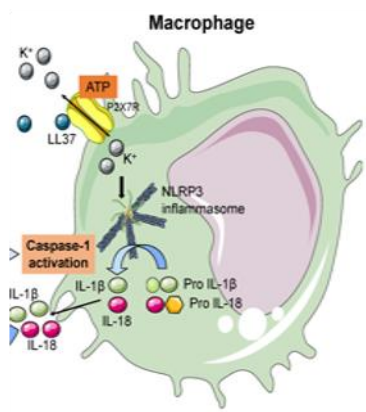
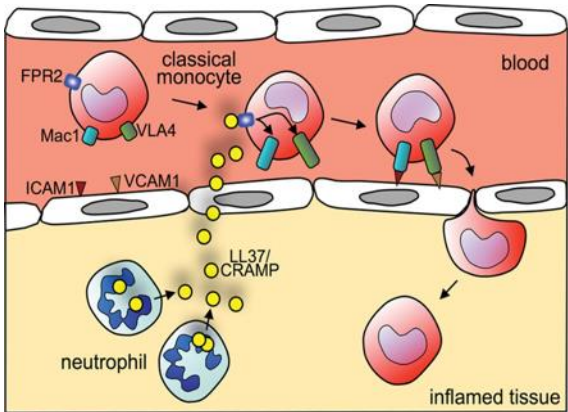
- **Large , few , dense**

Contain lysosomal hydrolytic enzymes.



Functions

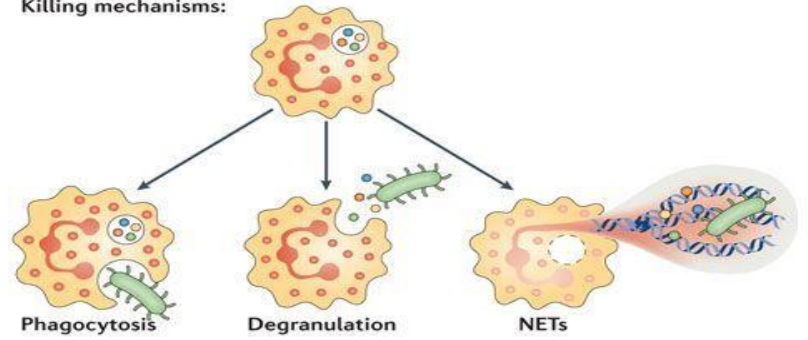
- ❑ The first line of defense.
- Micro-organisms in the C.T.
- Attraction of monocytes to the site of infection. ➡ Macrophages



Phagocytosis → killing of bacteria by phagocytins (specific secondary granules)

→ **Secretion of cytokines**

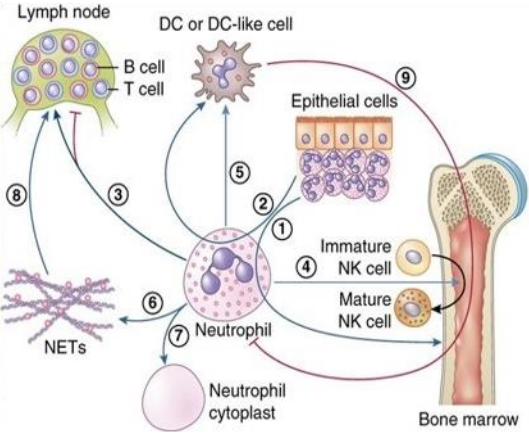
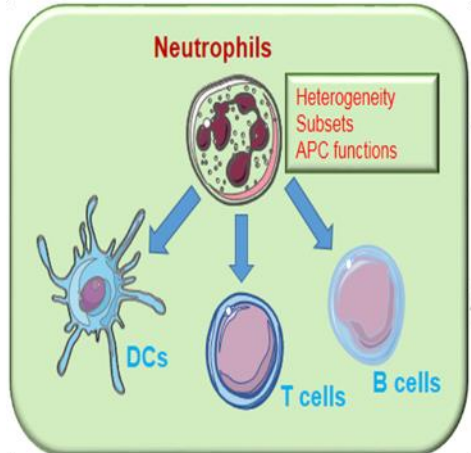
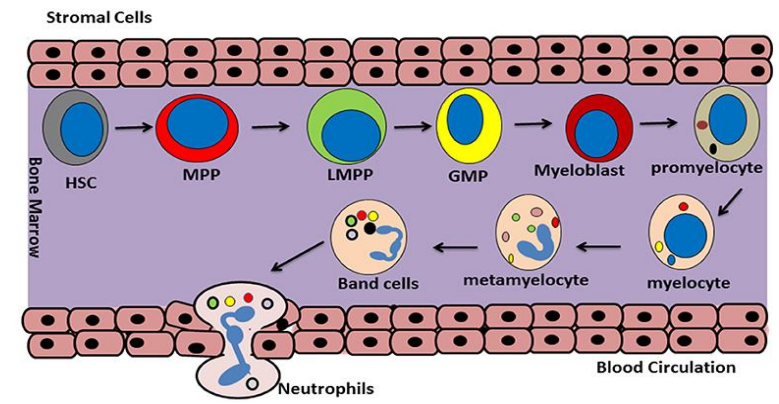
Killing mechanisms:



Nature Reviews | Immunology

- Stimulation of bone marrow to form new neutrophils

➤ Chemotaxis → migration →



- digestion by lysosomal enzymes (try, azurophilic granules)
- destruction of invader & CT by **Collagenase**
- death of neutrophils
Production of pus (**pus cells**)

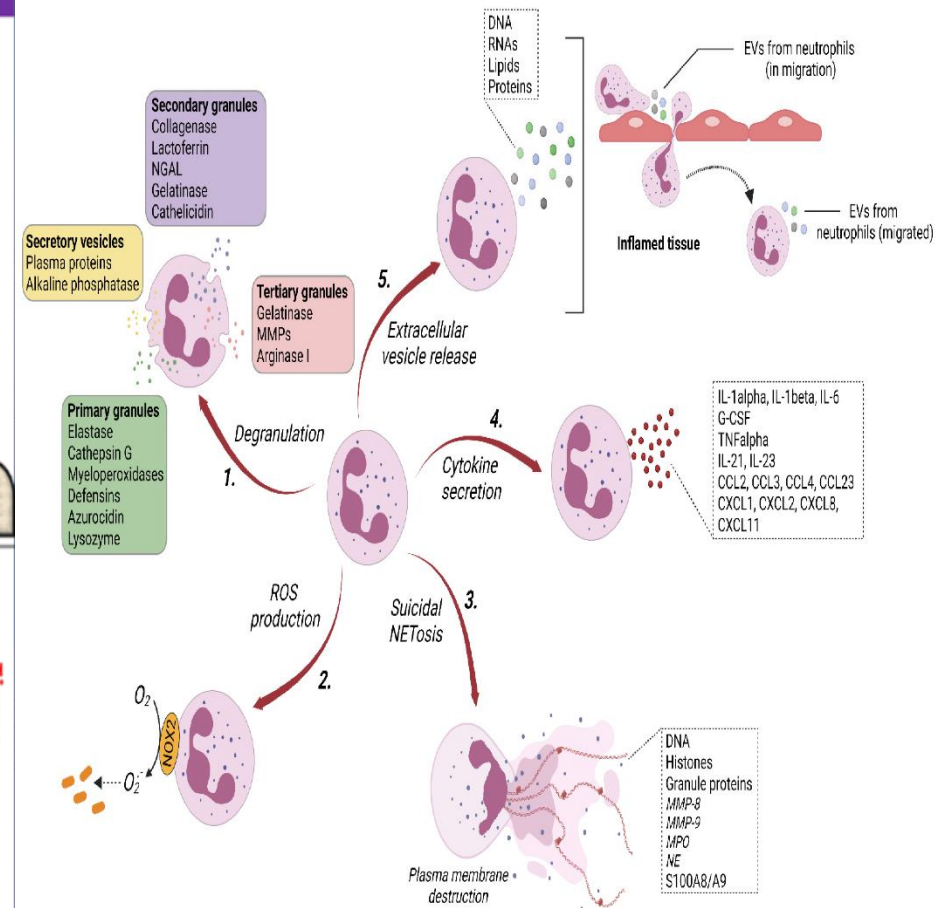
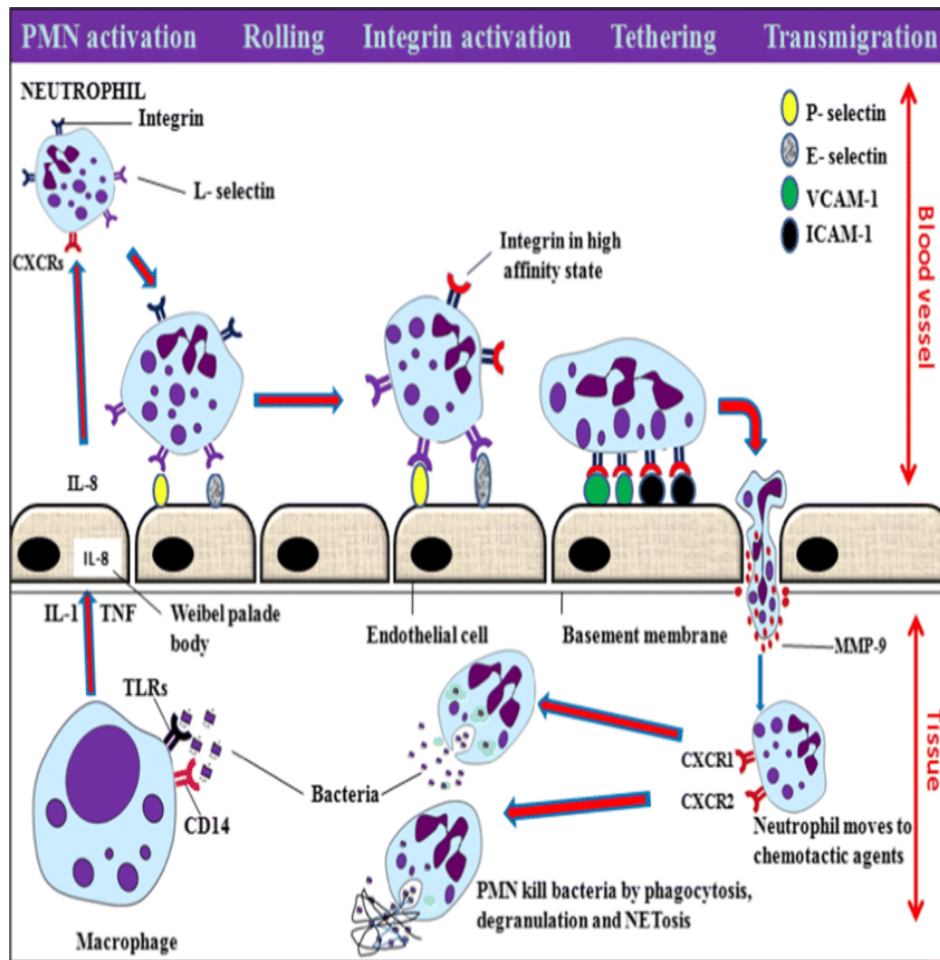
Life span: 1- 4 days in blood

Neutrophil and macrophage activation and migration at the site of inflammation.

The main phagocytic cells are macrophages in the tissues and neutrophils in the bloodstream.

Initially, macrophages in the tissue sense the presence of invaders act on the endothelial cells (ECs) and cause the release of interleukin binds to receptors on neutrophil surface causing neutrophil activation. Activated neutrophil helps in transmigration.

Chemokine receptors help neutrophils to move towards chemotactic gradients and after reaching its target, they attach, ingest and kill the foreign agent by various mechanisms

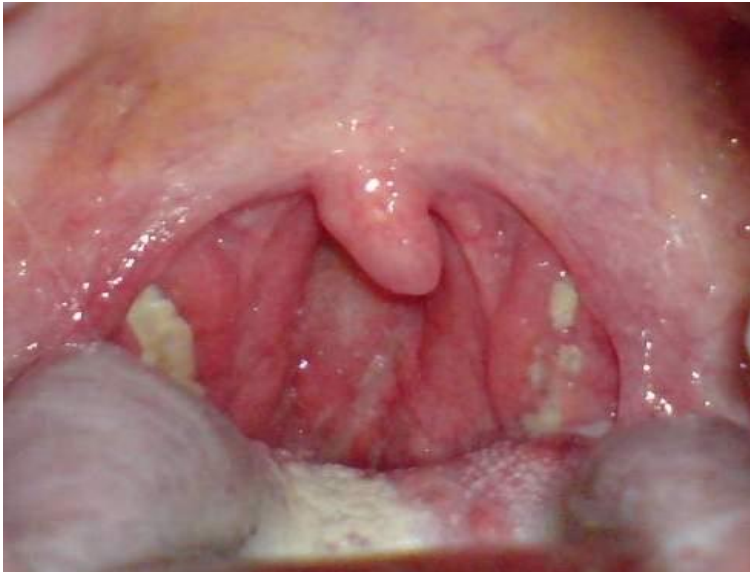

Abnormality of neutrophil count

Neutrophilia ▲ ▲

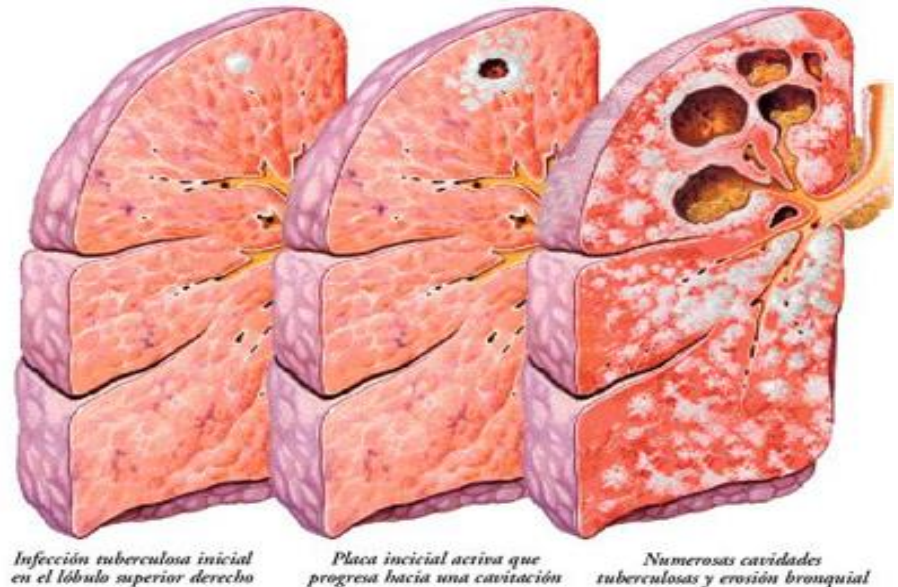
in **acute pyogenic infection** =
acute inflammations e.g.:

- ❖ Appendicitis
- ❖ Tonsillitis



Neutropenia: ▼ ▼

- ❖ Chronic infection e.g. TB
- ❖ Severe viral infection e.g. Influenza, Measles

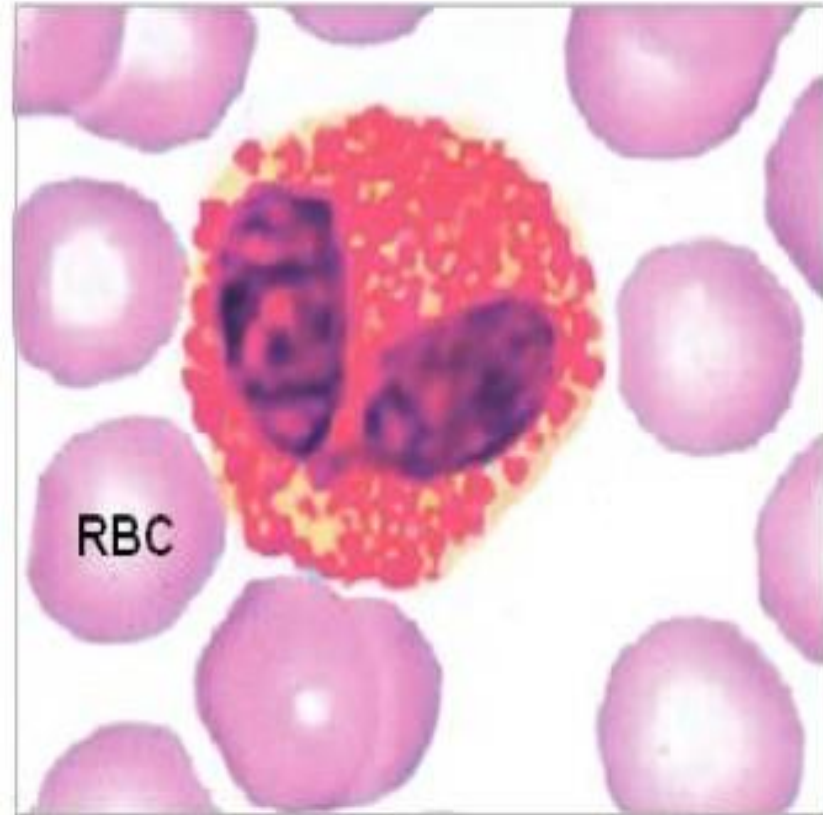


Eosinophils

- ❑ **Differential count** : 1- 4%
- ❑ **Size** : 12-15 microns.
- ❑ **Shape**: rounded
- ❑ **L.M.**

- ❑ **Nucleus**: bilobed C- shape

- ❑ **Cytoplasm** contains:
 - large **specific acidophilic granules**.
 - Few azurophilic granules



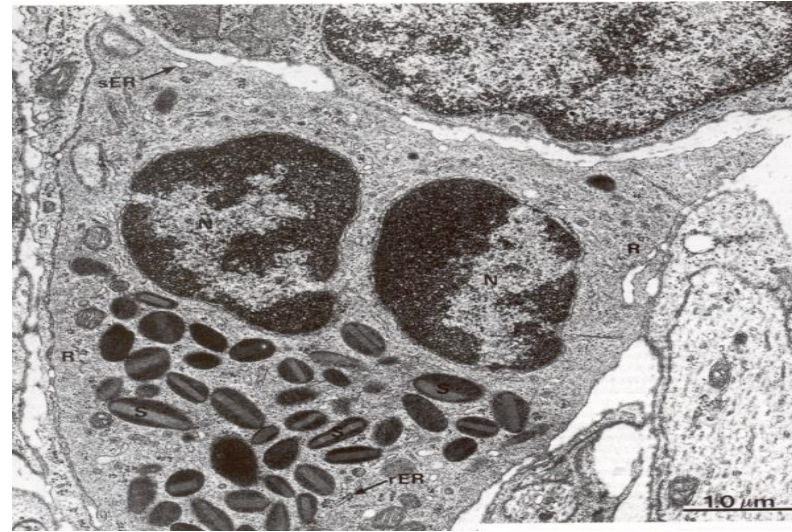


E.M:

- Bilobed C- shaped nucleus
- Cytoplasm contains
- Few organelles mitochondria, rER, & sER & glycogen
- **Specific granules** (Large, ovoid, crystalloid core contain many hydrolytic enzymes histaminase, eosinophil peroxidase)
- Few non specific granules

= **azurophilic granules**

Small, spherical Lysosomal hydrolytic enzymes



Function of Eosinophils

- Migrate to mucosa of GIT, respiratory, genito-urinary & skin.
- regulation of allergic reactions.
- Parasitic infection. (Not phagocytic)

Life span: several days up to week

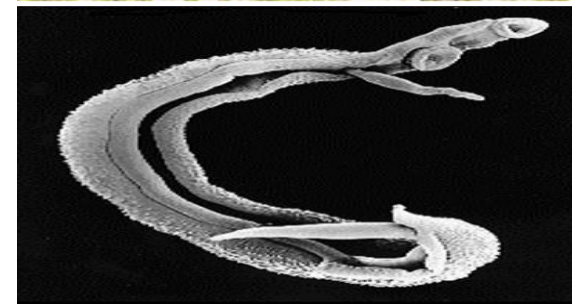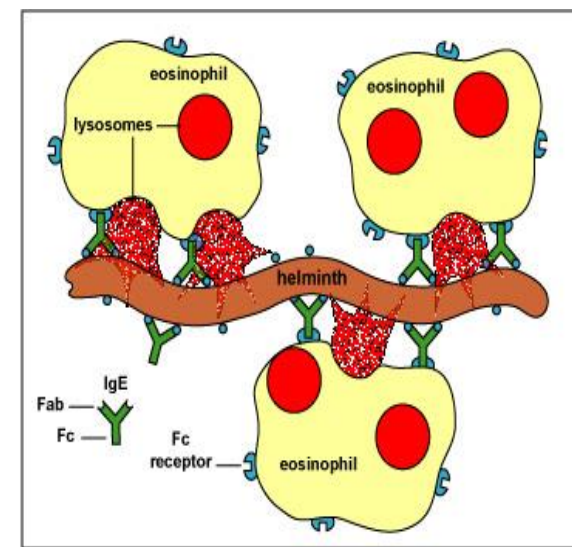
Abnormal Eosinophil Count

❑ **Eosinophilia = increase** ▲ ▲

- **Allergic** reactions e.g. bronchial asthma, allergy, **parasitic** infections e.g. Bilharziasis.

❑ **Eosinopenia = decrease** ▼ ▼

- Steroid therapy. Bone marrow depression.



Basophils

Mast cell of the blood

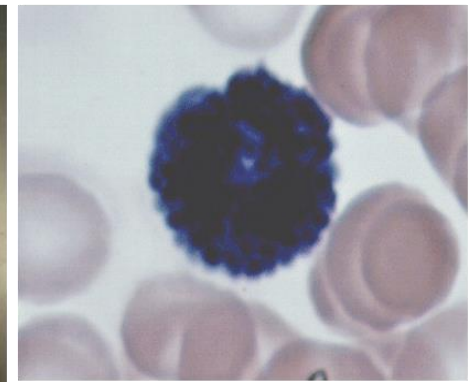
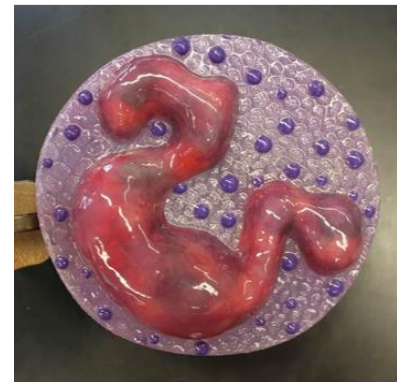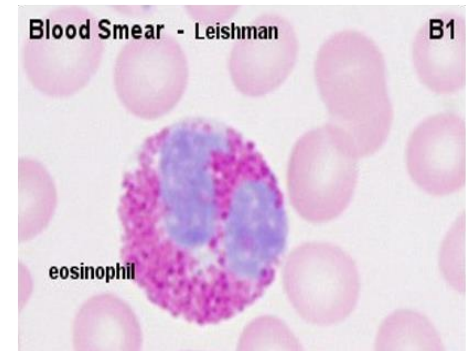
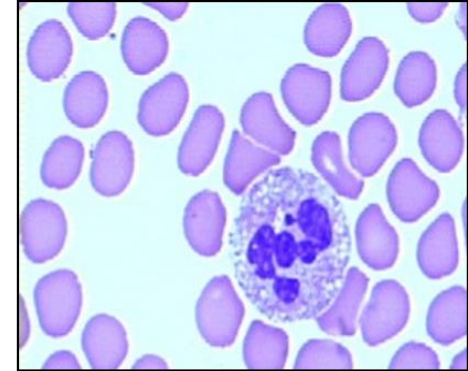
Differential count : $\frac{1}{2}$ - 1%

Size : **10** microns

Shape : Rounded

LM:

- **Nucleus:** Bilobed, (**S-shaped**)
- ❖ **obscured by large granules**
- **Cytoplasm:**
- ❖ **abundant deep blue granules.**
- ❖ **Metachromasia.**



E.M.

Nucleus : Bilobed S shape nucleus

Cytoplasm: mitochondria, ribosomes,
glycogen

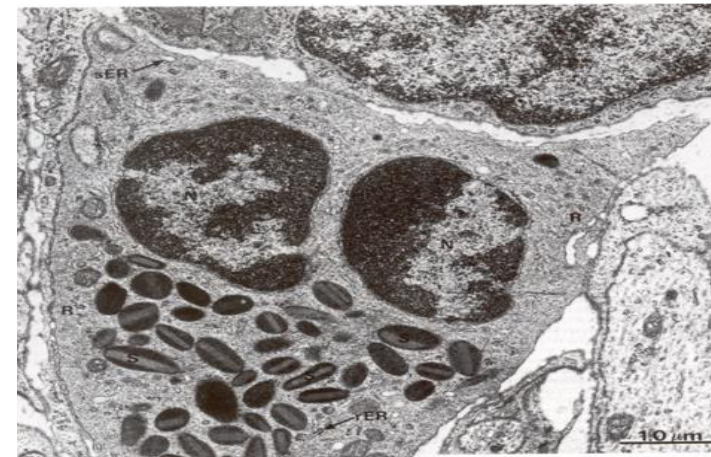
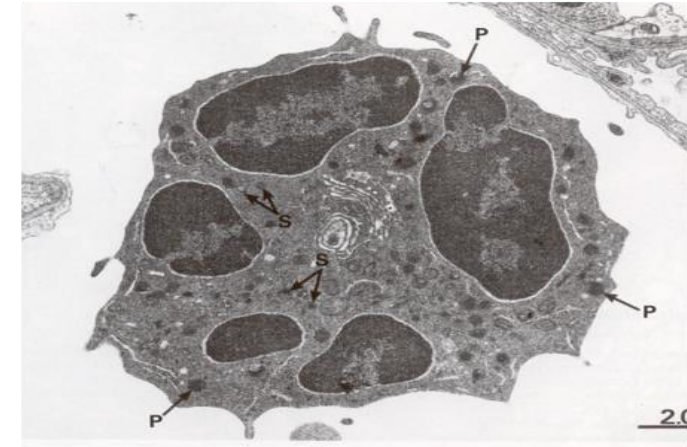
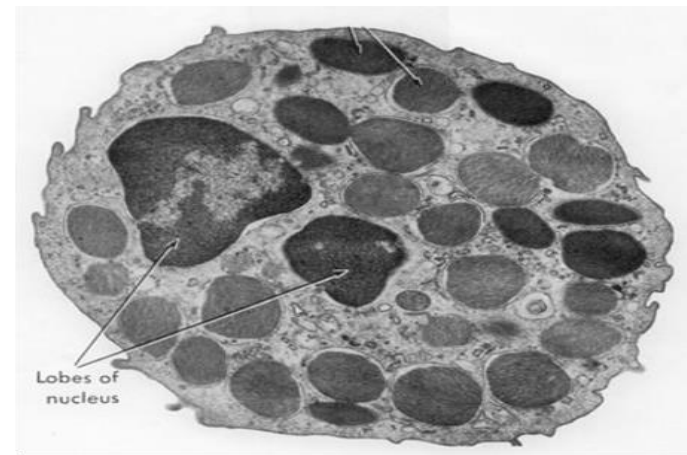
Granules :

specific granules

- Large, contain histamine, heparin

Non specific (azurophilic granules)

- Contain lysosomal hydrolytic enzymes.

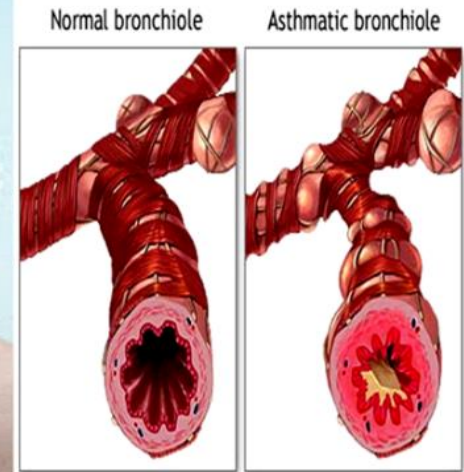
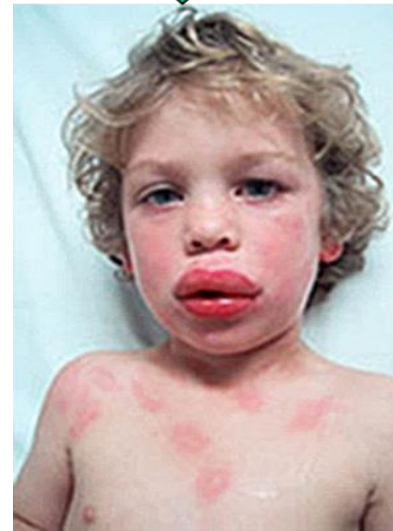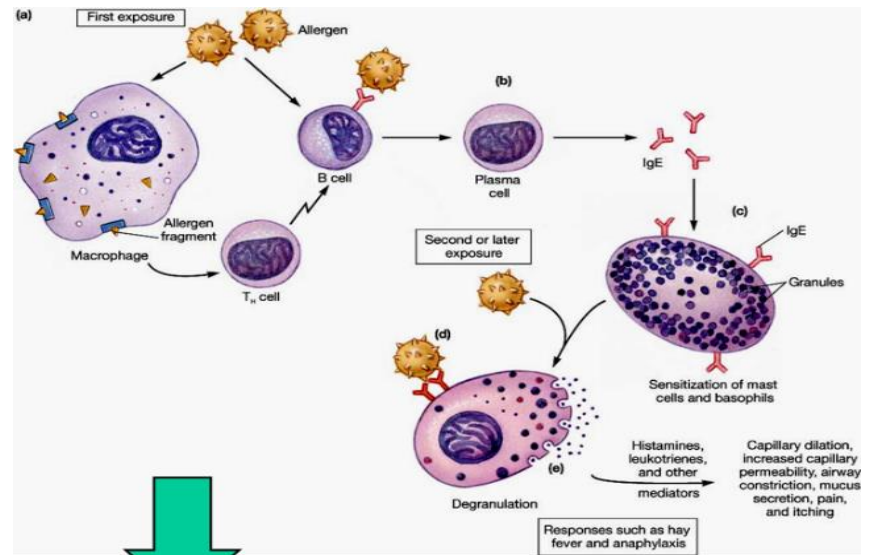


Functions

=Mast cell of blood:=

- **heparin:** anticoagulant
- **histamine: (anaphylaxis)**
- Secretion of histamine which initiates allergic reactions.
- Secretion of heparin which is a natural anti-coagulant.
- Secretion of eosinophil chemotactic factor to limit allergic reaction.

hypersensitivity reaction



Life span: **1-2** week

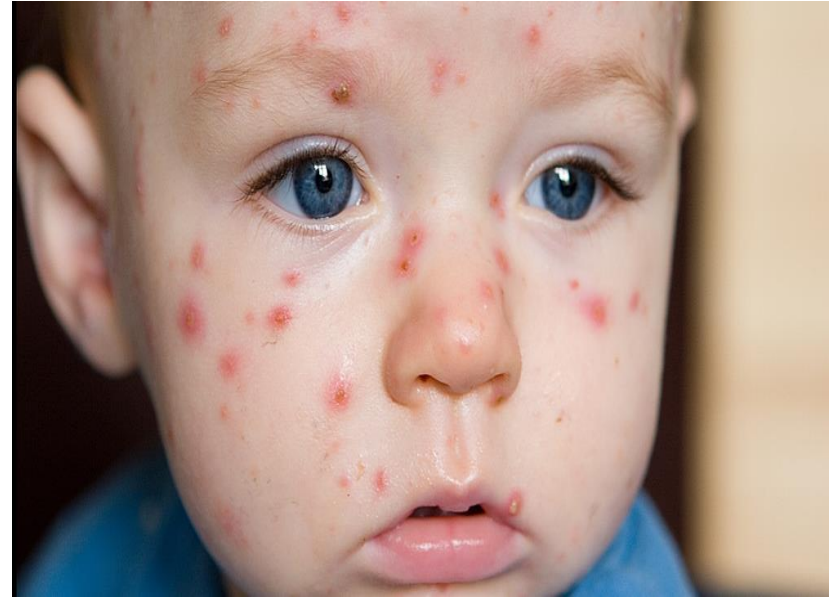Abnormal count

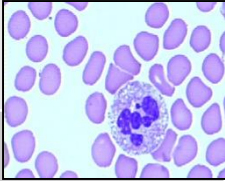

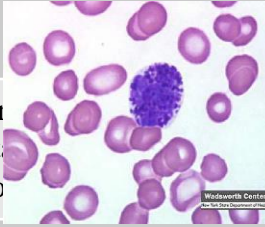
Basophilia:increase ▲ ▲

➤ viral infections e.g.

small pox and chicken pox.

➤ **Systemic allergy**



	Neutrophils	Eosinophils	Basophils mast cell of the blood .
Number	60-70% of leukocytic count	1-4% of leukocytic count	0-1% of leukocytic count
Size	10-12 μm in diameter 	larger than neutrophils (12-15 μm in diameter,	(10 mm) in diameter,
Shape	spherical in shape + Neutral granules	spherical in shape + Acidophilic granules	spherical in shape (basophilic) specific granules with heparin and histamine
Structure	multi-lobed nucleus human females may have inactivated second X chromosome (Barr body drum stick)	bi-lobed nucleus C-shape or	S-shape lobed nucleus, obscured by basophilic granules
Life span	lifespans 1-4 days in circulation;	several days Up to week 	1-2 weeks 
Function	first line of defense against any invading micro-organism	<ul style="list-style-type: none"> • Kill parasites, • associated with allergic reactions 	Basophils are involved in the release of Histamine during allergic reactions
Abnormality	Neutrophilia: i.e. abnormal increase in the number of neutrophils. This is observed in acute inflammations e.g. appendicitis, tonsillitis. Neutropenia: i.e. abnormal decrease in the number of neutrophils e.g. in influenza, typhoid fever.	1-Eosinophilia: i.e. abnormal increase in the number - Allergic reactions e.g. asthma, urticaria -Parasitic infections e.g. Bilharziasis. 2-Eosinopenia: i.e. ↓ decrease in the number prolonged corticosteroid therapy .	Basophilia in systemic allergic reaction

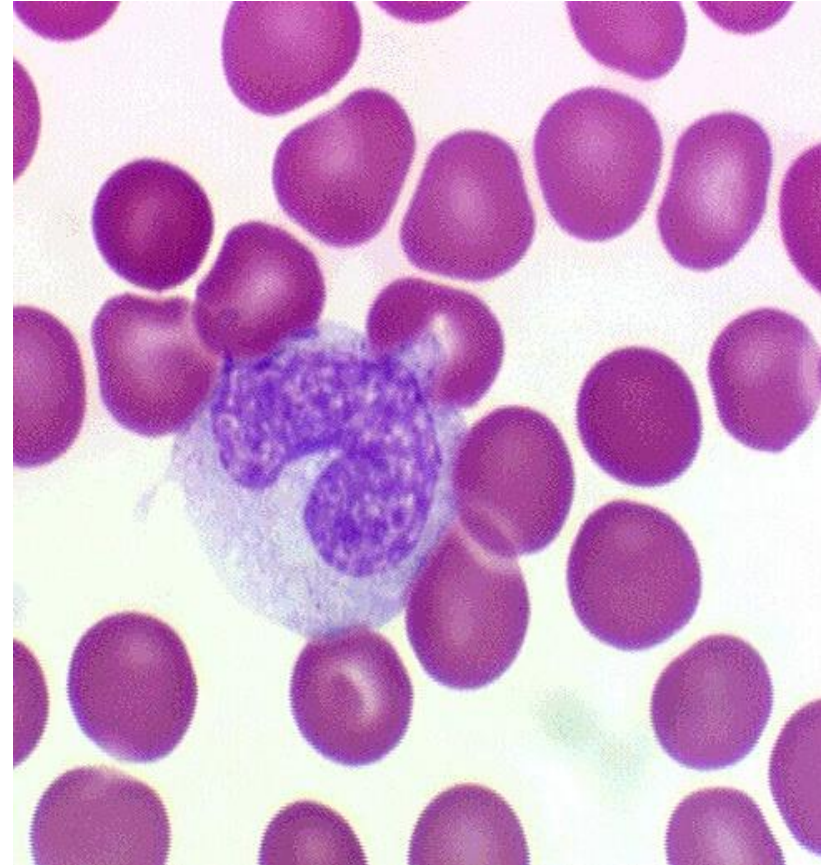
Agranular leukocytes

Monocyte

- **Differential count: 3 - 8%**
- **Size :** 20 microns = **Largest** in blood film
- **Shape : rounded**

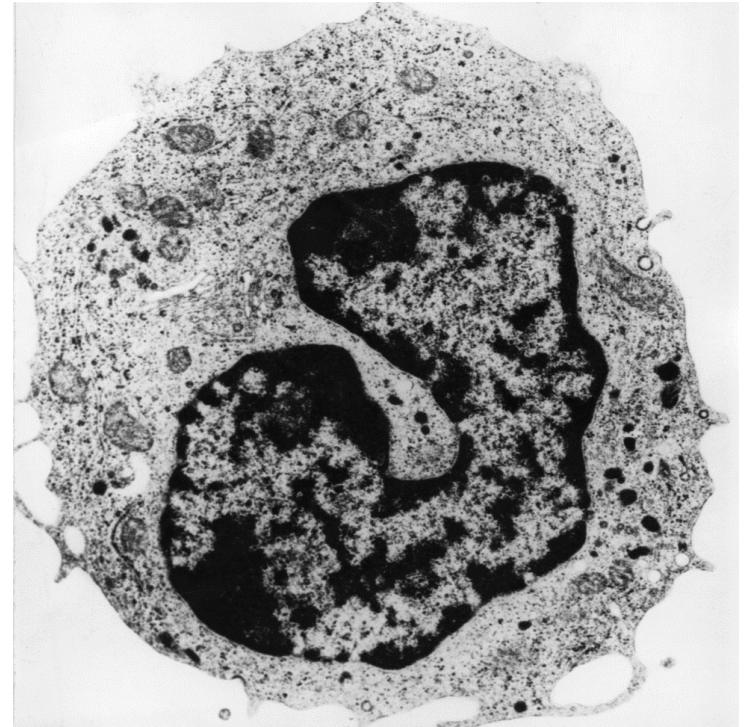
LM:

- **Nucleus:**
 - ❖ Large, eccentric , Kidney- shaped (**Indented**)
- **Cytoplasm:**
 - ❖ Finely granular, abundant pale basophilic non specific granules
= **Azuophilic granules**



EM:

- ❑ Irregular = Pseudopodia
- ❑ Nucleus: Large, eccentric kidney-shaped (Indented)
- ❑ The cytoplasm contains
 - a moderate amount of organelles.
 - Non specific (Azurophilic granules) few small dense granules containing lysosomal hydrolytic enzymes.



Function :

- Trans- migration & differentiation to tissue

MACROPHAGE

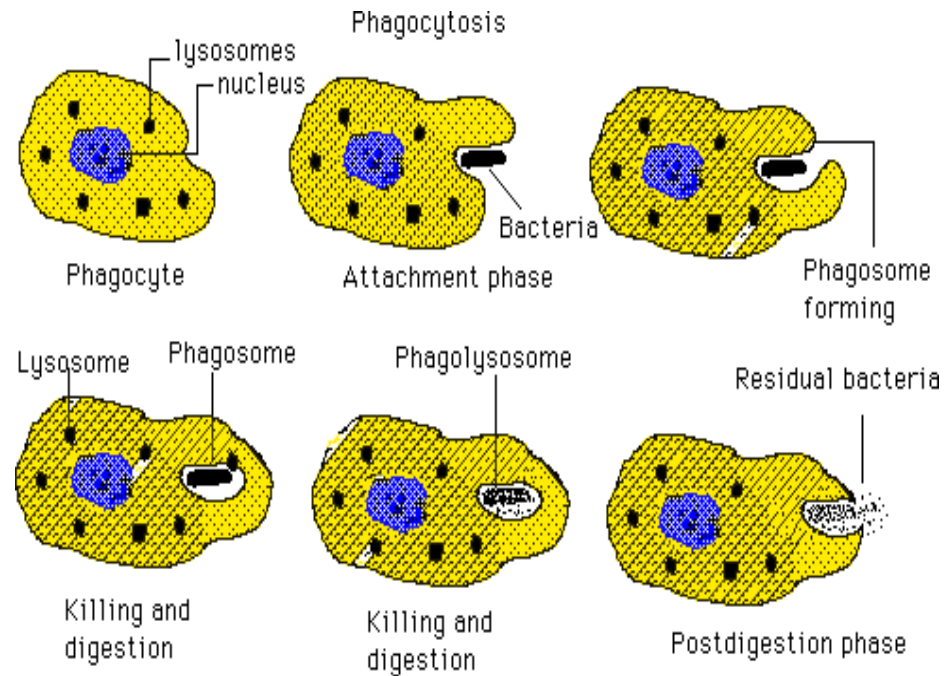
- Immunologic function:

➤ Phagocytosis and intracellular digestion of bacteria, virus

➤ Ag- presenting cell

Life span : 1-2 days

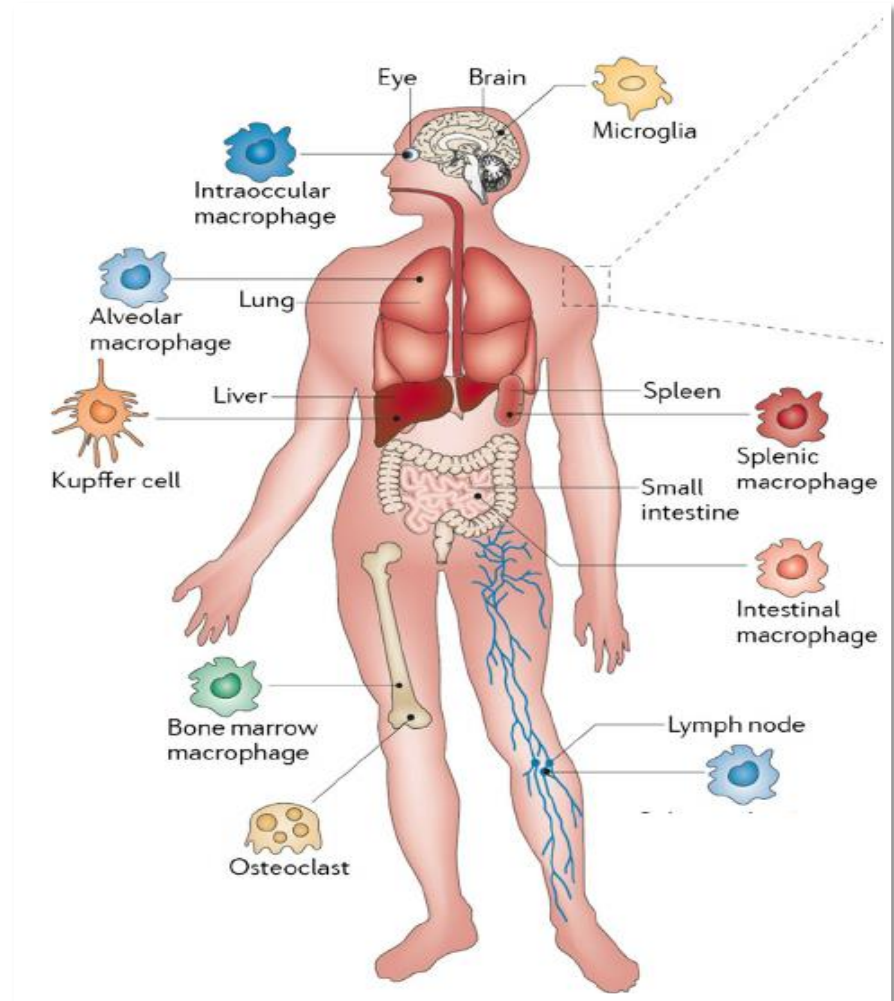
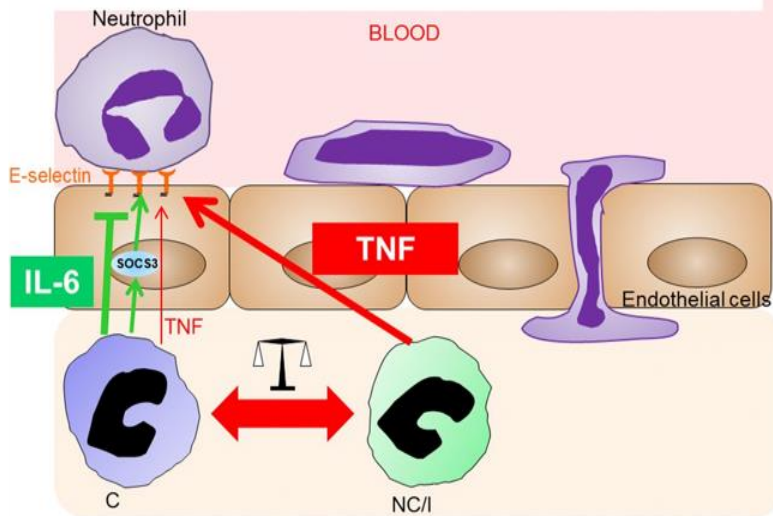
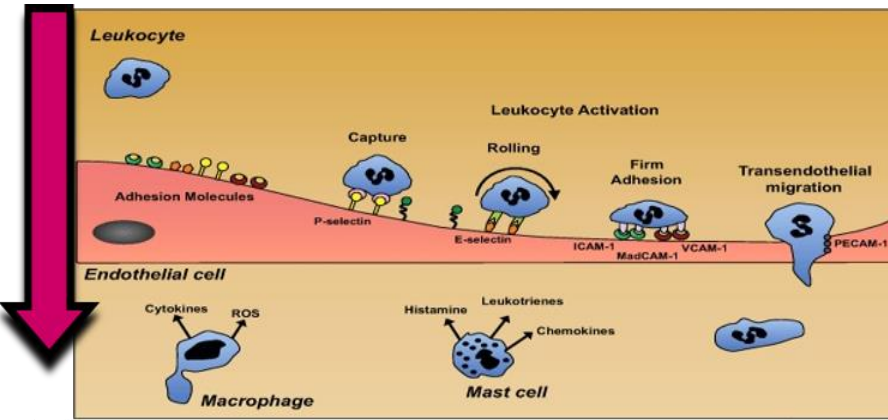
circulation in the blood, then enter the CT and transform into macrophages



- Circulate from region to another & Function in CT=

Immunological function

Mononuclear phagocytic cells



Abnormal Monocyte count

Increase number = Monocytosis

Causes:

1- Malaria

2- Chronic infections (glandular fever , syphilis, T.B.)

3-Lymphomas & Leukemia.

 in number of **Monocyte**

Causes:

▪ **Bone marrow depression**

➤ drugs

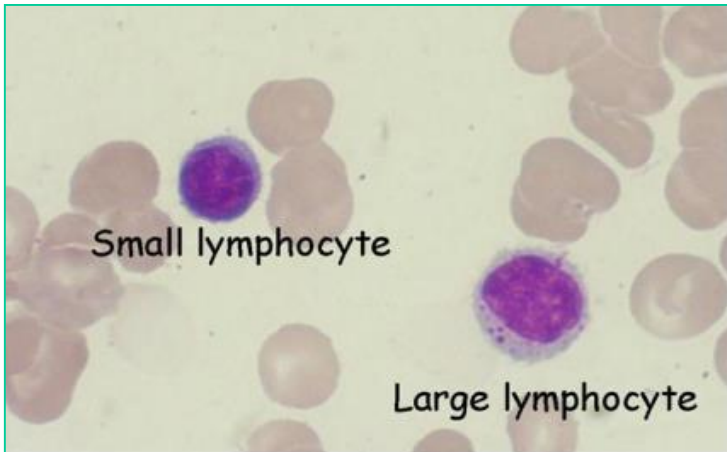
➤ Irradiation

➤ Severe chronic diseases

Lymphocytes

- Differential count: 20-30%
- Size : 9-12 microns
- According to the sizes:
 - large lymphocytes.
 - Medium-sized lymphocytes.
 - Small lymphocytes:

- ❖ Diameter = RBC.
- ❖ Most numerous.
- ❖ Functionally mature.



3 functional types:

➤ T- lymphocytes:

- Start development in bone marrow.
- Differentiate in thymus.
- Cell-mediated IR.

➤ B-lymphocytes:

- Develop & differentiate in bone marrow.
- Humoral immune response.

➤ Natural killer cells = Null cells

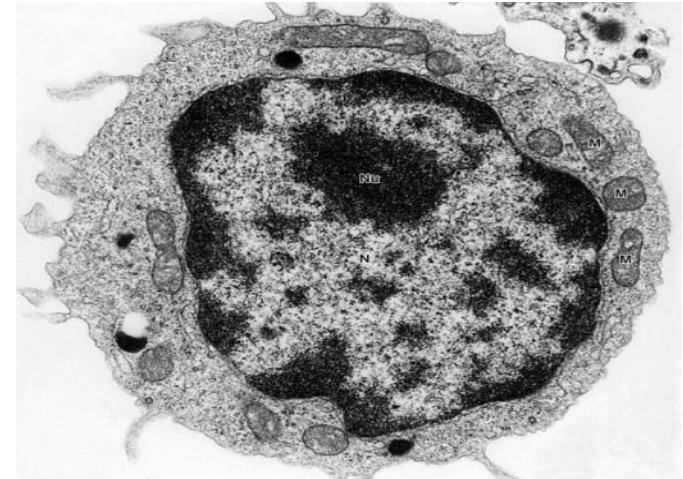
- Develop in bone marrow.
- Lack CDs of B or T.
- Are null cells(non B, nonT).
- They don't enter the thymus to be competent.
- They act nonspecifically to kill virally infected cells & tumor cells

❖ LM:

- **Shape = rounded**
- Large nucleus, thin cytoplasmic rim
- No stained granules in the cytoplasm (except small **Azurophilic granules**)
- **Small most common 90%**
- **Types: B- and T-lymphocytes (morphologically not distinguishable)**
- **Null-cells** (somewhat smaller size) Non B Non T

❖ EM:

- **Nucleus:** dense clumps.
- **Cytoplasm thin rim**
- No specific granules
Lysosomes= small & dense **Azurophilic granules**
- Many **free ribosomes** & few **mitochondria + 2 centrioles**
- ▲▲ The cell coat = **antigenic markers.**



Antigenic markers of lymphocytes


The cell coat: Large no. of cell receptors.

1. Major histocompatibility complex (MHC)

Glycoprotein + specific a.a. sequence.

- Tissue typing & antigenic recognition.
- 2 subclasses:
MHC I & MHC II.

2- The cluster of differentiation antigens (CDs):

- Cell- surface glycoprotein + specific a.a. sequence.
- Expressed on **different types of lymphocytes**
- Marker proteins upon which 

Functional types of lymphocytes.

Antigenic markers of lymphocytes

Major histocompatibility complex (MHC)

❖ MHC I:

- On all nucleated cells.
- Glycoprotein + specific a.a. sequence.
- Tissue typing.
- Endogenous antigenic recognition:
 - virus- infected cells.
 - malignant cells.

❖ MHC II:

- Expressed on antigen-presenting cells.
- Glycoprotein + specific a.a. sequence.
- Tissue typing.
- Exogenous antigenic recognition:
 - Phagocytosed foreign Ags.

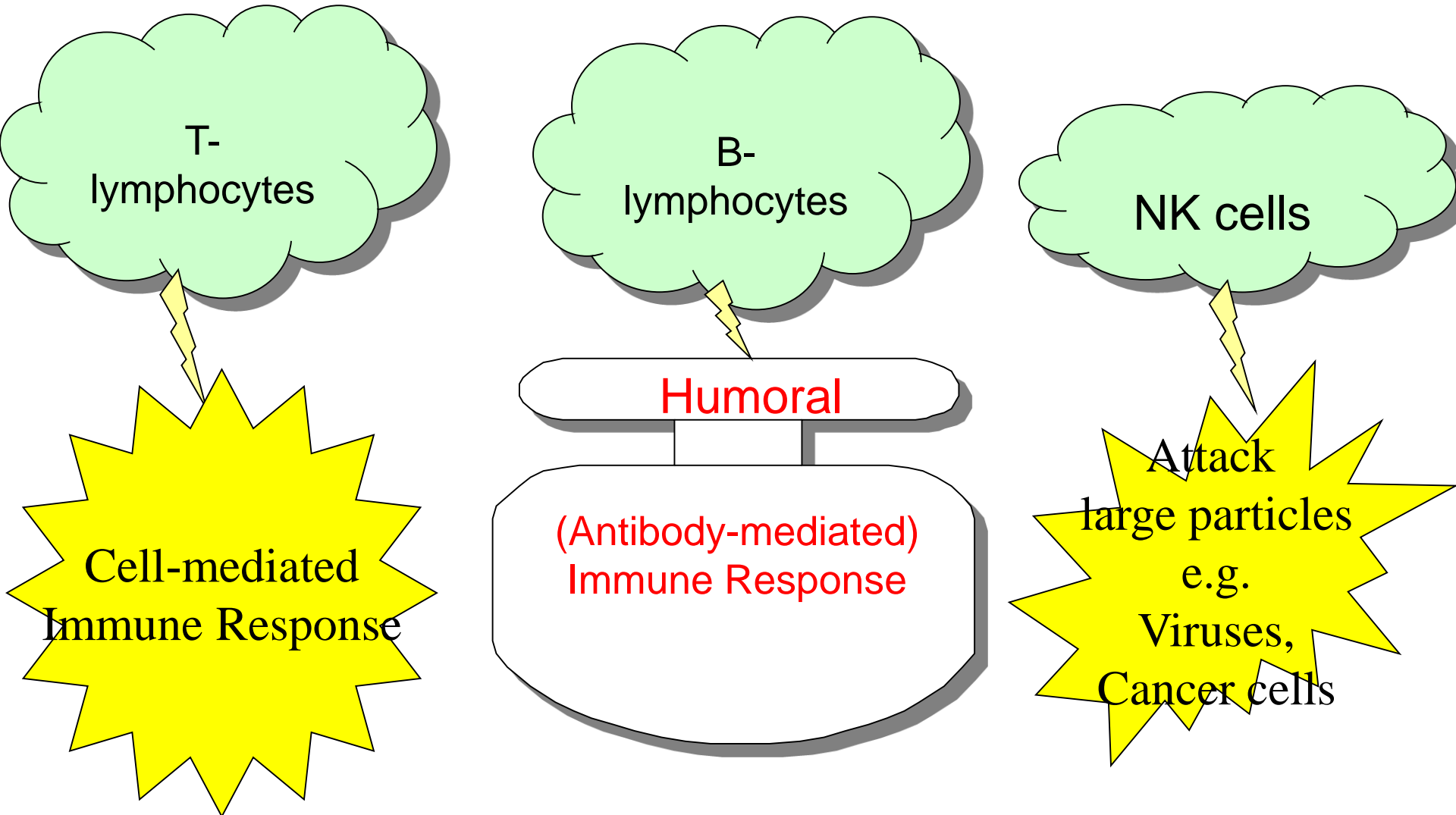
Function :

- ✦ After stimulation T-cells and B-cells become : Effector cells & Memory cells
- ✦ B cells form plasma cells, function in humoral immunity via immunoglobulins
- ✦ T cells function in cell-mediated immunity
- ✦ Effector T-cells: T helper cells, T suppressor cells, cytotoxic T cells
- ✦ Some T cells with “memory” of antigen exposure survive long periods; immunization
- ✦ Null Cells are composed of: Stem cells and Natural killer cells
- ✦ NK cells kill some foreign and virally alerted cells

❖ Life span:

- months-----
years

Functions of Lymphocytes



Abnormal lymphocyte count

1-Lymphocytosis: ↑ ↑

Causes:

Physiological: in children

Pathological:

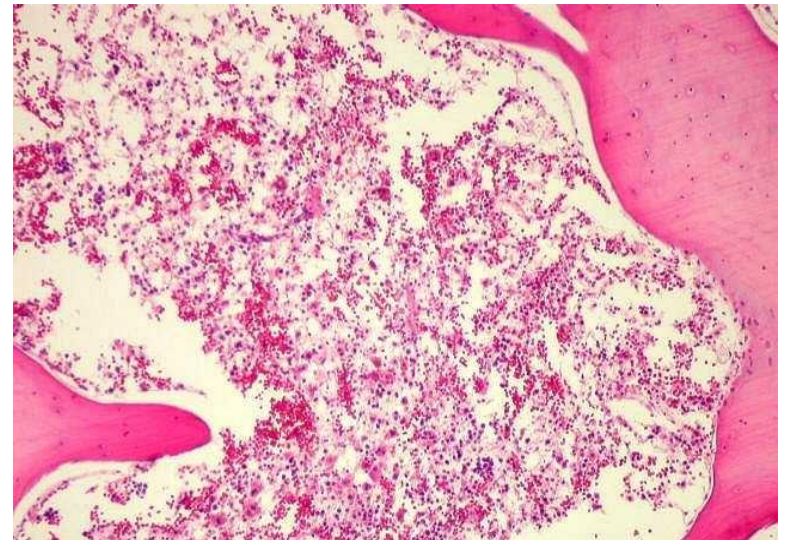
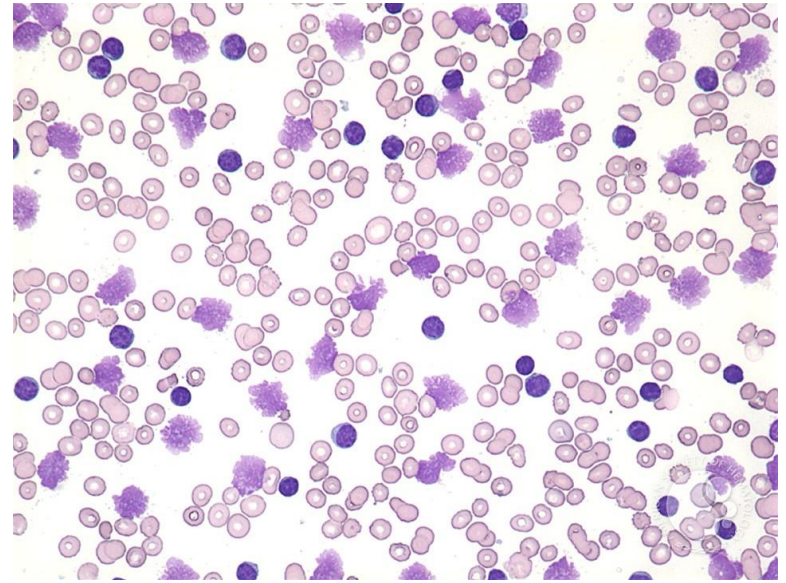
1-chronic infections tuberculosis, syphilis,

2-leukemia, Lymphoma.

2-Lymphopenia: ↓ ↓

Bone marrow depression.

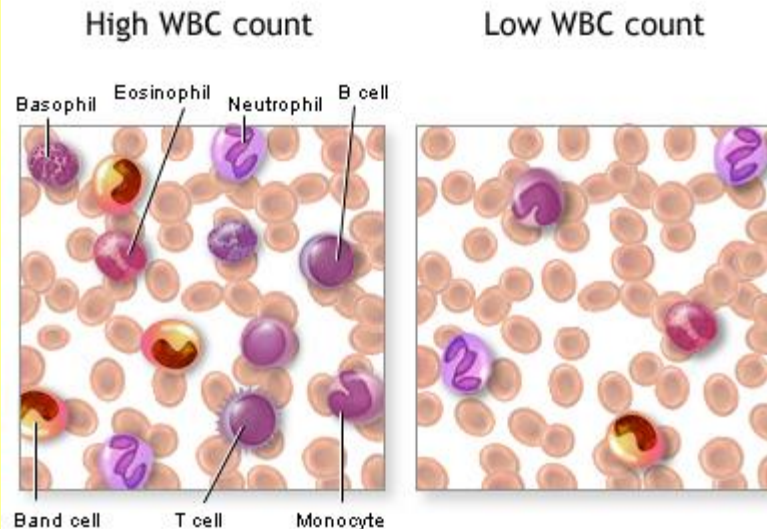
- ❖ drugs
- ❖ Irradiation
- ❖ Severe chronic diseases



Abnormalities in leukocytic count

leukocytosis

- Infection
- Inflammations
- Allergic reaction
- Leukaemia



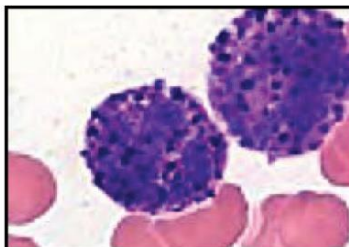- Bone marrow depression
- drugs
- Irradiation
- Severe chronic diseases
- Typhoid fever
- Measles

Leukopenia

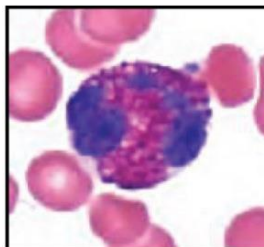
Acquired Causes of decrease in number

Decreased Production	Increased Destruction	Shift to Marginating Pool
Bone marrow	Peripheral circulation	Move from the circulating pool to attach along the vessel wall
Medication: Chemotherapy Antibiotics, etc	Autoimmune diseases (Rheumatoid arthritis, SLE, etc)	Severe infection Endotoxin release Hemodialysis Cardiopulmonary bypass

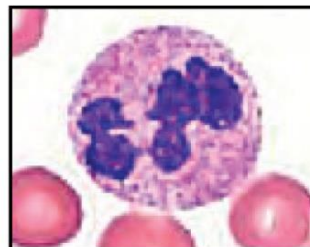Key



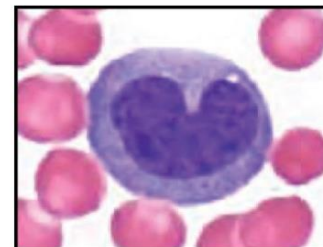Basophil



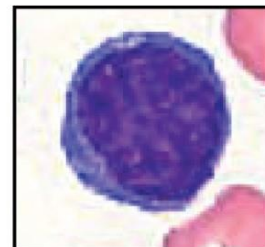Eosinophil



Neutrophil



Monocyte



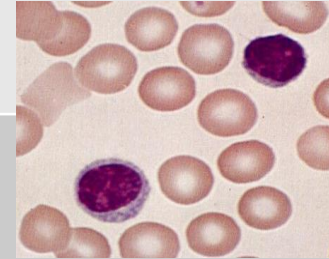
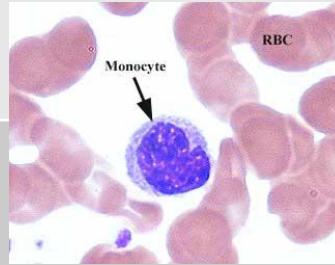
Lymphocyte

Monocyte

Lymphocyte

Subsets T, B, natural killer

Number	3-8% of WBCs	20-25 % of WBCs Next most common after neutrophils
Size	12-20 μm diameter	9-11 μm diameter Small , medium , large
Shape	Spherical	Spherical
Structure	Spherical , Nucleus kidney-shaped No obvious granules	Spherical , Nucleus indented No obvious granules
Life span	Circulate for 3-4 days before enter into tissues and organs	variable life spans Month – years (memory cell)
Function	Precursor of <u>macrophages</u> in tissues Macro = “big”; phage = “eat” Phagocytic function	B Cells involved in humoral immunity T Cells involved in cell-mediated immunity <ul style="list-style-type: none"> • T helper cells, • T suppressor cells, • cytotoxic T c & memory cell
Abnormality	<i>Monocytosis</i> : is an abnormal increase in the number of blood monocytes. It occurs in diseases like tuberculosis, malaria, and leukemia.	<i>Lymphocytosis</i> : It is an abnormal increase in the number of lymphocytes as in: leukemia, lymphoma, and viral infections.



Bone marrow

- **Def :** It is a semi-solid tissue . It is the primary site of new blood cell production or **hematopoiesis**
- Bone marrow is the site for other important activities in addition to hematopoiesis e.g. the removal of aged and defective erythrocytes and the **differentiation of B lymphocytes**. It is also the site of numerous **plasma cells**.

Site :

Yolk Sac: very early embryo

Liver, Spleen: NEWBORN

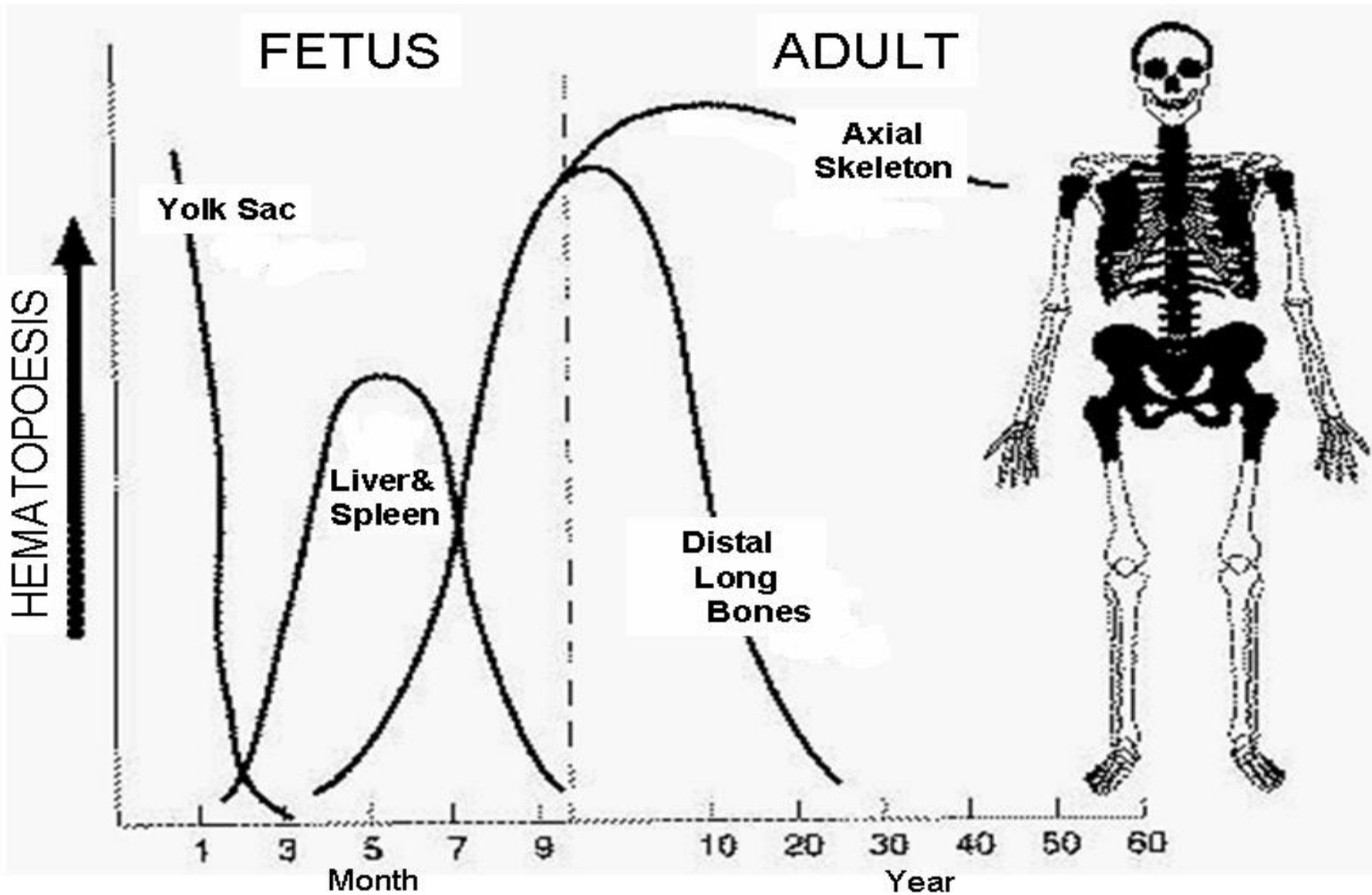
BONE

➤ **CHILDHOOD: AXIAL SKELETON & APPENDICULAR SKELETON BOTH HAVE RED (active) MARROW**

➤ **ADULT: AXIAL SKELETON RED MARROW, APPENDICULAR SKELETON YELLOW MARROW**

- In adult humans, bone marrow is primarily located in the ribs , vertebrae ,sternum , and bones of the pelvis .

Blood Forming Organs



Types of bone marrow

The tissue responsible for **Hemopoiesis** = formation of balanced amounts of the different blood elements.

- daily formed = daily destroyed elements

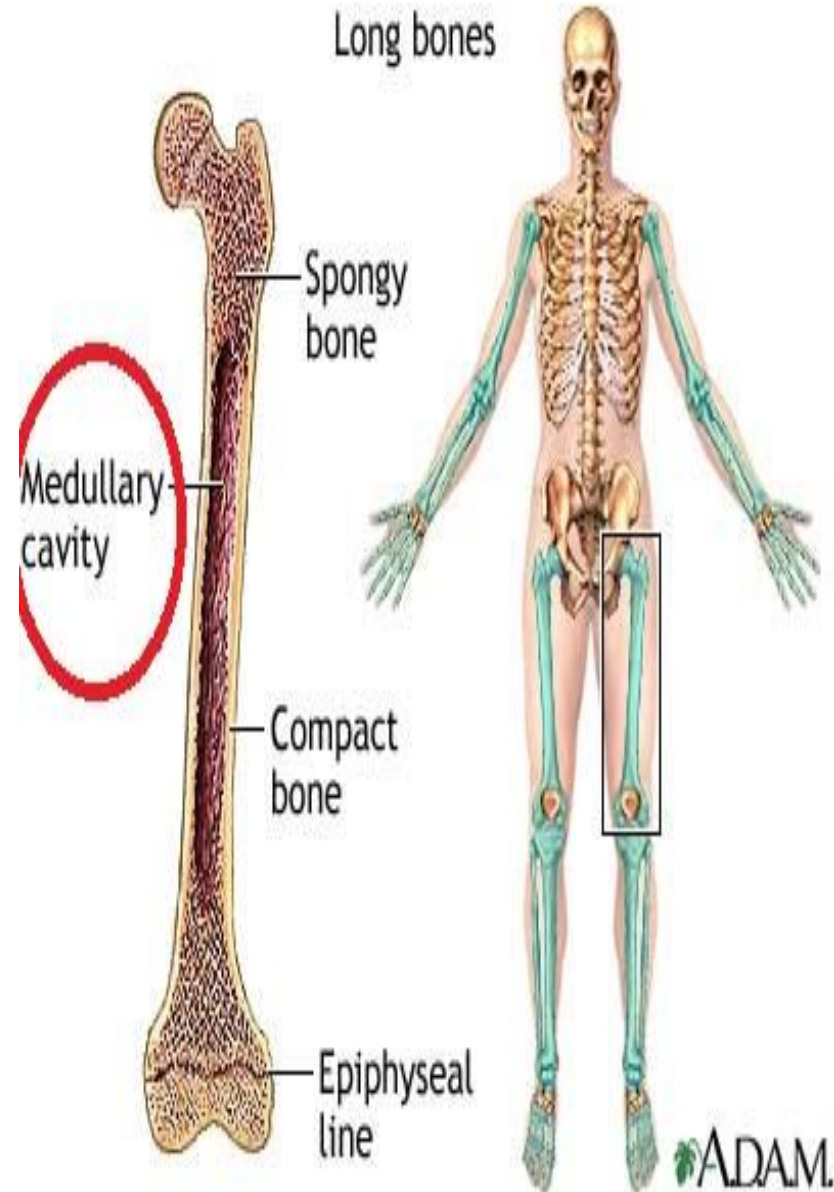
1-Red bone marrow: active.

2-Yellow bone marrow:

- inactive. Yellow color ► large number of fat cells.
- can revert to the red type in **stress** as hemorrhage and anaemia.

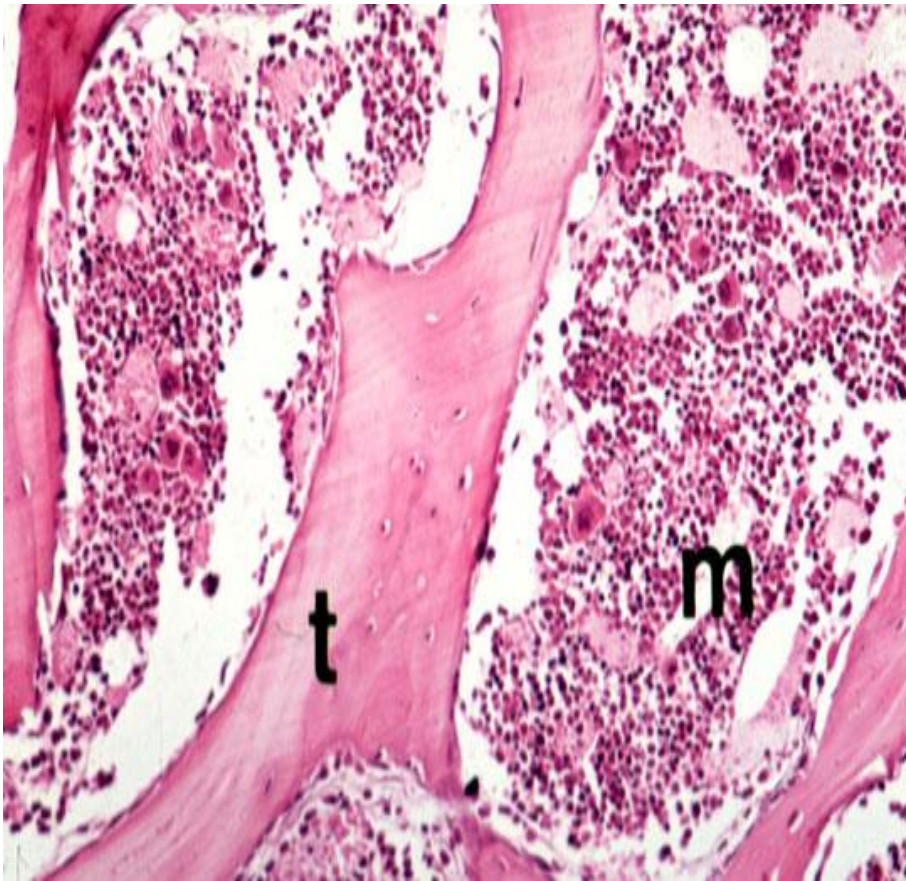
Sites:

1. Central bone marrow cavity in long bones.
2. Multiple marrow cavities (Flat bone) between trabeculae of cancellous bone.

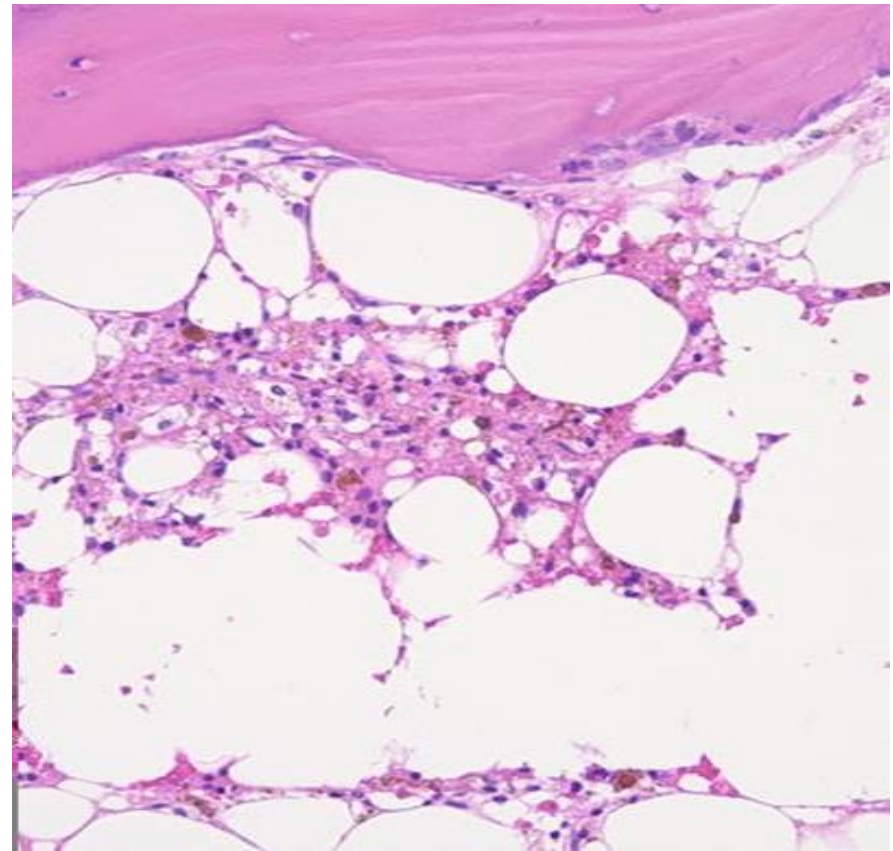


Types of bone marrow

Red bone marrow



Yellow bone marrow



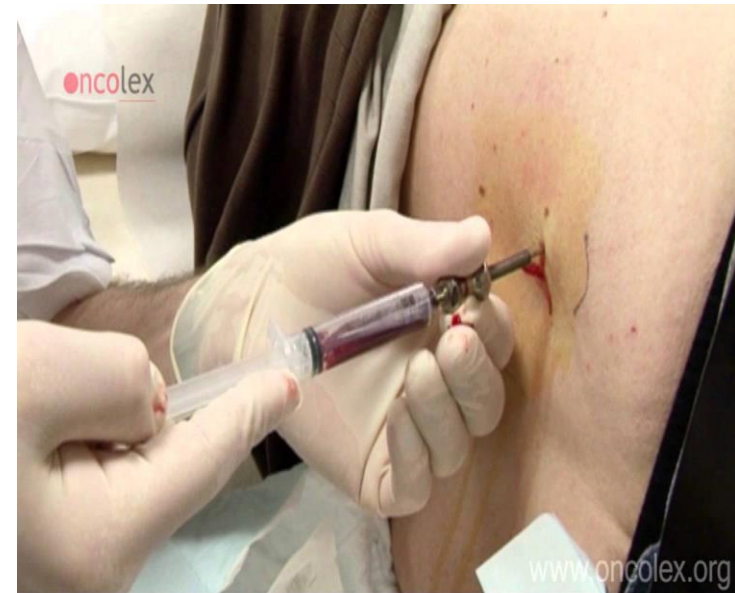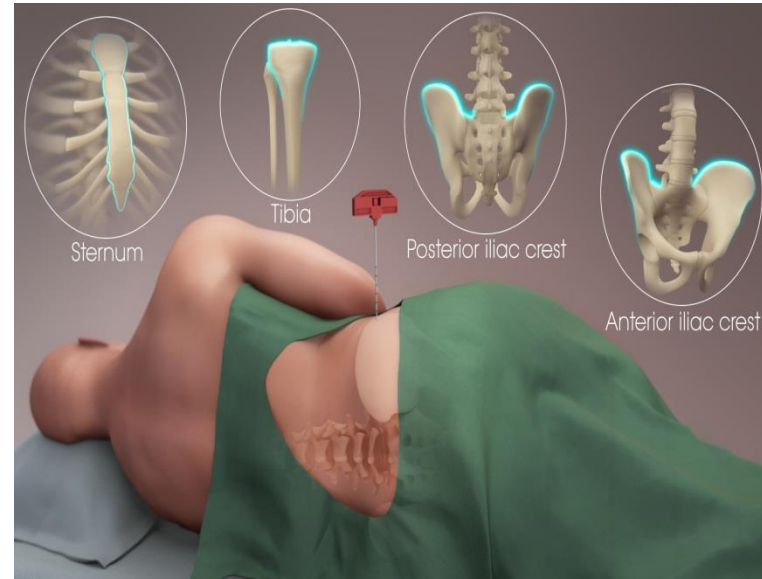
Bone marrow examination

- is the pathologic analysis of samples of bone marrow obtained via **biopsy** and bone marrow **aspiration**.
- ❑ The bone marrow produces the cellular elements of the blood, including **Platelets** , **RBCs** and **WBCs** .
- ❑ While much information can be obtained by testing the blood itself , it is sometimes necessary to examine the source of the blood cells in the bone marrow to obtain more information on hematopoiesis; this is the role of bone marrow aspiration and biopsy.
- ❑ Bone marrow examination is used in the diagnosis of a number of conditions, including **leukemia**, **multiple myeloma**, **anemia** , and **Pancytopenia** .

□ The stem cells are typically harvested directly from the red marrow in the iliac crest, often under **general anesthesia**. The procedure is minimally invasive and does not require stitches afterwards. Depending on the donor's health and reaction to the procedure, the actual harvesting can be an outpatient procedure, or can require **1–2 days of recovery in the hospital**.

• **In adults**, bone marrow may also be taken from the sternum, while the tibia is often used when taking samples from **infants**. In **newborns**, stem cells may be taken from the umbilical cord .

□ Another option is to administer certain drugs that stimulate the release of stem cells from the bone marrow into circulating blood. An **intravenous catheter** is inserted into the donor's arm, and the stem cells are then **filtered out of the blood**.



STRUCTURE & FUNCTION OF BONE MARROW

- ❑ The composition of marrow is dynamic, as the mixture of cellular and non-cellular components (connective tissue) shifts with age and in response to systemic factors.

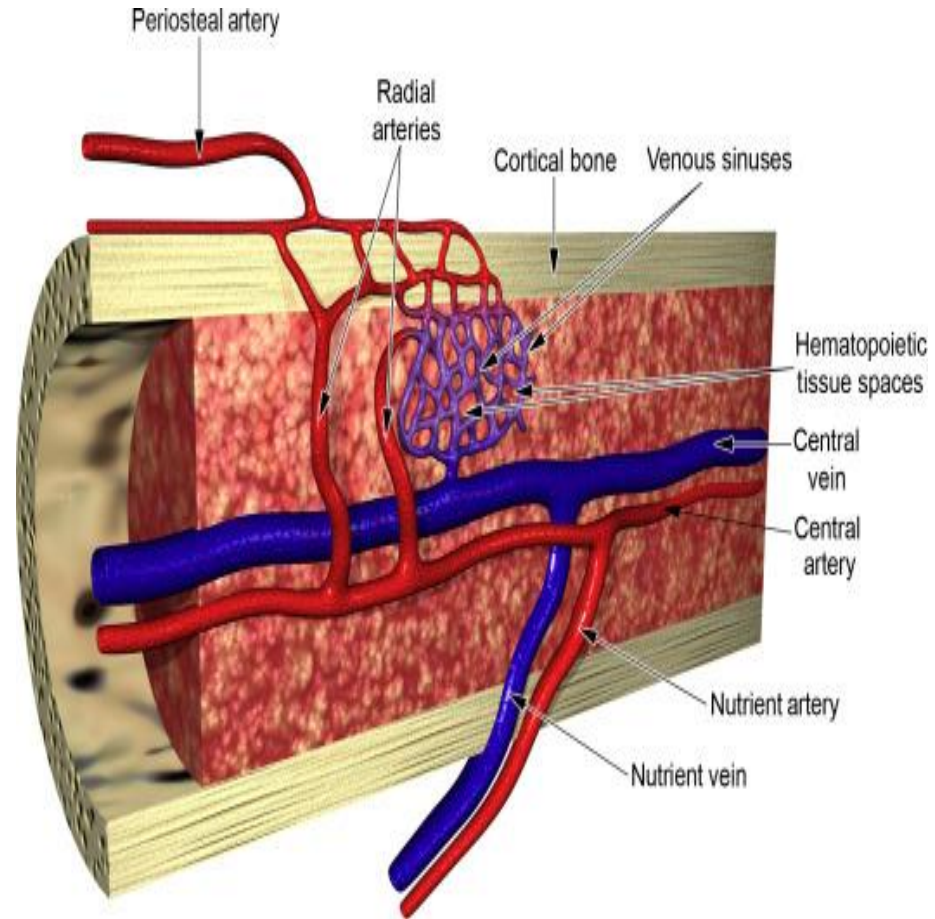
Bone marrow has :

- ❑ **vascular compartment**
- ❑ **Extravascular compartment.**

vascular compartment

The vascular compartment is supplied by

- ❑ a **nutrient** artery which branches into **central** longitudinal arteries which send out **radial** branches that eventually open into **sinuses**.
- ❑ These sinuses converge into a **central vein** that carries the blood out of the bone marrow into the general circulation.

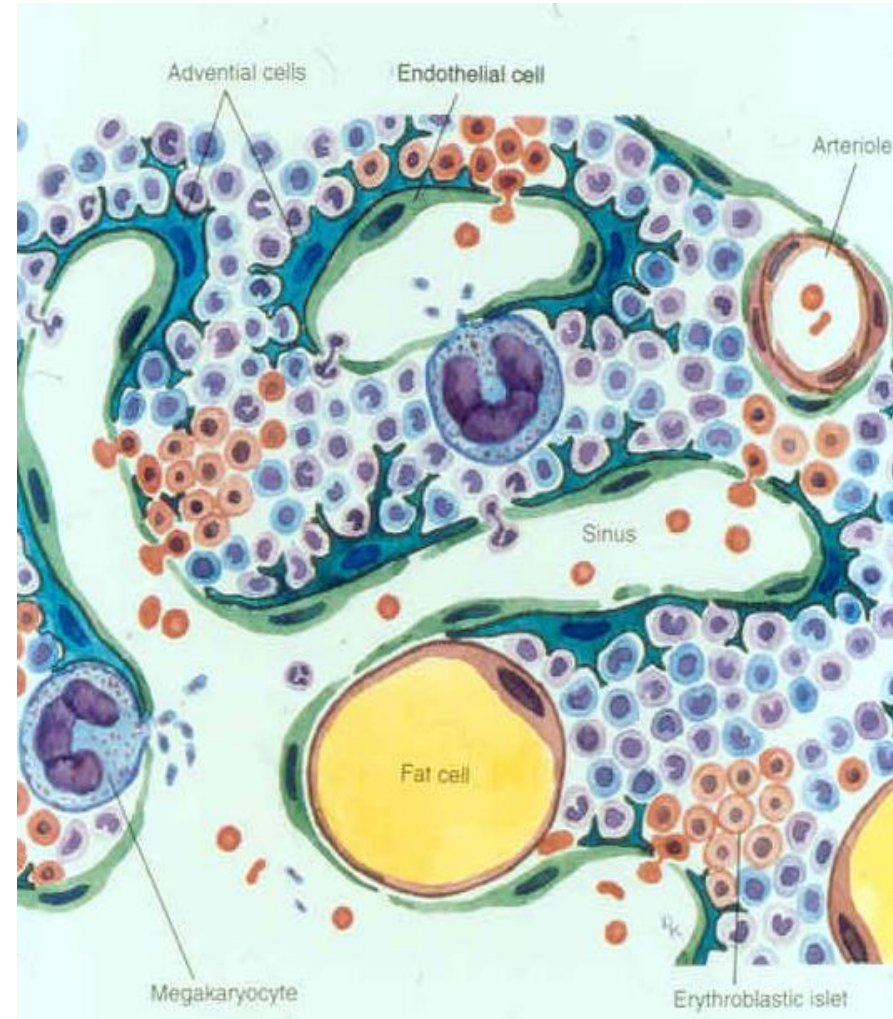


Extravascular compartment

- Hematopoiesis takes place in the extravascular compartment.
- The extravascular compartment

consists of:

- ❑ **a stroma** of reticular connective tissue
- ❑ **a parenchyma** of developing blood cells, plasma cell, macrophages and fat cells.
- Biological compartment is evident within the bone marrow, in that certain cell types tend to aggregate in specific areas.
- ❑ For instance, **erythrocytes**, **macrophages**, and their **precursors** tend to gather around **blood vessels**
- ❑ while **granulocytes** gather at the borders of the bone marrow.



Stroma

- ❑ **The stroma** of the bone marrow includes all tissue **not directly** involved in the marrow's primary function of **hematopoiesis**.
- Stromal cells may be **indirectly involved** in hematopoiesis, providing a microenvironment that influences the function and differentiation of hematopoietic cells, they generate **colony stimulating factors** , which have a significant effect on hematopoiesis.

❑ **Cell types** that constitute the bone marrow **stroma include:**

- Fibroblast (reticular cell)
- Macrophages , which contribute especially to RBCs production, as they deliver iron for hemoglobin production
- Adipocytes
- Osteoblasts (synthesize bone)
- Osteoclast (resorb bone)
- Endothelial cells which form the sinusoids. These derive from endothelial stem cells, which are also present in the bone marrow

Hematopoietic components

- At the cellular level, the main functional component of bone marrow includes the progenitor cells which are destined to mature into blood and lymphoid cells.
- ❑ Marrow contains **hematopoietic stem cells** which give rise to the three classes of blood cells that are found in circulation: WBCs (leukocytes), RBCs (erythrocytes), and platelets (thrombocytes).
- ❑ **The Pluripotent hemopoietic stem cells (PHSCs):**
 - great ability to divide.
 - 1/2 Reserve other 1/2 becomes more differentiated.

□ Multipotent hemopoietic stem cells (MHSCs):

- Daughter cells of the PHSCs.
- Histologically, **larger**
- Cell divisions but are more differentiated ►► **cell colonies** ►► **2 CFUs**

CFUs ►►► daughter stem cells more differentiated

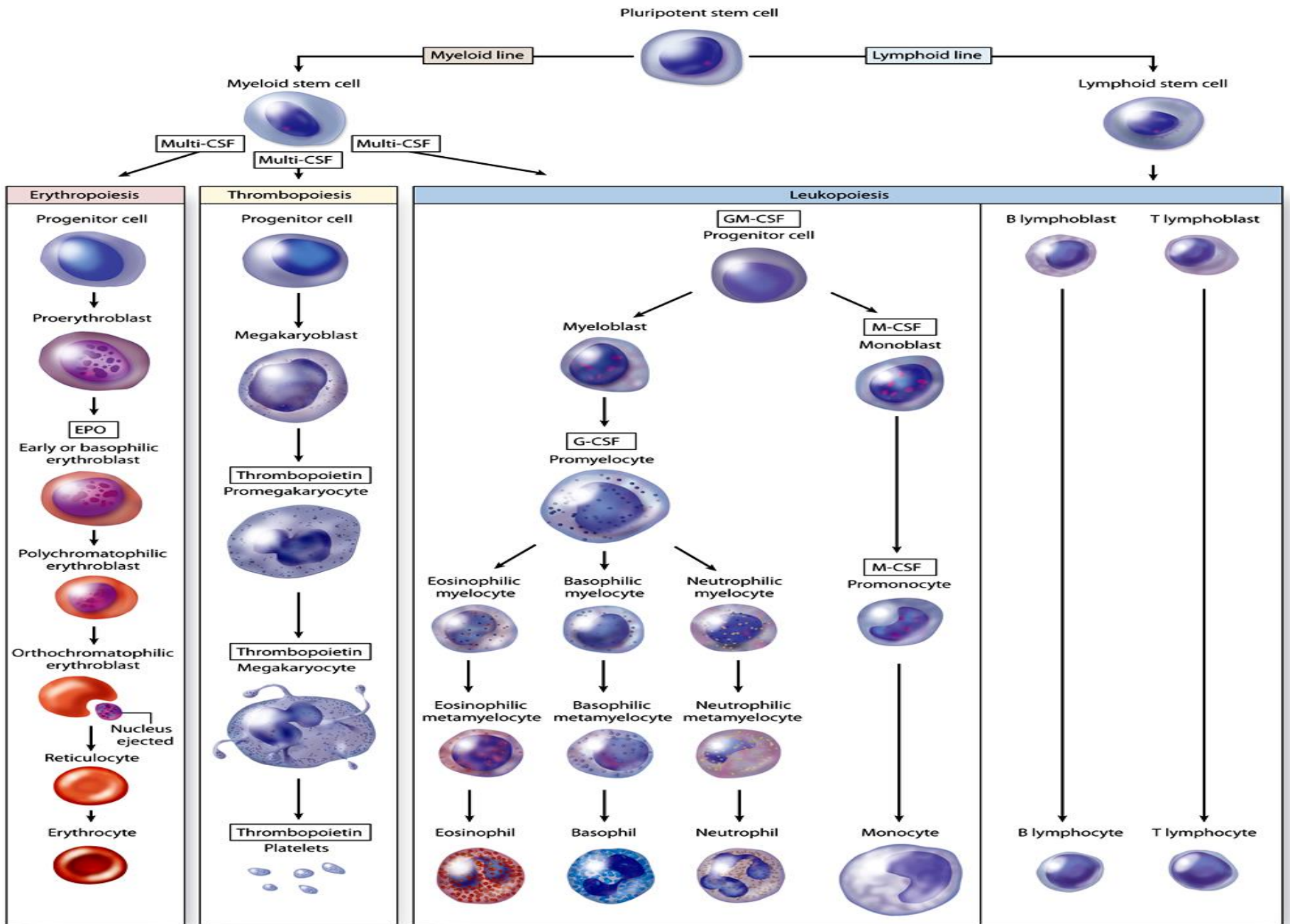
A- CFU- lymphocyte (CFU- Ly):

Some migrate to the thymus, spleen and lymph nodes where lymphopoiesis is completed.

B- CFU- erythrocyte, megakaryocyte/ granulocyte-monocyte

►► **unipotent progenitors**

- CFU-Erythrocyte (CFU- E)
- CFU-Megakaryocyte (CFU-Meg).
- CFU- Granulocyte /monocyte (CFU-GM),



Function

Bone marrow is the site for other important activities in addition to hematopoiesis.

These include:

Mesenchymal stem cells

- The bone marrow stroma contains mesenchymal stem cells (MSCs), also known as marrow stromal cells. These are **multipotent stem cells** that can **differentiate** into a variety of cell types. MSCs have been shown to differentiate, in vitro or in vivo , into osteolasts, chondrocytes, myocytes, marrow adipocytes

Bone marrow barrier

- The blood vessels of the bone marrow constitute a barrier, inhibiting immature blood cells from leaving the marrow. Only mature blood cells contain the membrane proteins, such as aquaporin and glycophorin, that are required to attach to and pass the blood vessel endothelium.
- Hematopoietic stem cell may also cross the bone marrow barrier, and may thus be harvested from blood.

Lymphatic role

- The red bone marrow is a key element of the lymphatic system , being one of the primary lymphoid organs that generate lymphocytes from immature hematopoietic progenitor cells. The bone marrow and **thymus** constitute the primary lymphoid tissues involved in the production and early selection of lymphocytes.

Hematopoiesis

Def : A process by which **blood cells** are **formed** by proliferation and differentiation of stem cells.

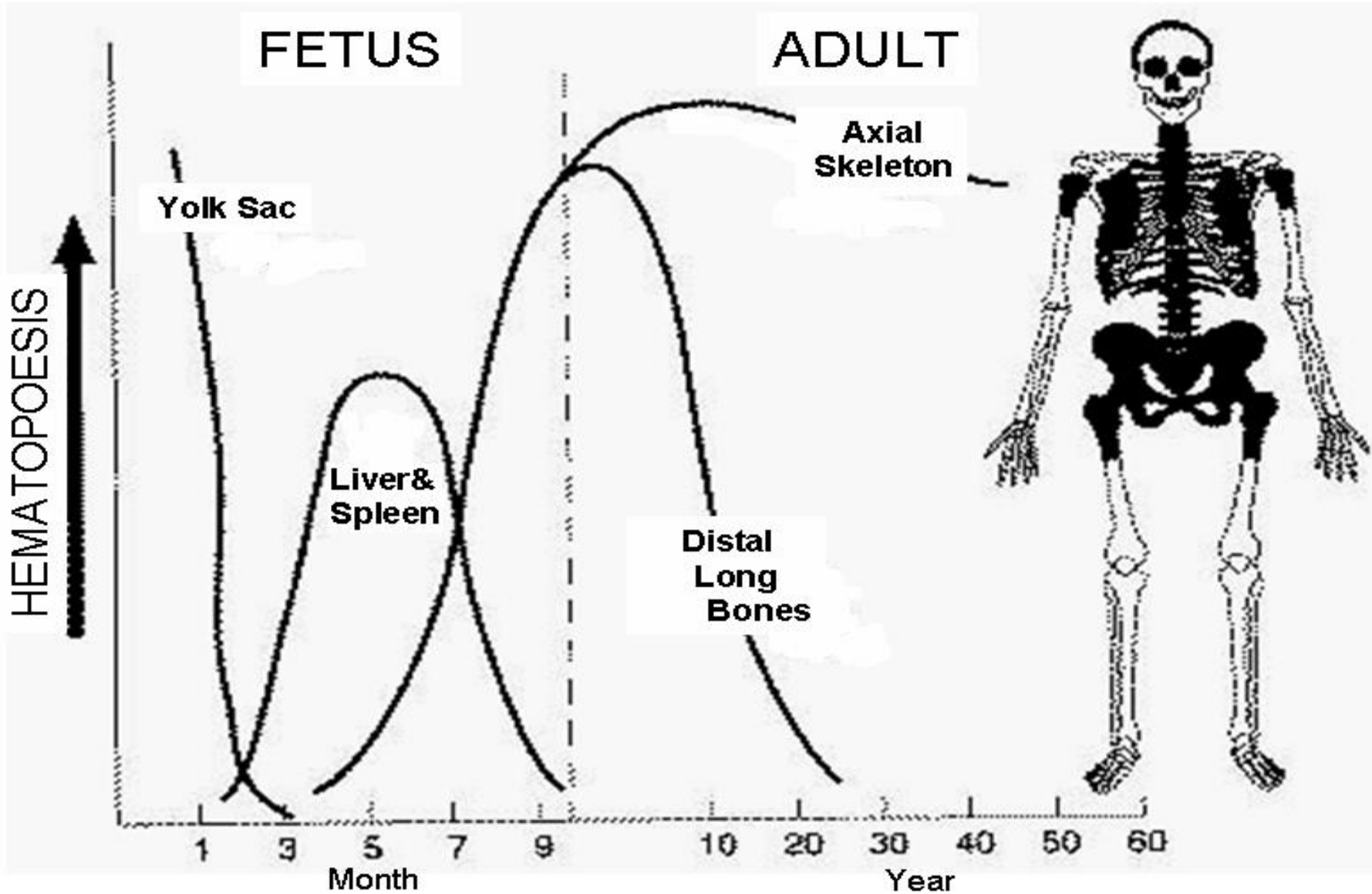
Prenatal hematopoiesis

- ❖ Yolk sac (2-8 weeks)
- ❖ Liver & spleen (8- 28)
- ❖ Bone marrow  after (22 weeks)

Postnatal Hematopoiesis

- ❖ **Prior to puberty:** skull, ribs, sternum, vertebrae, clavicles, pelvis, and long bones.
- ❖ **After puberty:** same bones except **no more shafts of long bones.**
- ❖ **Extra-medullary hemopoiesis:** liver and spleen continue to produce blood cells even after birth.

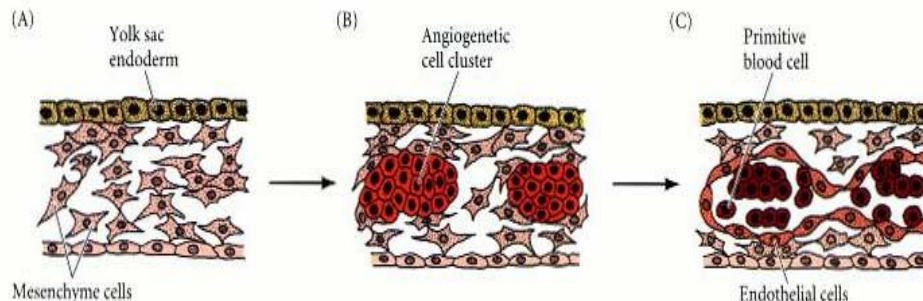
Blood Forming Organs



Prenatal hematopoiesis

1- Yolk Sac Hematopoiesis (blood islands) 2-8 weeks:

- In the yolk sac, mesenchymal cells differentiate to clusters of hemangioblast cells.
- 1-Peripheral hemangioblasts further differentiate into endothelial cells &
- 2-Central hemangioblasts give rise to **nucleated red blood cells**, **no leukocytes** are formed in this phase.



- **2- Fetal Liver & spleen Hemopoiesis:** From **8 - 28** wks;
 - *Liver and spleen are colonized by definitive hematopoietic stem cells.
 - ***Erythrocytes still have nuclei**, **leukocytes begin to appear**. All blood cell types (**except T cells**) can differentiate in the fetal liver & spleen.
 - **extra-medullary hematopoiesis
- **3- Prenatal Myeloid phase:** Bone marrow is colonized late in embryogenesis (after **22 weeks**) by definitive hematopoietic stem cells **derived from the fetal liver & spleen**.
- All blood cell types (**except T cells**) can differentiate in the bone marrow.

Postnatal hematopoiesis

Prior to puberty:

skull, ribs, sternum,
vertebrae, clavicles, pelvis, and
shafts of long bones.

After puberty:

same bones except **no more
shafts of long bones.**

Extra-medullary hemopoiesis:

liver and spleen continue to produce
blood cells even after birth

CFUs ▶▶▶ daughter stem cells
more differentiated

A- CFU- lymphocyte (CFU- Ly):

Some migrate to the **thymus,
spleen and lymph nodes**
where lymphopoiesis is
completed.

B- CFU- granulocyte / monocyte, erythrocyte, megakaryocyte (CFU-GEMM): ▶▶ unipotent progenitors

- CFU-Erythrocyte (CFU- E)
- CFU-Megakaryocyte (CFU-Meg).
- CFU- Granulocyte /monocyte
(CFU-GM),

Cell potency

Cell potency is a cell ability to differentiate into other cell types

- ❑ **Totipotency** is the ability of a single cell to divide and produce all of the differentiated cells in an organism. Zygotes are examples of totipotent cells
- ❑ **pluripotency** refers to a stem cell that has the potential to differentiate into any of the three germ layers : endoderm ,mesoderm or ectoderm but not into extra-embryonic tissues like the placenta.
- ❑ **Multipotency** for example, a multipotent blood stem cell —and this cell type can differentiate itself into several types of blood cell like lymphocytes ,monocytes ,neutrophils **Oligopotency** is the ability of progenitor cells to differentiate into a few cell types

Examples of oligopotent stem cells are the lymphoid or myeloid stem cells.

- ❑ **Unipotency** one stem cell has the capacity to differentiate into only one cell type.

•

The Myeloid Cells

1-The Pluripotent hemopoietic stem cells (PHSCs):

- great ability to divide.
- $\frac{1}{2}$ Reserve other $\frac{1}{2}$ becomes more differentiated.

2- Multipotent hemopoietic stem cells (MHSCs):

- Daughter cells of the PHSCs.
- **larger**
- Cell divisions but are more differentiated ►► **cell colonies** ►► **2** CFUs

CFUs ►►► daughter stem cells more differentiated

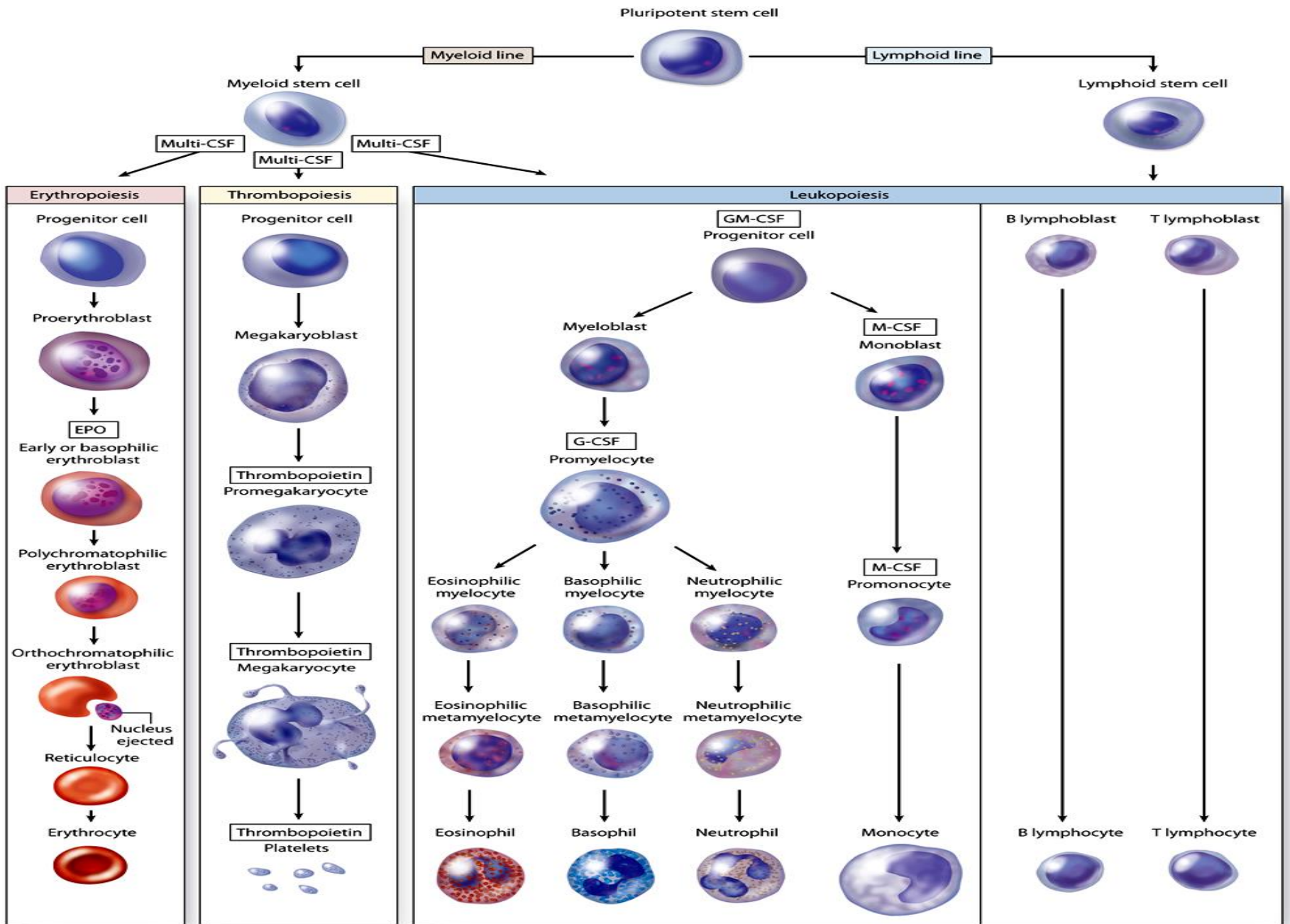
A- CFU- lymphocyte (CFU- Ly):

Some migrate to the **thymus, spleen and lymph nodes** where lymphopoiesis is completed.

B- CFU- erythrocyte, megakaryocyte/ granulocyte-monocyte

►► **unipotent progenitors**

- CFU-Erythrocyte (CFU- E)
- CFU-Megakaryocyte (CFU-Meg).
- CFU- Granulocyte /monocyte (CFU-GM),



Erythropoiesis

Formation of RBCs – Takes about **7 days**

1-UMC

2-Pluripotential hemopoietic

stem cells (hemocytoblast)

3-Restricted erythrocyte progenitor

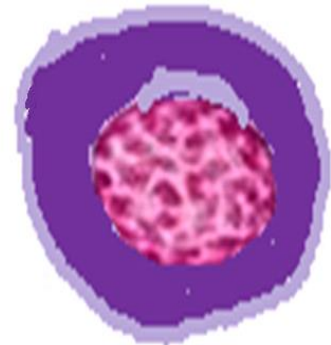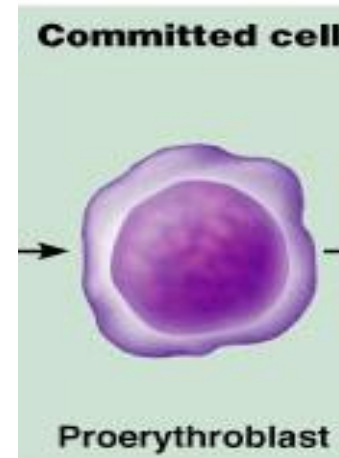
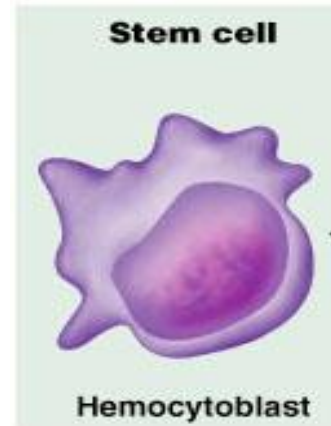(Colony-forming unit erythrocytes (CFU-E))

4- Pro- erythroblast:

- **Large.**
- basophilic cytoplasm with abundant Ribosomes.
- Large nucleus

5- Basophilic Erythroblast:

- **Most active in hemoglobin** synthesis.
- Ribosomes are ▲▲ abundant.
- Cytoplasm is strongly basophilic



Erythropoiesis

6- Polychromatophilic Erythroblast

- hemoglobin ▲▲.
- Ribosomes are still ▲▲.
- Cytoplasm shows eosinophilic areas alternating with basophilic spots.
- **Last stage** in repeated cell divisions.
- Only **morphological maturation** of the erythroblasts.

7- Orthochromatophilic Erythroblast (Normoblast):

- Synthesis of hemoglobin **is completed**.
- Ribosomes ▼▼.
- **Nucleus:**
 - is condensed and reduced in size.
 - Gradually pushed towards the periphery ►► completely extruded from the cell.
 - Phagocytosed by the bone marrow macrophages.

Erythropoiesis

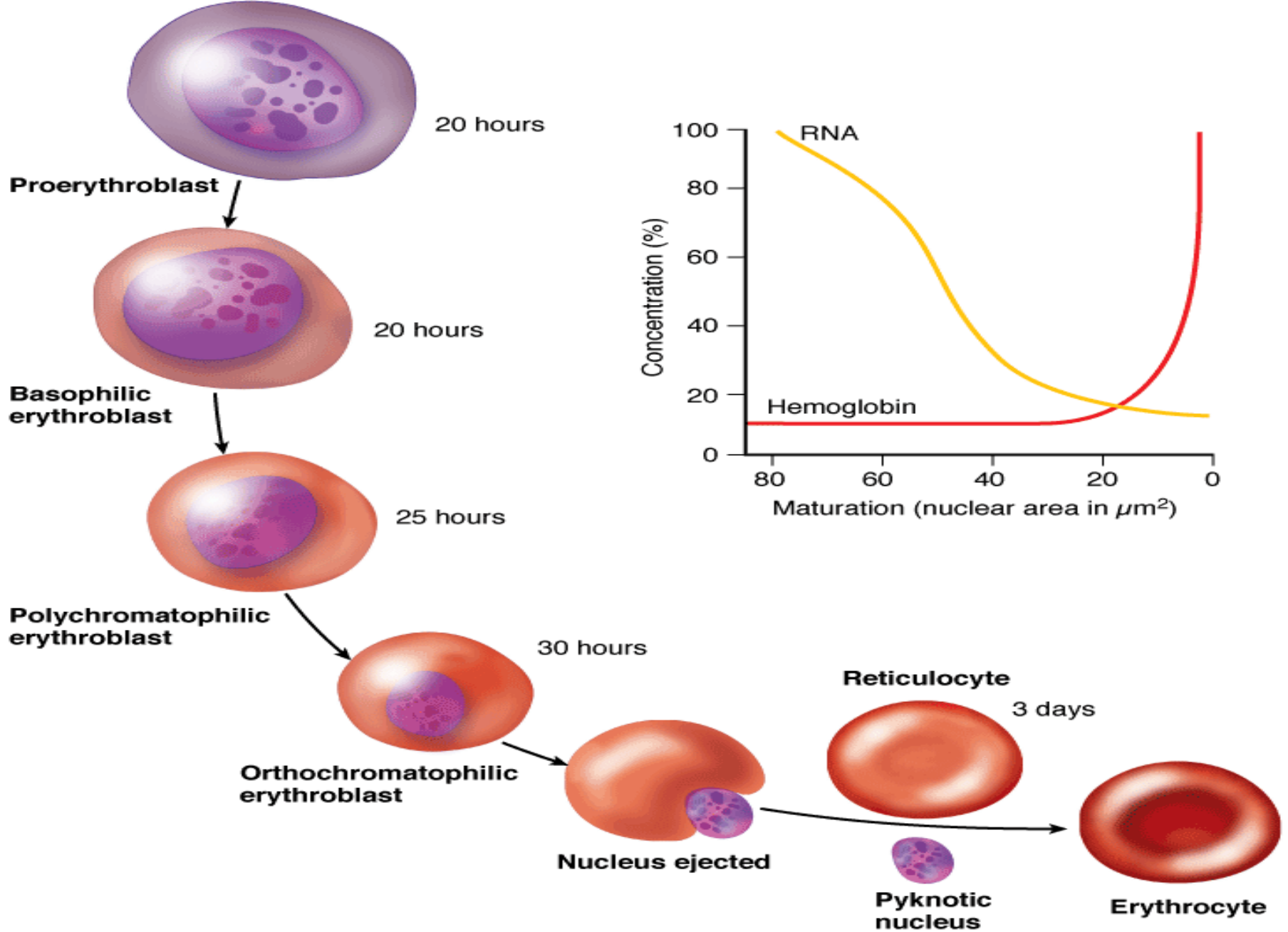
8- Reticulocytes

- immature RBCs
- non-nucleated
- differ than mature RBCs
 - slightly larger (8 μ m).
 - Cytoplasm contains remnants of ribosomes.
 - On staining with **cresyl blue** form a reticulate pattern.
- Reticulocytes represent 1% of all RBCs in normal blood film.
- **Clinical significance:**

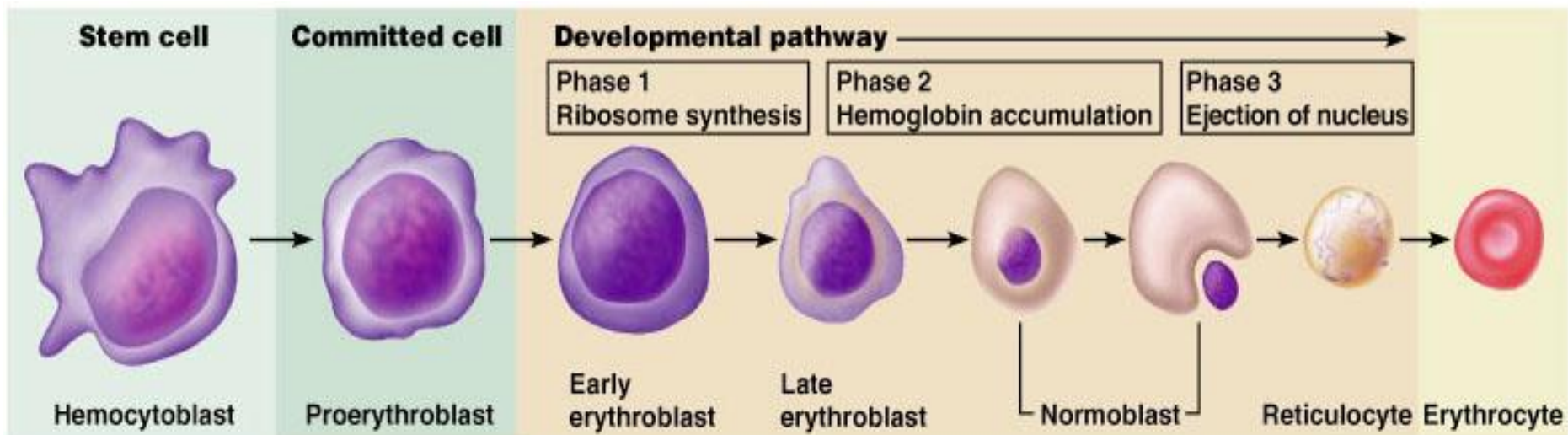
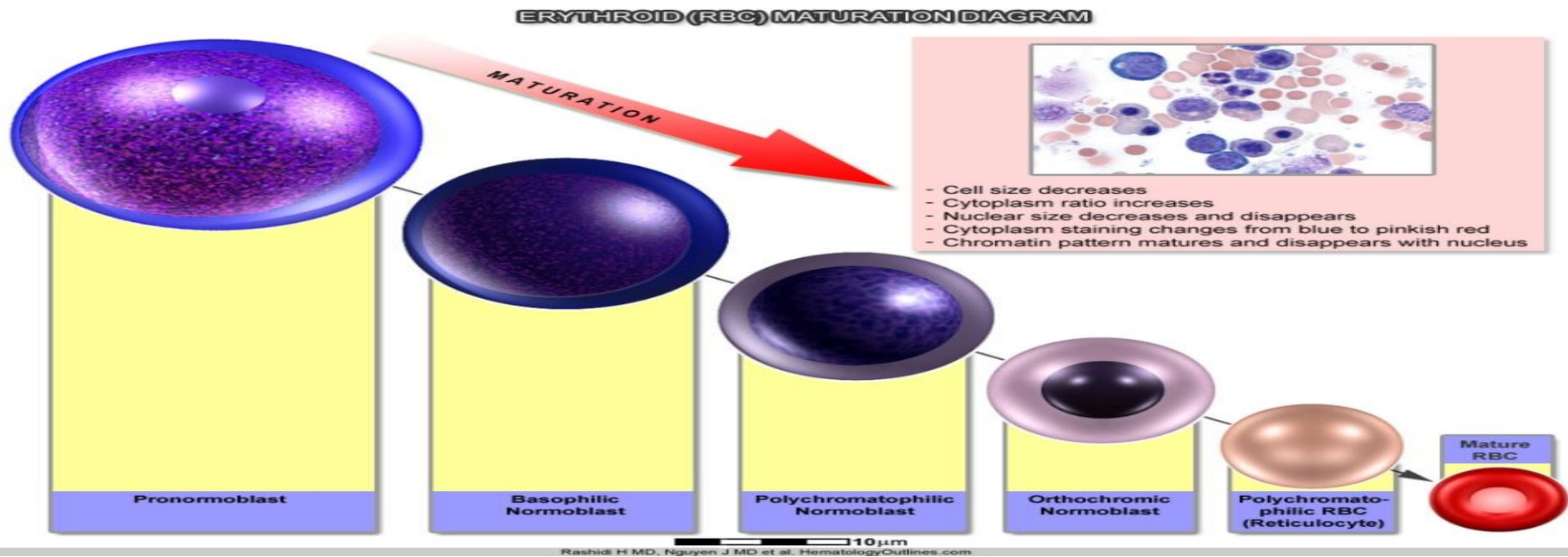
An increase in this percentage indicates an

- accelerated rate of erythropoiesis.
- compensate for anemia or hemorrhage.

9. Mature RBCs



Erythropoiesis – Staining change



THROMBOPOIESIS

Formation of platelets

Takes about **10 days**

1-UMC.

2-Pluripotential hemopoietic stem cells
(hemocytoblasts).

3-Restricted megakaryocyte progenitor
(Colony-forming unit (CFU-Meg).

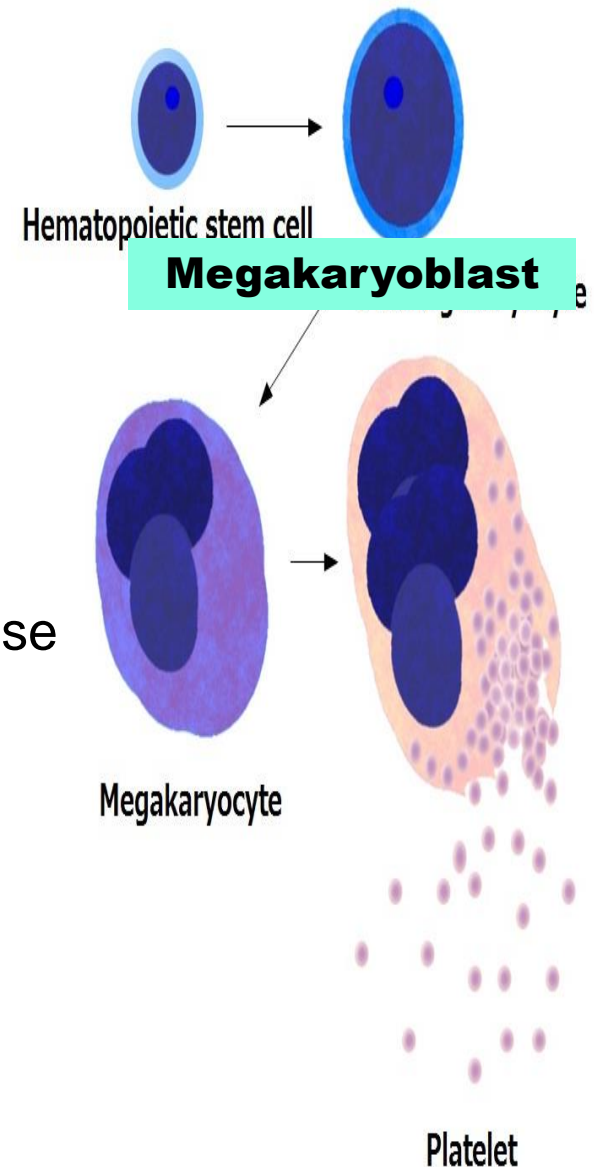
4-Megakaryoblast: numerous nucleoli,
multiplication of nuclear DNA (**polyploidy**), intense
basophilic cytoplasm.

5.Promegakaryocyte: **lobulated nucleus** +
multiple granules (clotting factors, lysosomes)

6-Megakaryocyte

→ demarcation membranes

→ **platelets.**



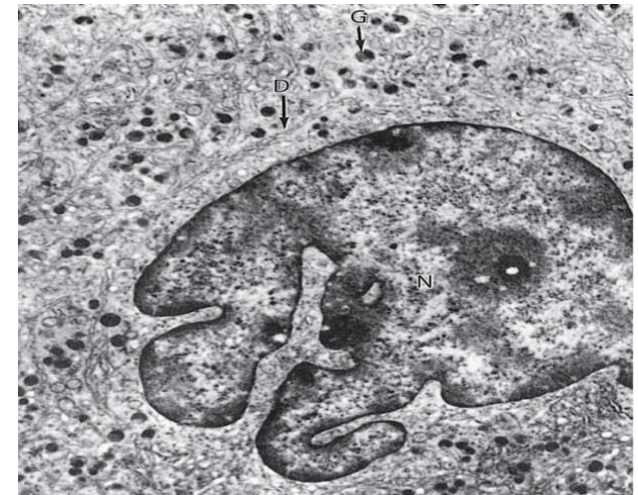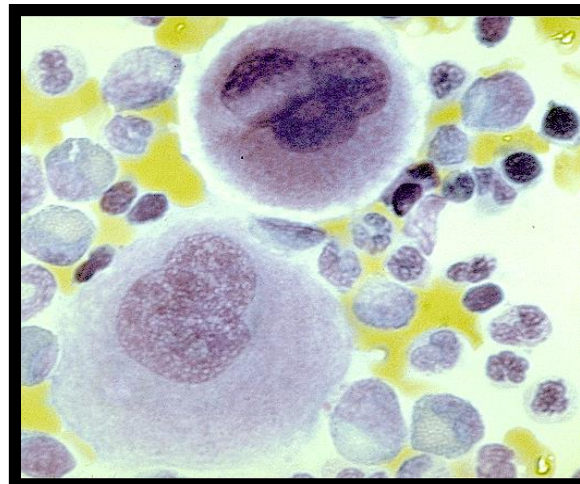
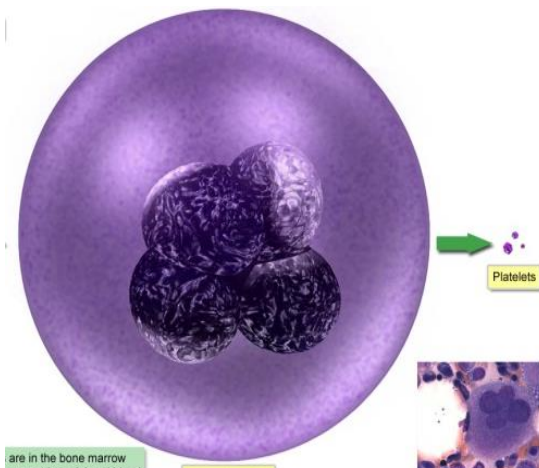
Megakaryocyte

LM

- Giant cell (150 μ).
- Nucleus:
 - Lobulated.
 - Polyploid.
- Cytoplasm:
 - Filled with many organelles.
 - 3 types of granules.

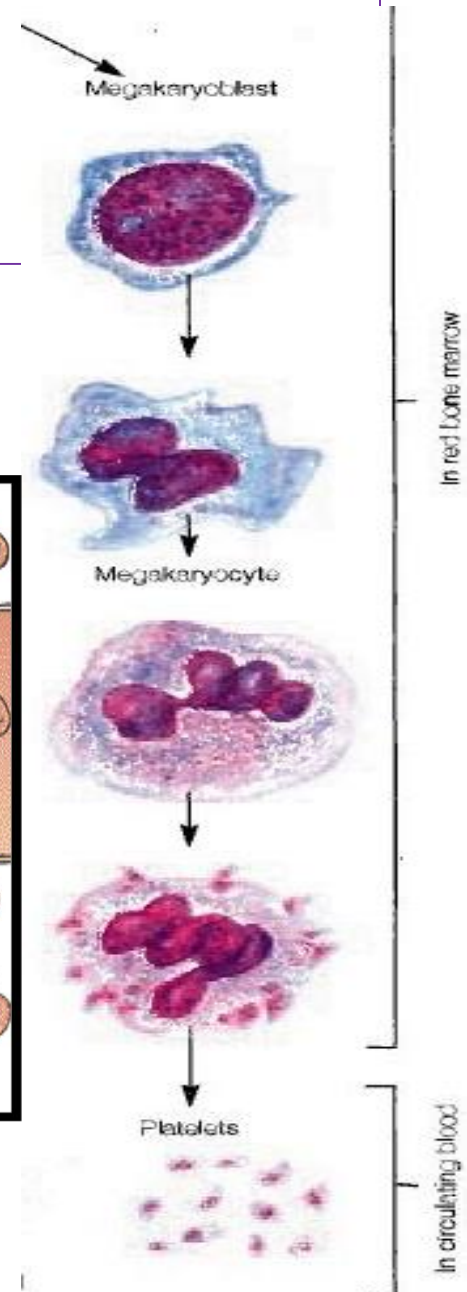
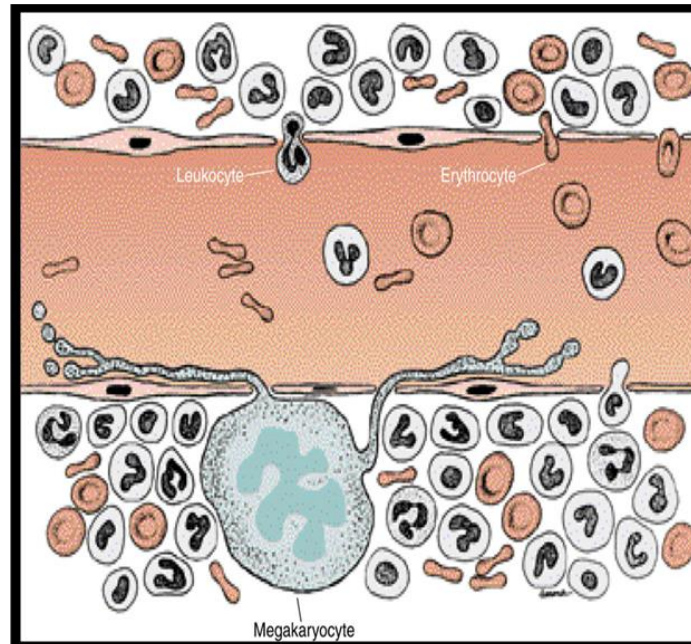
EM

- Lobulated nucleus + numerous cytoplasmic granules (Alpha, Delta, Lambda)
- Membranous demarcation lines around the granules ▼ ▼
- Lines of cleavage.



Megakaryocyte- release of platelets

- Megakaryocytes are located near BM sinusoids.
- Extend cytoplasmic processes:
 - ▼ ▼
- release of platelets into blood stream.
- **1200 platelets / megakaryocyte**



LEUKOPOIESIS

CFUs ▶▶▶ daughter stem cells more differentiated

A- CFU- lymphocyte

(CFU- Ly):

Some migrate to the **thymus, spleen and lymph nodes** gland where lymphopoiesis is completed.

B- CFU-

granulocyte/monocyte, erythrocyte, megakaryocyte
(CFU-GEMM):

▶▶ **unipotent progenitors**

- CFU-Erythrocyte (CFU- E)
- CFU-Megakaryocyte CFU-Granulocyte /monocyte (CFU-GM),

Granulopoiesis

- begins from a **hematopoietic** stem cell .
- These are **multipotent** cells that reside in the bone marrow niche and have the ability to give rise to all hematopoietic cells, as well as the ability of self renewal
- They give rise to either a common lymphoid progenitor or a common myeloid progenitor
- An **oligopotent** progenitor cell, that gives rise to the myeloid part of the hematopoietic tree.
- The first stage of the myeloid lineage is a granulocyte - monocyte progenitor (GMP), still an oligopotent progenitor
- then develops into **unipotent** cells that will later on form a population of **granulocytes**, as well as a population of **monocytes** .
- The first unipotent cell in granulopoiesis is a **myeloblast**

Granulopoiesis

1-UMC

2-Pluripotential hemopoietic stem cells (**hemocytoblasts**)

3-Restricted granulocyte progenitor, that are called (Colony-forming unit granulocytes (**CFU-G**))

4-Myeloblast

5-Promyelocyte :(nonspecific granules)

6-Myelocyte :

(specific granules N,E,B.....?)

7-Metamyelocyte:

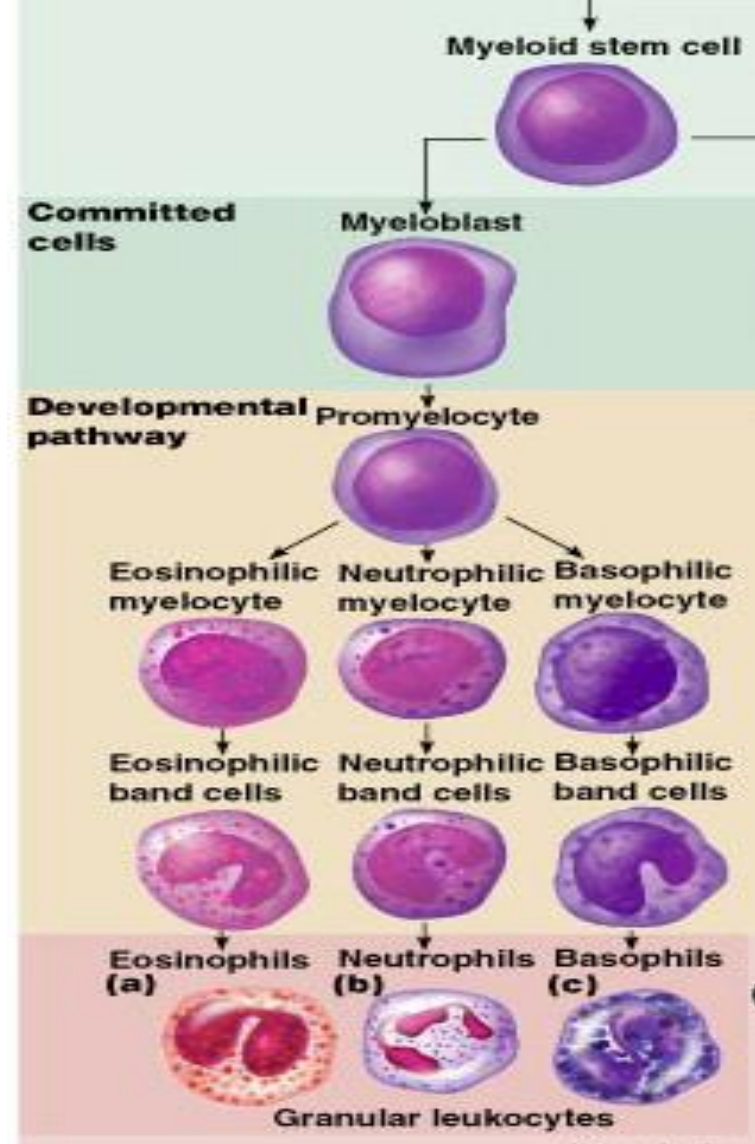
(specific granules N, E,B +**indentation of nucleus**)

8-Band cell

Smaller cells ,curved band nuclei ,**cannot divide**. May be present in peripheral blood.

9-Mature cells: (Neutrophils ,Eosinophils Basophils)

Takes about 10-11 days



Monopoiesis

1-UMC

2-Pluripotential

hemopoietic stem cells

(hemocytoblasts)

3-Restricted monocyte

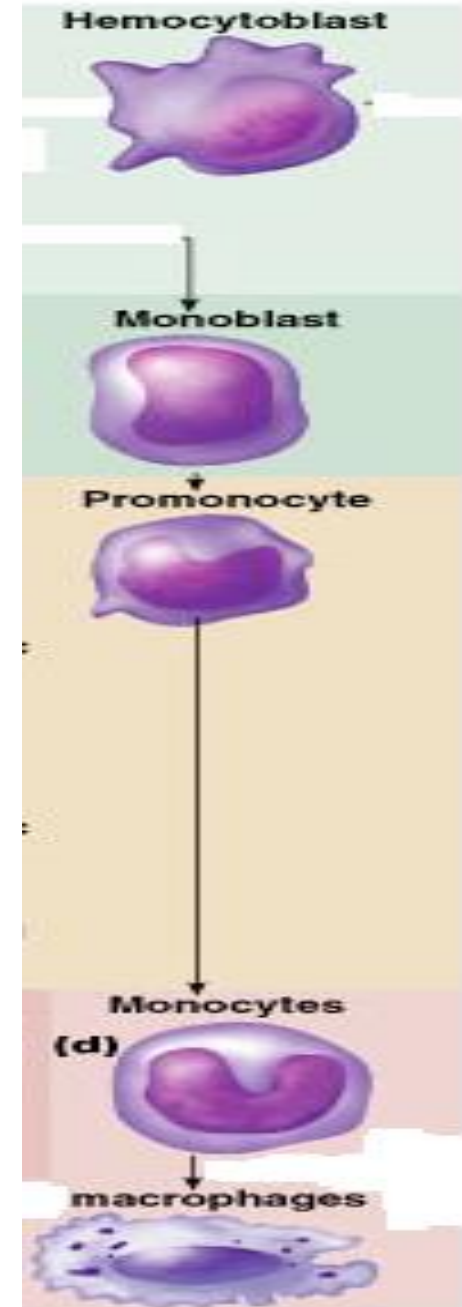
progenitor

(CFU-M) or with (CFU GM)

4-Monoblast.

5-Promonocyte : indented nucleus + lysosomes.

6-Mature monocyte : 2 days in blood stream, then → tissue macrophages for several months.



Lymphopoiesis

Takes place in 1ry lymphoid organs

BM , Thymus

1-UMC

2-Pluripotential hemopoietic stem cells

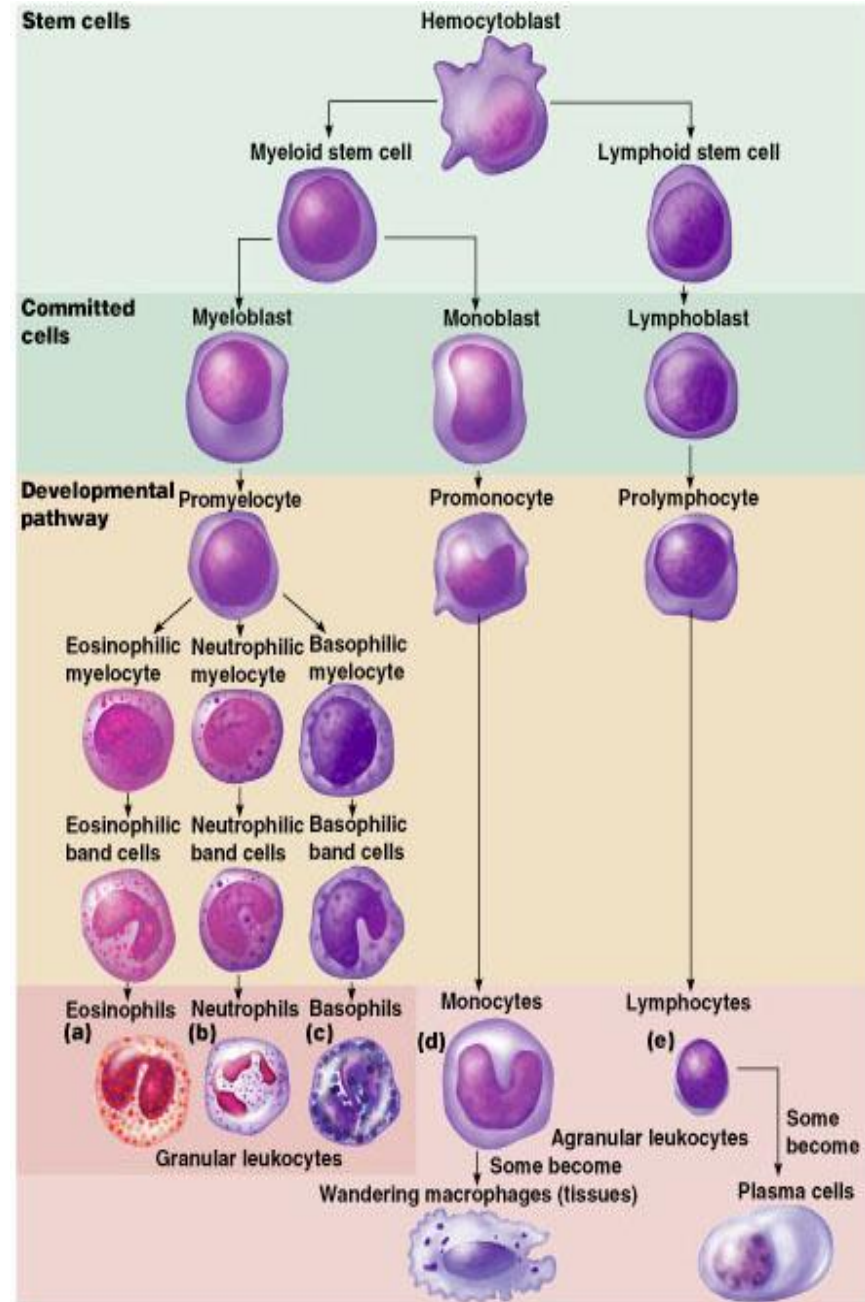
3-Restricted lymphocyte progenitor (Colony-forming unit (CFU-L))

4-Lymphoblasts

5- Prolymphocytes

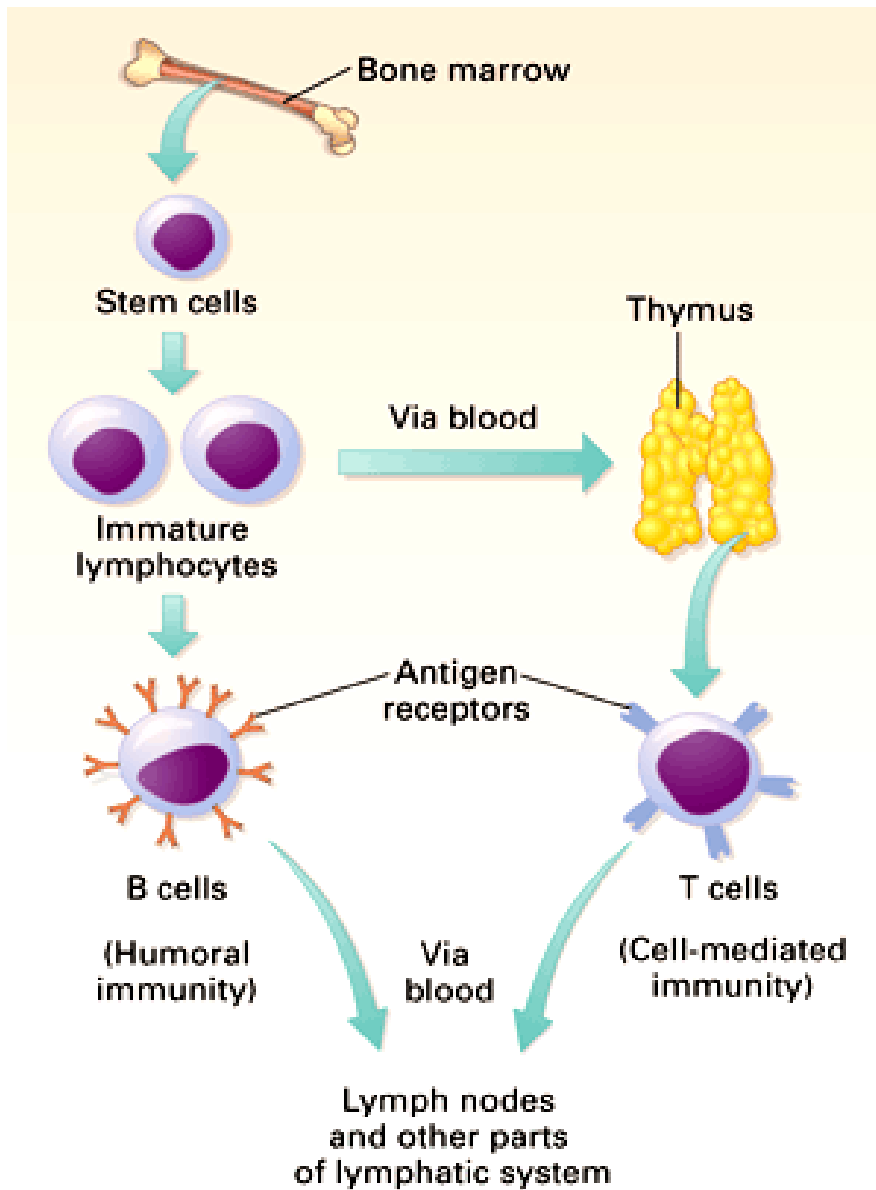
6-Lymphocytes.....

(B, T (precursors) & Null cells?)

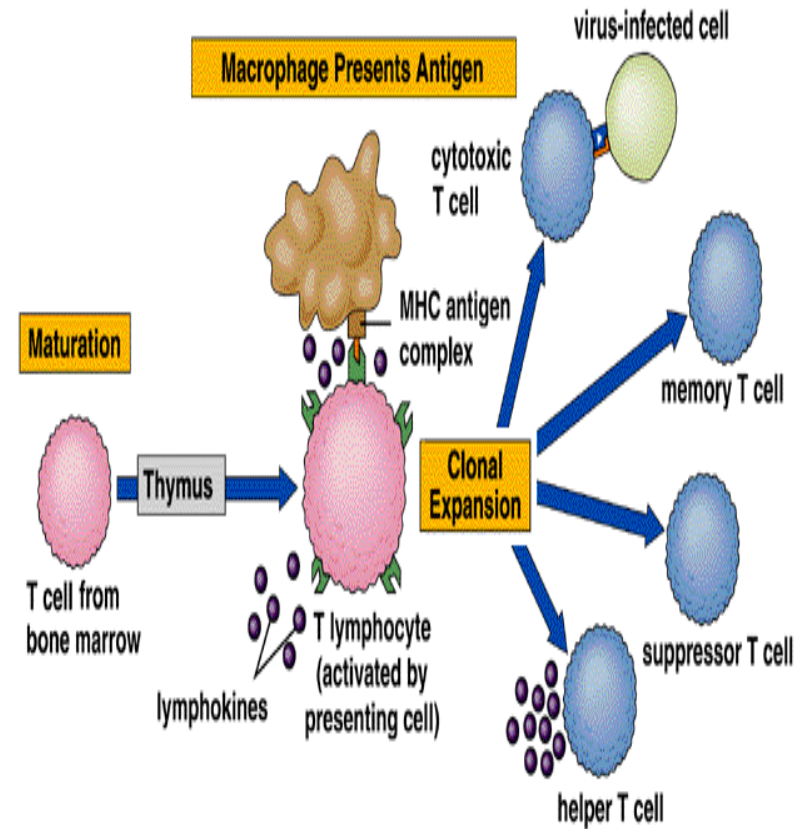


LYMPHOPOIESIS

- **Definition & sites.**
 - **Involves the following:**
 1. **PHSCs.**
 2. **MHSCs.**
 3. **CFU-Ly:**
 - **Some daughters migrate to thymus**
 - **▶▶ CFU- LY T, where:**
 - ❖ **Reside in outer cortex ▶▶**
 - ❖ **T- lymphoblasts:**
 - **Repeated mitosis.**
 - **Azurophilic granules.**
 - **Express surface markers.**
 - ❖ **Thymus ---Mature T- lymphocyte--**
 - ▶▶ **peripheral lymphoid org**
- **Definition & sites.**
 - **Involves the following:**
 1. **PHSCs.**
 2. **MHSCs.**
 3. **CFU-Ly:**
 - **Some daughters remain in bone marrow**
 - **▶▶ CFU- LY B, where: ▶▶**
 - ❖ **B- lymphoblasts:**
 - **Repeated mitosis.**
 - **Azurophilic granules.**
 - **Express surface markers.**
 - ❖ **Mature B- lymphocyte---- ▶**
 - ▶ **peripheral lymphoid organs.**



T-Cell Activation and Diversity



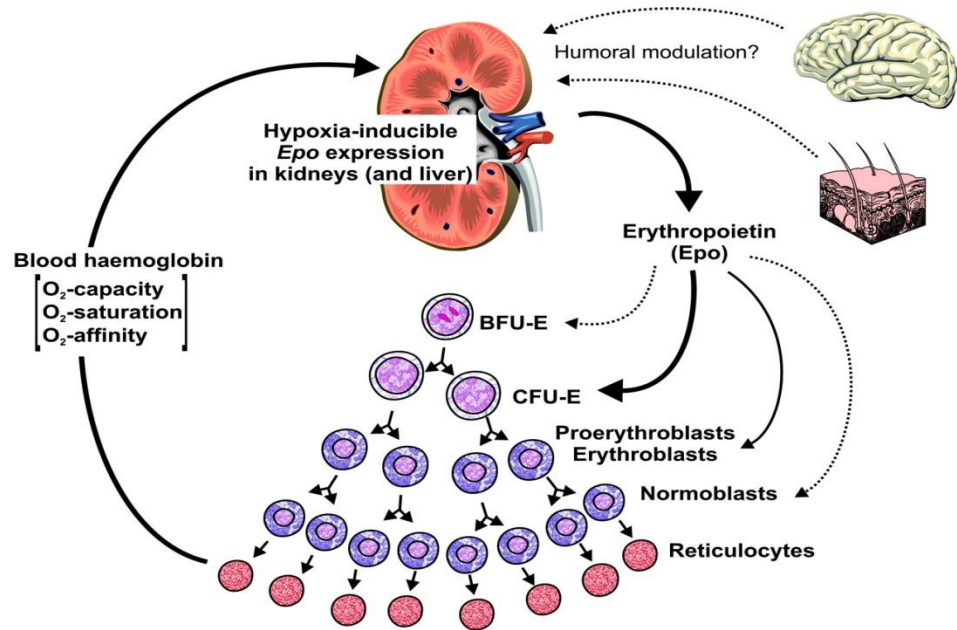
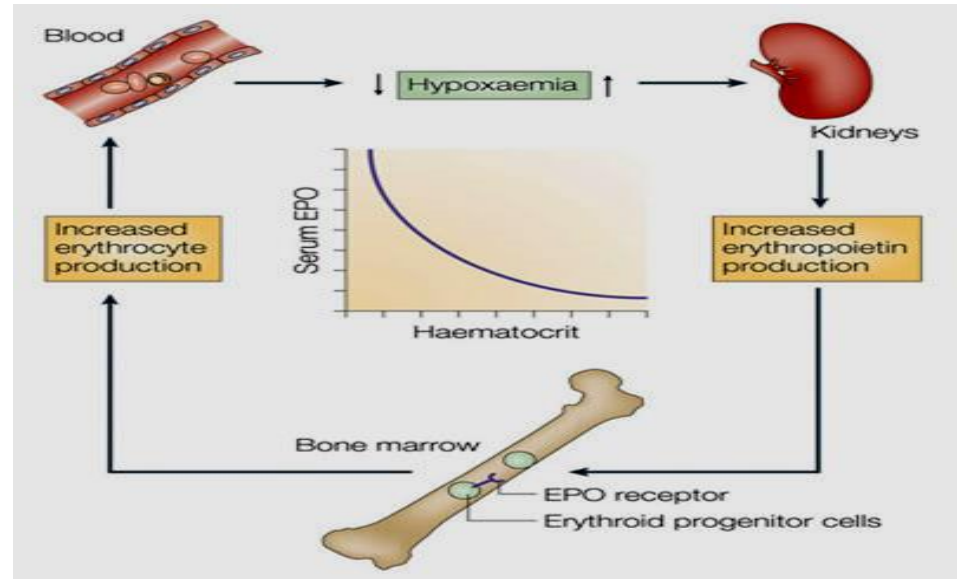
FACTORS AFFECTING HAEMOPOIESIS

- **Stimulated by:**

1. Erythropoietin.
2. Thyroxin.
3. Growth hormone.
4. Testosterone.

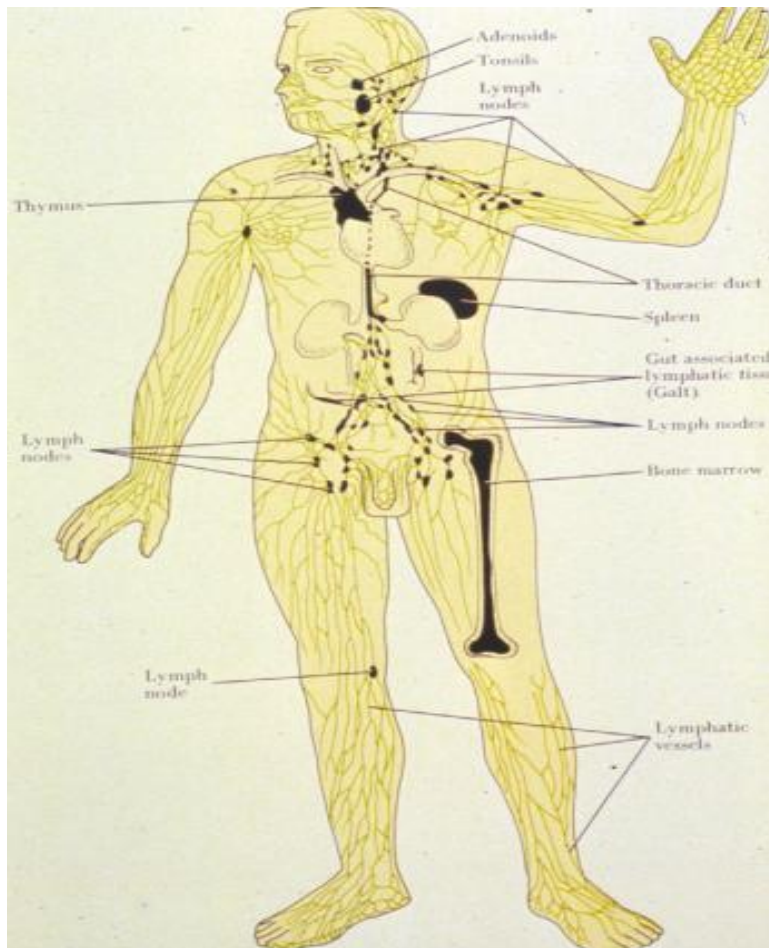
- **Inhibited by:**

- 1- Estrogen.
- 2- Nutritional deficiency.



immune system

- All **cells** and **structures** distributed throughout the body that Protect the body from invasion of micro-organisms or foreign substances



Body defense Mechanisms

1. **Surface protective mechanisms**
2. **The innate immune system**
 - **Non –specific immune response**
 - acts rapidly & has **no** immunological memory e.g.
 - ❖ Complement system
 - ❖ Phagocytic cells
 - ❖ Natural –Killer cells
3. **The adaptive immune system:** able to distinguish self from non-self
 - **Specific immune response**
 - specificity & diversity
 - has memory,
Its contents are : T & B lymphocytes & APCs
 - **Humoral immunity** Against antigens
 - **Cell mediated immunity** Against tumor, transplant cells, virus infected cells & microorganisms

Lines of Defense

Break the cycle of transmission

Physical Barrier

- Skin: Stratum Cornium
- HCl In Stomach
- Mucus In Intestines

First Line: Phagocytes to the **K**ill infectious agent

Neutrophils

Monocytes → macrophage

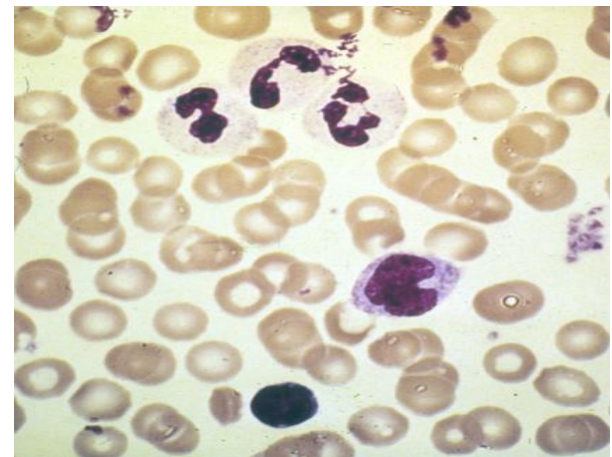
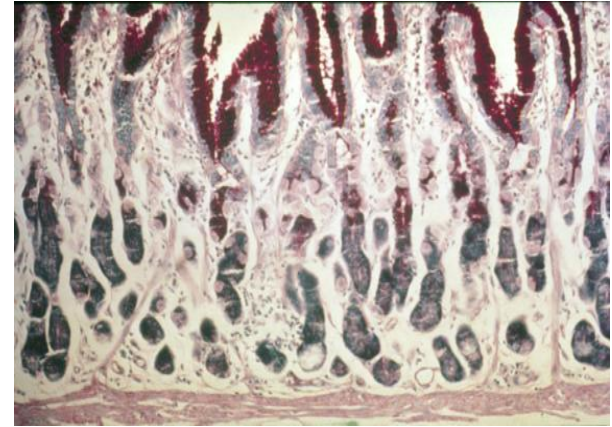
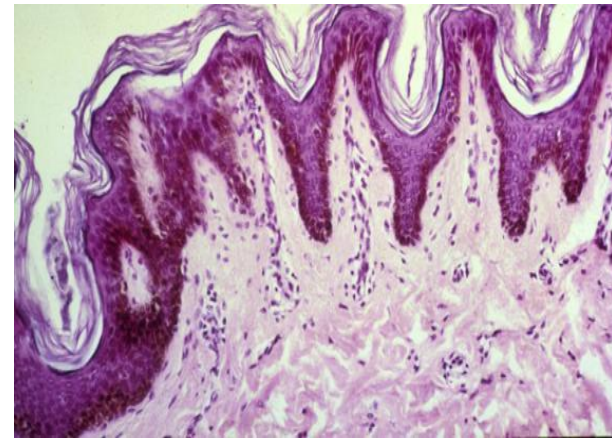
Increase host resistance

Characteristics of Immunity

Acquired - requires exposure to antigens

Specificity - response is unique to exposure

Memory - remembers previous exposure



Immune system

Cells

❑ Fixed cells -

- **Reticular cells** - connective tissue cells that may secrete a fine matrix of reticular fibers that these cells extend cytoplasmic processes
- **Follicular dendritic cells (FDCs)** – appear similar to reticular cells in shape, but are really a type of macrophage - found in the germinal centers of lymph nodes. These cells bind foreign antigens and interact with lymphocytes as antigen presenting cells.

❑ Free cells

- 1. macrophages
- 2. various classes of lymphocytes (B and T)

Lymphoid organs

1ry = Central

- ❑ Bone marrow
- ❑ Thymus gland

2- 2 ry = Peripheral

- ❖ Lymph nodes
- ❖ Spleen
- ❖ Tonsils
- ❖ MALT

Cells of the immune system

❑ Macrophages

❑ Antigen – presenting cells

- ❖ Dendritic cells
- ❖ Macrophages
- ❖ B- lymphocytes
- ❖ Epithelial reticular cells

Express **both MHC I & II** on their cell membrane

❑ Granular leucocytes(N,E,B)

❑ Mast cell

❑ Lymphocytes (B ,T, natural killer)

❑ Lymphocytes

Arise in the red bone marrow, they protect the body against antigens

Types of lymphocytes

- ❑ **T-lymphocytes** (T cells):
mature in the thymus, directly attack and destroy foreign cells
- ❑ **B-lymphocytes** (B cells):
mature in the bone marrow, produce plasma cells that manufacture antibodies
- ❑ **NK (natural killer)** cells (non-specific immunity) = they mature in the bone marrow

Lymphatic system

- It is part of the **circulatory** system and an important part of the immune system.
- It returns fluids that have leaked from the circulatory system back to the blood

Lymphatic system consists of :

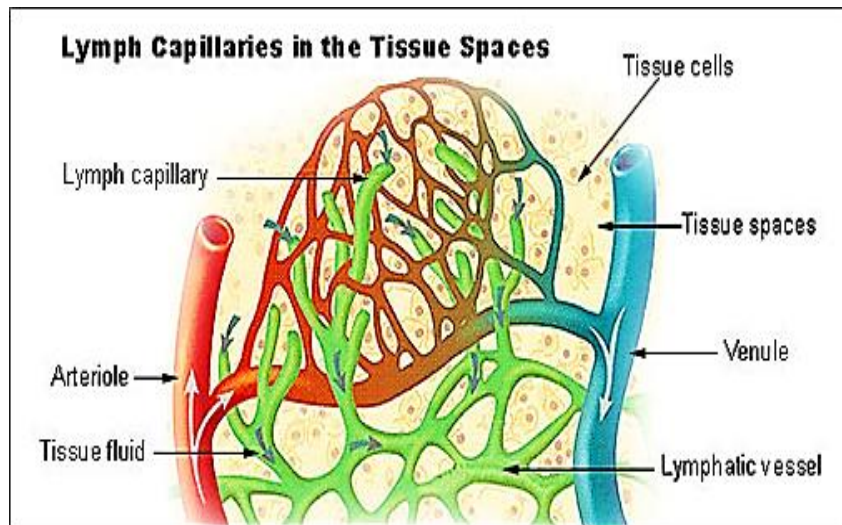
- ❖ Lymph vessels
- ❖ Circulating lymph
- ❖ Lymphoid tissues (organs)

Functions of lymphatic system

- ❑ Lymphatic system maintains the balance of fluid in the blood versus the tissues (fluid homeostasis)
- ❑ It facilitates absorption of fats and fat-soluble nutrients in the digestive system.
- ❑ It is part of the immune system and helping defend against foreign bodies such as bacteria
- ❑ Involved in production of lymphocytes and plasma cells

Lymphatics (lymphatic vessels)

- Lymphatic Vessels – Originate as lymph capillaries – Capillaries unite to form larger lymph vessels • Resemble veins in structure • Connect to lymph nodes at various intervals
- **lymphatic vessels**, conduct the lymph between different parts of the body. Lymphatics are resemble veins in structure except, that their coats are thinner and that these have numerous valves.



Lymph is protein rich fluid that circulates throughout the lymphatic system.

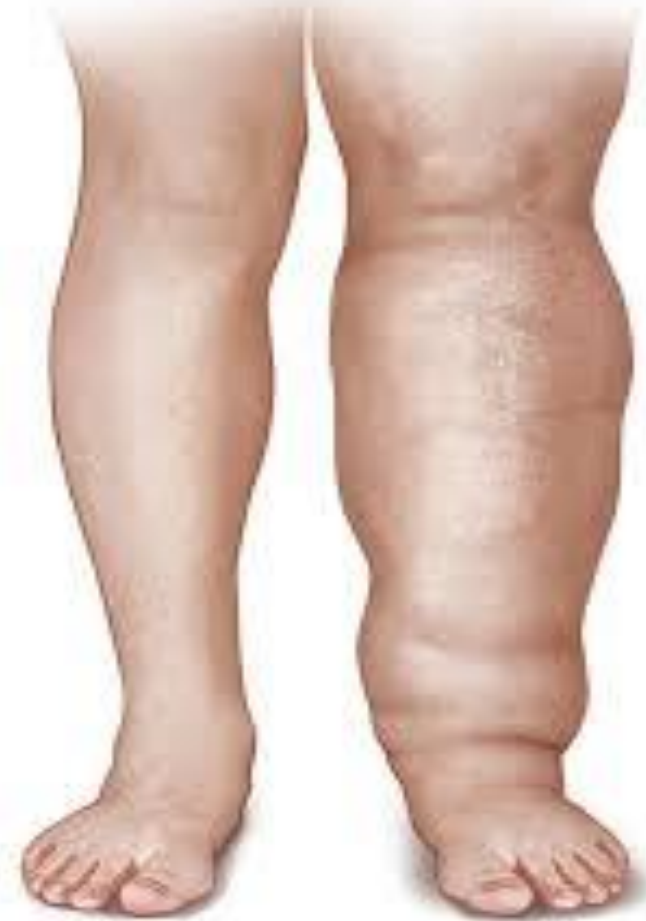- It is formed, when the interstitial fluid (the fluid which lies in the interstices of all body tissues) is collected through lymph capillaries, then transported through larger lymphatic vessels to lymph nodes, where it is cleaned by lymphocytes, before emptying ultimately into the right or the left subclavian vein, where it mixes back with the blood.

Lymphoedema is a long-term (chronic) condition that causes swelling in the body's tissues. It can affect any part of the body, but usually develops in the arms or legs.

- It develops when the lymphatic system does not work properly. The lymphatic system is a network of channels and glands throughout the body that helps fight infection and remove excess fluid.

There are 2 main types of lymphoedema:

- **primary lymphoedema** – caused by faulty genes that affect the development of the lymphatic system; it can develop at any age, but usually starts during infancy, adolescence, or early adulthood
- **secondary lymphoedema** – caused by damage to the lymphatic system or problems with the movement and drainage of fluid in the lymphatic system; it can be the result of a cancer treatment, an infection, injury, inflammation of the limb, or a lack of limb movement



Lymphatic system organs

- 1-**The primary or central lymphoid organs**, that generate lymphocytes from immature progenitor cells.

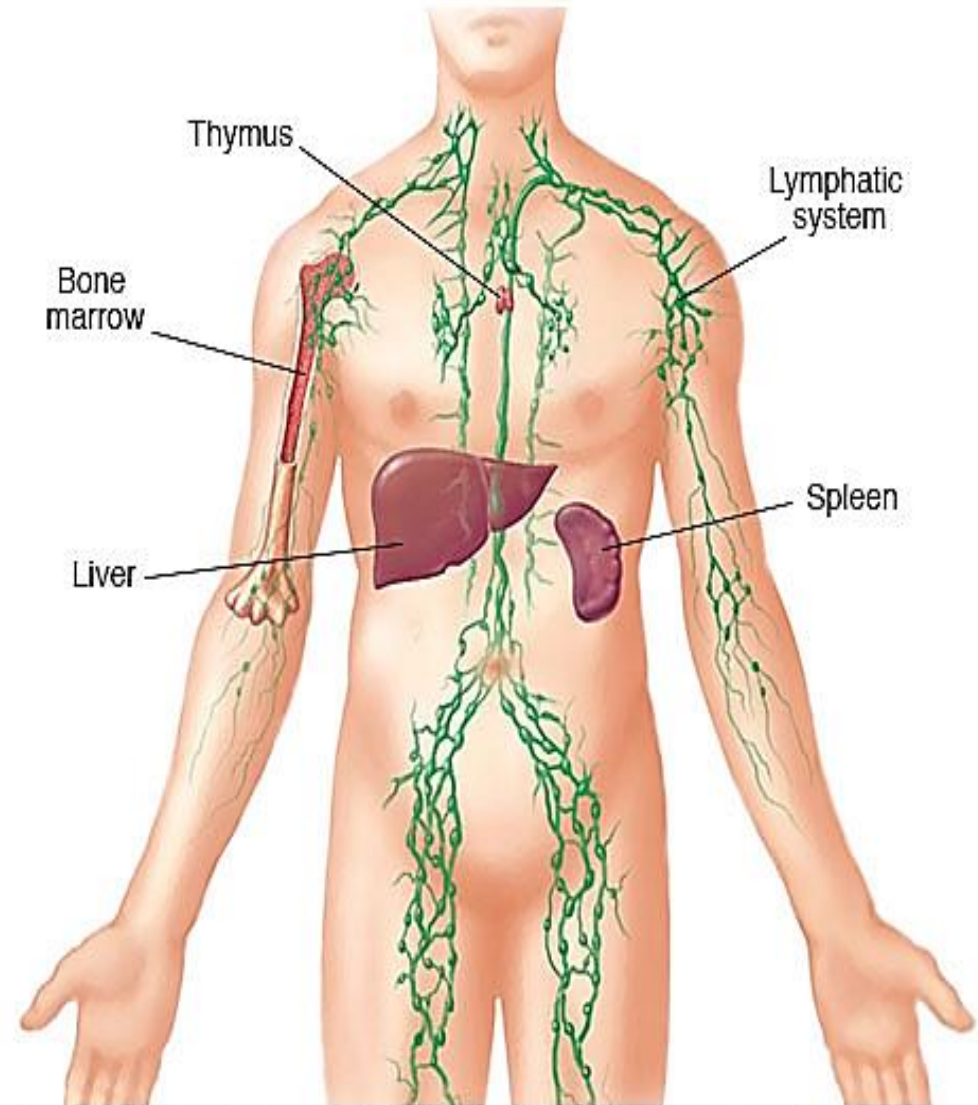
1^{ry} = central lymphatic organs

BM, Thymus

- 2-**Secondary or peripheral lymphoid organs**, which include:

2^{ry} lymphatic organs

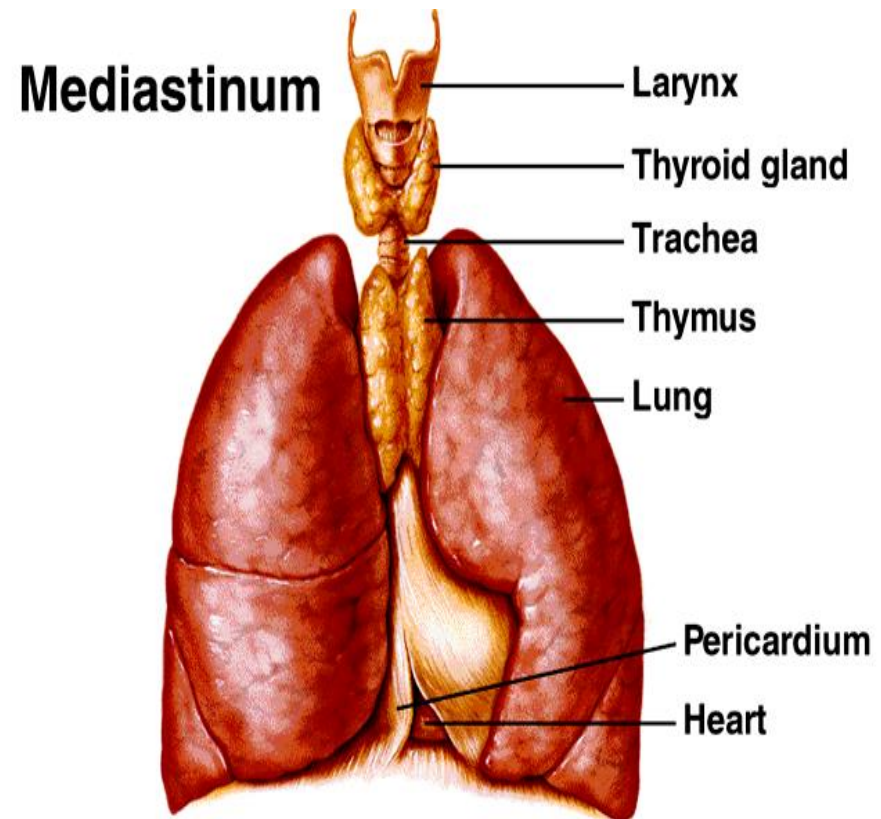
- **Lymph node**
 - **Spleen**
 - **Lymphatic nodules**
1. **Solitary**
 2. **Aggregations**
- **Tonsil**
 - **Peyer's patches**
 - **Appendix**



Central lymphoid organs

Thymus gland

- The thymus is the site of maturation for T cells. The thymus increases in size from birth in response to **postnatal antigen stimulation.**
- **Basic structure of lymphatic organs:**
- **1-Stroma** (Connective tissue component):
- capsule ,trabeculae (septa), **reticular C.T.**
- **2-Parenchyma** (functioning component): lymphocytes, macrophages (& or) epithelial cells with special arrangement.



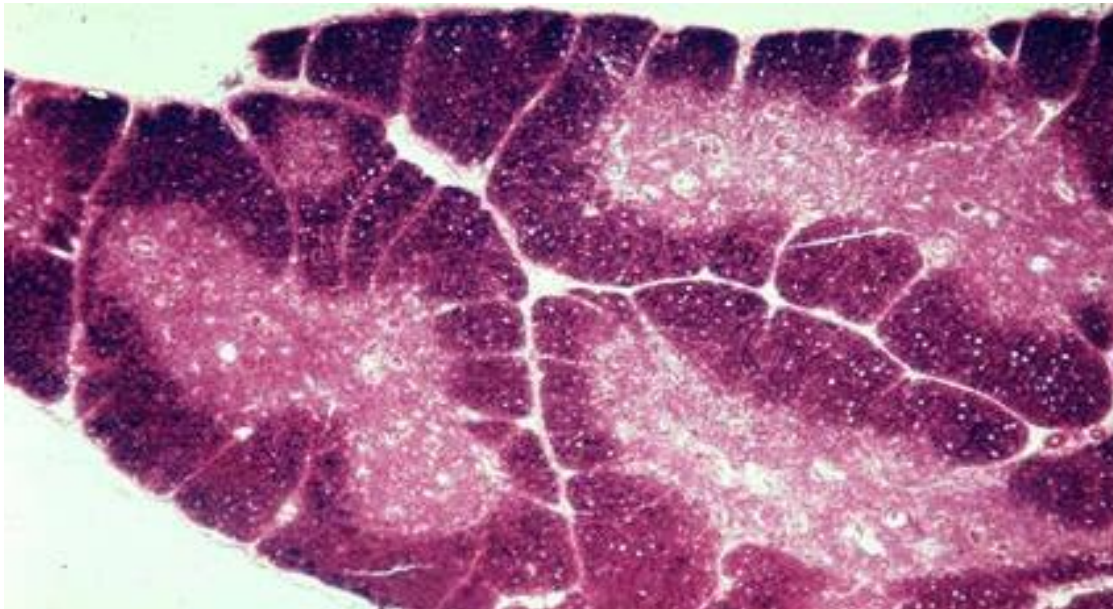
Thymus gland

A-Stroma

1. Capsule
2. Trabeculae
3. NO reticular F

B- Parenchyma

- 1- Cortex
- 2- Medulla



Thymus gland

Structure:

1- Stroma: C.T component (capsule, trabeculae (septa)...lobes & lobules

No reticular fibers

The organ is highly lobulated and is invested by a loose connective tissue capsule.

* From the capsule, connective tissue septa containing blood vessels penetrate the substance of the organ, forming lobes.

* Thin septa divide the lobes into incomplete lobules with common medulla.

2-Parenchyma: (functioning component)

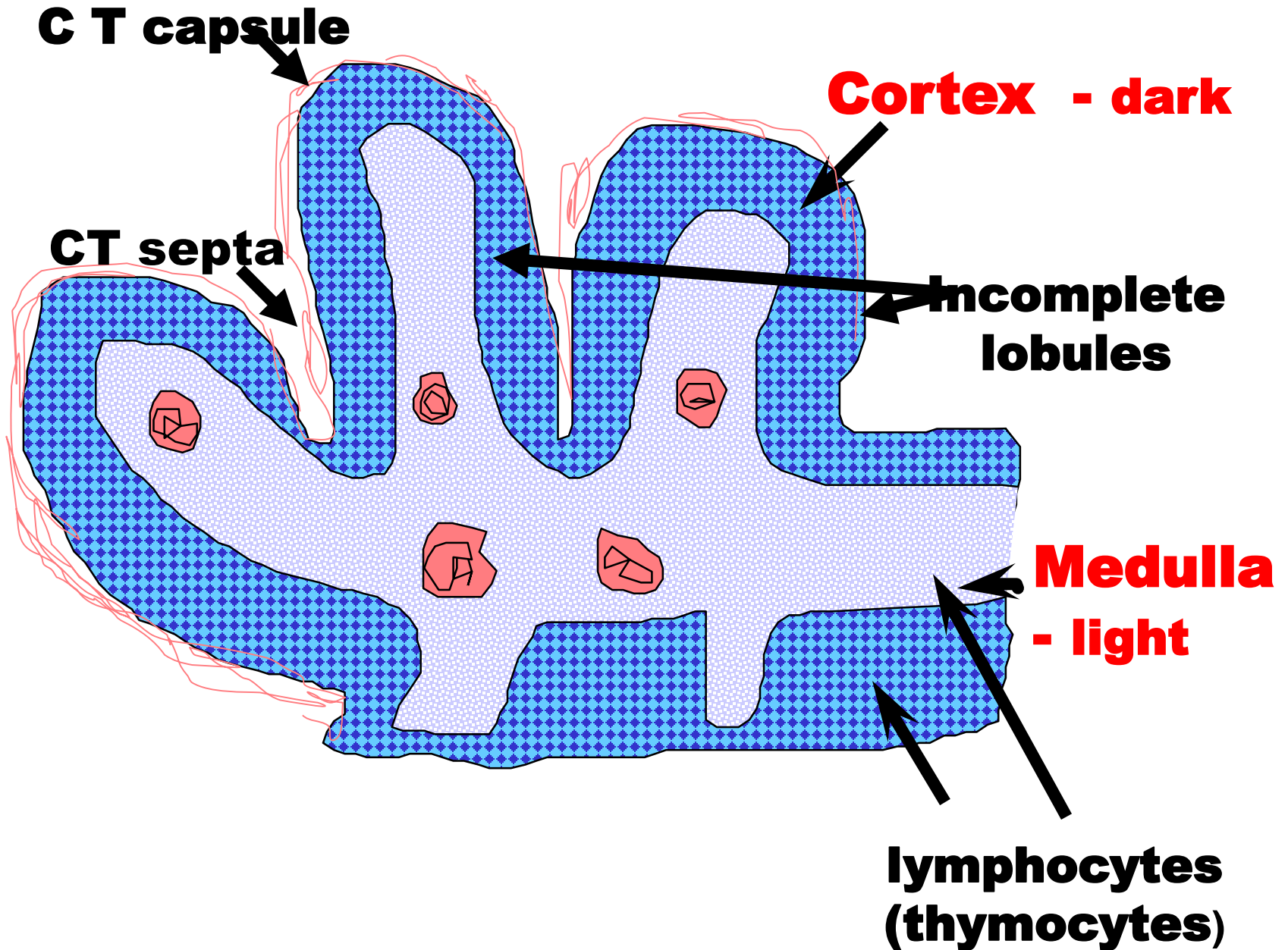
-Lymphatic component .

-Epithelial reticular cells.

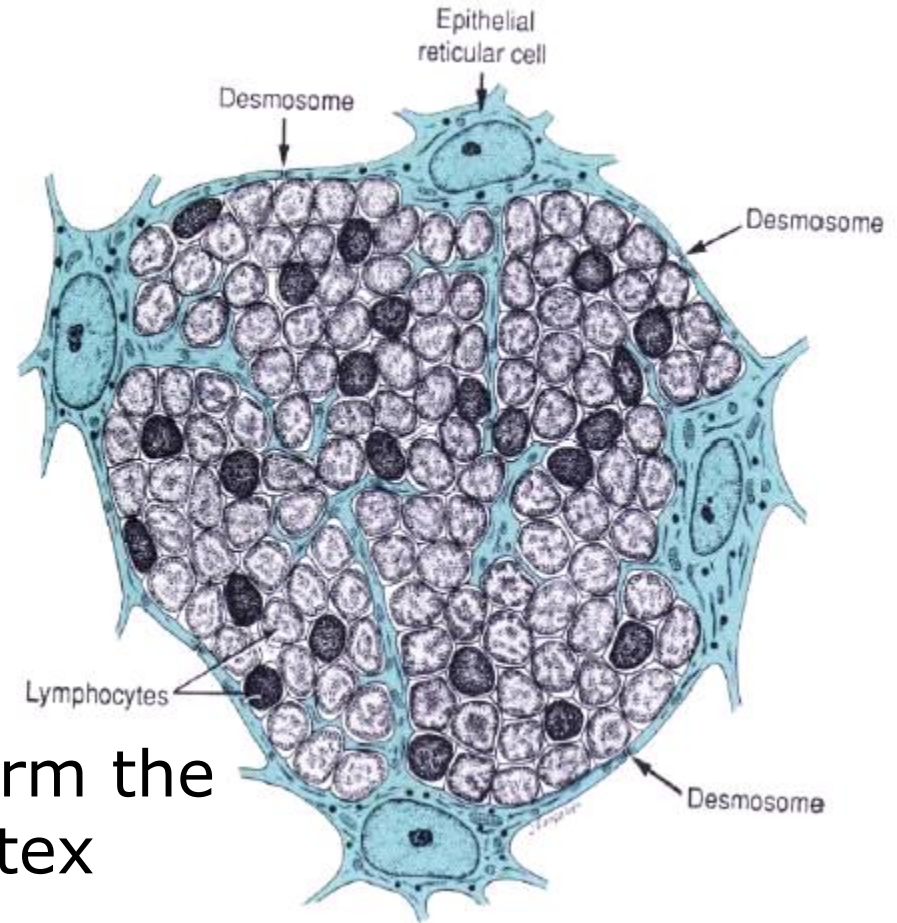
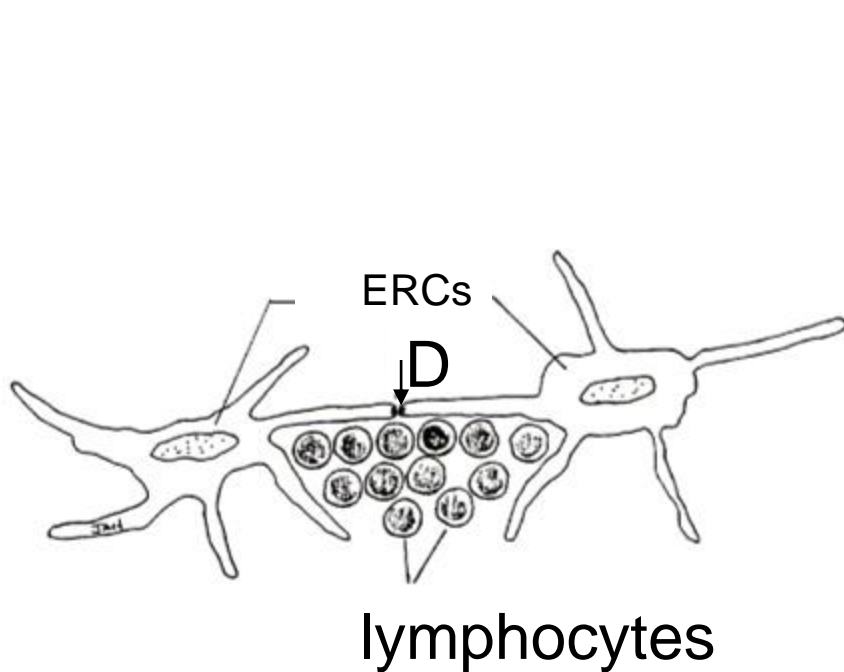
-Some macrophages.

Each lobe has dark cortex and pale medulla.

Stroma



Cytoreticulum of the thymus



The epithelial reticular cells form the cytotreticulum dividing the cortex into lymphocyte filled compartments. So they provide a framework for the developing T

2-Parenchyma

A-Cortex

B-Medulla

Both contain

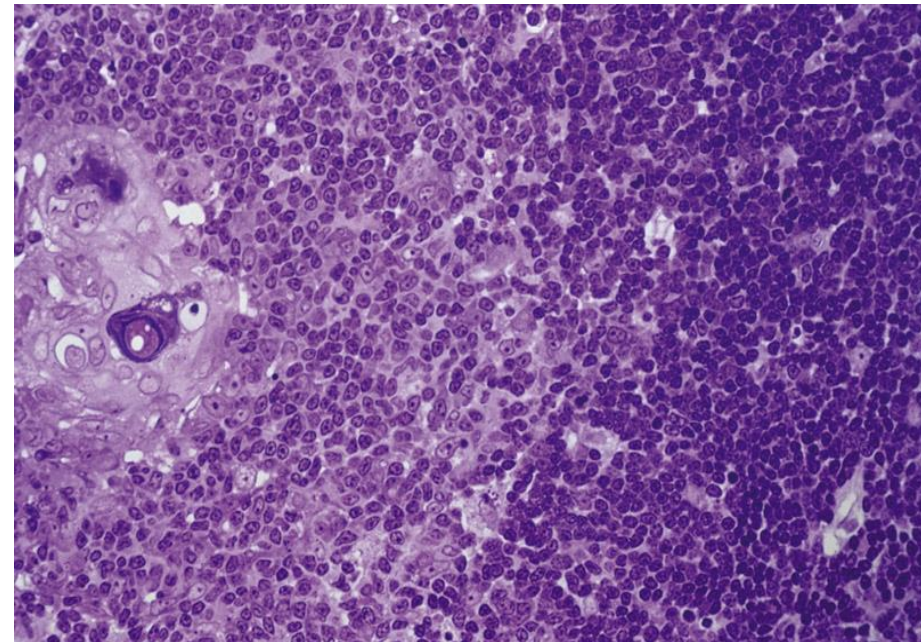
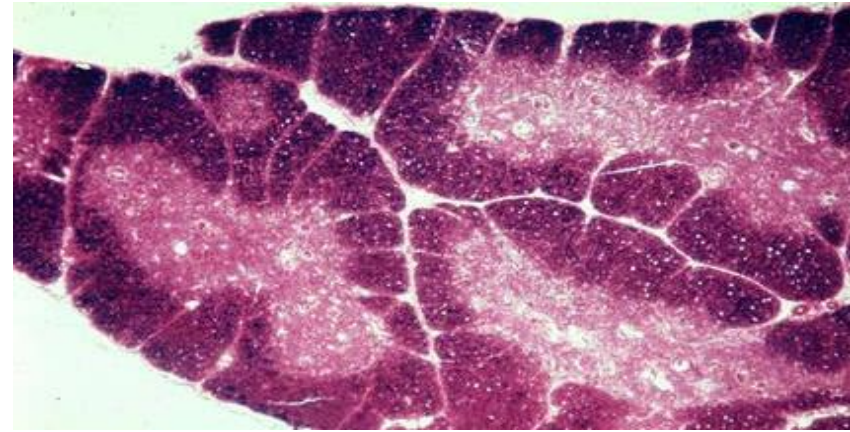
- 1- T- Lymphocytes. **No B- lymphocytes & plasma cell**
- 2- Epithelial reticular cells.
- 3- Macrophages.
- 4- Blood capillaries.

Cortex of thymus lobule

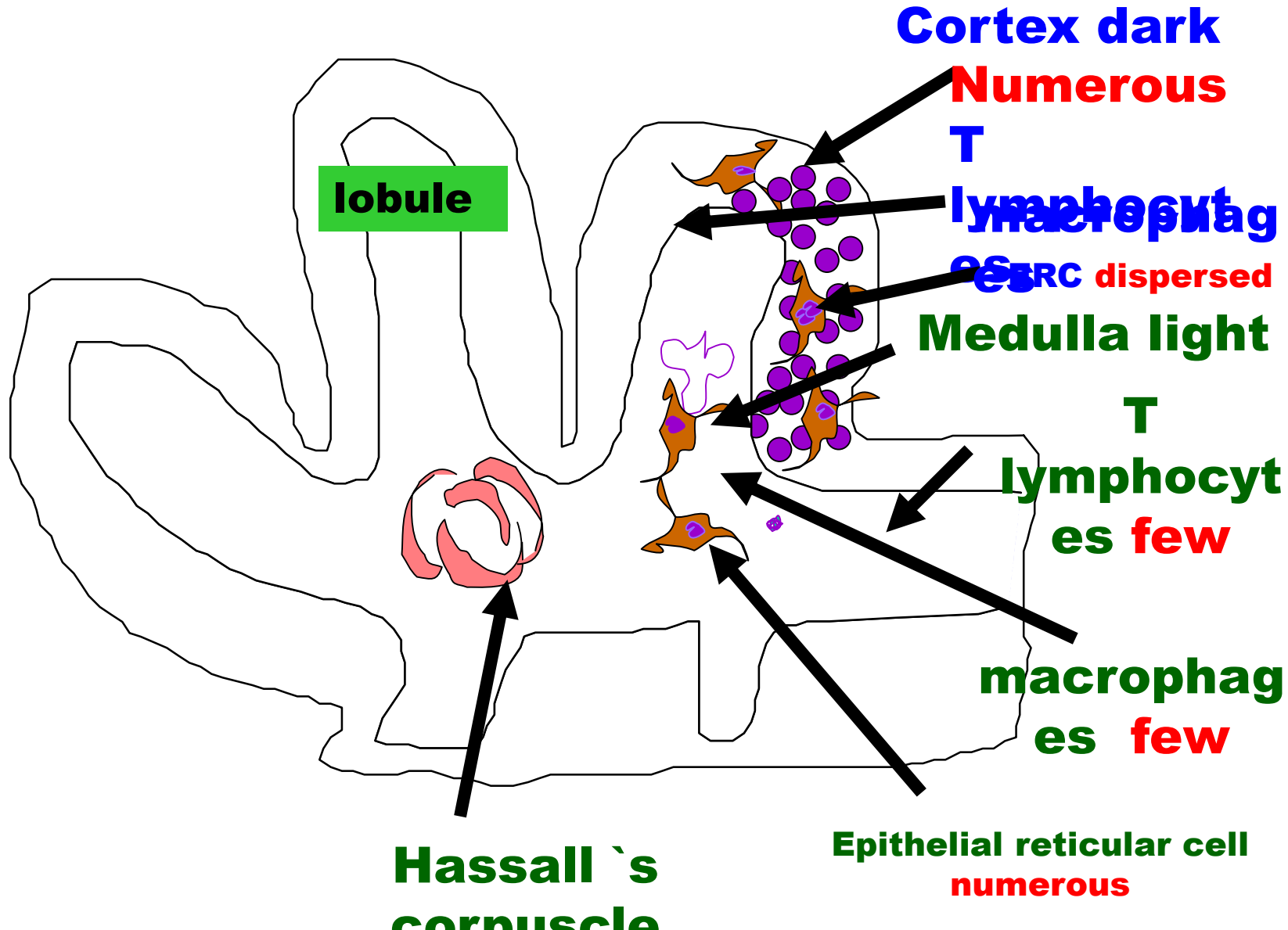
Peripheral dark-stained zone.

The cortex contain **densely packed T-** lymphocytes, epithelial reticular cells & macrophages .

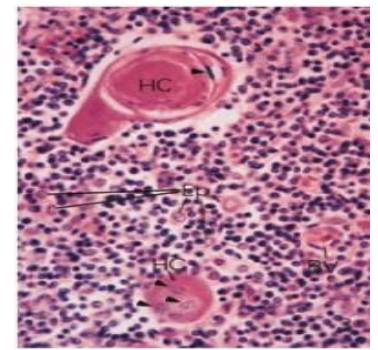
Mature T lymphocytes leave the cortex to the medulla.



Parenchyma of thymus



Thymic medulla



- * The thymic medulla contains primarily small, but fully mature, T lymphocytes.
- * T lymphocytes leave the medulla **via venules**.
- * These lymphocytes will populate specific regions of other lymphoid organs L.N., Spleen **(thymus dependant zones)**

• Hassall's corpuscles

Contains Hassall's corpuscles **(diagnostic feature)**, which vary in size & are acidophilic in reaction.

* They consist of **concentric layers of epithelial reticular** cells, which are frequently **degenerate**, and may **calcify**.

Functions : Unknown

Epithelial reticular cells

Endodermal in origin.

*Branched cells with pale nuclei and acidophilic cytoplasm.

*Do **not** produce **reticular fibers**.

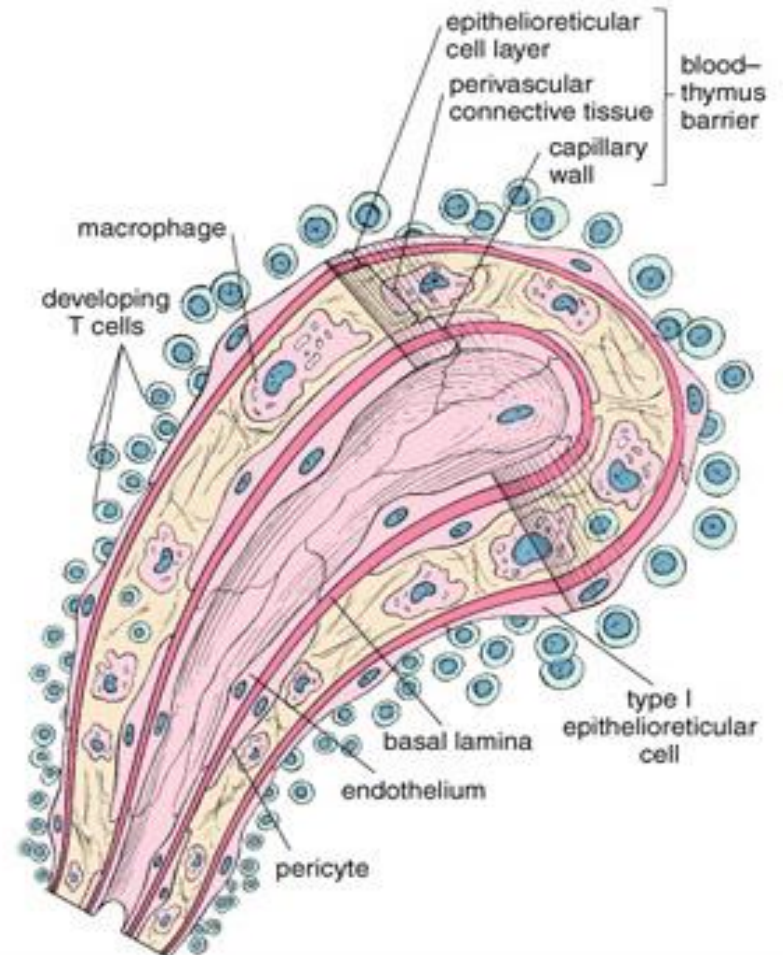
Functions of ERC

1. Cytoreticulum
2. APC
3. Blood Thymus Barrier
4. Secretion of Growth factors (**thymulin, thymosin, thymic humoral factor, thymopoietin**) which regulate T cell maturation, proliferation, and function within the thymus and peripheral tissues.


Blood thymic barrier

It is a barrier **between T cells and the lumen of the cortical vessels.**

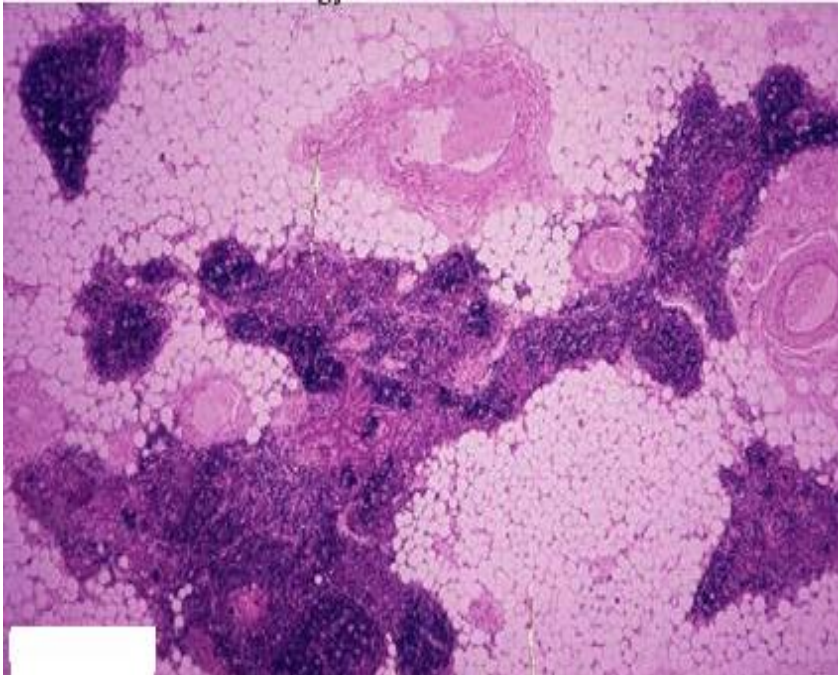
1. Continuous endothelium with tight junction
2. Thick basal lamina
3. Pericyte
4. perivascular space with macrophages
5. basal lamina of **Epithelial reticula cell** Epithelial reticular cells with tight junction



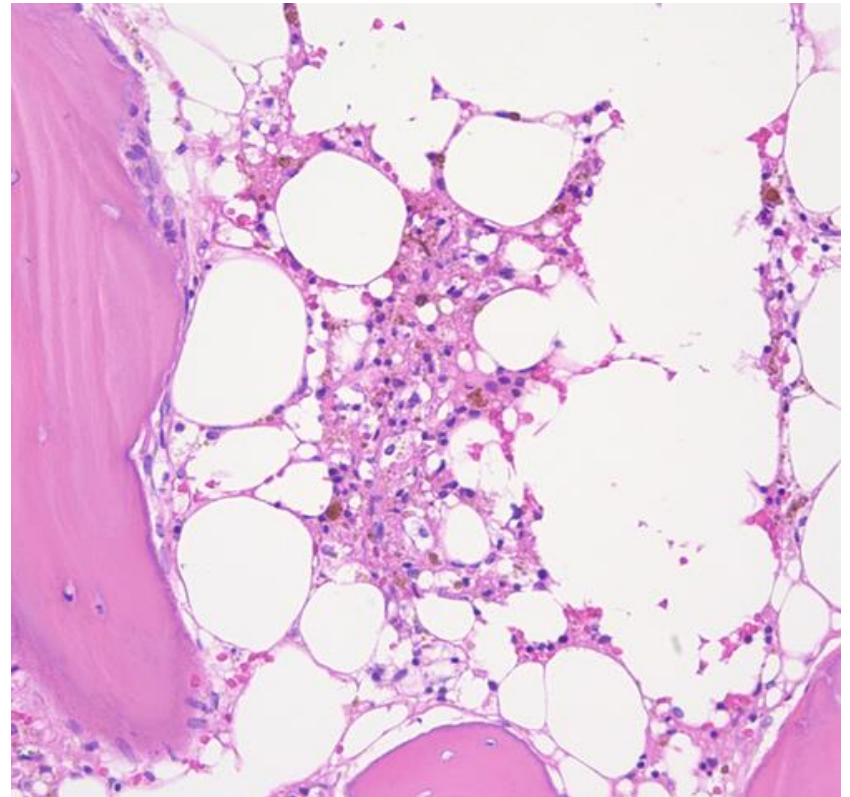
Thymus gland of adult

- * Replaced by **Fibrous & adipose tissue.**
- * Few lymphocytes, epithelial reticular cells &
- *  Hassall's corpuscles.

Involution of thymus in adult



Yellow bone marrow



Specific structure of thymus

- 1. Undergo involution**
- 2. No reticular fiber**
- 3. No lymphatic nodule**
- 4. No B- lymphocytes & plasma cell**
- 5. Hassall 's corpuscle**
- 6. No afferent lymphatic**

Cell in lymphoid organs

❑ Macrophages

❑ Antigen – presenting cells

❖ Dendritic cells

❖ Macrophages

❖ B- lymphocytes

❖ Epithelial reticular cells

❑ Granular leucocytes(N,E,B)

❑ Mast cell

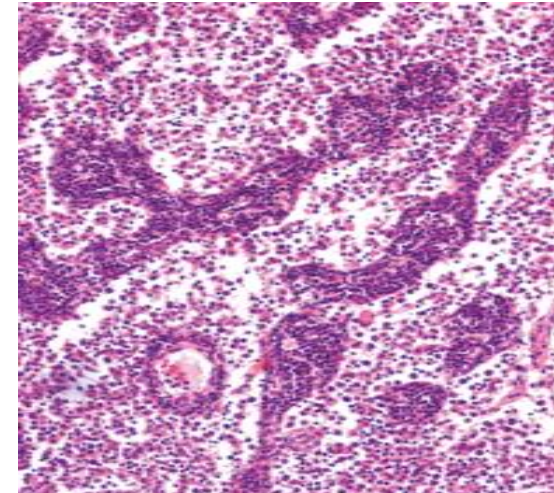
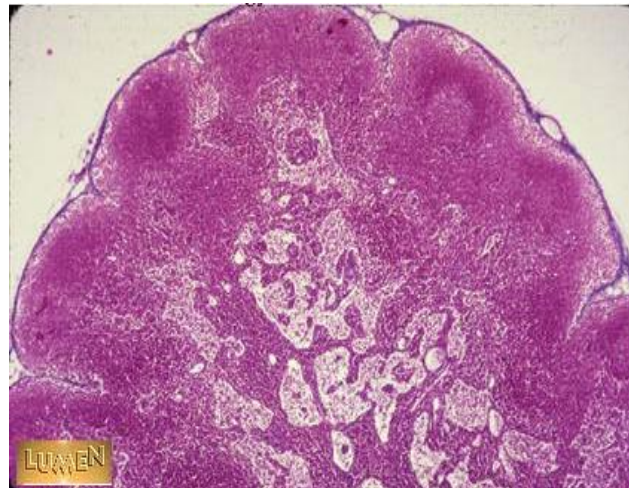
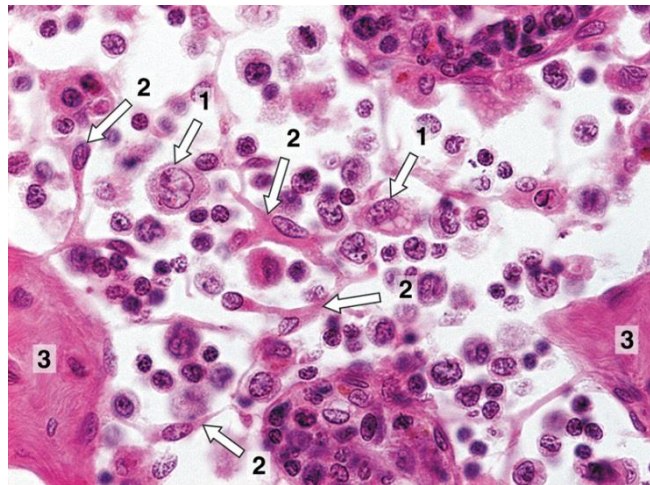
❑ Lymphocytes (B ,T, natural killer)

Diffuse = Loosely arranged

- Scattered in the lymphatic organ

Dense Aggregation

1. Lymphatic nodules = **follicles**
2. Lymphatic **cor**ds



Lymphatic nodules (follicles)

- *Non-encapsulated collections of lymphocytes.
- *Found in all lymphoid organs **except thymus**.

The lymphatic nodules are collection or spherical masses of lymphoid cells (B cell) which form either primary or secondary nodules

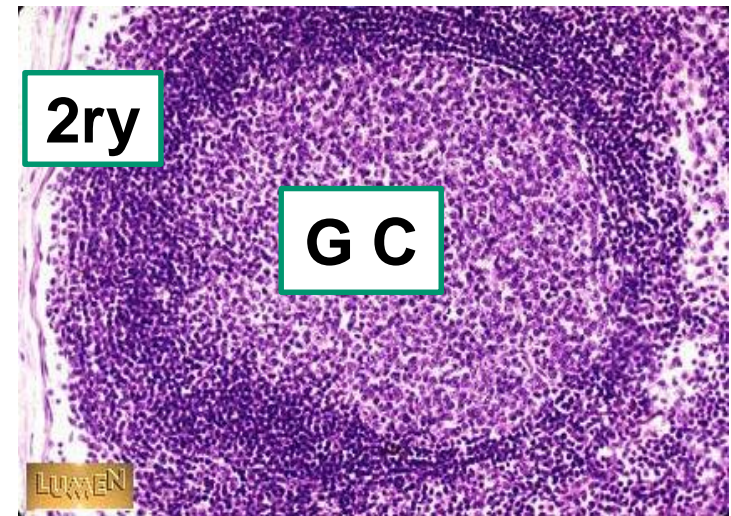
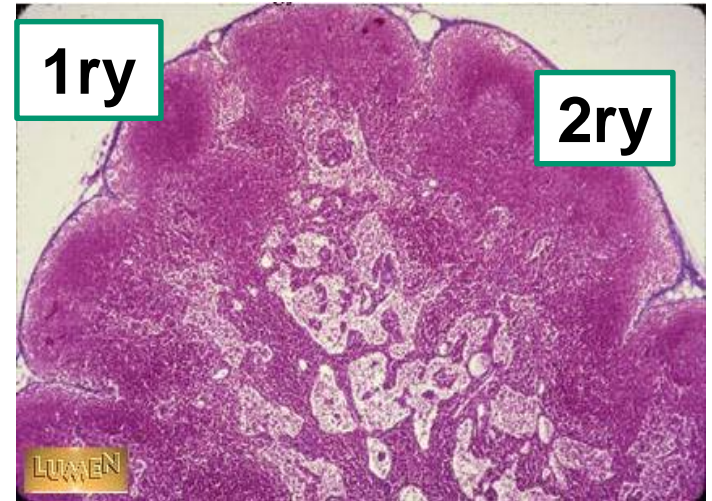
Primary nodule: mainly formed of small B- lymphocytes + macrophage .

no germinal center.

Secondary nodule: it appears with paler area in the central part which is call germinal center or the reaction center

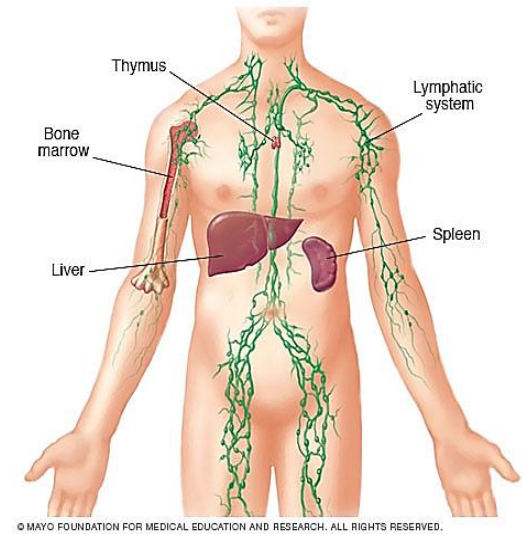
Contain lymphoblast + plasma cell

contains pale germinal center ,Mantle zone & peripheral zone



Structure of lymph node

- **Site:** along path of lymph vessels, most numerous in neck ,axilla , groin, along major vessels and in body cavities
- Small encapsulated oval bean shape structures. Serve as filter for removal of foreign bodies
- **Shape :** Each node is oval or bean shaped with fibrous capsule.
- It has a convex surface that is perforated by lymphatic vessels that have valves to pass lymph to the LN.
- It has concave surface (**hilum**) that is the site of entry and exit of artery and vein of LN. The lymph leave the node via efferent lymphatic vessels located in the hilum.



© MAYO FOUNDATION FOR MEDICAL EDUCATION AND RESEARCH. ALL RIGHTS RESERVED.

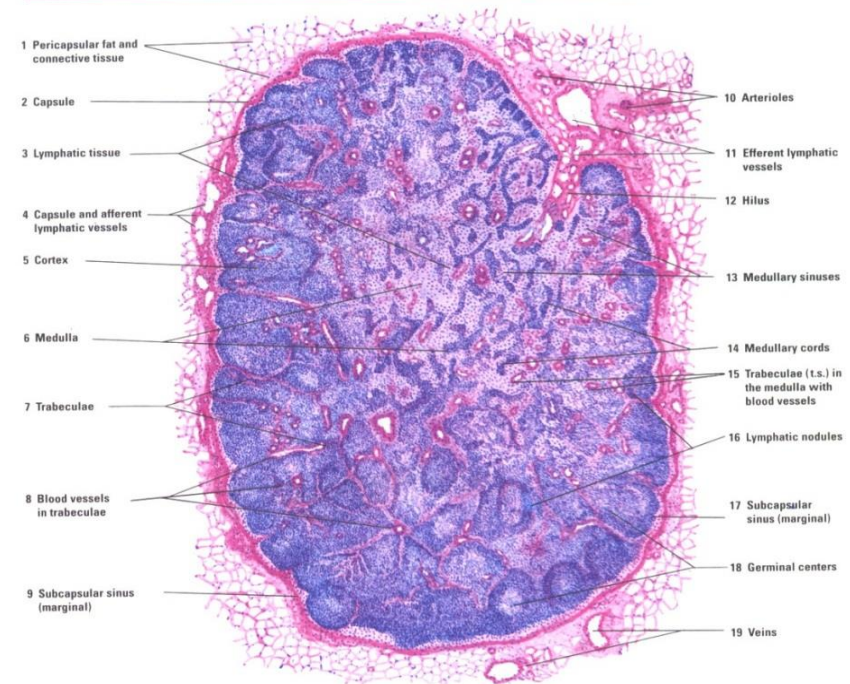


Fig. 8-1 Lymph Node (panoramic view). Stain: hematoxylin-eosin. Low magnification.

Histological structure of lymph node

STROMA

- **The coarse stroma:**
- **CT capsule** (**complete fibroelastic**)
- **Trabeculae in the cortex:** send perpendicular dividing the cortex into several incomplete compartments
- Thickened at the hilum
- It form sheath around the BV enter the LN at the hilum.
- **In medulla** the trabeculae runs in different direction forming a sort of network
- **Fine stroma:**
- Suspended from capsule and trabeculae
- in the form of **reticular fibers** and cells holding parenchymal cells in its meshes

Parenchyma

- **cortex** The outer part of the LN is highly cellular→
- superficial (**outer**) cortex
- Deep cortex = Paracortex (**inner cortex**)
- **Medulla**
- The inner part of the LN is
- less cellular→
- The cellular component of the LN which are T & B lymphocytes plasma cells and APCs are arranged into dense and loose arrangement.
- **Dense**→ cortical nodules
- medullary cords
- **Loose**→ loosely scattered B lymphocytes, plasma cells, macrophages and lymph sinuses

Lymph node stroma (CT skeleton)

Coarse stroma

Capsule

Afferent lymphatic

Fine stroma

Trabeculae

Reticular fibers

Suspended from the capsule and trabeculae

Efferent lymphatic

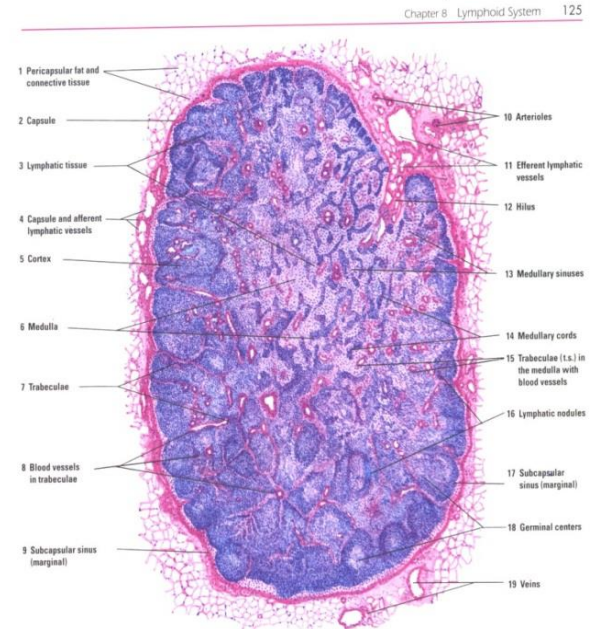


Fig. 8-1 Lymph Node (panoramic view). Stain: hematoxylin-eosin. Low magnification.

Parenchyma of LN

1. Lymphocytes B,T

2. plasma cells

3. Neutrophils

4. APCs

(macrophages)

5.

primary Follicle

Follicles=
nodules

Secondary
follicle
Germinal
center

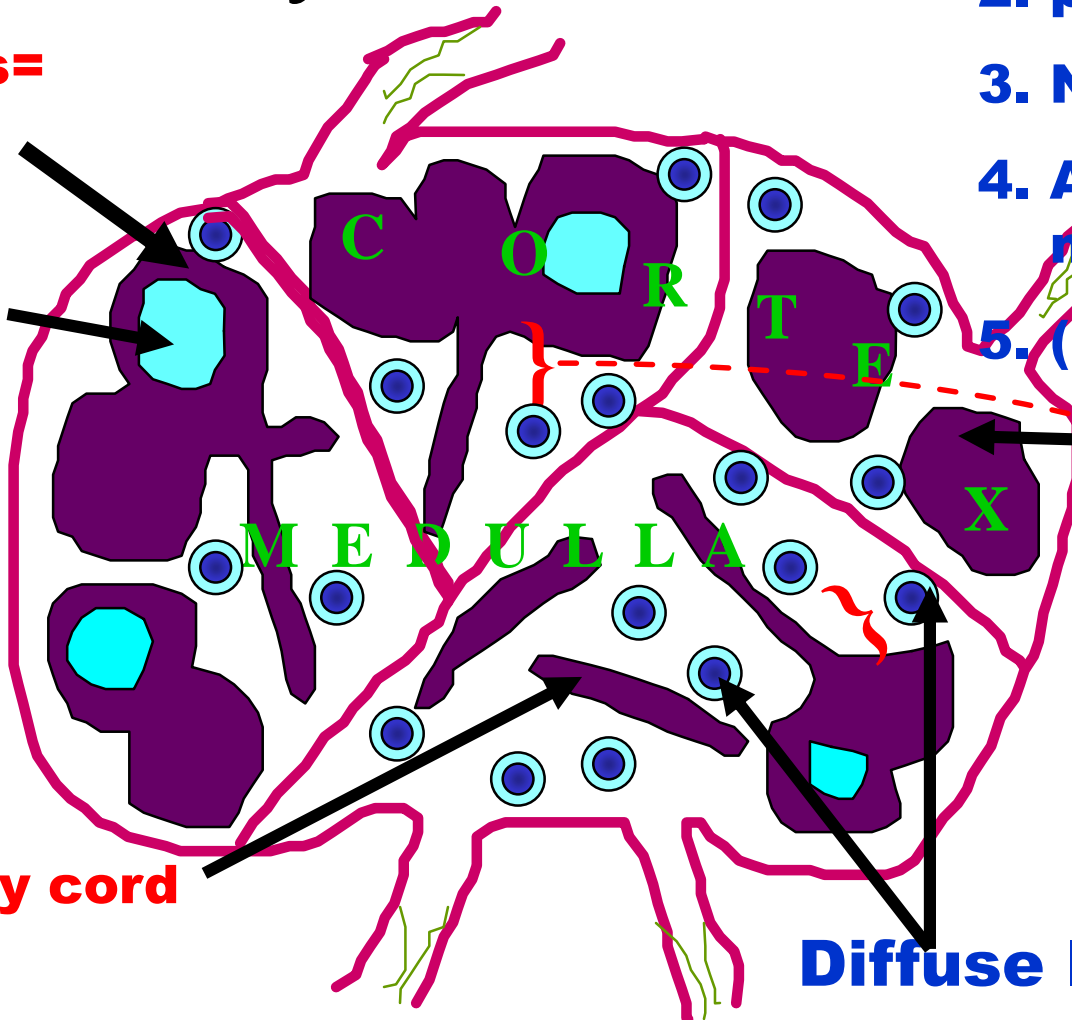
Paracortical
zone

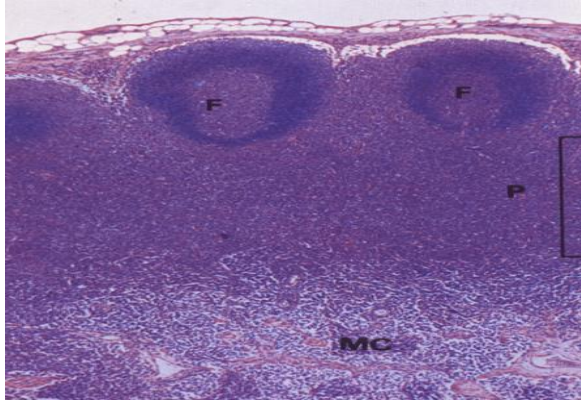
Medullary cord

Diffuse lymphatic tissue

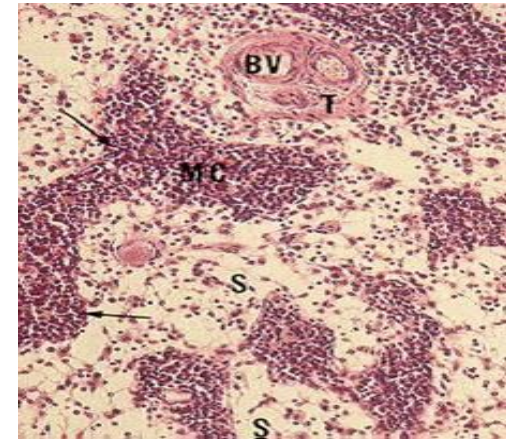
Dense lymphatic tissue

Lymphocytes, plasma cells,
and macrophages.





Parenchyma



Cortex

❖ Outer cortex

Cortical nodule

- **Primary nodule**
- **B lymphocytes + macrophages**
- **Secondary nodule**
- **B lymphocytes + macrophages**
- **Lymphoblast (Germinal center) + macrophages**

❖ Inner cortex

= (thymus dependant area)

= Paracortical area is Formed of

- T lymphocytes**
- Macrophages**

❖ Medulla

1. Lymphatic sinuses
2. large blood vessels & supporting trabeculae
3. All are present in a framework of reticular fibers
4. **medullary cords**
Contains :
 - B lymphocytes
 - Numerous Plasma cells
 - Marophages

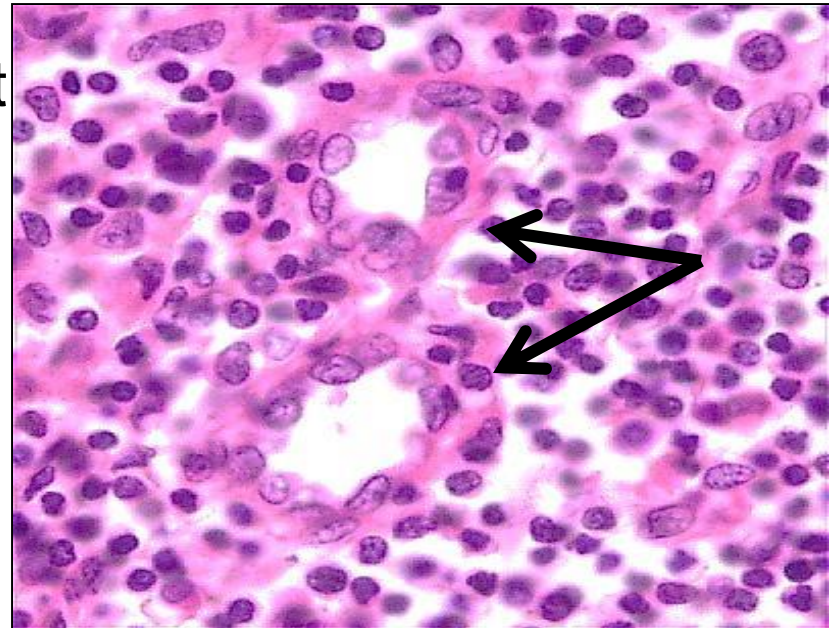
2- Paracortex (cortico-medullary):

- between the cortex and medulla
- Is called the **Thymus dependent zone** of the lymph node, contains T cells have migrated from the thymus

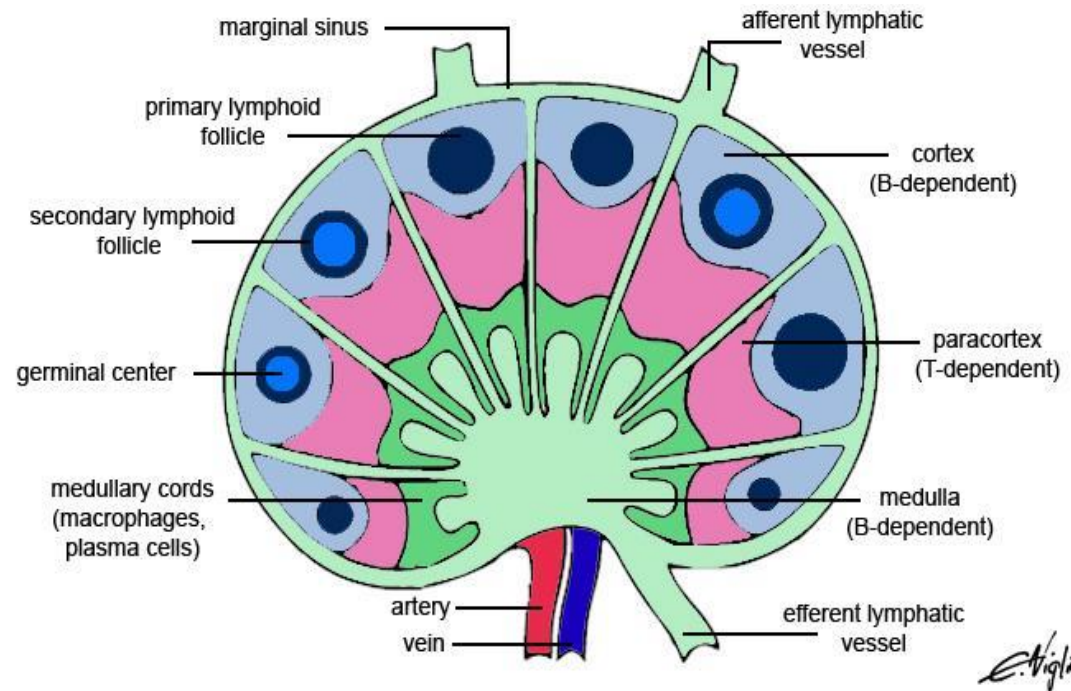
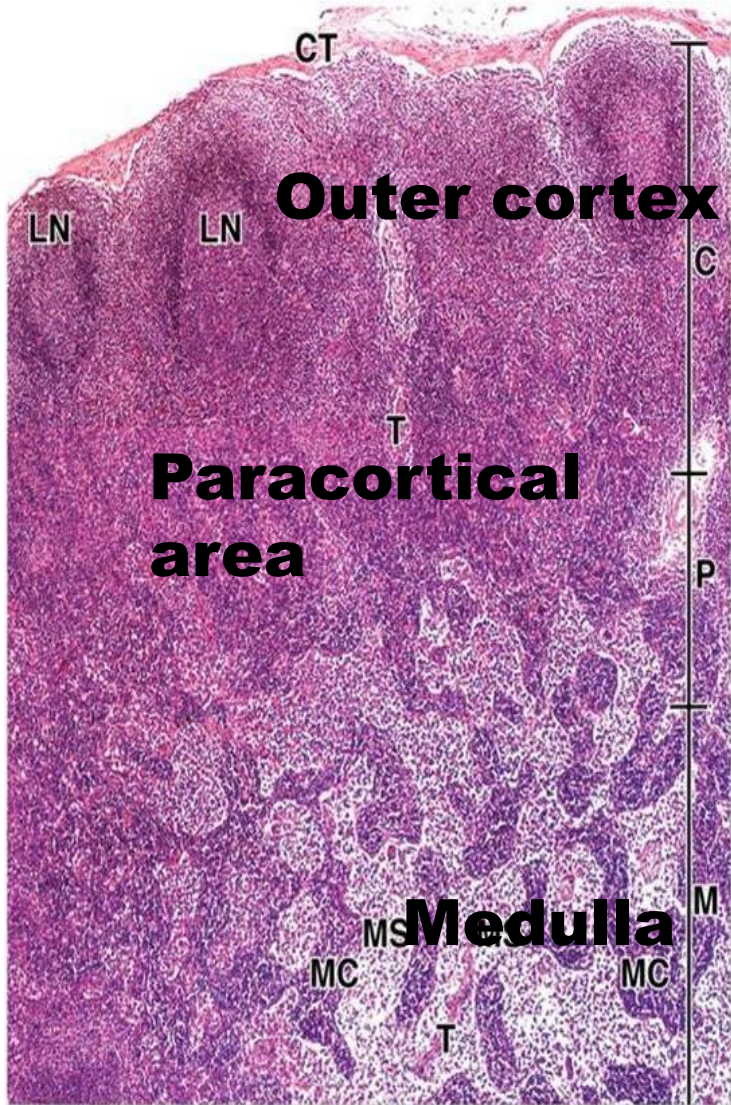
[T lymphocytes + High endothelial venules (HEV)]

HEV:

- is the point of entry of T cells from blood to lymph node
- its endothelial lining is unusual
- is cuboidal to facilitate movement of T cells into LN



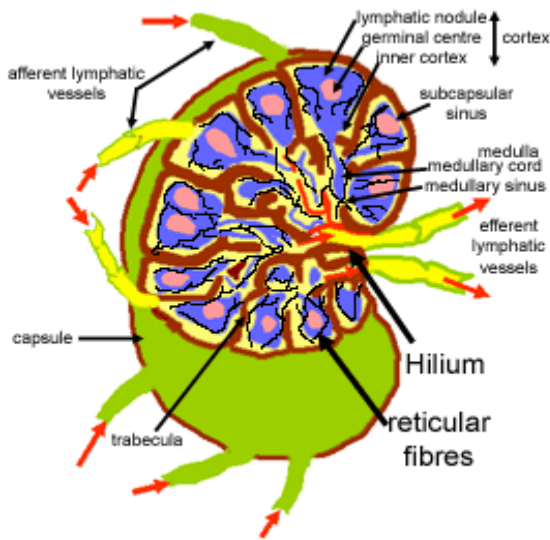
Three regions of LN



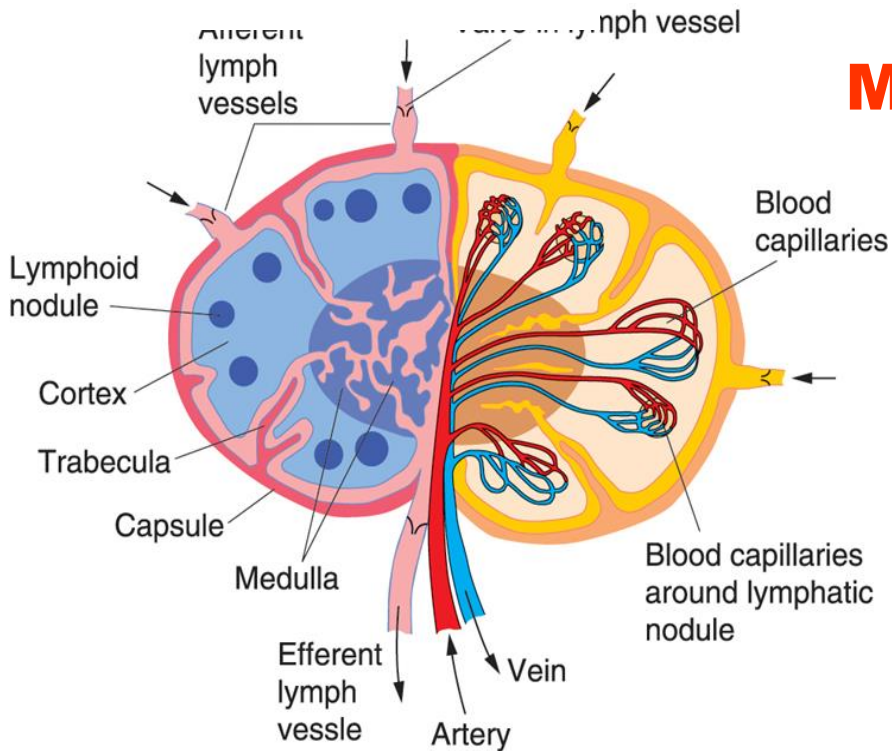
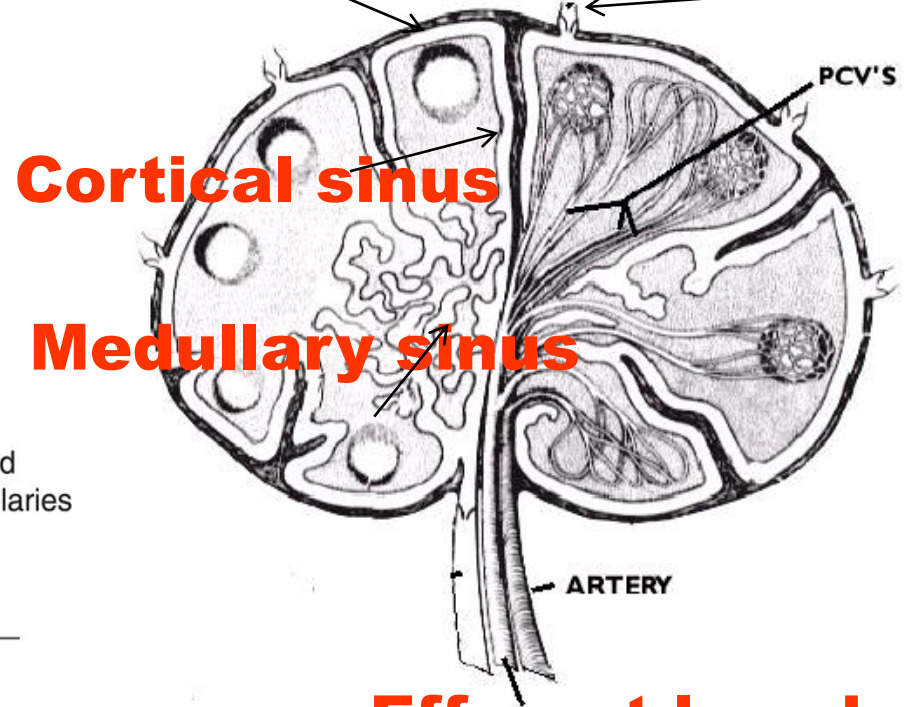
Function of lymph node

1. The primary function of the lymph node is to **filter the lymph** which drains antigen from the tissues
2. production of B lymphocyte
3. immunological response

Lymphatic circulation



Subcapsula lymphatic **Afferent lymph**



Efferent lymphatic

Structure of the spleen

A-Stroma:

1-Capsule: **complete thick** rich in collagenous and smooth muscle fibers. **Covered by peritoneum**

2-Trabecula: Collagenous connective tissue projections from the capsule at the hilum . Branches repeatedly, and imperfectly divide the spleen into anastomosing chambers.

3-Reticular CT: reticular cells and fibers.

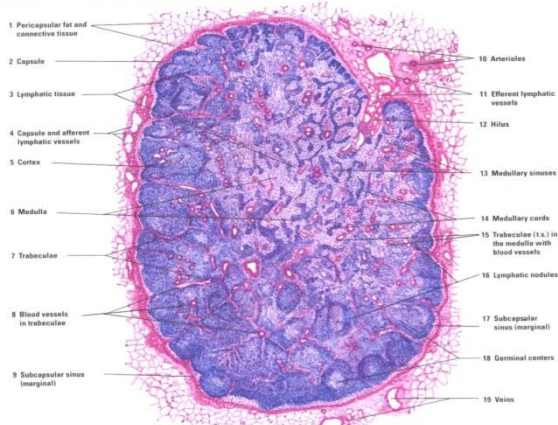
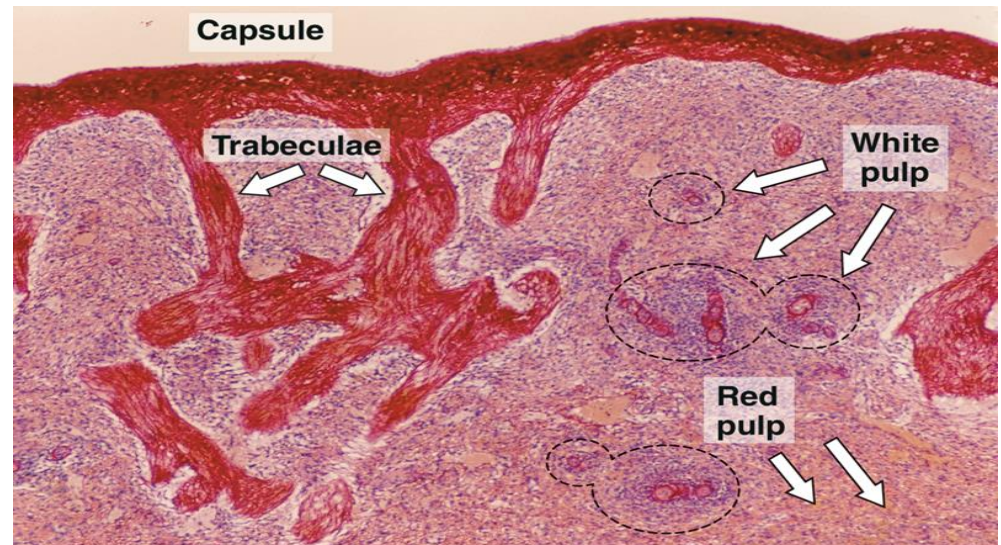
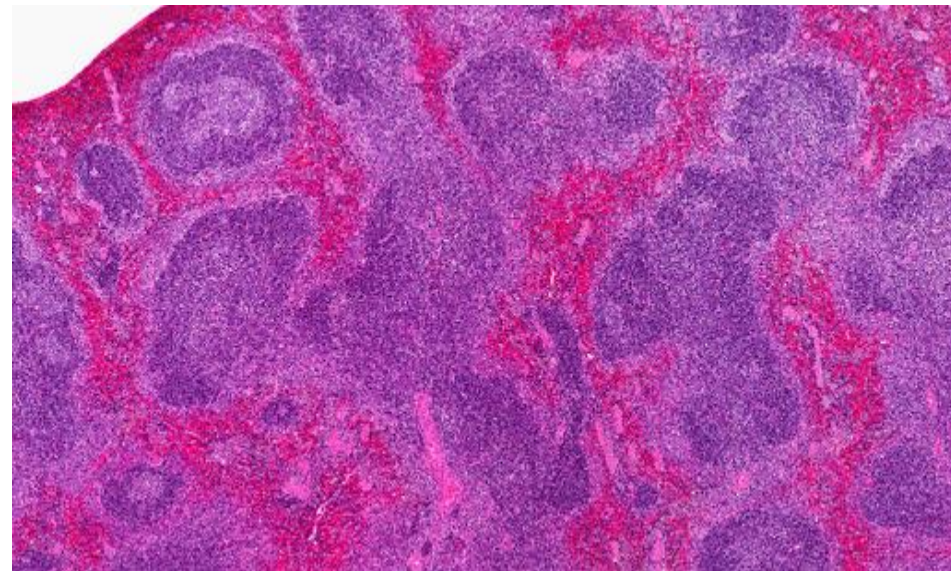
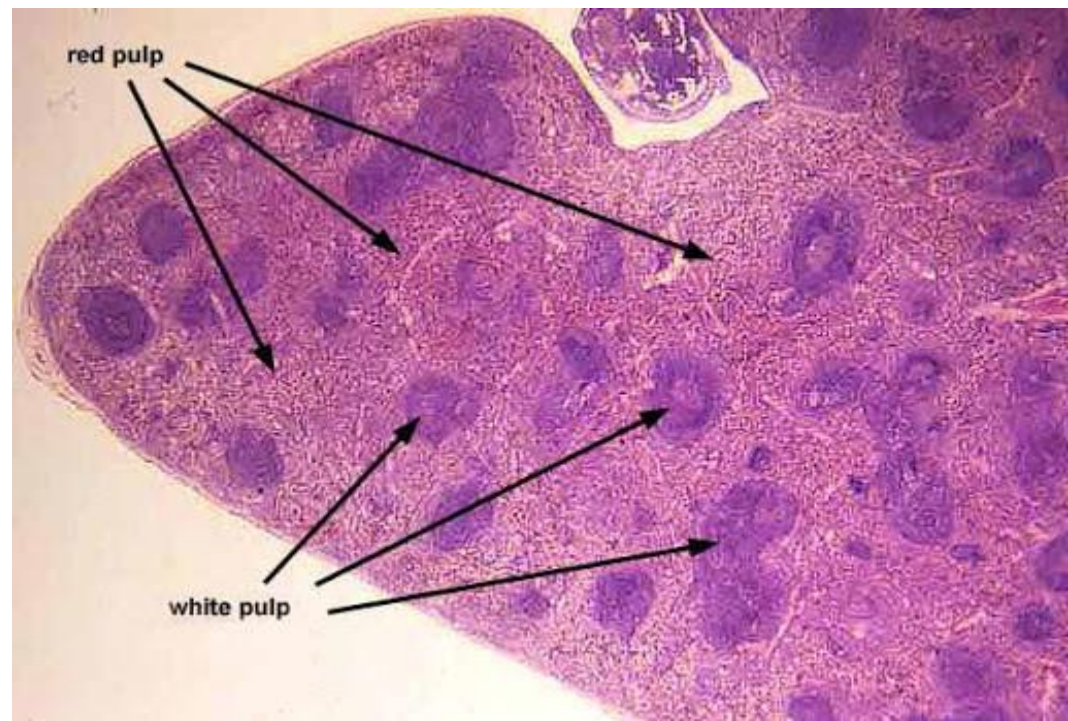
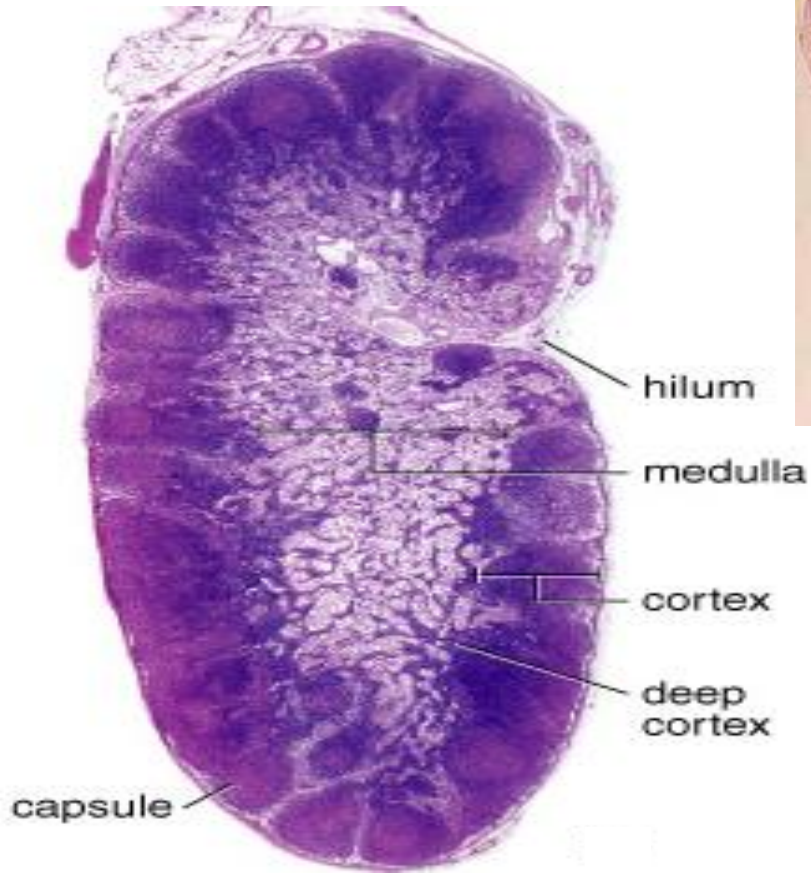
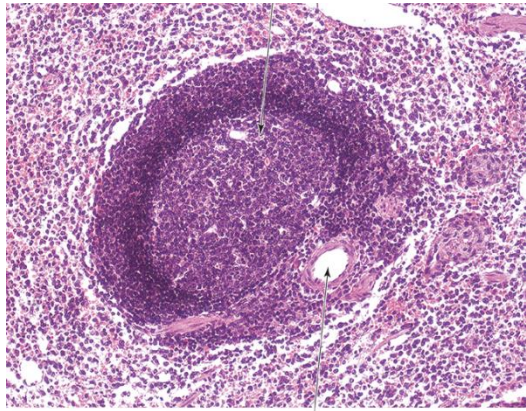


Fig. 8-1 Lymph Node (panoramic view). Stain: hematoxylin-eosin. Low magnification.



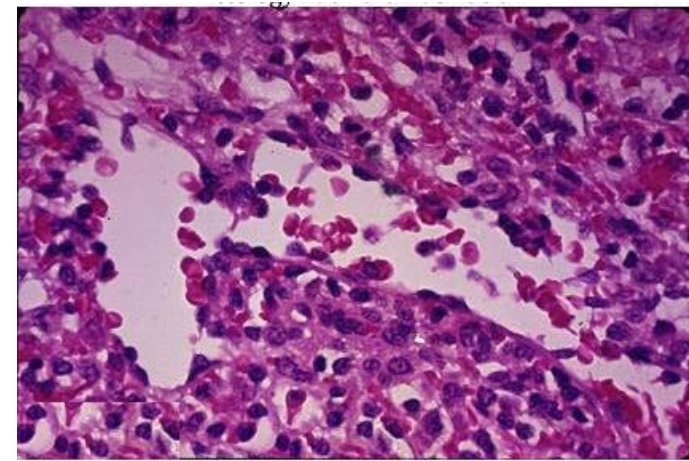
Spleen





Parenchyma

NO Cortex & Medulla



1-White pulp:

White pulp = lymphatic nodules (splenic Malpighian corpuscles): with pale germinal centers+mantle zone+ peripheral zone.

Central arteries : run at the periphery of the nodules (eccentric central). They are branches of splenic arteries and give numerous capillaries before leaving the white pulp to enter the red pulp.

Central arteries are ensheathed by T lymphocytes (**PALS**)

Thymus dependant zone: is the peri-arterial lymphatic sheath (PALS) of **T lymphocytes**

2-Red pulp:

So-called because of its color during life. Red color is due to abundant erythrocytes in and around blood sinusoids.

Consists of:

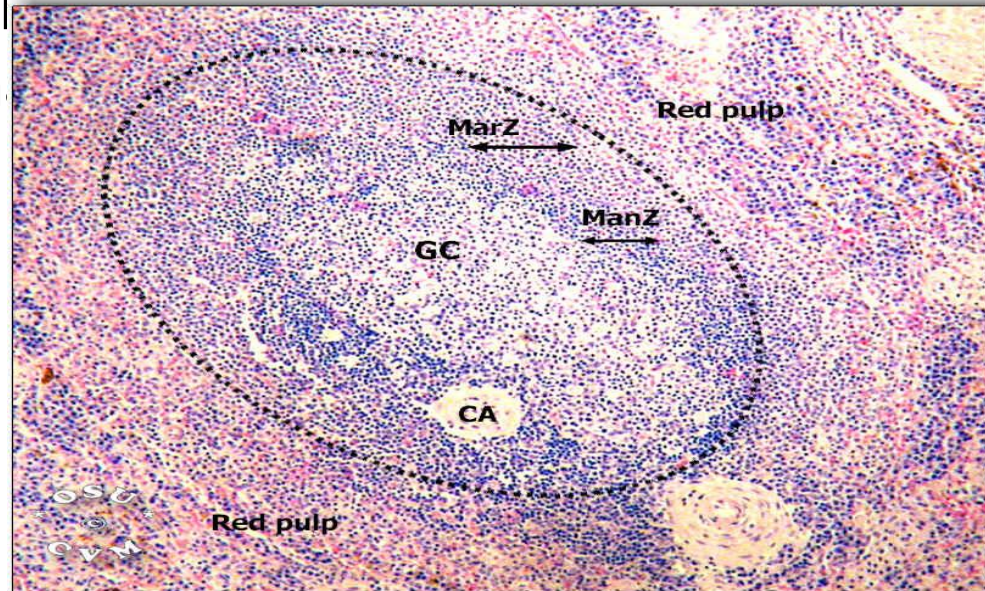
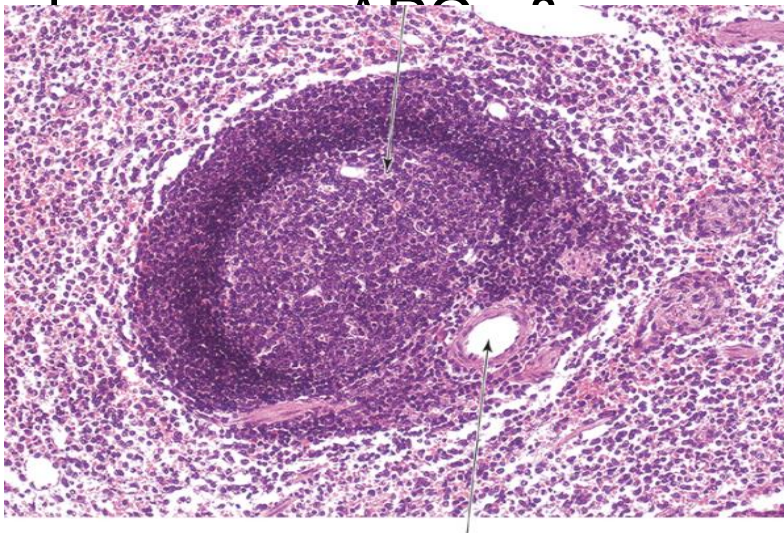
1-Blood sinusoids

2-Lymphatic tissue (**Billroth cords**): Lymphatic tissue of the red pulp is not as compact as that of the white pulp.

- + **Marginal zone**

white pulp of spleen:

- ❑ **Periarteriolar lymphoid sheaths (PALS):** mainly T lymphocytes encircle the arteriole (**Thymus dependent zone of spleen**)
- ❑ **Germinal center** : lightly stained, contain B cells, activated B cells, plasma cells & macrophages are (located between PALS and marginal zone)
- ❑ **Mantle zone**: Dark stained, around germinal zone , mainly B cells
- ❑ **Marginal zone** at the periphery



Red pulp

(So-called due to its red color during life (↑ RBCs))

RBCs, platelets, WBCs, macrophages, B-lymphocytes, plasma cells,

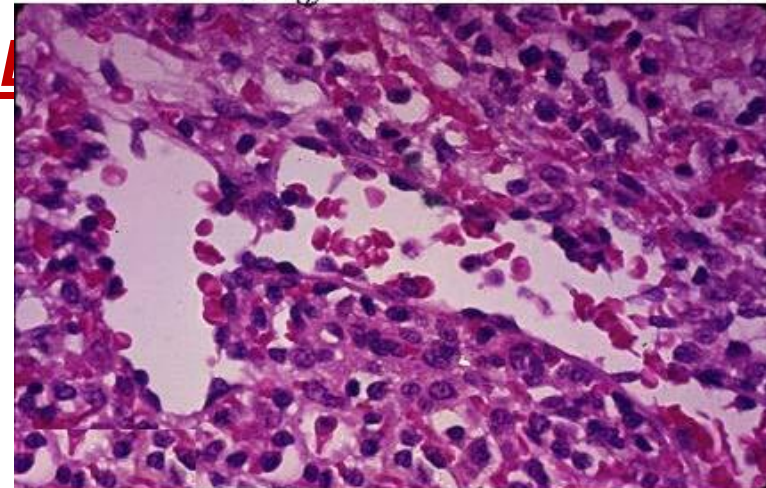
1-splenic cords (Billroth cords):

- **Fibrils of loose CT within** blood sinusoids infiltrated with blood cells & plasma cells , macrophages

2-Blood sinusoids (venous sinuses):

- wide spaces lined e fenestrated endothelium to allow passage of cells to the blood.

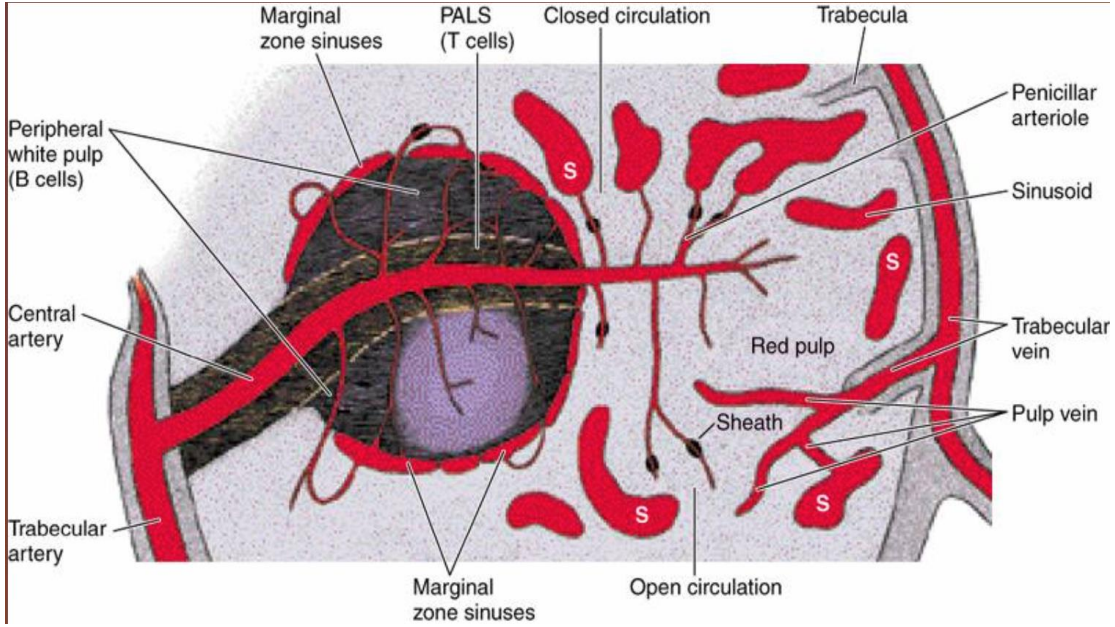
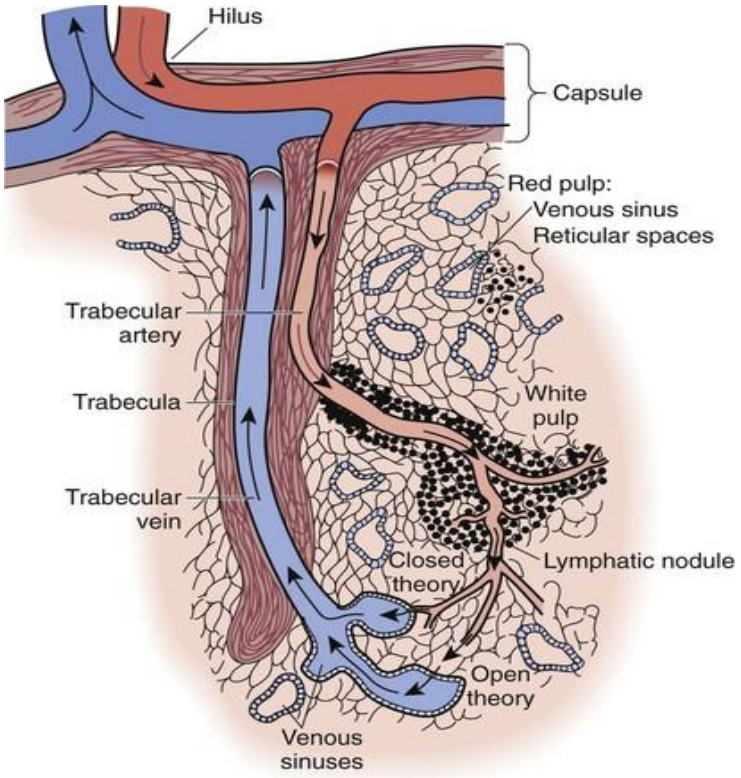
*(Macrophages of spleen called **L**)*



- 1-Open pattern.**
- 2-Closed pattern.**
- 3-Open and closed**

Theories of splenic circulation:

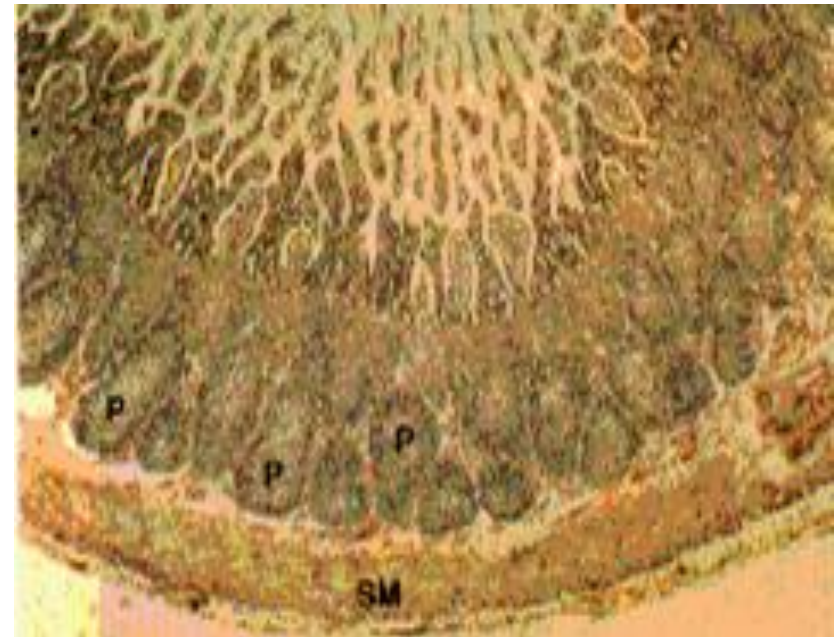
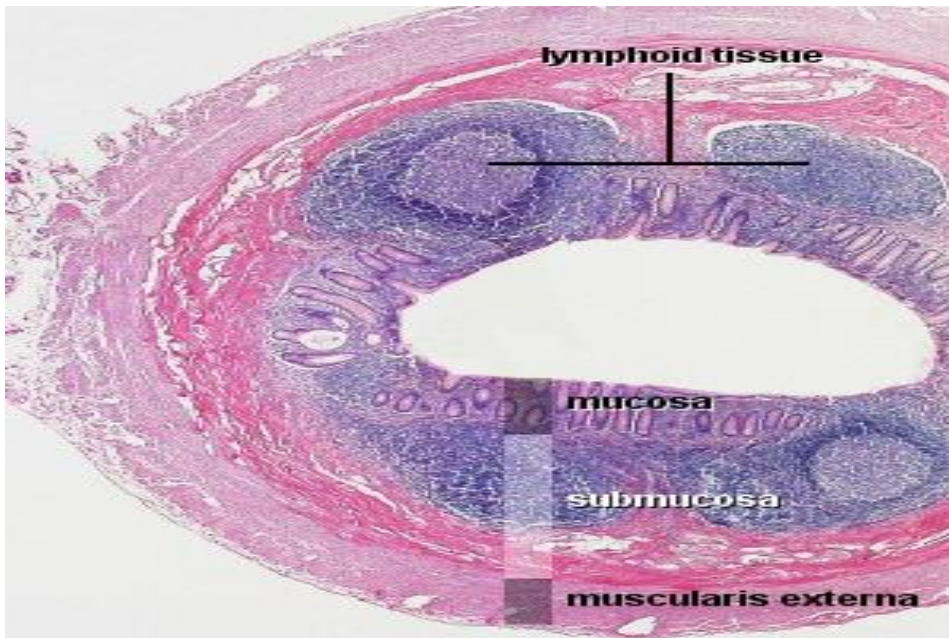
- 1-Splenic artery.
- 2-Trabecular artery.
- 3-Central artery in white pulp.
- 4-Penicillar arterioles in red pulp
- 5-Sheathed capillaries surrounded by reticular cells and macrophages
- 6-Sinusoids (sinuses) of red pulp
- 7-Trabecular vein.
- 8-Splenic vein.



	LN	Spleen
Peritoneal covering	Absent	Present
Capsule	Capsule of collagen + elastic F	Capsule of collagen + elastic F + smooth M
Trabeculae	Thin regular from the cortex not contain smooth M	Thick irregular from the hilum contain smooth M
Parenchyma	Cortex + Medulla	White and red pulp
Dense lymphoid T	Cortical nodules + Medullary cords + thymus dependent area in deep cortex	Scattered white pulp with central artery +thymus dependent area in periarterial sheath
Loose lymphoid T	Scattered lymphocytes + plasma cells + macrophages + Lymph sinuses	Scattered lymphocytes + plasma cells + macrophages + + granulocytes + Blood sinuses
Function	<input type="checkbox"/> Filtration of lymph <input type="checkbox"/> Immunological response	<input type="checkbox"/> Filtration of blood <input type="checkbox"/> Immunological response

Aggregates of Lymphoid Follicles (MALT)

- *Many bacteria permanently inhabit the digestive and respiratory tracts.
- *To fight these invaders, MALT is especially abundant under the mucosa.
- *Examples are: **Peyer's patches** of ileum and MALT of **appendix**.



Tonsils

Partially encapsulated
lymphoid tissue.

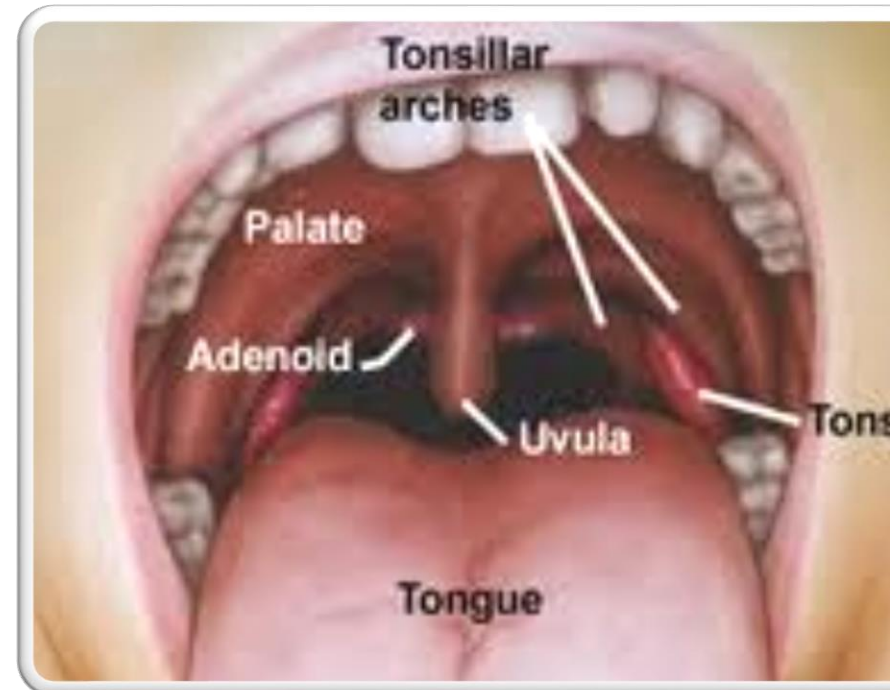
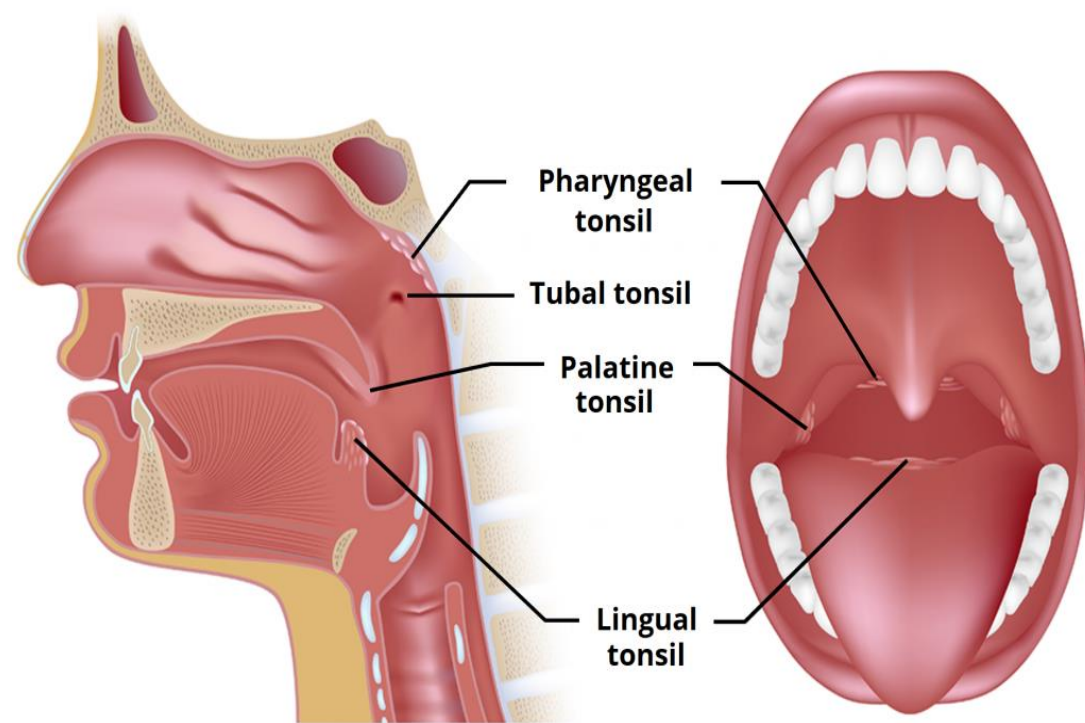
3 types

Palatine

pharyngeal

lingual

- Under the epithelium of initial portion of digestive system.
- Their function is to generate immune responses against foreign antigens that may enter the oral cavity



Palatine Tonsil

1. Stroma

Incomplete Capsule

❑ Anterior medial

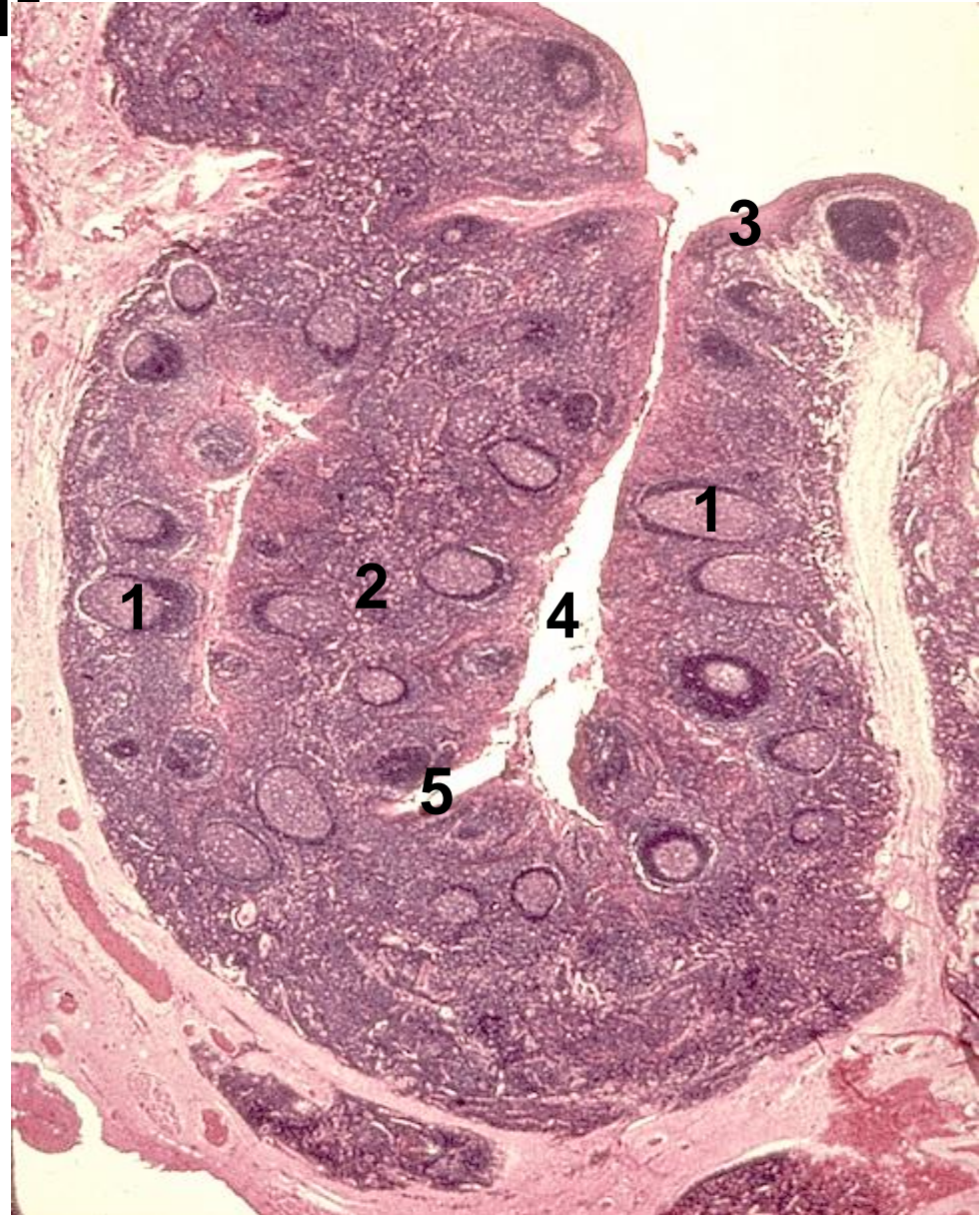Epithelium of the oral cavity
mucosa (1ry crypt, 2ry crypt)

❑ Posterior lateral

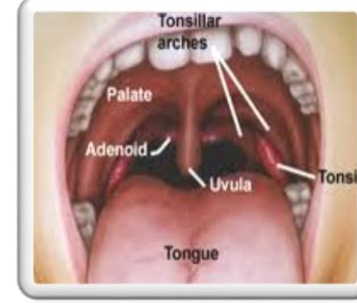
C.T. capsule + palatine gland

2- Parenchyma:

1. Lymphoid follicles
2. Diffuse lymphoid tissue



Palatine Tonsil



Stroma

- The two palatine tonsils are located in the lateral walls of the oral part of the pharynx.
- **Each tonsil is characterized by:**

Incomplete capsule:

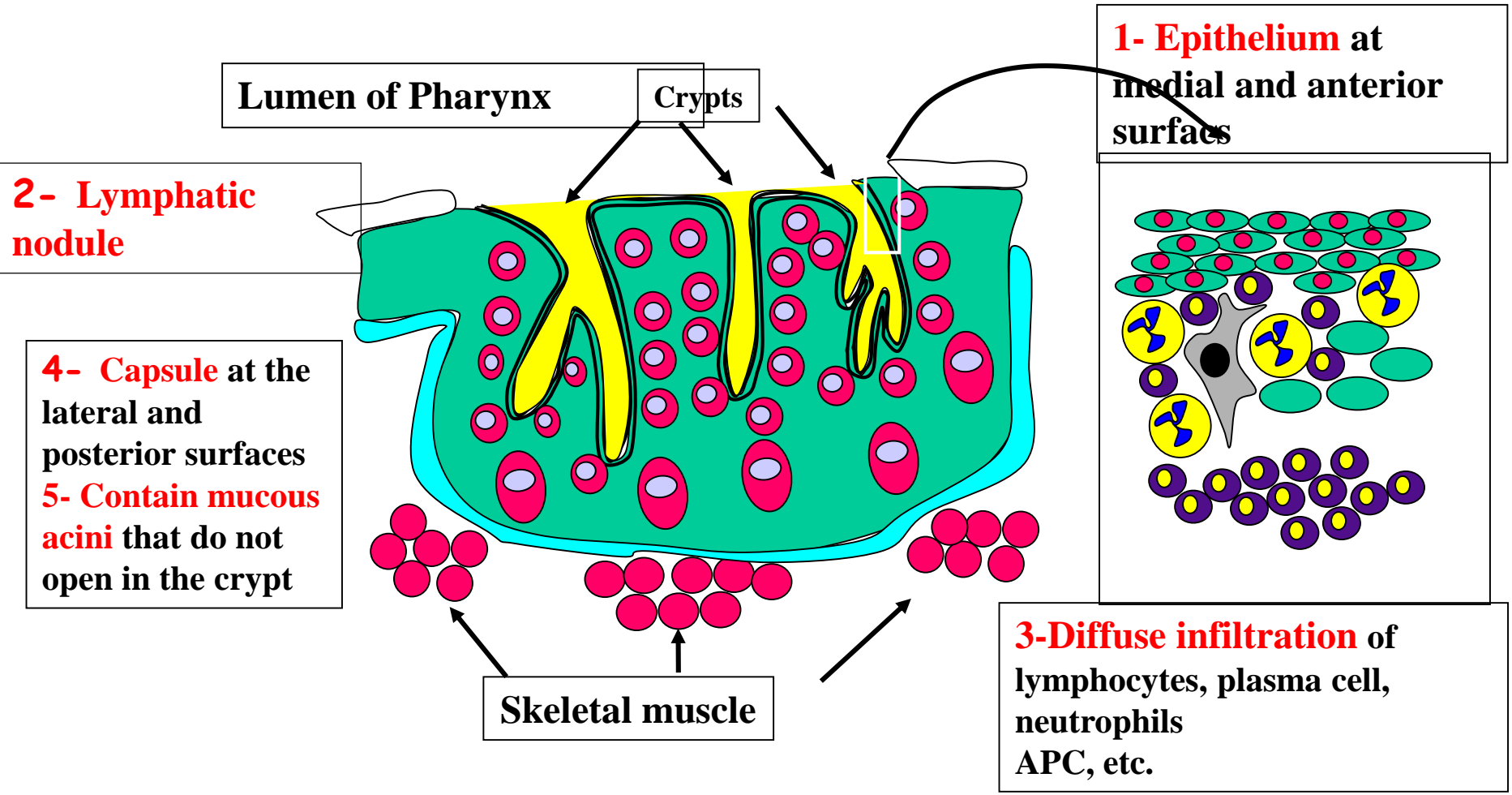
- **anterior and medial surfaces: covered by non ker str sq ep.**
- **Dips inside the parenchyma forming 1ry & 2ry crypts (15-20).**
- **In the lumen of the crypt: desquamated epithelial cells, live and dead lymphocytes and bacteria.**
- **Posterior lateral : C.T. capsule**
- + **palatine gland mucus secreting gland (palatine gland)**

Parenchyma

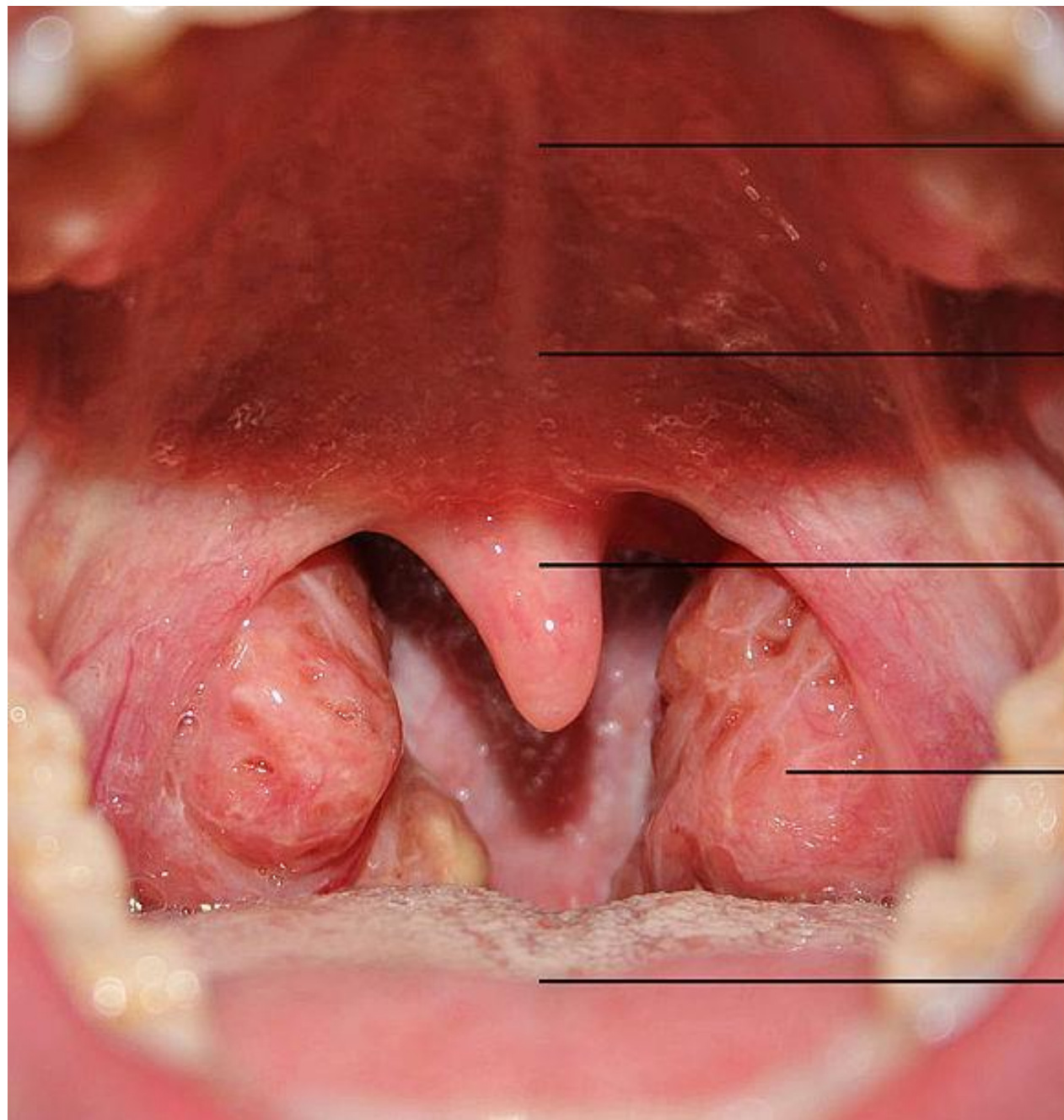
- **Lymphatic nodules:** present under epithelium and around the crypts.
- The **loose lymphoid** tissue consists of loosely arranged lymphocytes, plasma cells, leukocytes and macrophages.
- Present in between the lymphatic nodules.
- **No lymph sinuses** are present.

Palatine tonsils

Site: lateral wall of oropharynx



Capsule: Act as barrier against spread of infection Separate tonsil from surrounding tissue



Hard palate

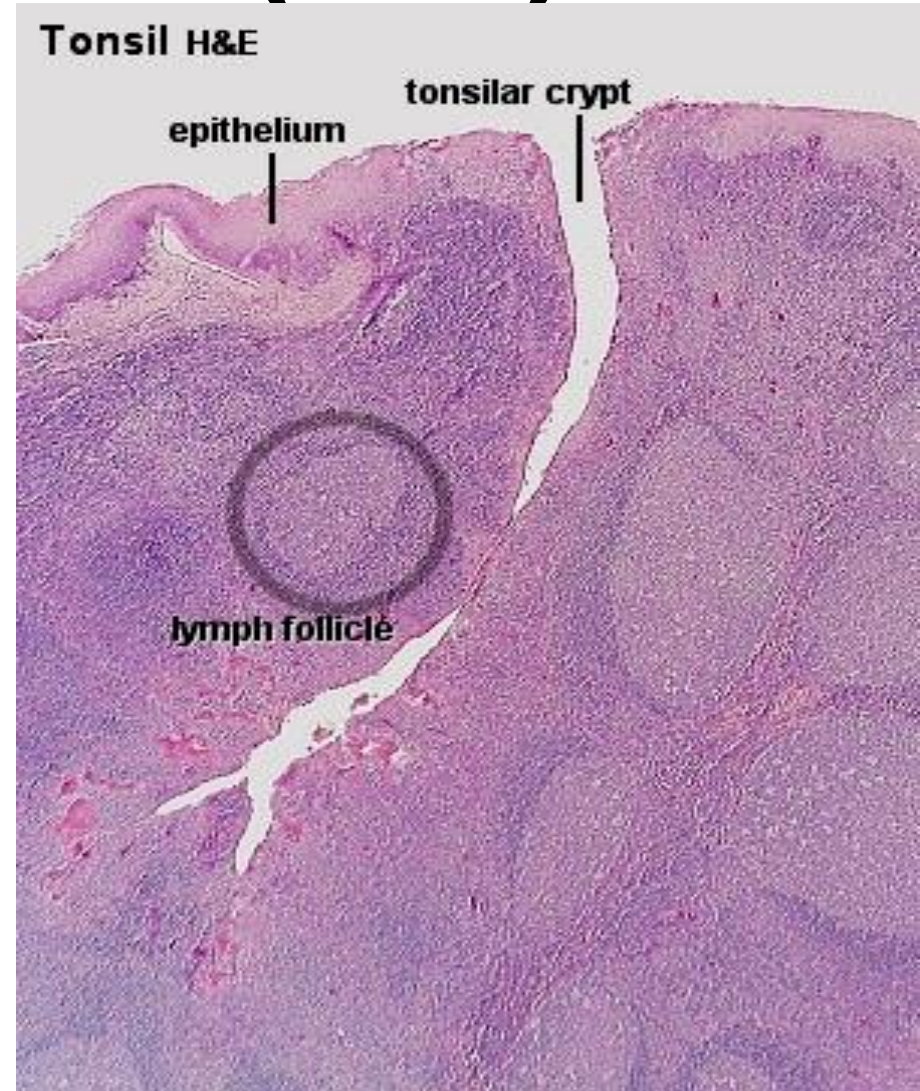
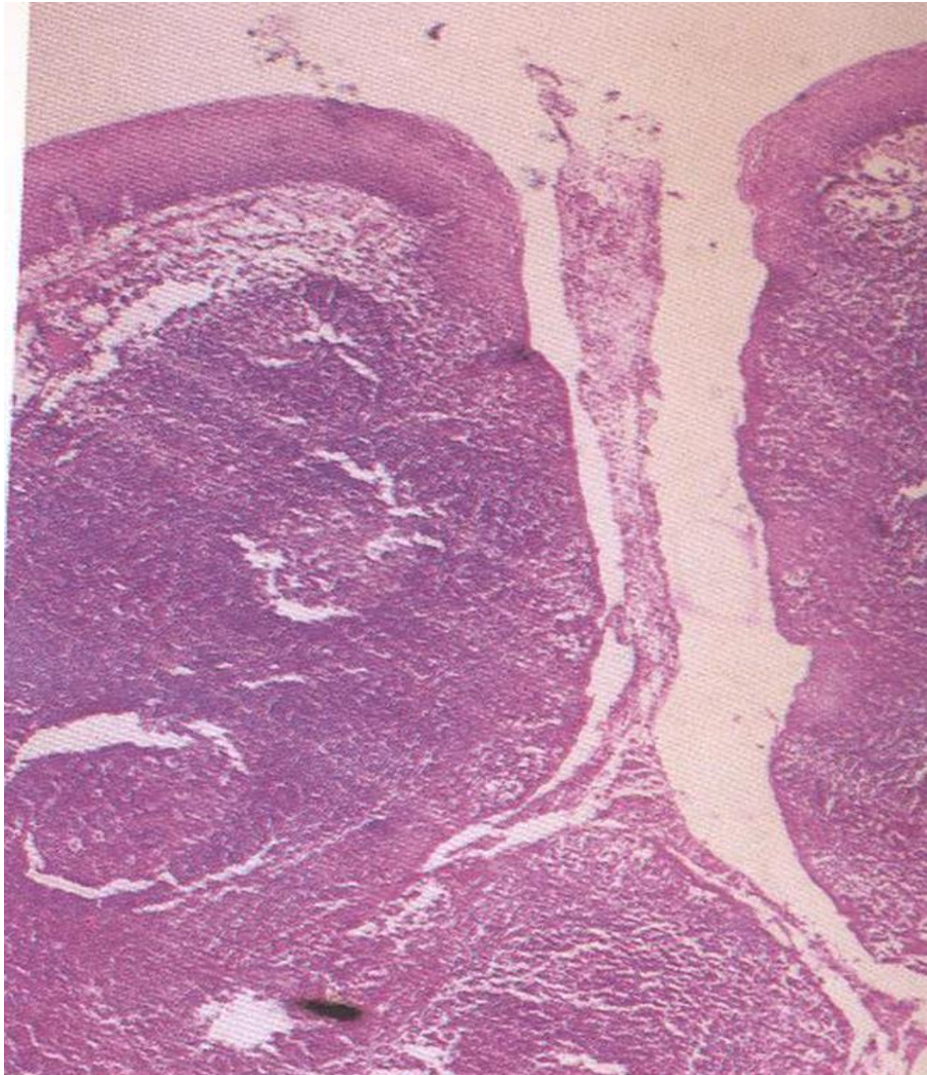
Soft palate

Uvula

Palatine tonsil

Tongue

Palatine Tonsil (H&E)



Pharyngeal tonsil

- **Single lymphoid mass**

Site: Under mucous membrane of nasopharynx
pseudostratified ciliated columnar epithelium

- **No crypts but folds**
- **contain diffuse lymphoid tissue**
- **Atrophy after 4 years old**

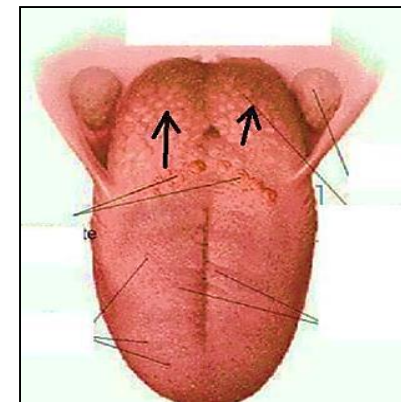
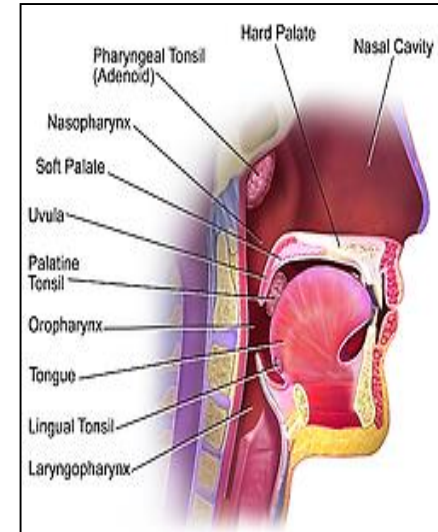
Hypertrophy ----- Adenoid

Lingual tonsil

The posterior 1/3 human tongue

Covered e non keratinized stratified squamous epithelium.

contains lymphoid nodules + diffuse lymphocytes.





Thank you