

Pediatric Discussion

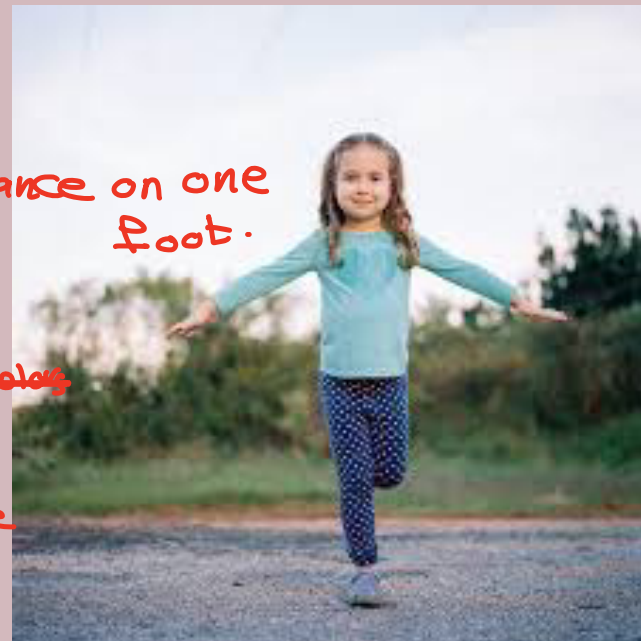Dr.Omar Nafae

Presented by: Eman Mohammed
2023/8/13 Sunday



Station

- 1-What is the name of this skill? → Balance on one foot.
- 2-What is the age of this girl? 4 years
- ~~3-How many color can she name? 4 colors~~
- 4-How many can she count? Count to 20 or more
- 5-What is her pencil skill?
↳ Copies a cross



Station

1- Describe the lesion → hyperpigmentation lesion
(Café Au Lait Spot)

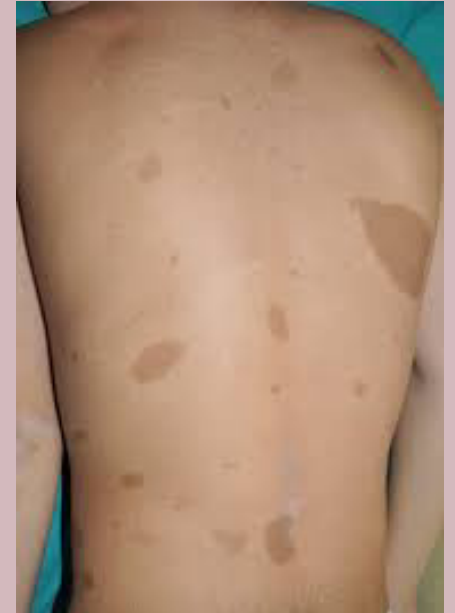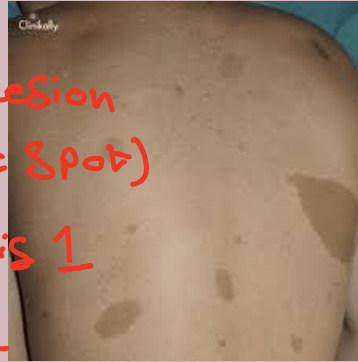2- What is your diagnosis → Neurofibromatosis 1

3- what is mode of inheritance Autosomal dominant

4- Write another finding associated with this disease

↳ Lisch nodules

D Dx: Neurofibroma, Lisch nodule, Freckling, HTW
macrocephaly, Renal involvement, heart involvement



Case study

15 Months old patient with history of vomiting and fever

1-What is your DDX? → *Bacterial meningitis*

2-What are the most common 3 organism ?
→ *S. pneumoniae*
→ *N. meningitidis*
→ *H. influenzae*

3-if the culture show gram + diplococci, what is the organism? *S. pneumoniae*

4-what is the treatment? , and what is the role of corticosteroids?

* 3rd generation Cephalo... + Vancomycin + Corticosteroid
↓
Dexamethasone

• Blood

- WBC = 22, Platelets = 298, RBC = 4.5, Na = 136, K = 3.6, glucose = 95

• Urine:

- RBC = 2-4, protein = +1, PH = 5.5

• CSF:

- Protein = 110
- Glucose = 2
- WBC = 1000 (90 % neutrophile)

Case study

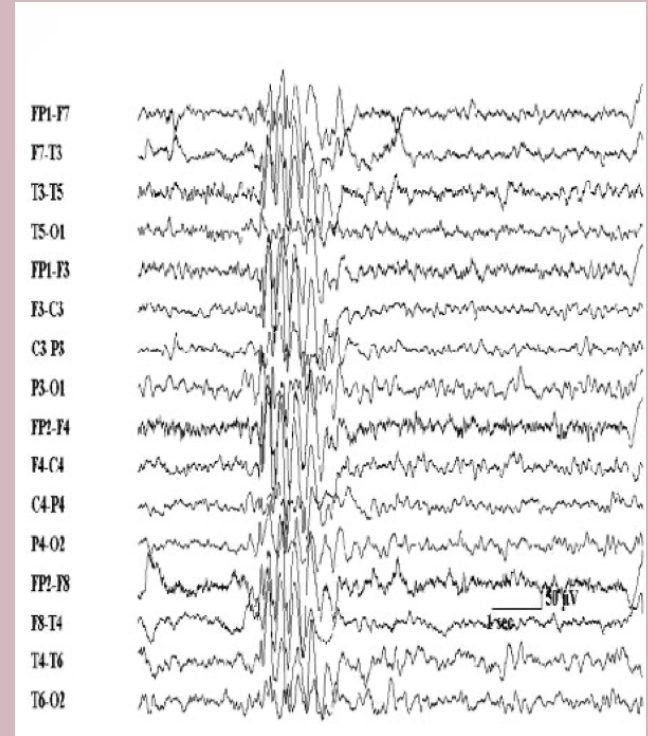
A 6 weeks old male presented to the Emergency Room with fever, poor feeding. on physical examination there was bulging fontanelle. CSF test shows presence of neutrophils, increase protein, low glucose level

- 1-What is the most likely diagnosis? *acute bacterial meningitis*
- 2-List 3 causative agents? *GBS, E Coli, Listeria*
- 3- Management? *ampicillin + Cefotaxime.*
- 4- What are the neurological sequels this child at risk for?
→ hydrocephalus, hearing loss, mental retardation

Case study

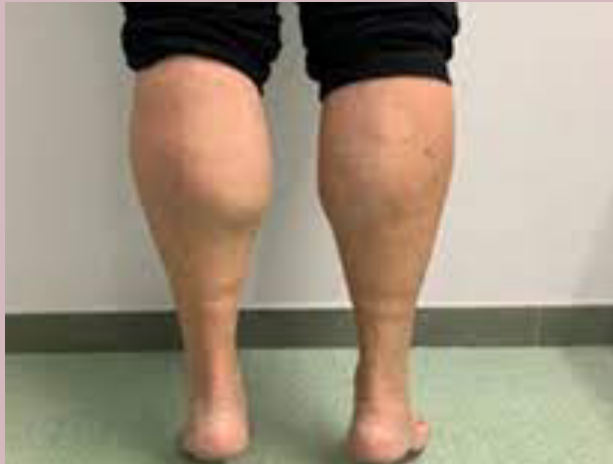A female, 14 years old , complain of early morning myoclonic seizures ,the seizure often single or multiple myoclonic jerks .
The EEG shows generalized fast spike and wave discharges (look at the picture)

- 1-What is Your Diagnosis? *Juvenile myoclonic epilepsy*
- 2- What is the Treatment?
↳ Valproic acid.



Station 2

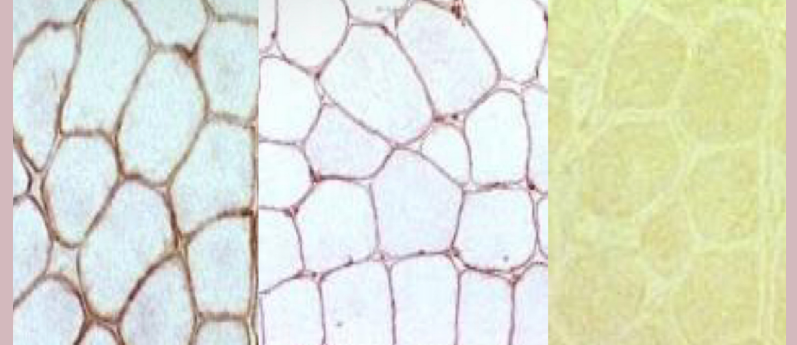
Look at this pictures and answer the questions in the next slide:




1



2



- 1-What is the name of the sign in pic 1? → *Calf hypertrophy*
- 2-What is the name of the sign in pic 2? → *Gower sign*
- 3-Give 3 DDx.
- 4-Give 2 Lab test for the diagnosis. → *CPK, nerve conduction study*
- 5-What is the name of the material stained in the biopsy? *Eosin and hematoxilline stain the dystrophin.*

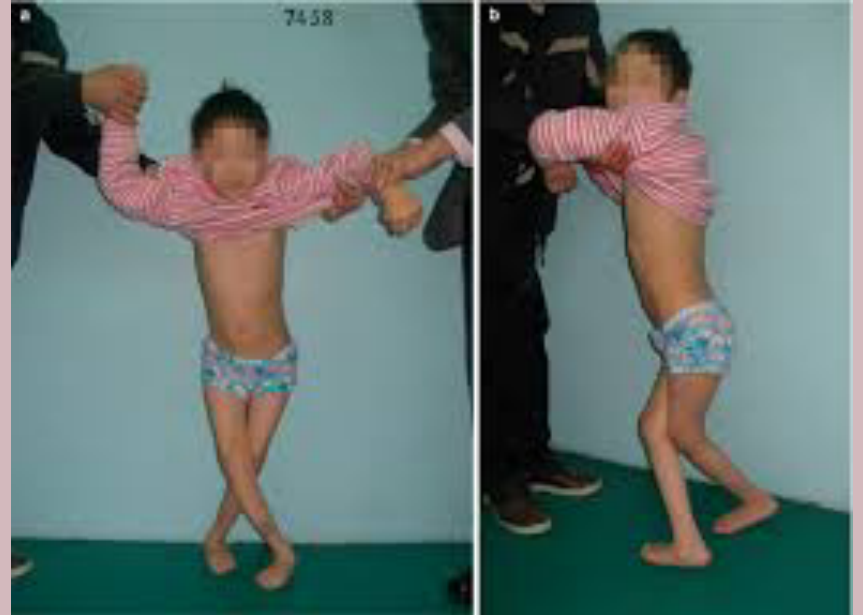

Station

1-What is the sign called?

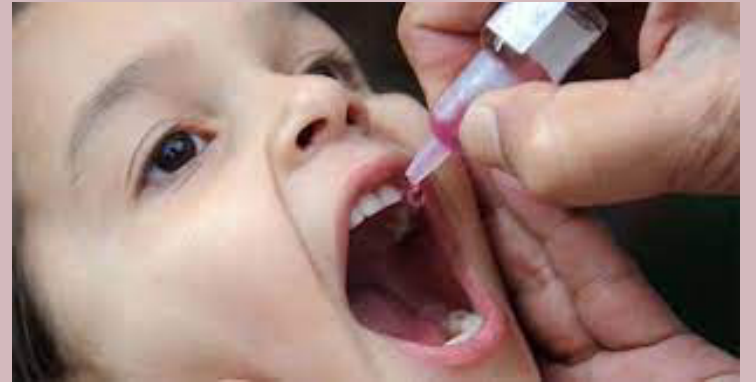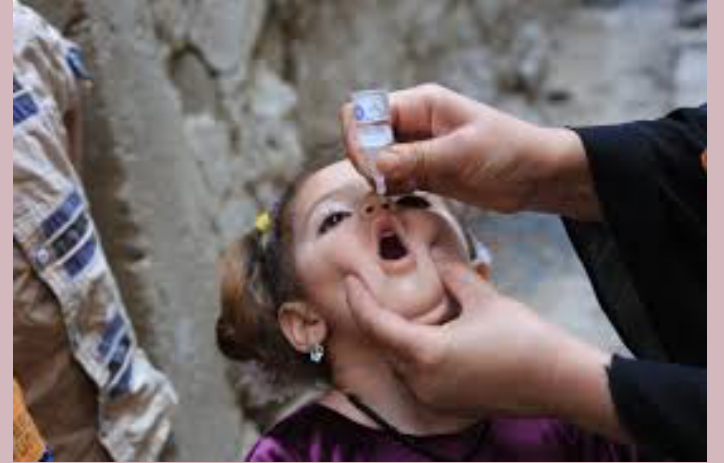→ Scissoring posture

2-Give one disease you can see this sign?
cerebral palsy [spastic]



1-What do we call this vaccine? *opv*

2-What is the age of this child? *91 day*
تخافوق



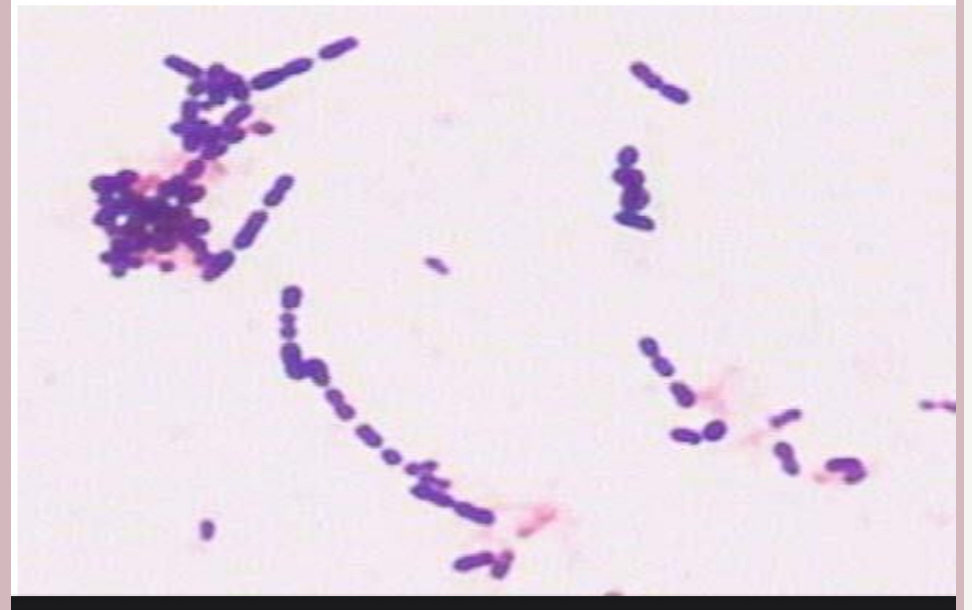Gram stain for CSF for 5 year old patient with meningitis.

1-identify the microorganism?

Strep. pneumoniae

2-What is the treatment for it?

Corticosteroids + Vancomycin + 3rd genera...



Gram +

Case Study

A child 18 Months old came to ER with Fever, jerking movement and loss of consciousness.

1- What is the most common diagnosis? *febrile seizure*

2- what is the most important diagnosis? *meningitis*

3- what are the vaccines that the child should take at this age?

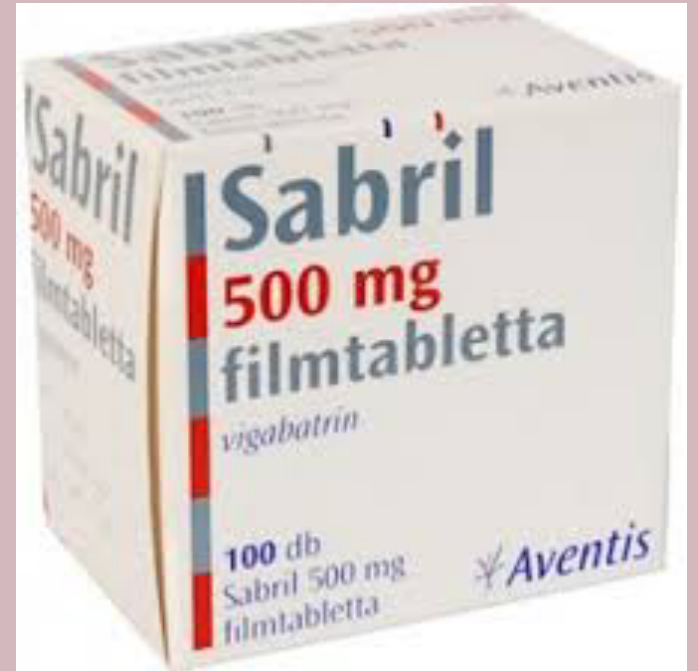*DpT (booster) , opv (booster) , Hep A, MMR
+ Vit A 20000*

1- This drug used in treatment in?

West Syndrome.

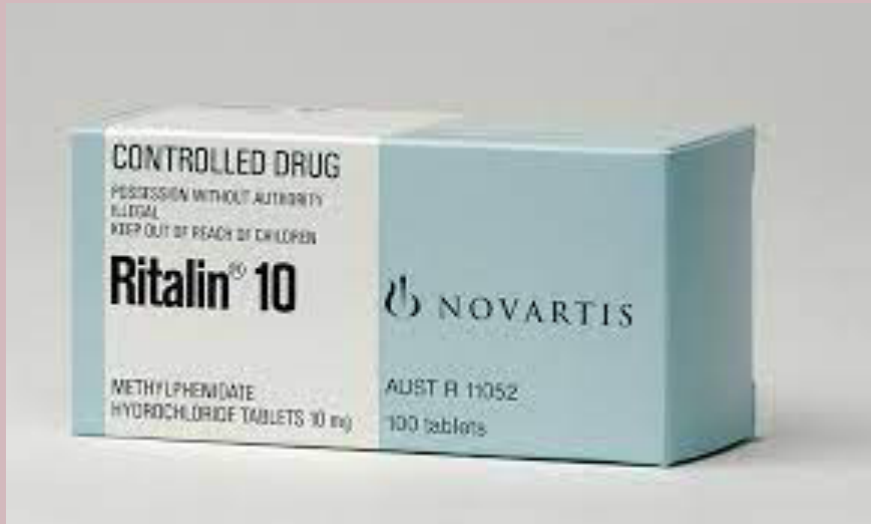2-Give one side effect of this drug?

Visual field defect



Vigabatrin

- This Medication used in? *ADHD*
- Mechanism of action? *Stimulants*



Thank You

