

# Wareed(2018) Mini-OSCE

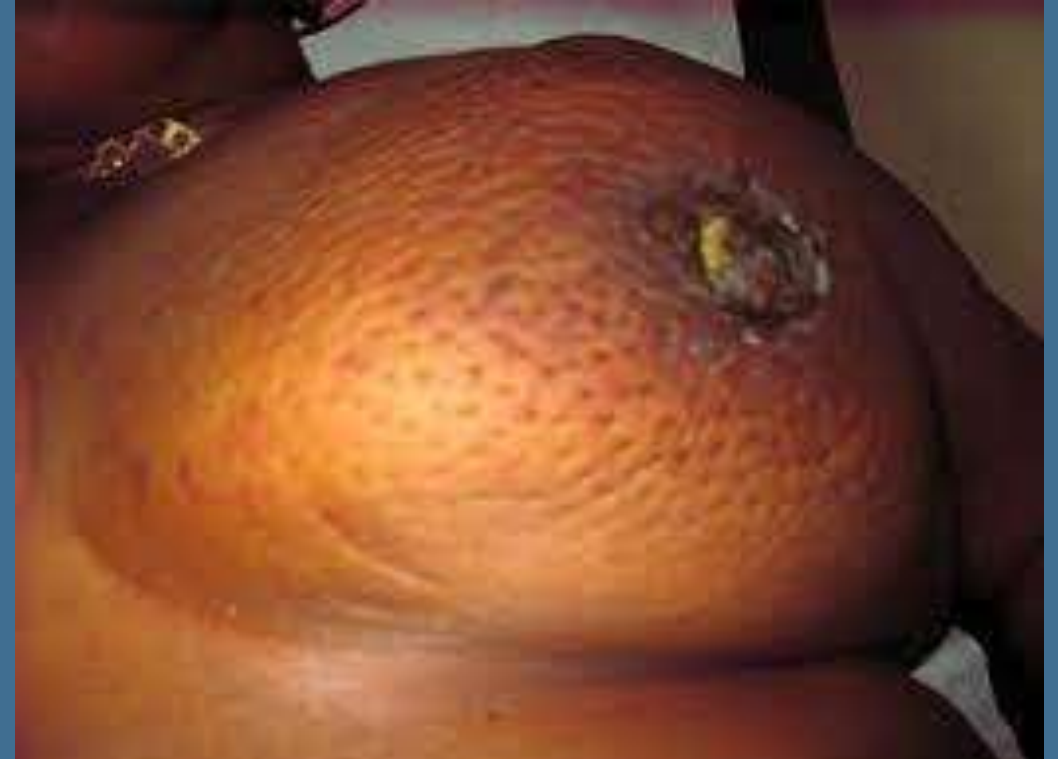What is the most likely diagnosis ?

1)

2) Peau d'orange of breast

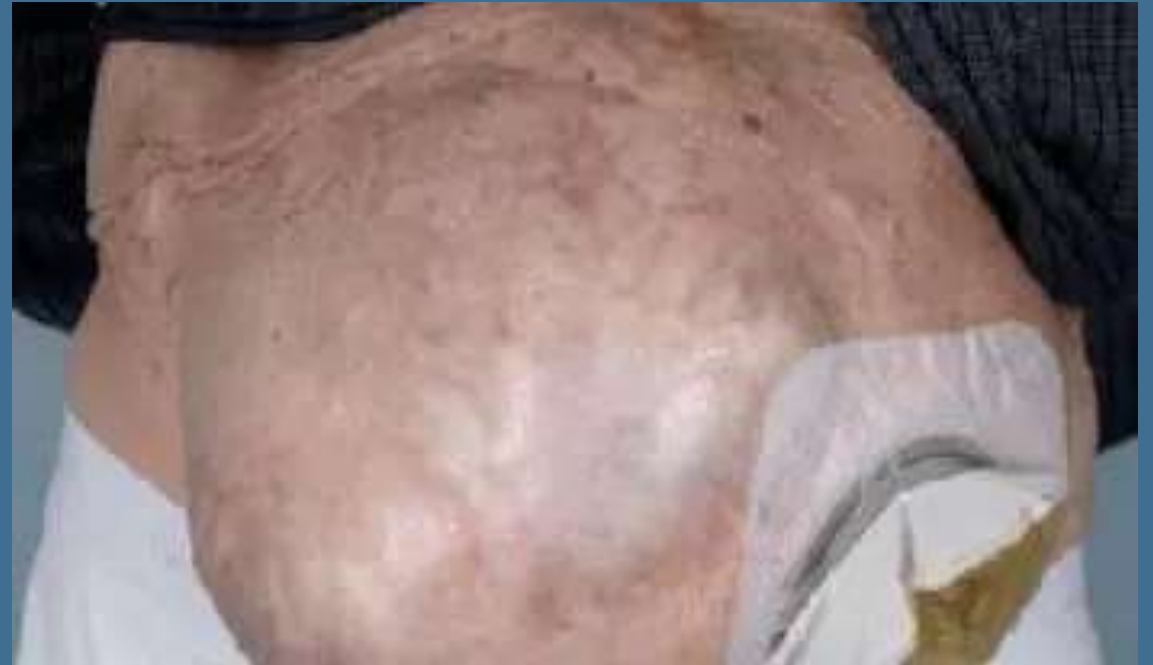3)

4)



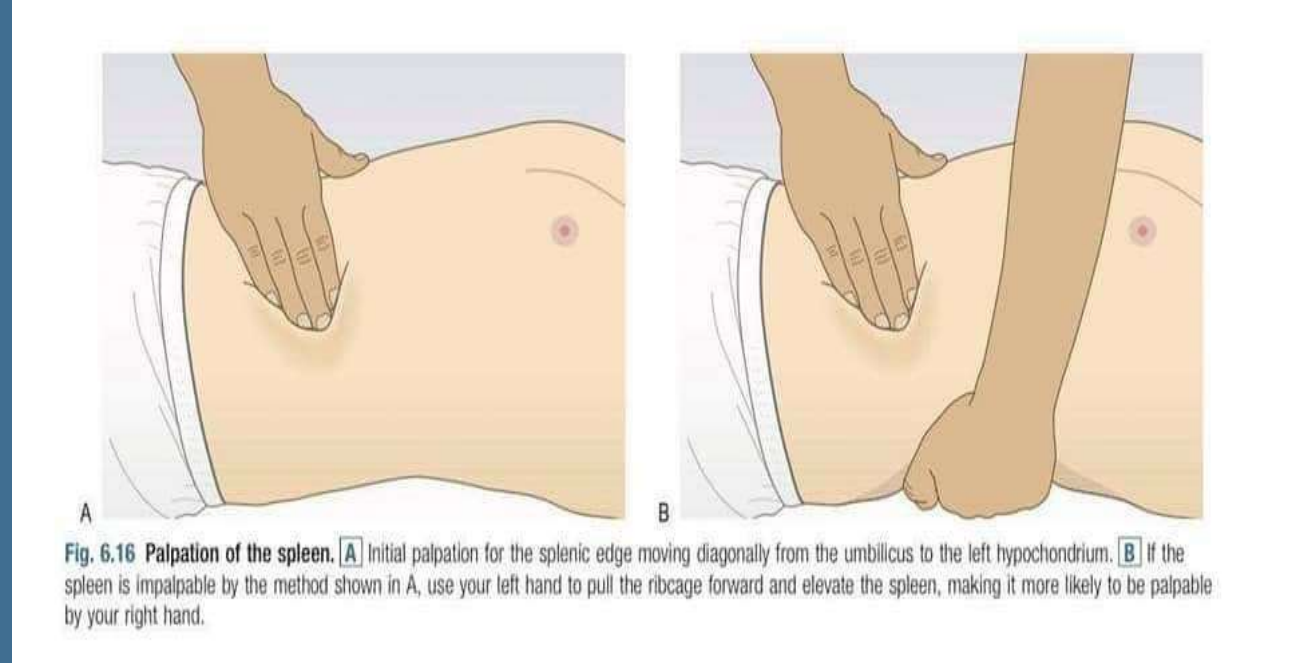
65 y.o patient had a colon resection a year ago, later on he developed a mass at the site of operation ?

- 1) Peri-umbilical hernia
- 2) Direct inguinal hernia
- 3) Indirect inguinal hernia
- 4) **Incisional hernia**



# The doctor is examining ?

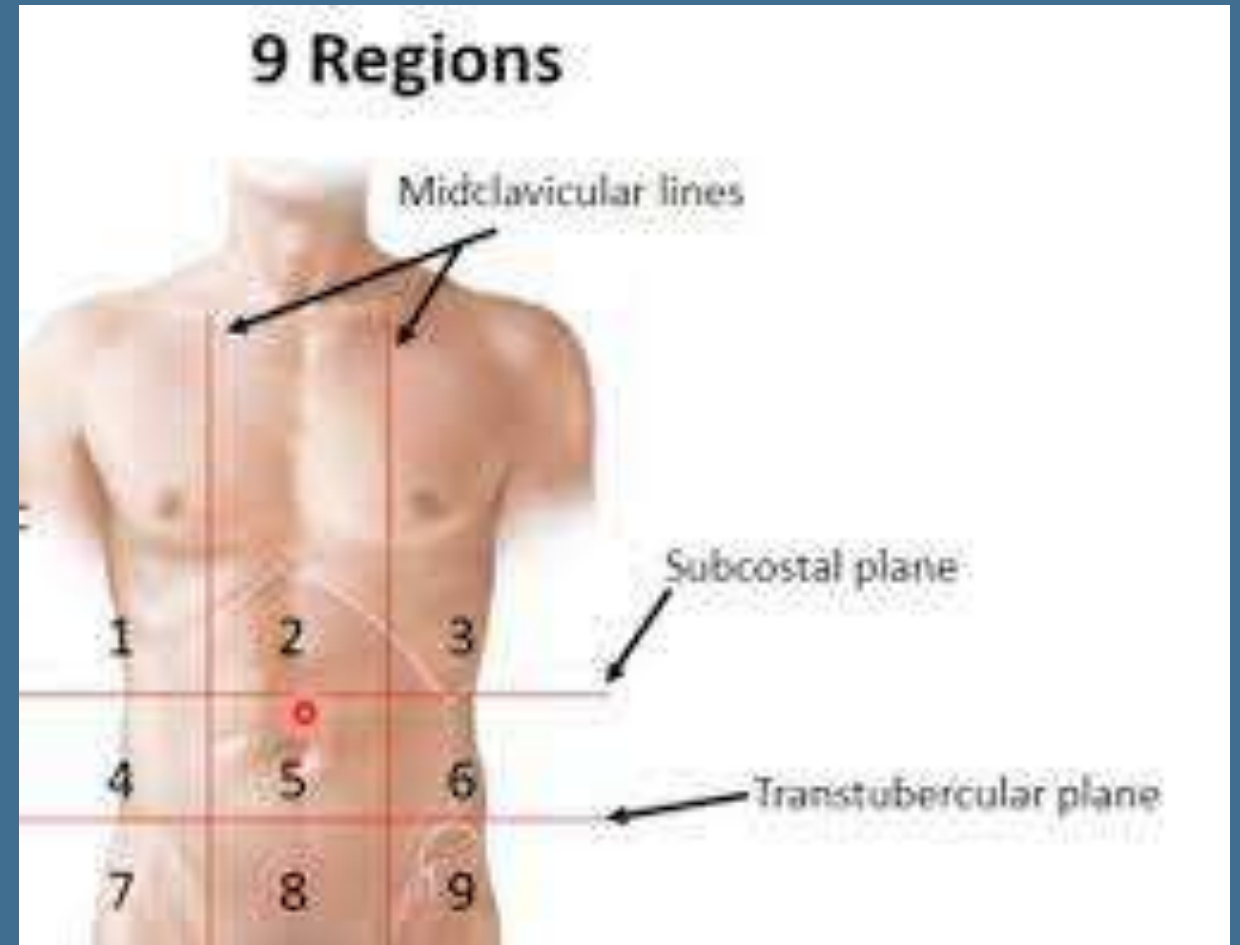
- 1) Kidney
- 2) Liver
- 3) Spleen
- 4) stomach



الصورة غير دقيقة لكن اعتمدوا  
الإجابة لأنها من الدكاترة

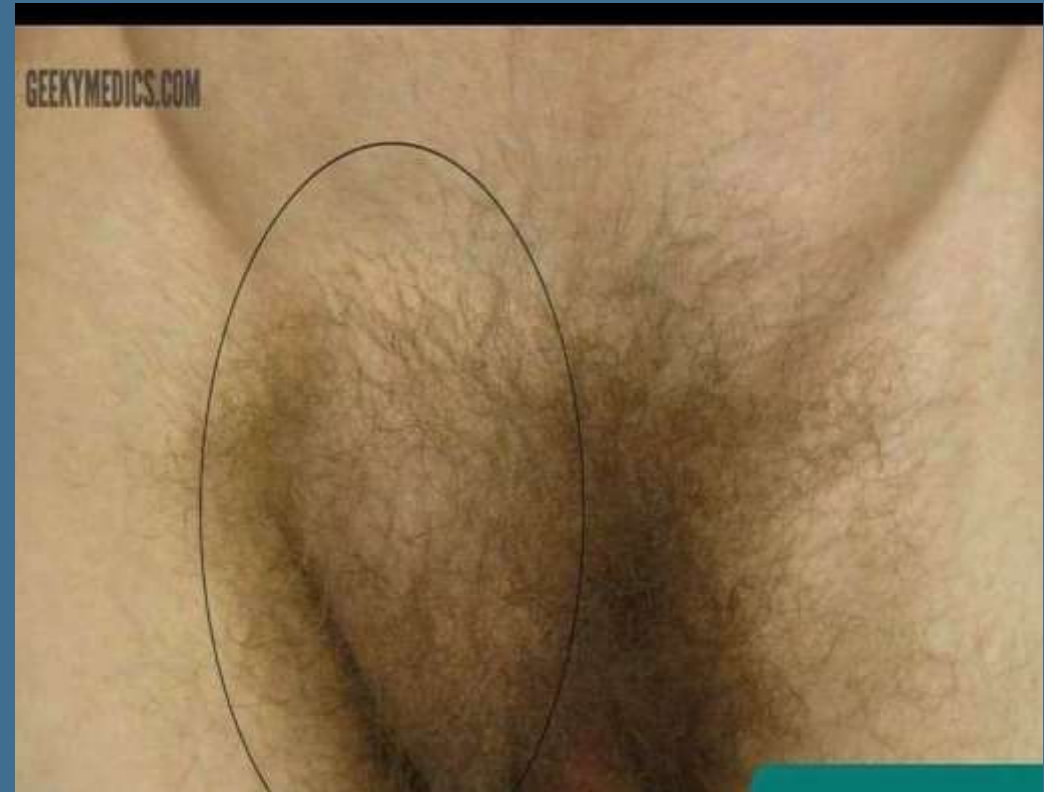# What is the name of region number 9 ?

- 1) Left hypochondriac region
- 2) left iliac fossa
- 3) left lumbar region
- 4) Hypogastric region



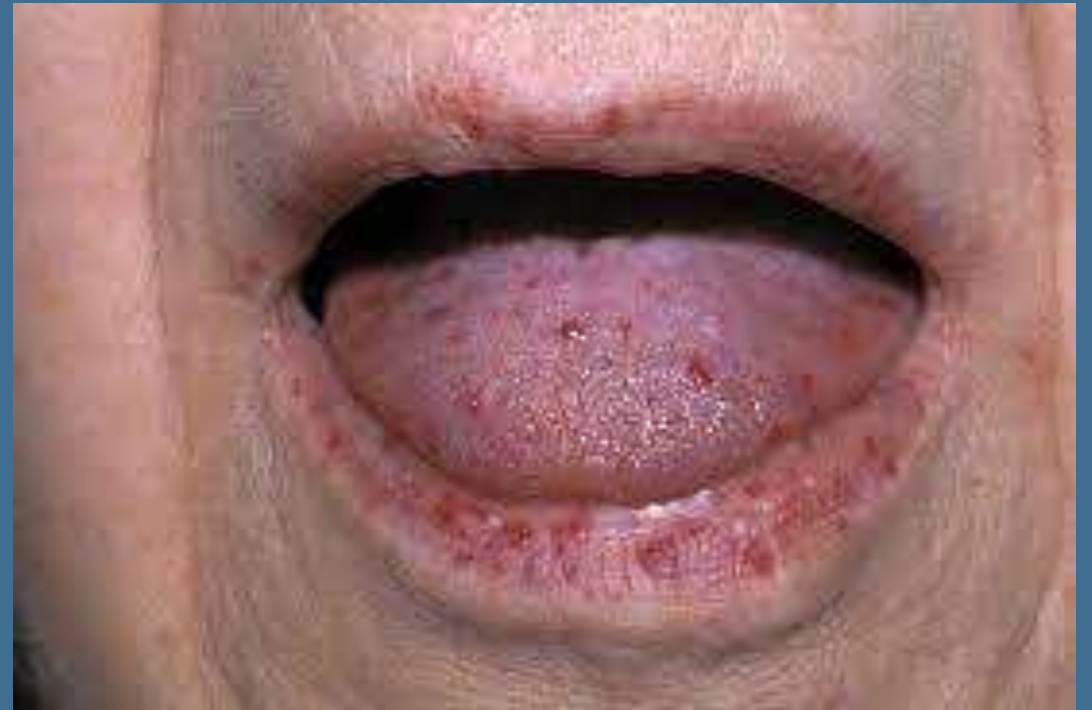# Recur after deep inguinal ring closure ?

- 1) Left indirect inguinal hernia
- 2) right direct inguinal hernia
- 3) right indirect inguinal hernia
- 4) Left direct inguinal hernia



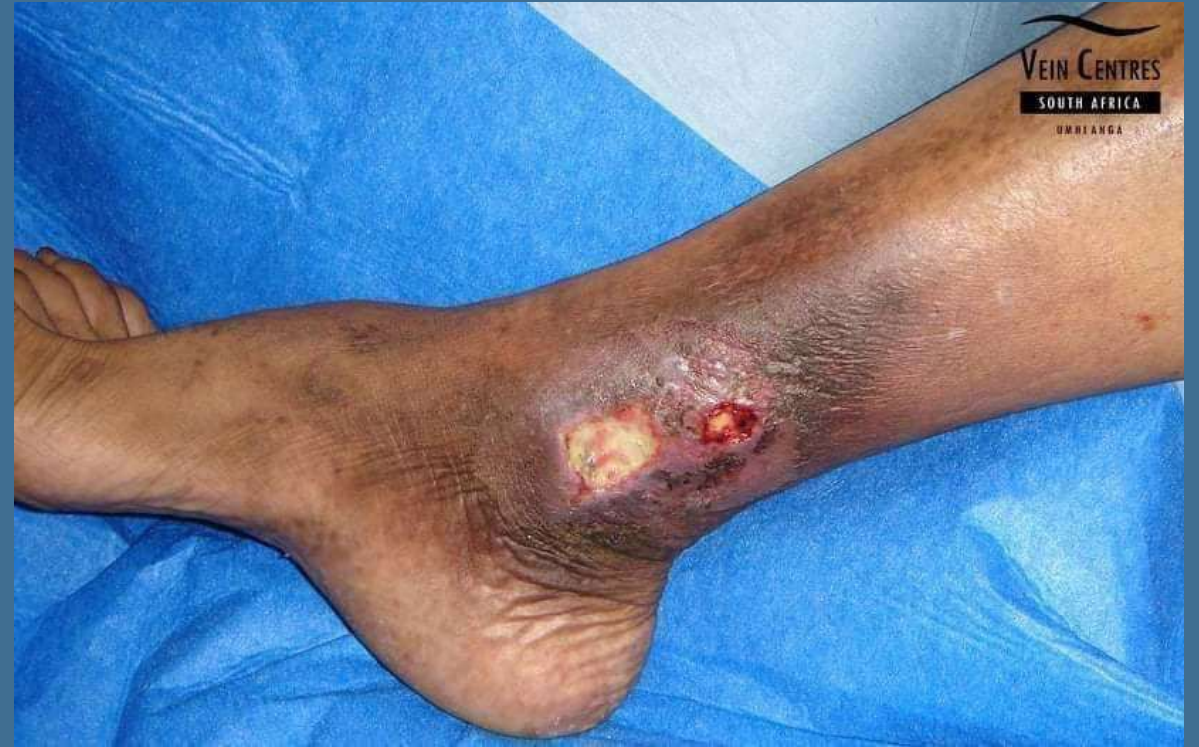# Diagnosis of this condition ?

- 1) Telangiectasia
- 2) Petechial rash
- 3) Addison's disease



# Diagnosis ?

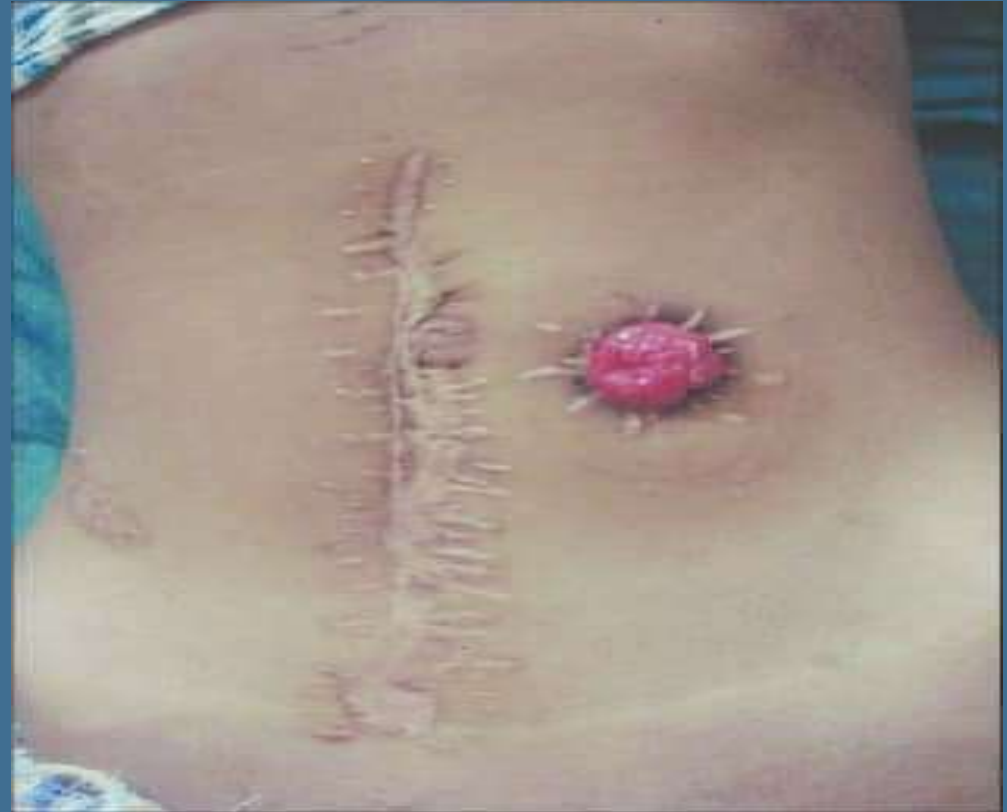- 1) Arterial ulcer
- 2) Neuropathic ulcer
- 3) Bed ridden ulcer
- 4) Sloping edge ulcer





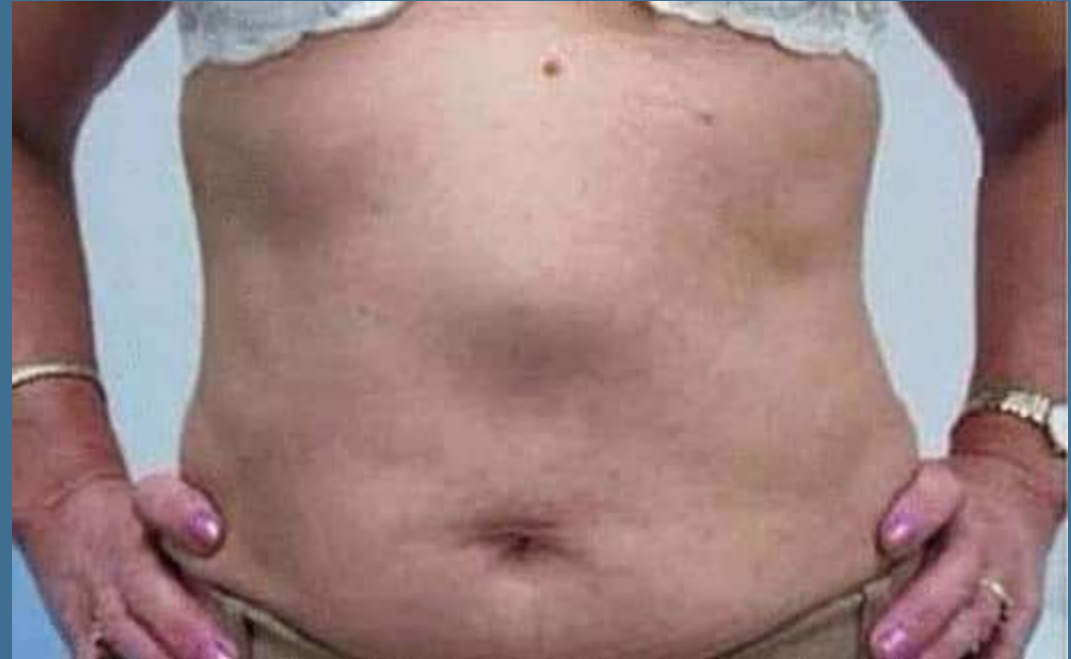# What is the name of incision ?

- 1) Kocher incision
- 2) Paramedian scar
- 3) Rutherford-morison incision
- 4) Pfannestiel incision
- 5) **Midline incision**

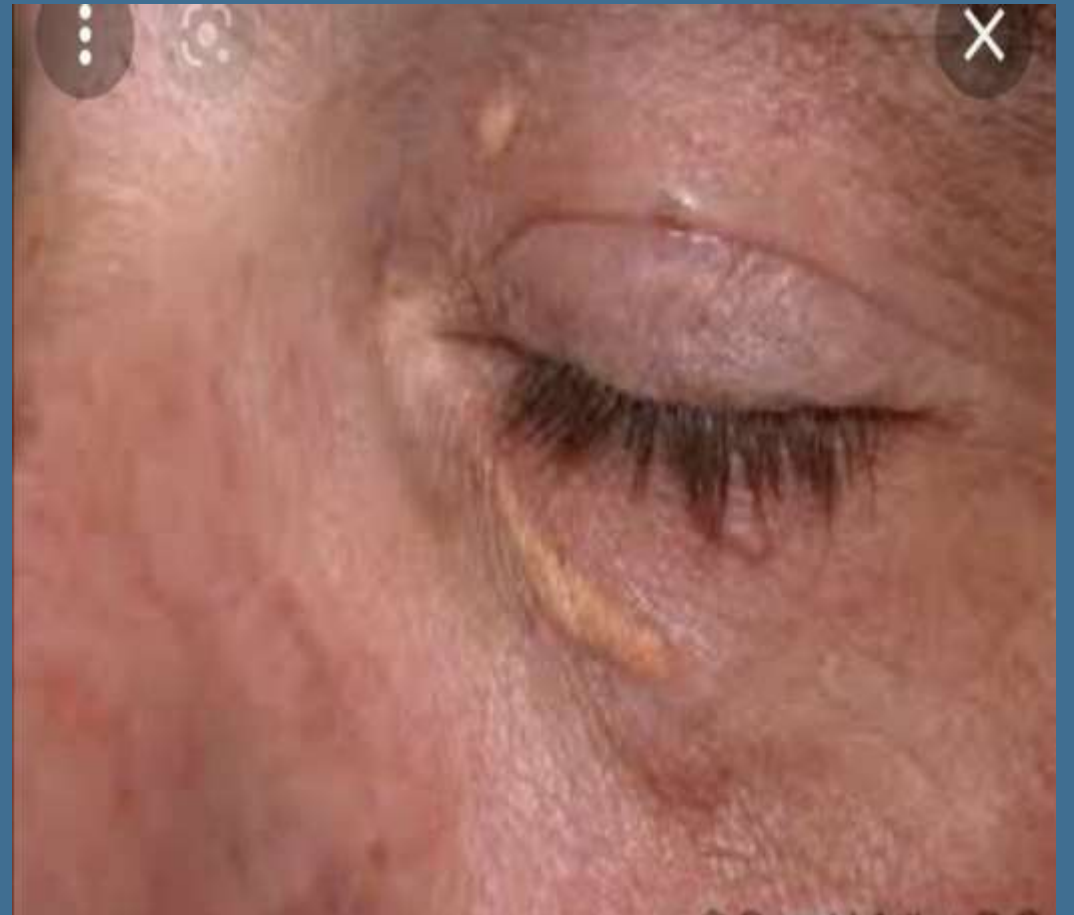

The patient has a mass that disappears on lying down ?

- 1) Aortic aneurysm
- 2) Epigastric hernia
- 3) Abdominal lipoma
- 4) Abdominal diverticuli
- 5) Gastric cancer



# 1) Hyperlipidemia(xanthelasma)

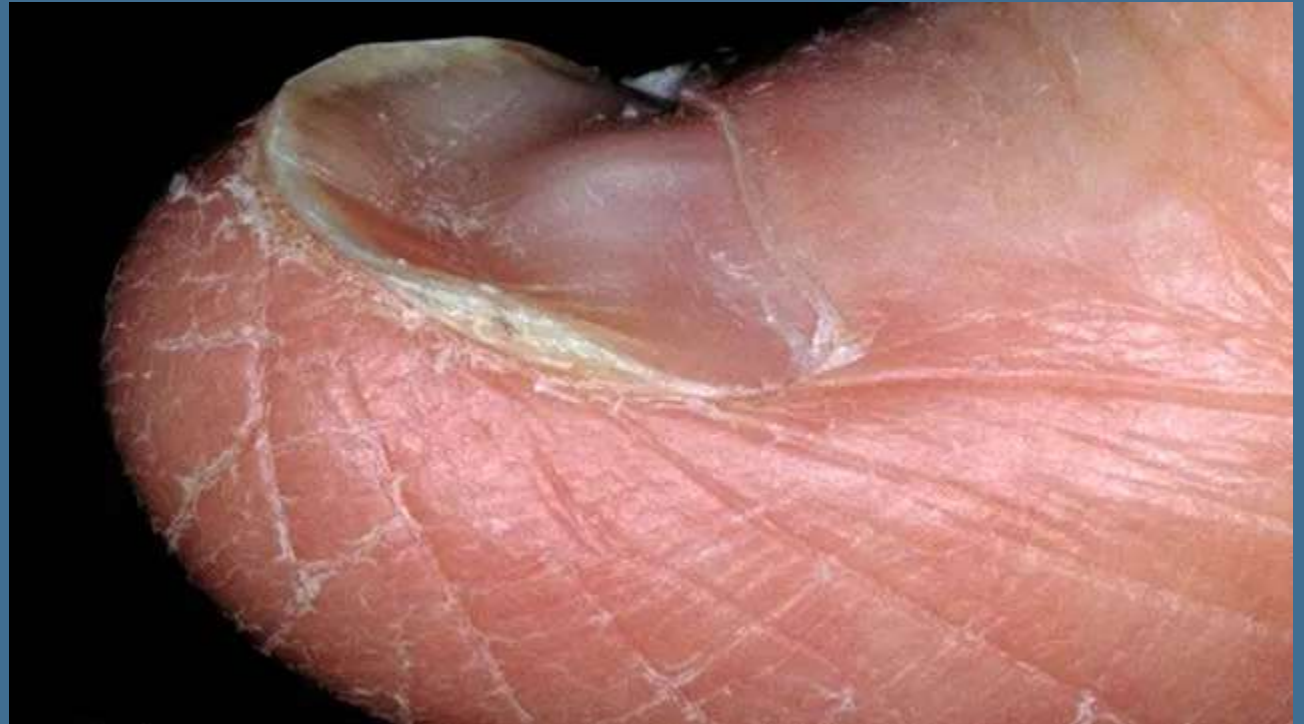

This test is done for patients with ?

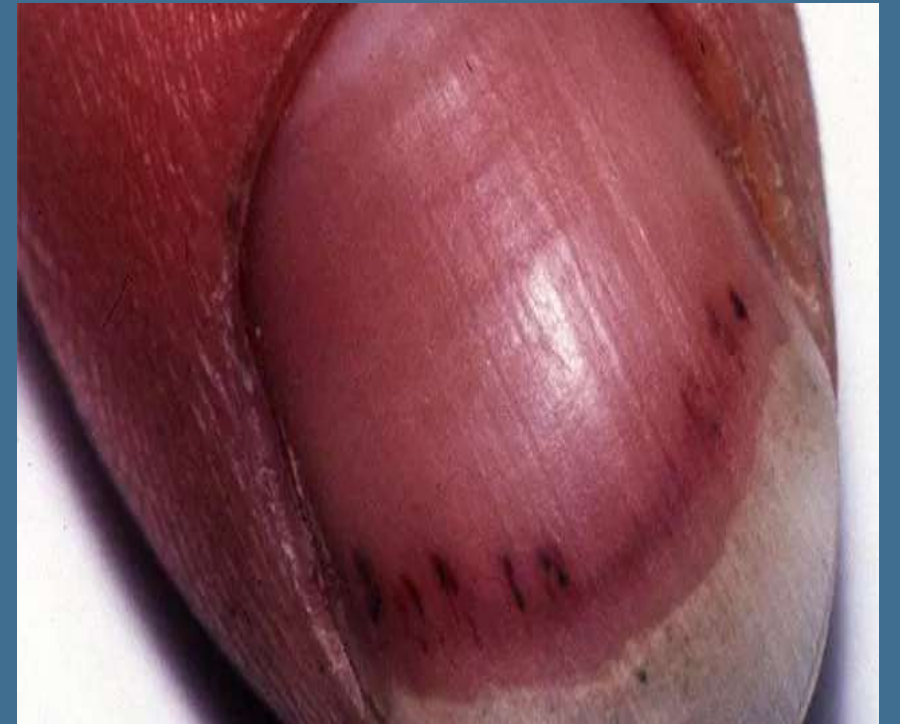- 1) Aortic Regurgitation
- 2) Radio-femoral delay
- 3) Aortic stenosis
- 4) Radioradial delay



- 1) leukonychia
- 2) Onycholysis
- 3) Koilonychia
- 4) paronchia

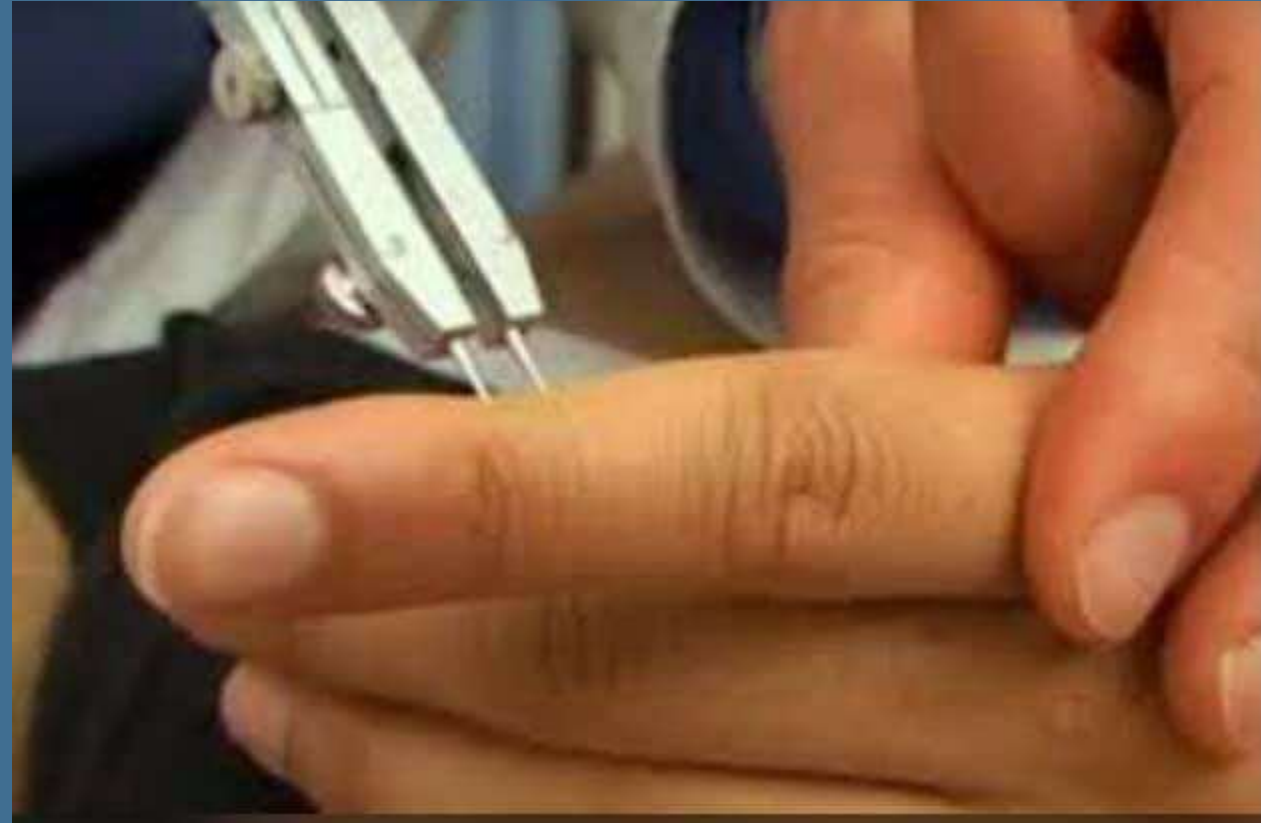

1) Splinter hemorrhage (infective endocarditis)

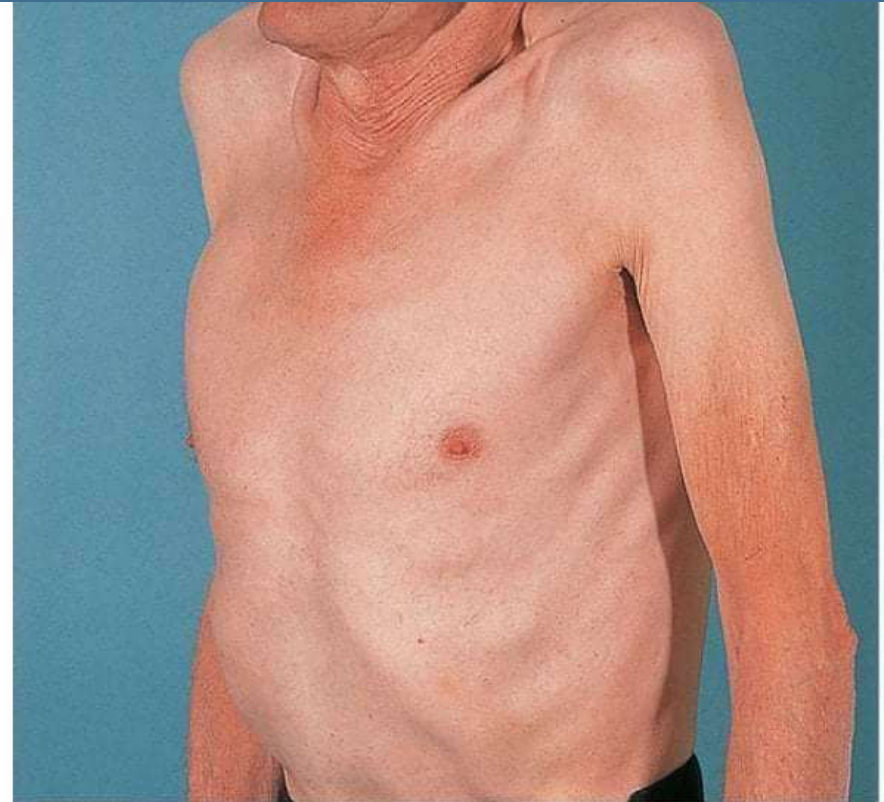


Name of the test?

- 1) Two point discrimination  
(high cortical function)
- 2) pain
- 3) Touch test




1) Hyper inflated chest with raised sternum



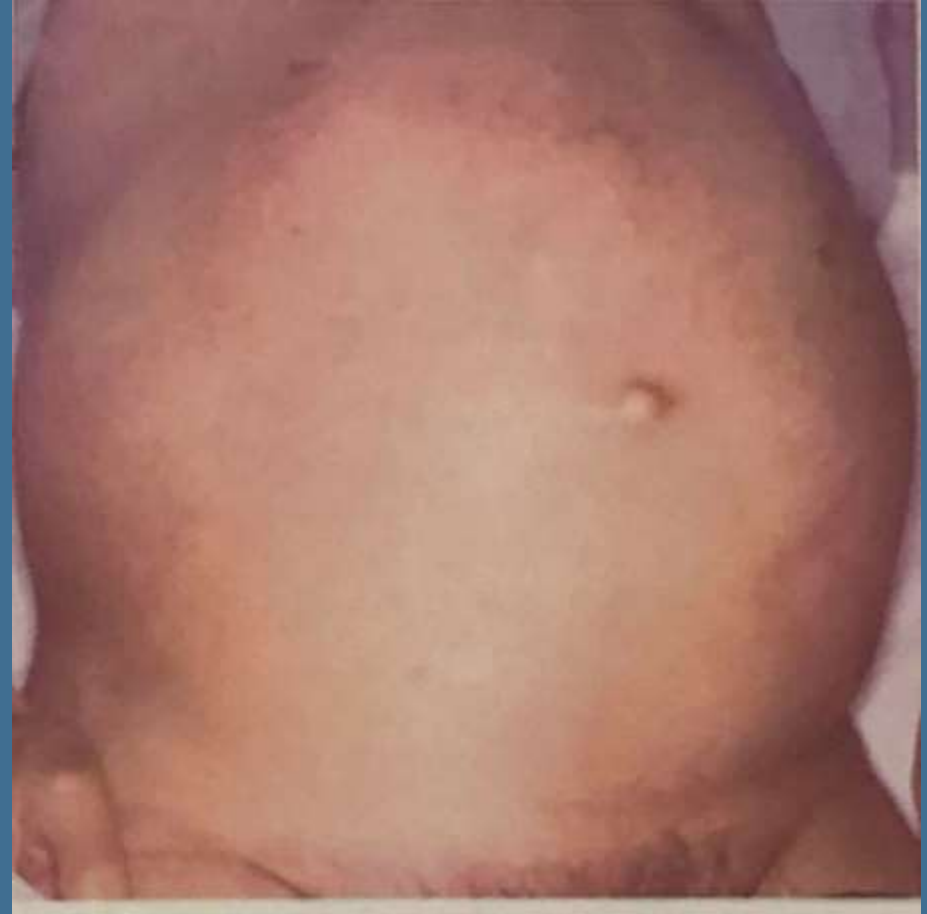

- 1) Purulent sputum
- 2) Mucopurulent sputum
- 3) Mucoïd sputum=m



# What is the test done for this condition?

- 1) Transmitted thrill
- 2) Shifting dullness
- 3) Superficial palpation



الدكتور أكد انها moderate ascites  
لذلك الإجابة shifting dullness

# Apex beat in the 6<sup>th</sup> ICS & anterior axillary line

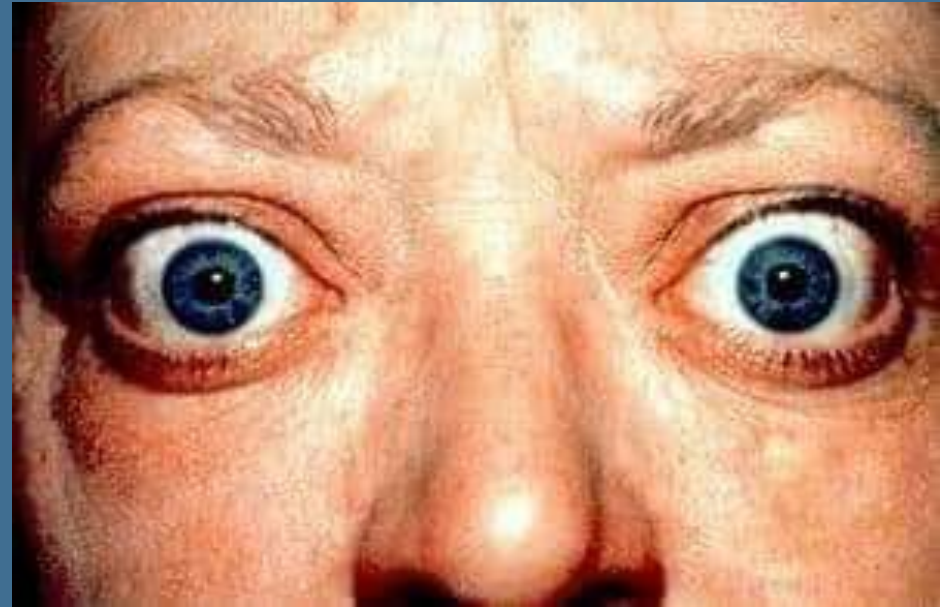- 1) Right ventricular hypertrophy
- 2) **Right ventricular dilation**
- 3) Left ventricular dilation
- 4) Left ventricular hypertrophy
- 5) Right atrial hypertrophy

نص السؤال ماتذكرناه :)

Lid lag ?

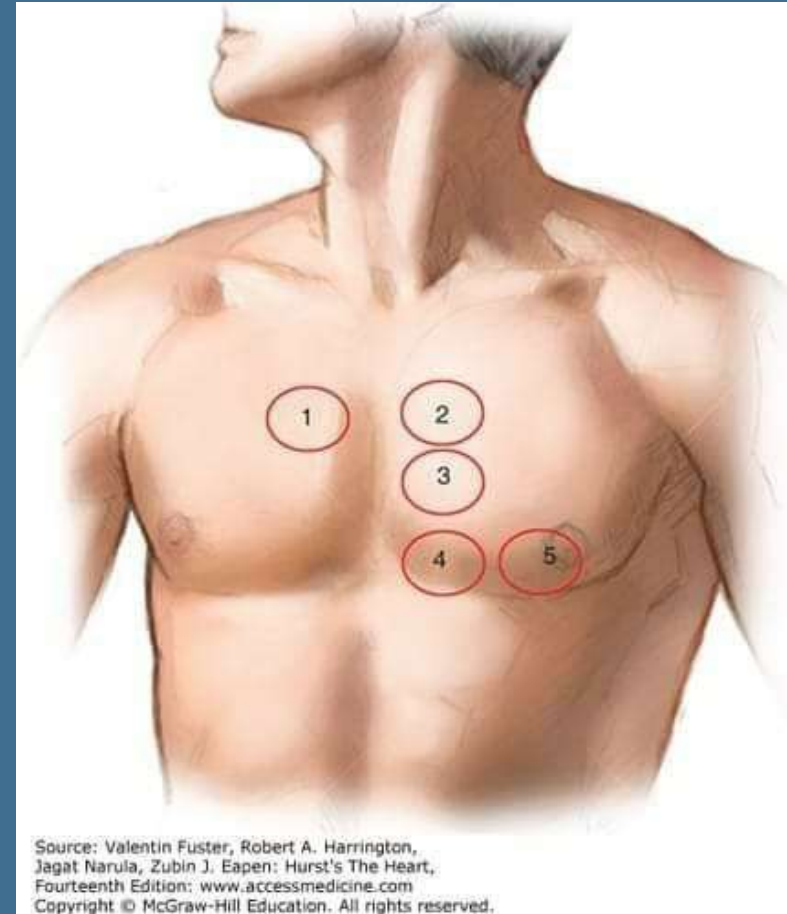
Lid retraction?

Exophthalmos xxx (الاعلى)

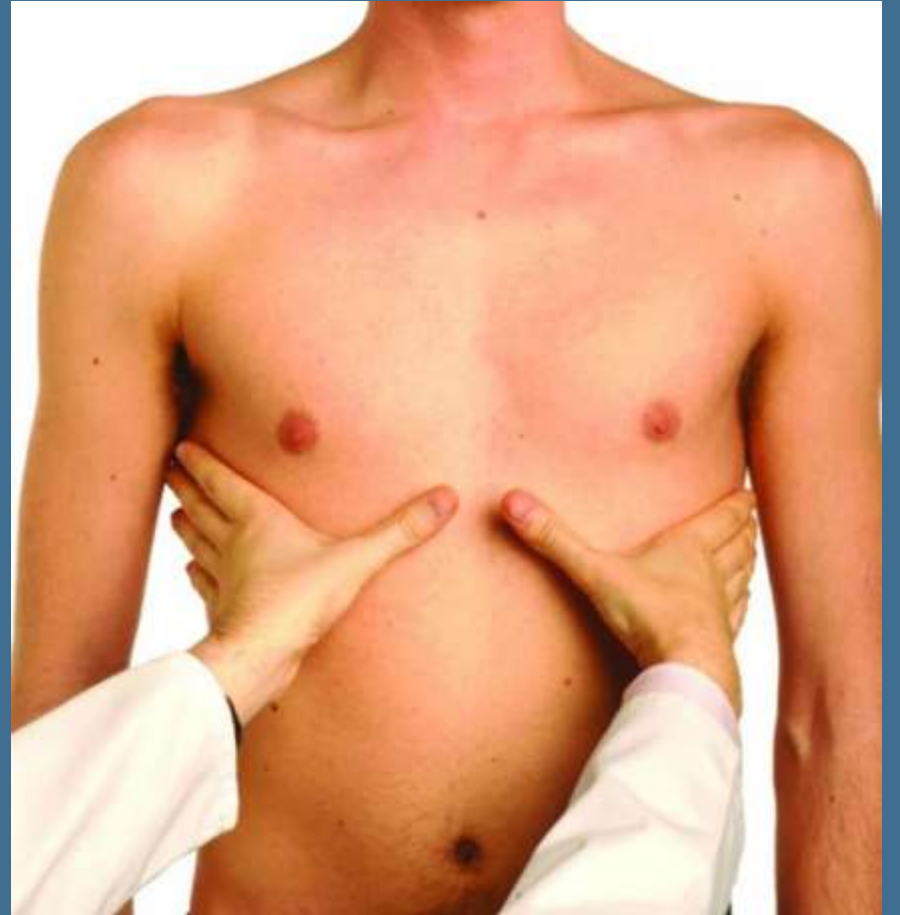

# Erb's area ( secondary auscultatory area) ?

- 1) 1
- 2) 2
- 3) 3
- 4) 4
- 5) 5

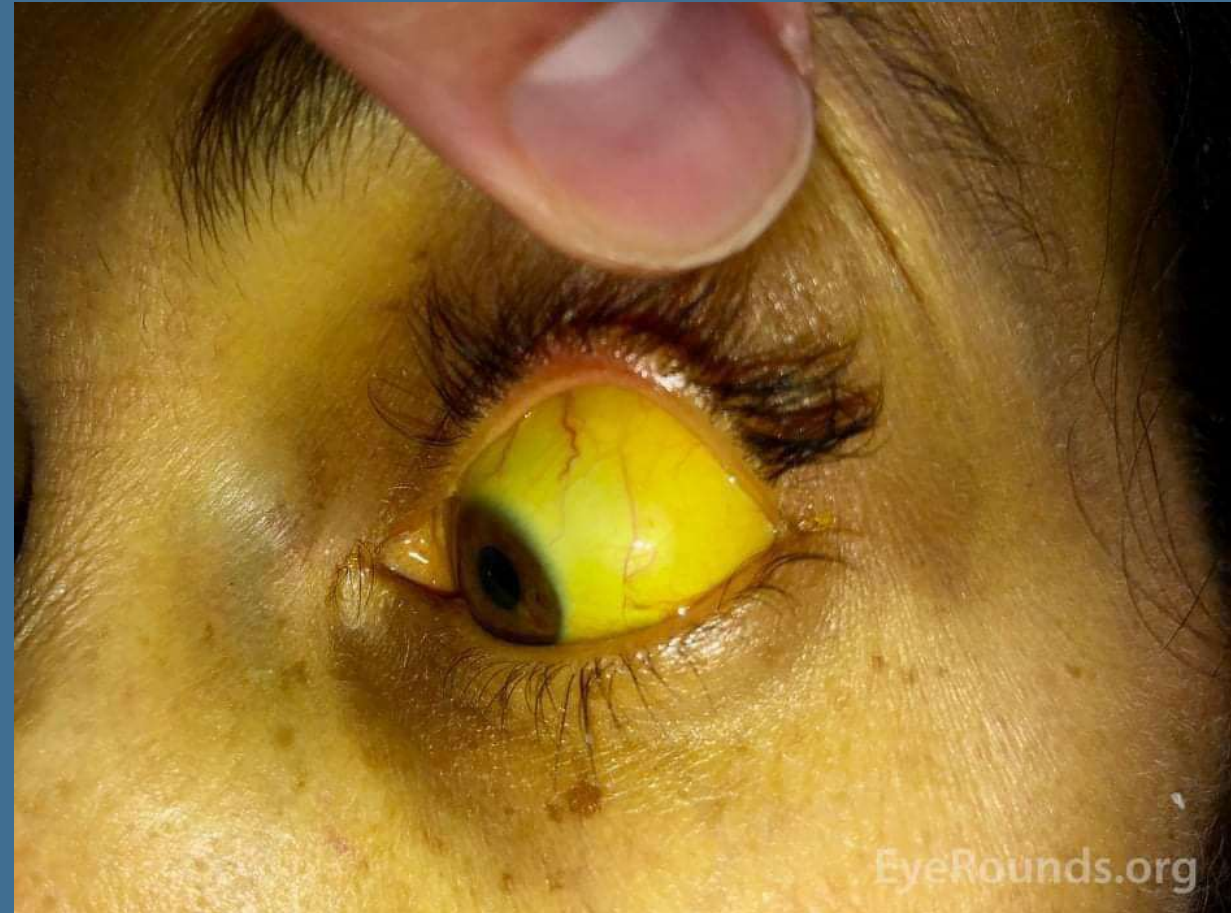

## 1) Chest expansion test



Pt came to ER complaining of pale stool and dark urine, what is the most appropriate differential diagnosis ?

- 1) Hemolytic anemia
- 2) Liver cirrhosis
- 3) Cholecystitis
- 4) Drug induced
- 5) Obstructive(post hepatic) jaundice “stone in bile duct”



Right bells palsy (VII nerve)

