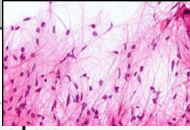

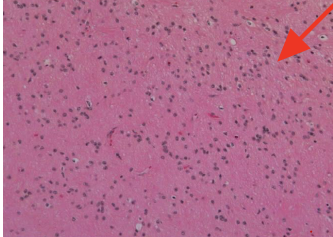
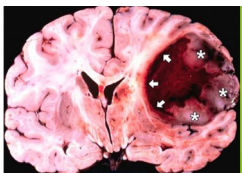
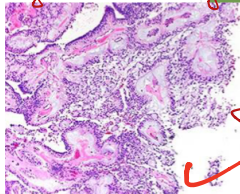
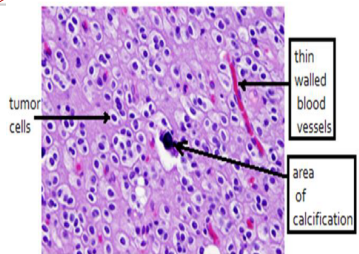
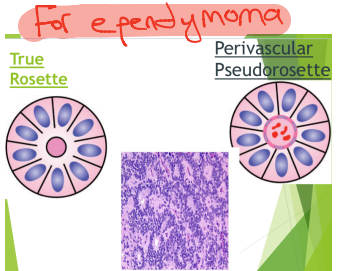
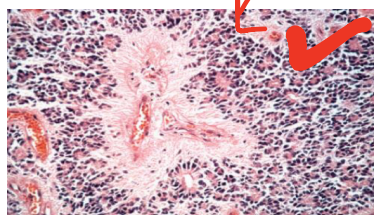
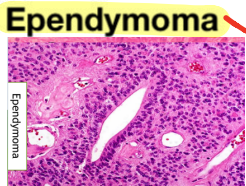
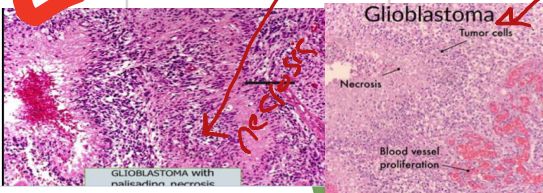
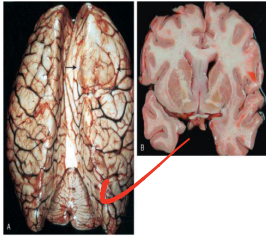
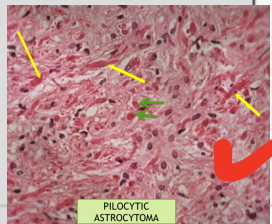
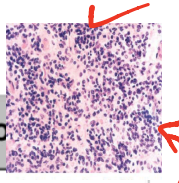
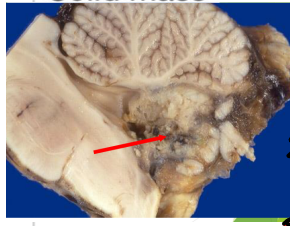
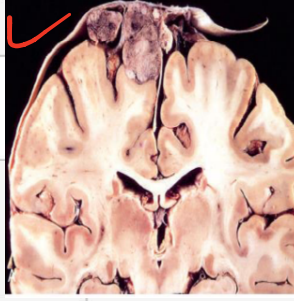
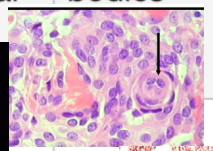
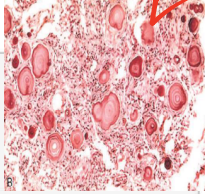


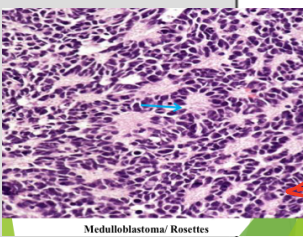
Brain tumors

Tumor	Age	Location	Features	Morphology	Histology
Astrocytoma			GFAP + (all) ? <i>all GFAP +</i>		
1- pilocytic	Children	Cerebellum	IDH - BRAF + 	Cystic with mural component	Bipolar astrocytes, microcyst, Rosenthal fibers, eosinophils
2- diffuse / fibrillary	Adult	Cerebrum	IDH+	Solid lesion 	Proliferating astrocytes that are mildly pleomorphic with no mitotic figures, mixed fibrillary stroma
3-anaplastic	Adult	Cerebrum	IDH+	Solid	Astrocyte with high pleomorphism and high mitotic figures
4-GBM	Adults	Cerebrum	Variable ki-67 	Ring enhancing lesion with hemorrhage and necrosis	Pleomorphism and high mitotic figures + Bv proliferation + palisading necrosis
Ependymoma	-Children -Young adults	-4th ventricle -Lumbosacral spine / 3rd or lat. ventricle	<i>myxomatous changes</i> 	Gray, fleshy mass	<i>round</i> Rosette Perivascular pseudo-rosette Myxopapillary changes
Oligodendroglioma	Adults	Cerebrum	IDH + 1p/19q co-deletion	<u>Calcification</u>	Fried egg cells with calcification

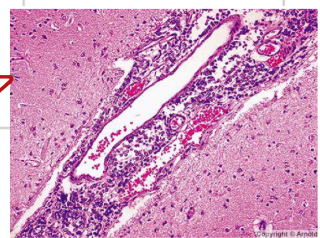
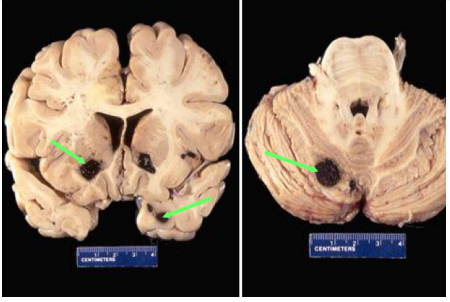
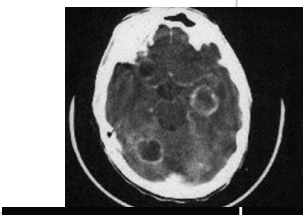




Tumor	Age	Location	Features	Macroscopy	Histology
Medulloblastoma	Children	Midline cerebellum or roof of 4th ventricle	-Myc + : poor prognosis -WNT : favorable	Solid mass 	1-Sheets of small blue hyperchromatic cells 2-Homer-wright rosette 3-Neurofibrillary background
Meningioma	Adult female	Parasagittal Falx cerebri Sphenoid Ventricles	1-PR + 2-NF2 inactivated gene	Well defined solid with dural based mass 	Psammoma bodies :- 
Neuronal tumor					
1- dysembryoplastic neuroepi tumor	Childhood	Nodular lesion at temporal lobe			
2-ganglioglioma	<30	Temporal lobe mostly			Mixed neurons and astrocytes
3- central neurocytoma	Adults				Neuropil
Lymphoma	Adults (AIDS)	Periventricular	EBV +	Single or multiple ring enhancing nodules	B cell lymphoma
Germ cell tumor	First 2 decades of life	Midline (pineal , suprasellar)			Germinoma
Mets		1-Brain mets 2-leptomeningeal mets		Multiple lesions 1- Gray -white matter junction 2- border zone btw MCA and PCA	Primary : - Lung (MC) - Breast - GI - Kidney - Melanoma



Medulloblastoma/ Rosettes



origin of solid primary tumors