

وسهلا



أهلا

يُمنع أخذ السلايدات بدون
إذن المحرر واي اجراء
يخالف ذلك يقع تحت طائلة
المسؤولية القانونية
جميع المعلومات للاستخدام
التعليمي فقط

الأستاذ الدكتور يوسف حسين

رئيس قسم التشريح والأنسجة والأجنة

كلية الطب - جامعة مؤتة - الأردن

دكتورة من جامعة كولونيا المانيا

Prof. Dr. Youssef Hussein Anatomy - YouTube

الواتس 00201224904207

Shoulder region

اليوتيوب د. يوسف حسين

Muscles of the shoulder region

Deltoid

Supraspinatus

Infraspinatus

Teres minor

Teres major

البيوتوب د. يوسف حسين

Deltoid Muscle

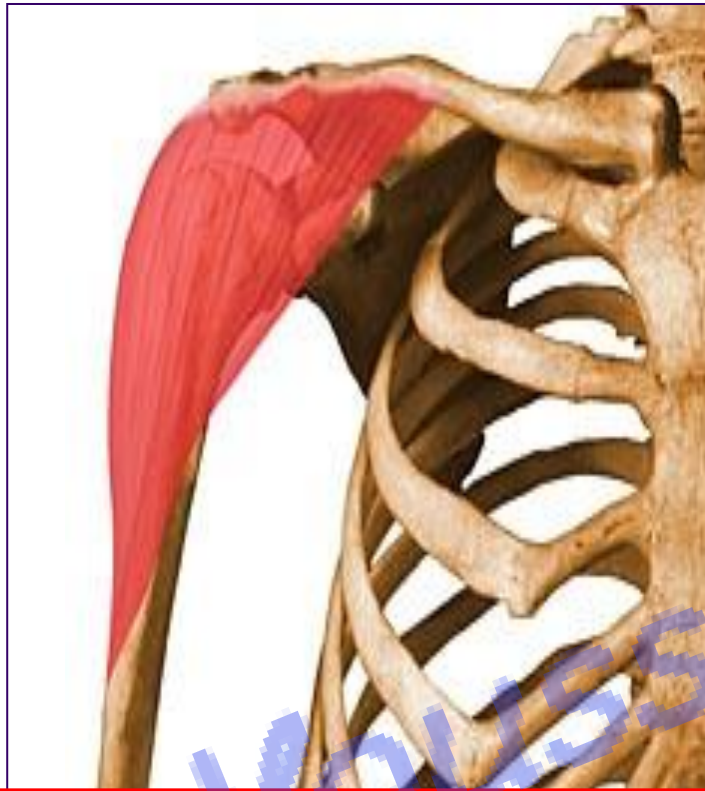اليوتيوب د. يوسف حسين

[Prof. Dr. Youssef Hussein Anatomy - YouTube](#)

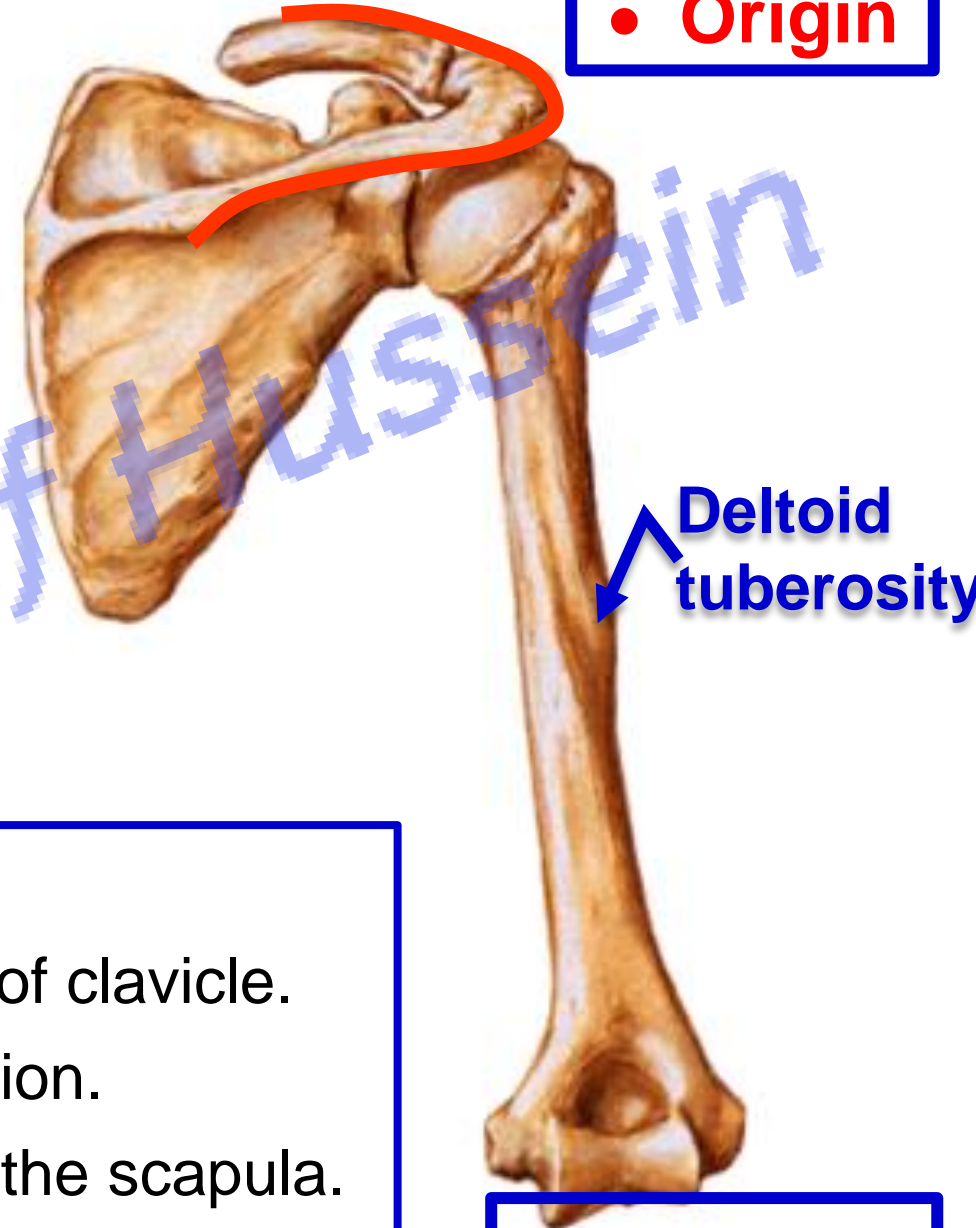
• Deltoid Muscle

اليوتيوب د. يوسف حسين

Prof. Dr. Youssef Hussein Anatomy - YouTube



• Origin



• Insertion

** Origin:

- 1- **Anterior fibers** from anterior border of lateral 1/3 of clavicle.
- 2- **Middle fibers** from the lateral border of the acromion.
- 3- **Posterior fibers** from the lower lip of the spine of the scapula.

** **Insertion:** into the deltoid tuberosity of the humerus.

• Deltoid Muscle

Prof. Dr. Youssef Hussein Anatomy - YouTube

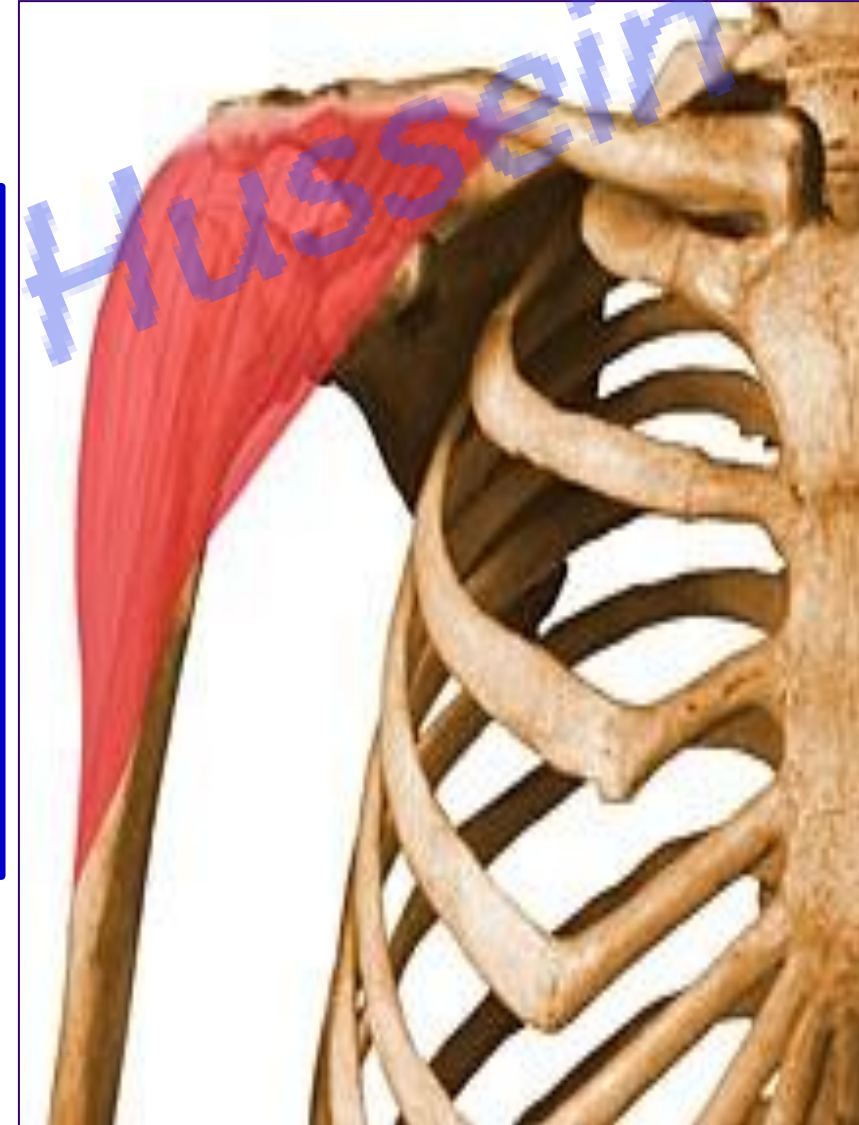اليوتيوب د. يوسف حسين

**** Nerve supply:** axillary nerve (C5&6).

**** Actions:**

- 1- Anterior fibers**, flexion, and medial rotation of arm.
- 2- Posterior fibers**, extension and lateral rotation of the arm.
- 3- Middle fibers** abduct the arm from 15 to 90 degree.
- 4- Round contour** of the shoulder.

Paralysis of deltoid muscle leading to **Flat shoulder** and **Loss of abduction**



** Structures under cover the deltoid

1- **Joint:** Shoulder joint.

2- **Nerve;** Axillary nerve.

3- **Vessels:** Anterior and posterior circumflex humeral vessels.

4- **Bursa:** Subdeltoid (Subacromical) bursa.

5- **Bones:** Coracoid process and upper part of shaft of the humerus.

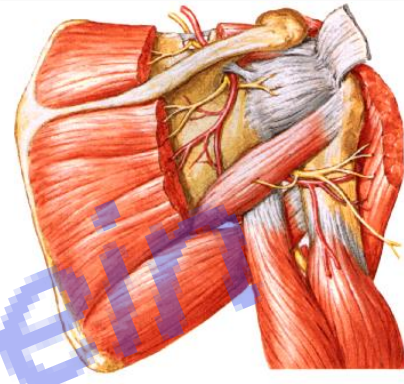
6- **Muscles:** Suprspinatous, infraspinatous, teres minor, coracobrachialis and biceps.

7- **Ligaments:** Coracoacromial, coracoclavicular and transverse humeral ligaments.

[Prof. Dr. Youssef Hussein Anatomy - YouTube](#)

* **Intramuscular injection into the deltoid muscle:** on its lateral aspect about 4 -5 cm below the acromion to avoid injury of axillary nerve, it is used for injection of small volume equal or less than 2 ml

اليوتيوب د. يوسف حسين



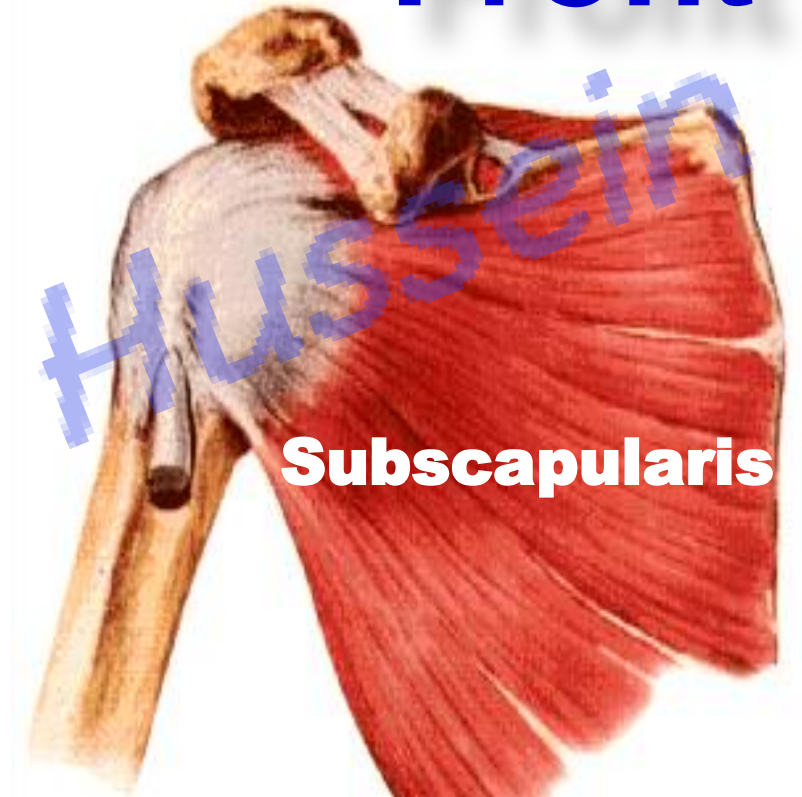
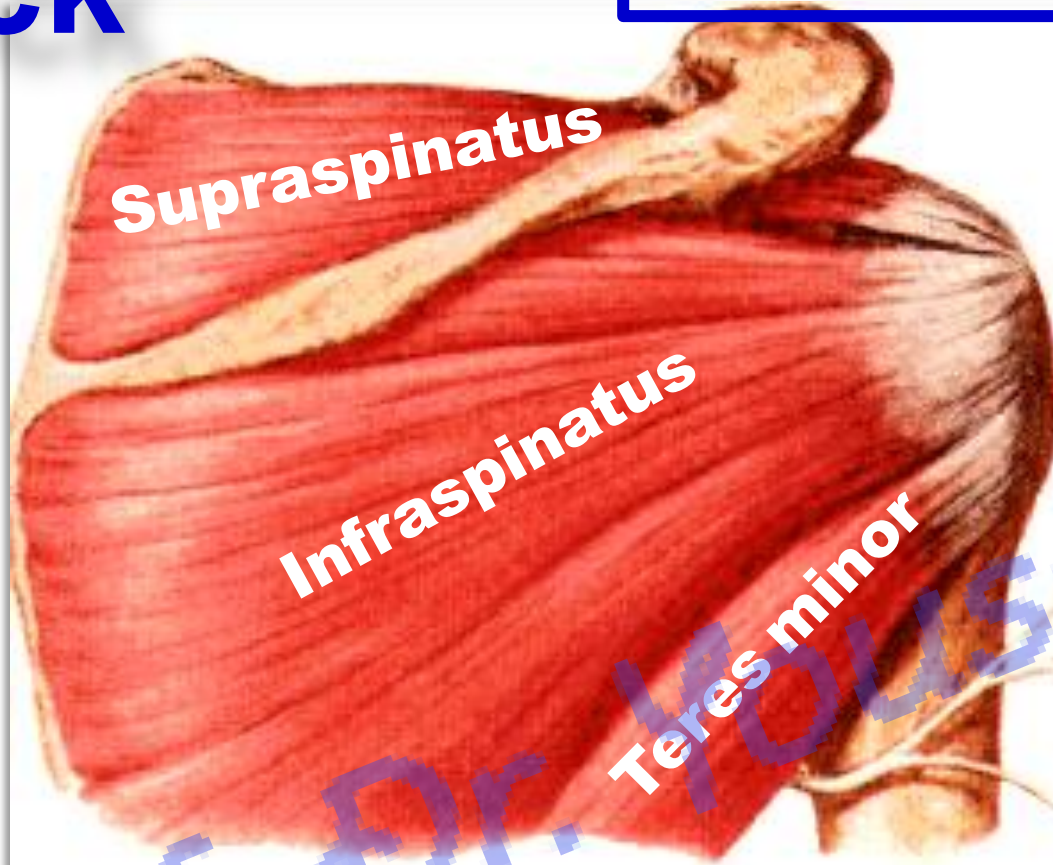Rotator cuff muscles

الـيوتـيـوب دـ. يـوسـف حـسـين

Back

• Rotator cuff Muscles

Front

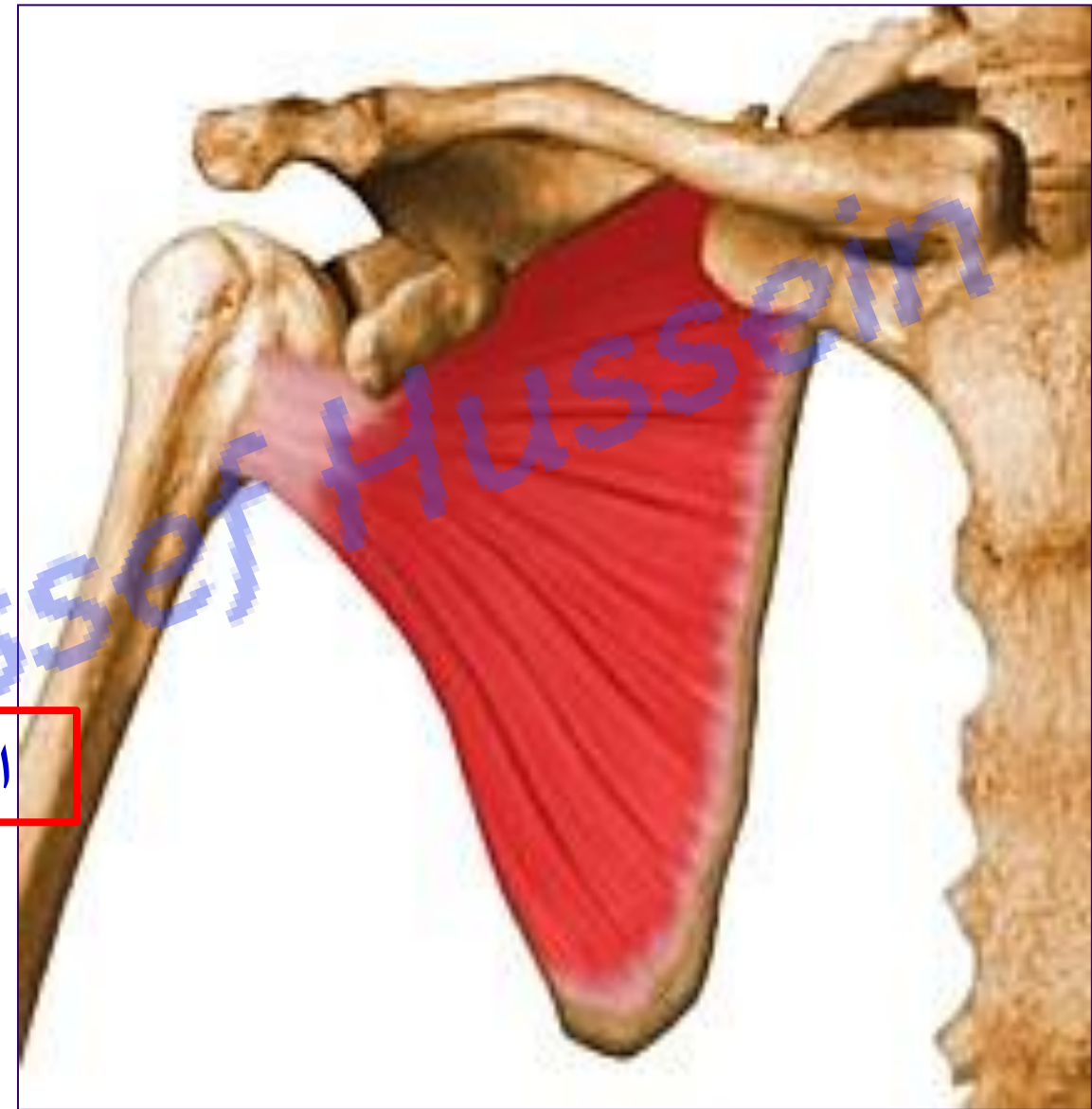


- These muscles play an important role in **stability of the shoulder joint** but the inferior aspect not supported by muscles. So dislocation of the shoulder is almost inferiorly.
- They keep humerus in contact with glenoid cavity during movements of shoulder joint.

❖ Subscapularis muscle

- ❖ **Origin:** medial 3/4 of subscapular fossa
- ❖ **Insertion:** lesser tuberosity
- ❖ **Nerve supply:** (double) upper & lower subscapular nerves (C5&6)
- ❖ **Actions:**
 - 1- **Adduction** and **medial** rotation of the arm.
 - 2- Fixation of the shoulder joint

اليوثيوب د. يوسف حسين



(Infront)

[Prof. Dr. Youssef Hussein Anatomy - YouTube](#)

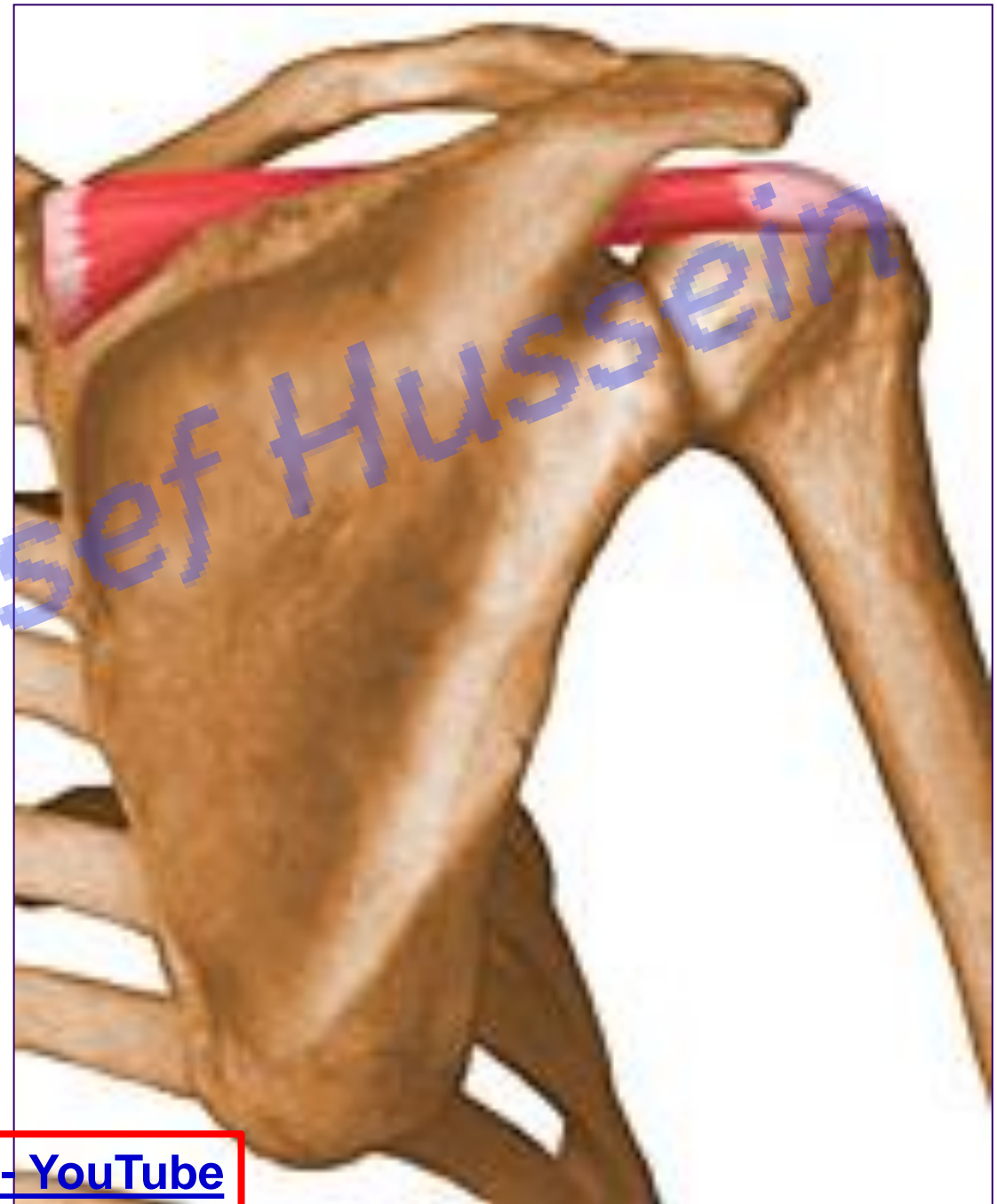❖ Supraspinatous muscle

- ❖ **Origin:** medial 3/4 of supraspinatous fossa
- ❖ **Insertion:** top of the greater tuberosity
- ❖ **Nerve supply:** suprascapular nerve (C5&6)
- ❖ **Actions:**
 - 1- **Abduction** from 0 to 15 degrees.
 - 2- Fixation of the shoulder joint

أيوبيوب د. يوسف حسين

(above)

[Prof. Dr. Youssef Hussein Anatomy - YouTube](#)



**** Applied anatomy**

- ❖ **Paralysis of the Supraspinatus**, the patient can abduct his arm manually or by lateral flexion of the trunk.
- ❖ Its tendon passes **deep to coracoacromial arch** and separated from it by subacromial bursa.
- ❖ **Acute rupture of the tendon of supraspinatous** leading to severe pain in the shoulder during abduction.
- ❖ **Chronic degeneration of the tendon of supraspinatous** leading to gradual increase stiffness of the shoulder joint (it appear as powder like deposits and can be seen by x-ray).

اليوثيوب د. يوسف حسين

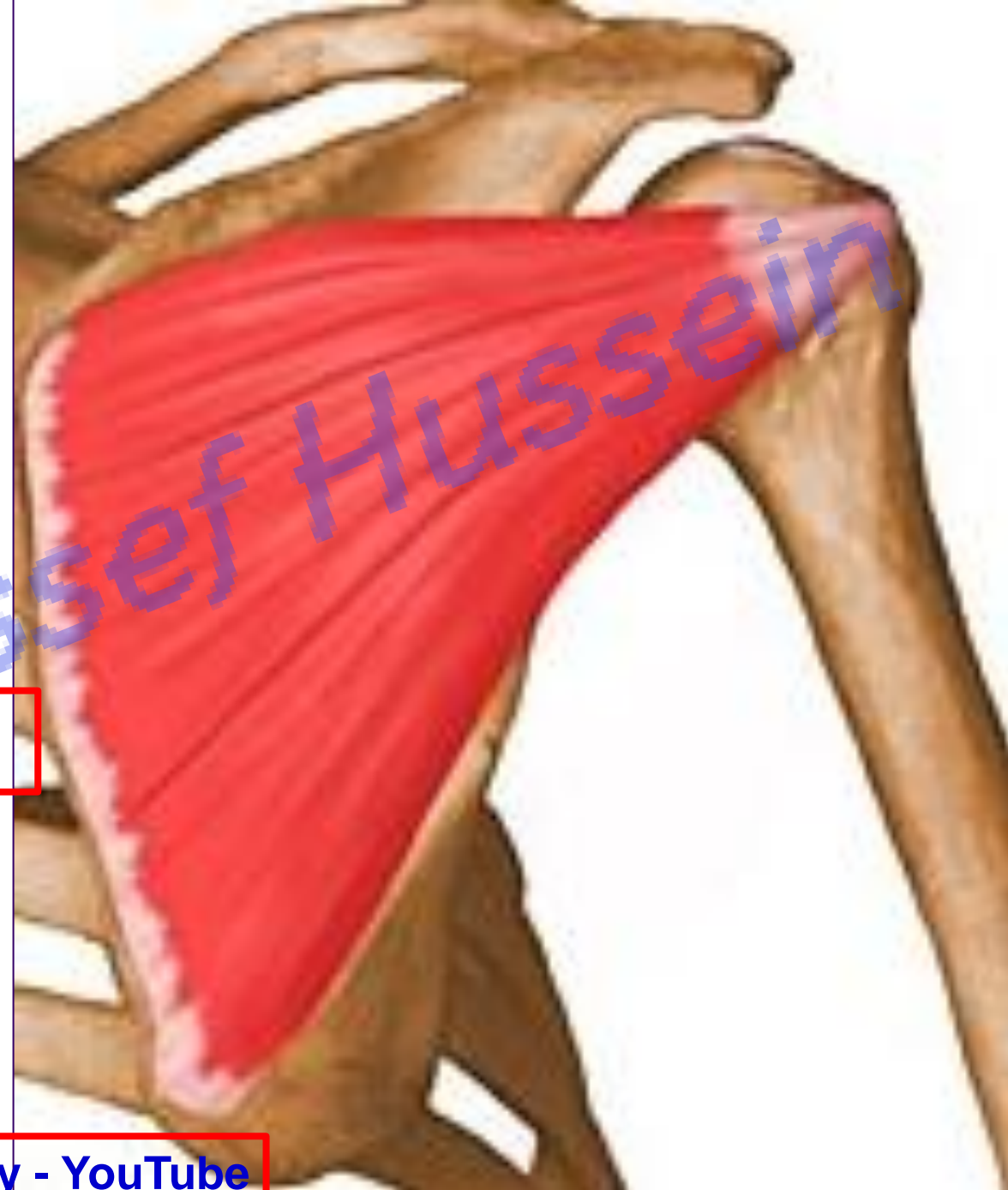❖ **Infraspinatous muscle**

- ❖ **Origin:** medial 3/4 of infraspinatous fossa
- ❖ **Insertion:** middle impression of the greater tuberosity
- ❖ **Nerve supply:** suprascapular nerve (C5&6)
- ❖ **Actions:**
 - 1- **Adduction** and **lateral** rotation of the arm.
 - 2- Fixation of the shoulder joint

اليوثيوب د. يوسف حسين

(**behind**)

[Prof. Dr. Youssef Hussein Anatomy - YouTube](#)

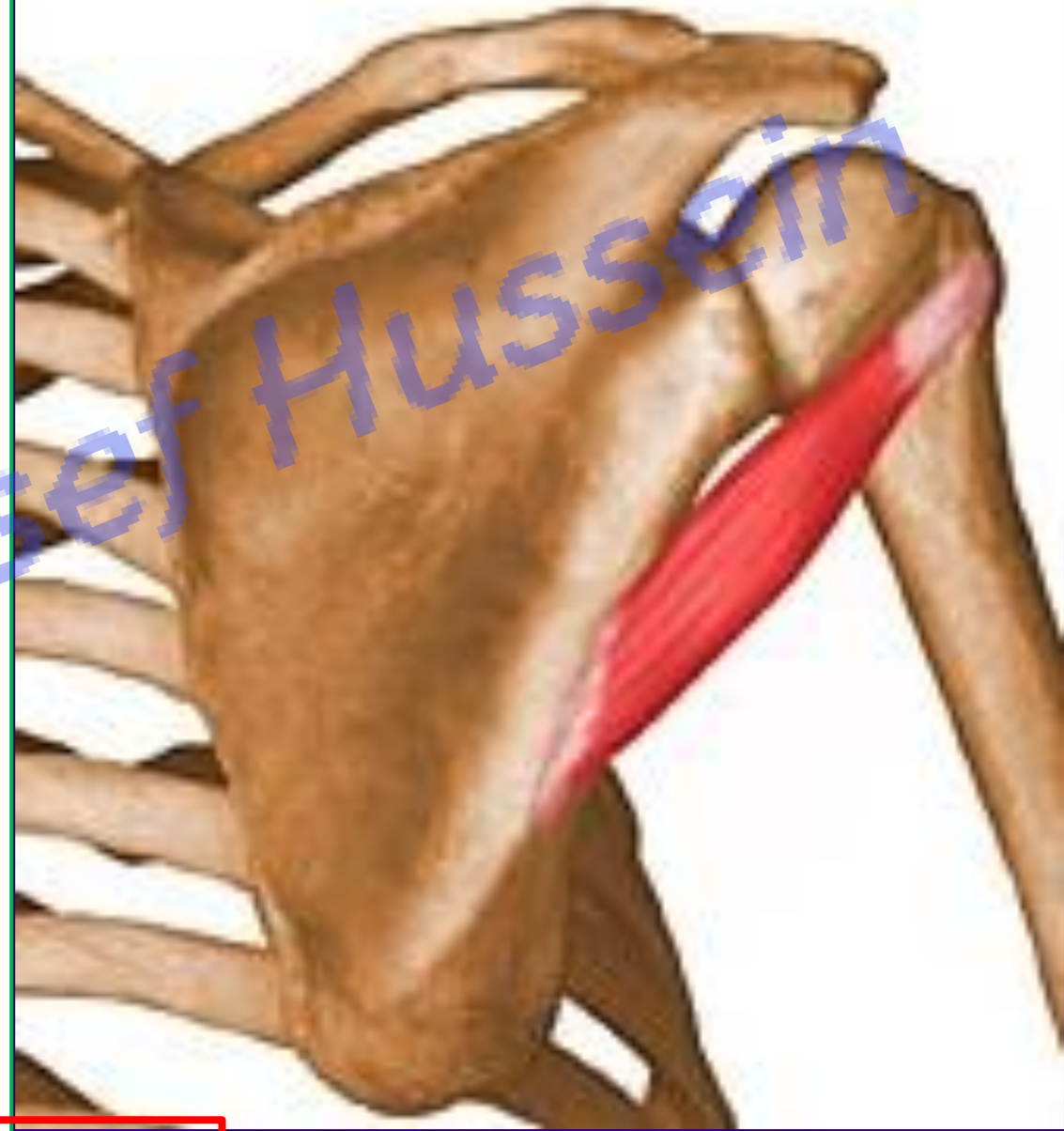

❖ Teres minor muscle

- ❖ **Origin:** upper 2/3 of the dorsal aspect of the lateral border of the scapula
- ❖ **Insertion:** Lower impression of the greater tuberosity
- ❖ **Nerve supply:** axillary nerve (C5&6)
- ❖ **Actions:** اليوثيوب د. يوسف حسين
 - 1- **Adduction** and **lateral** rotation of the arm.
 - 2- Fixation of the shoulder joint

(**behind**)

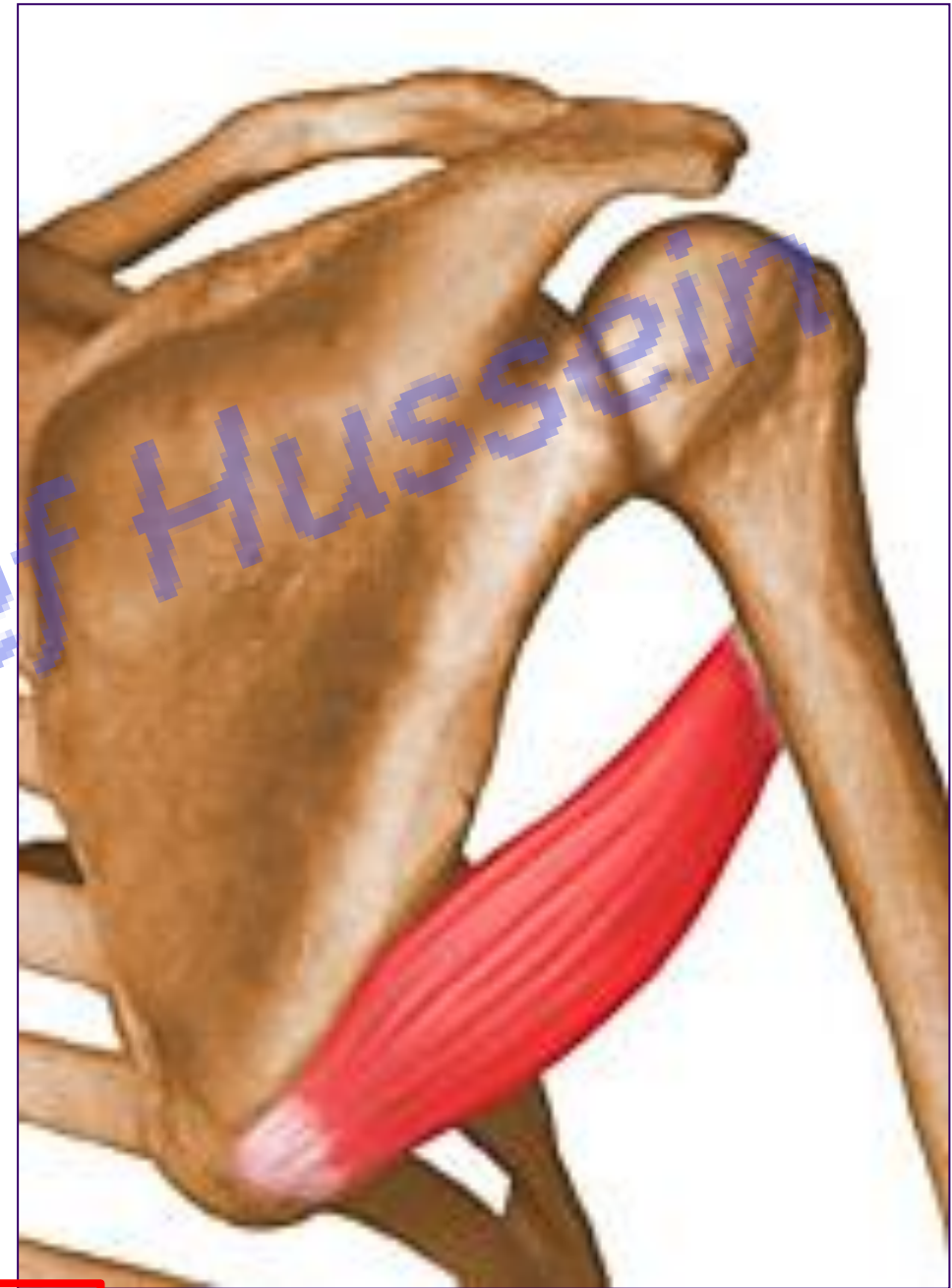[Prof. Dr. Youssef Hussein Anatomy - YouTube](#)



❖ Teres major muscle

- ❖ **Origin:** lower 1/3 of the dorsal aspect of the lateral border of the scapula (large ovale area)
- ❖ **Insertion:** medial lip of the bicipital groove
- ❖ **Nerve supply:** lower subscapular nerve (C5&6)
- ❖ **Actions:**
 - **Adduction** and **medial** rotation of arm.

اليوثيوب د. يوسف حسين





اليوطيوب د. يوسف حسين

Intermuscular
spaces of
shoulder region

[Prof. Dr. Youssef Hussein Anatomy - YouTube](#)

- **Intermuscular Spaces**

1- Upper (Medial) triangular space: boundaries:

- **Superiorly:** Teres minor and Subscapularis.
- Inferiorly: Teres major.
- **Laterally:** Long head of triceps.

** It transmits circumflex scapular artery.

2- Quadrangular space: boundaries:

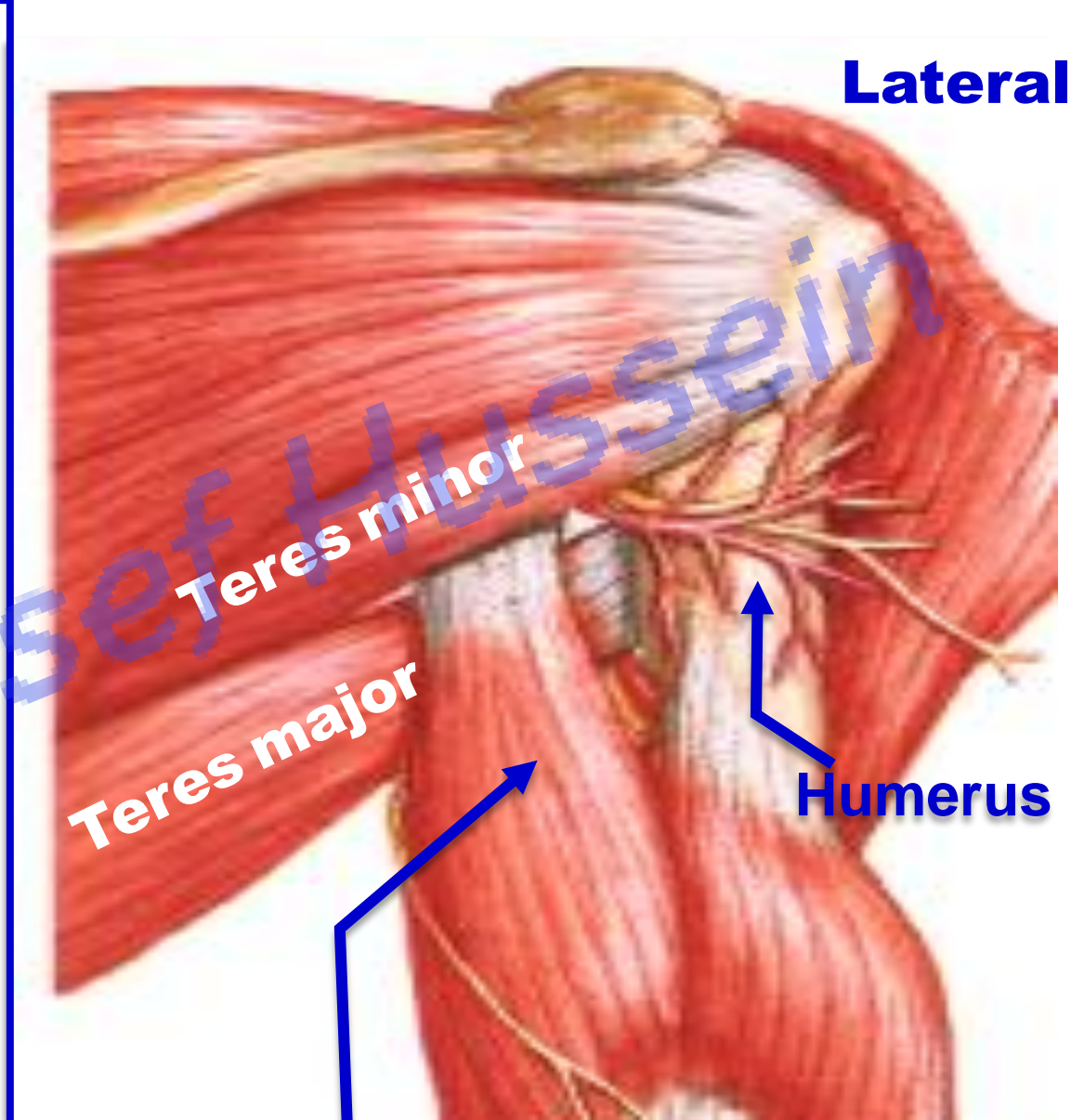
- **Superiorly:** Teres minor, and subscapularis.
- Inferiorly: Teres major.
- **Medially:** Long head of triceps.
- **Laterally:** Surgical neck of the humerus.

** It transmits axillary nerve and posterior circumflex humeral artery.

3- Lower (Lateral) triangular space: boundaries:

- **Superiorly:** Teres major.
- Medially: Long head of triceps.
- **Laterally:** Shaft of the humerus.

** It transmits radial nerve and profunda brachii vessels.



Lateral

Long head of triceps

https://www.youtube.com/channel/UCVSNqbibj9UWYaJdd_cn0PQ

يُمنع أخذ السلايدات بدون
إذن المحرر واي اجراء
يخالف ذلك يقع تحت
طائلة المسؤولية القانونية

اليوتيوب د. يوسف حسين



Thank You

Questions

Prof. Dr. Youssef Hussein Anatomy - YouTube