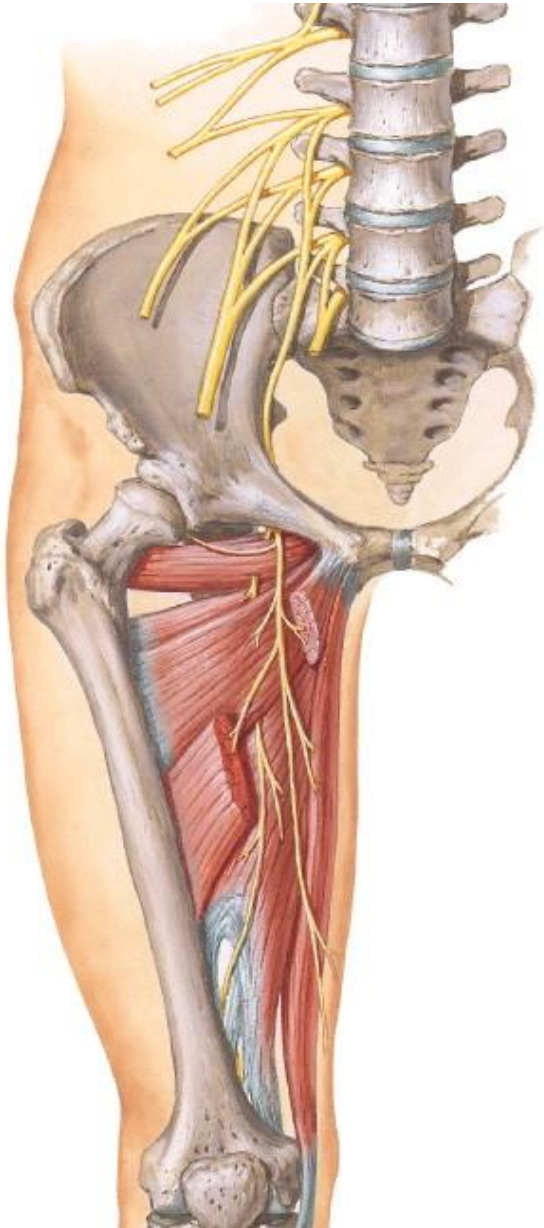


MEDIAL COMPARTMENT OF THE THIGH



BY

DR ABULMAATY MOHAMED
ASSISTANT PROFESSOR
ANATOMY & EMBRYOLOGY
MUTAH UNIVERSITY

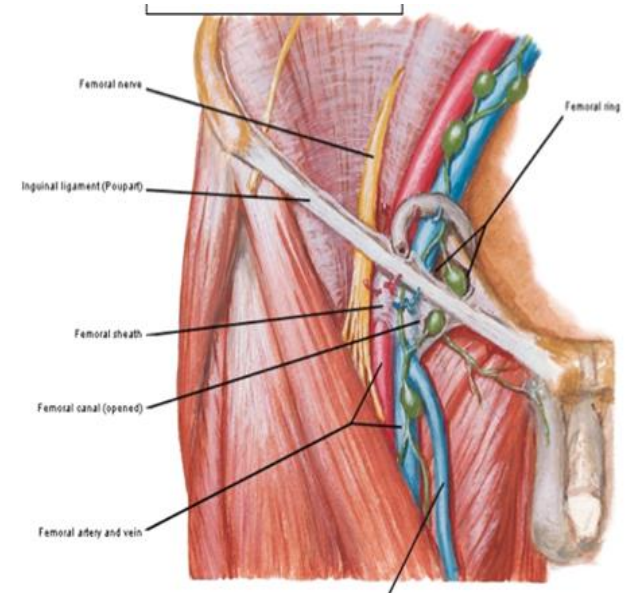
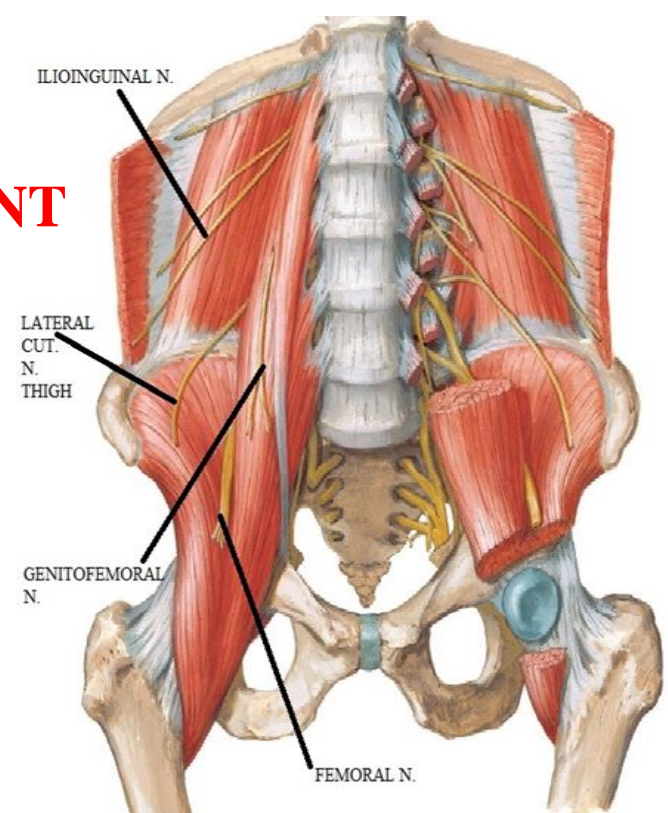
FEMORAL NERVE

NERVE OF THE ANTERIOR COMPARTMENT

O.: inside psoas major as the largest branch from lumbar plexus (L2, 3, 4 nerves)

C & R:

- emerges from lateral border of psoas major
- runs () psoas & iliacus (behind fascia iliaca)
- enter thigh deep to inguinal lig lateral to femoral artery
- pass in femoral Δ
- Lateral to femoral art
- Outside femoral sheath
- end 4 cm below inguinal lig
by dividing into ant & post divisions



FEMORAL NERVE

NERVE OF THE ANTERIOR COMPARTMENT

Branches:

A-Muscular:-

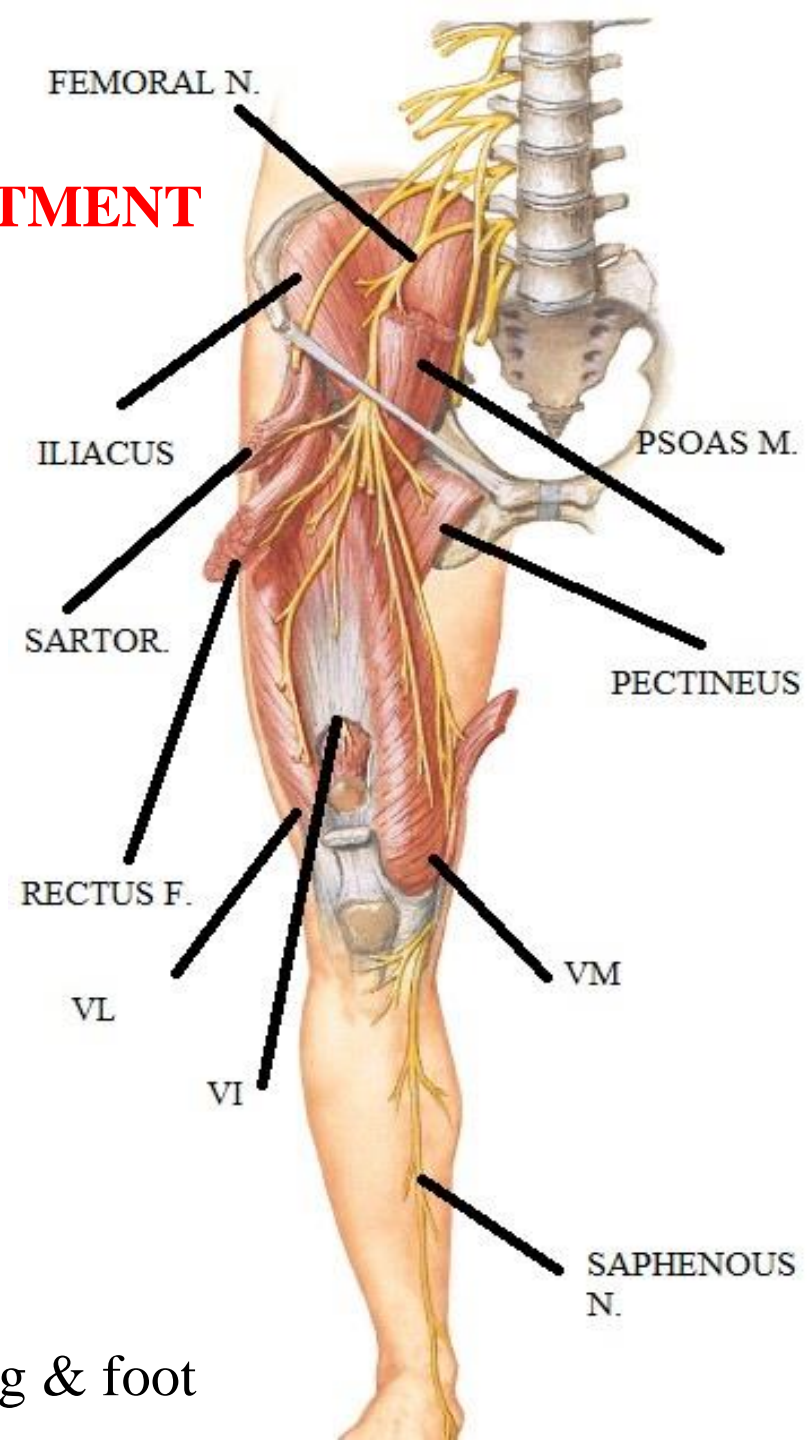
- 1-iliacus (in abdomen)
- 2- pectineus
- 3-Sartorius
- 4-heads of quadriceps femoris

B-articular:-

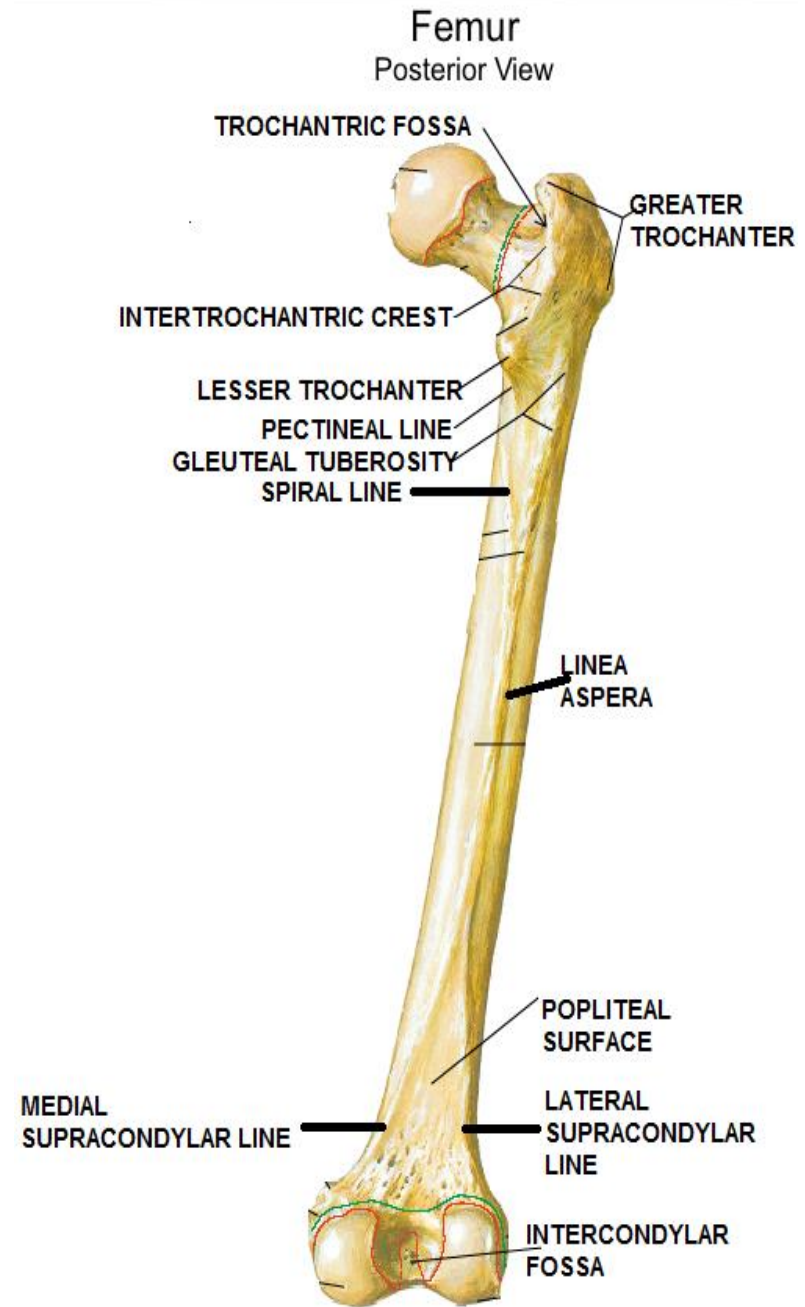
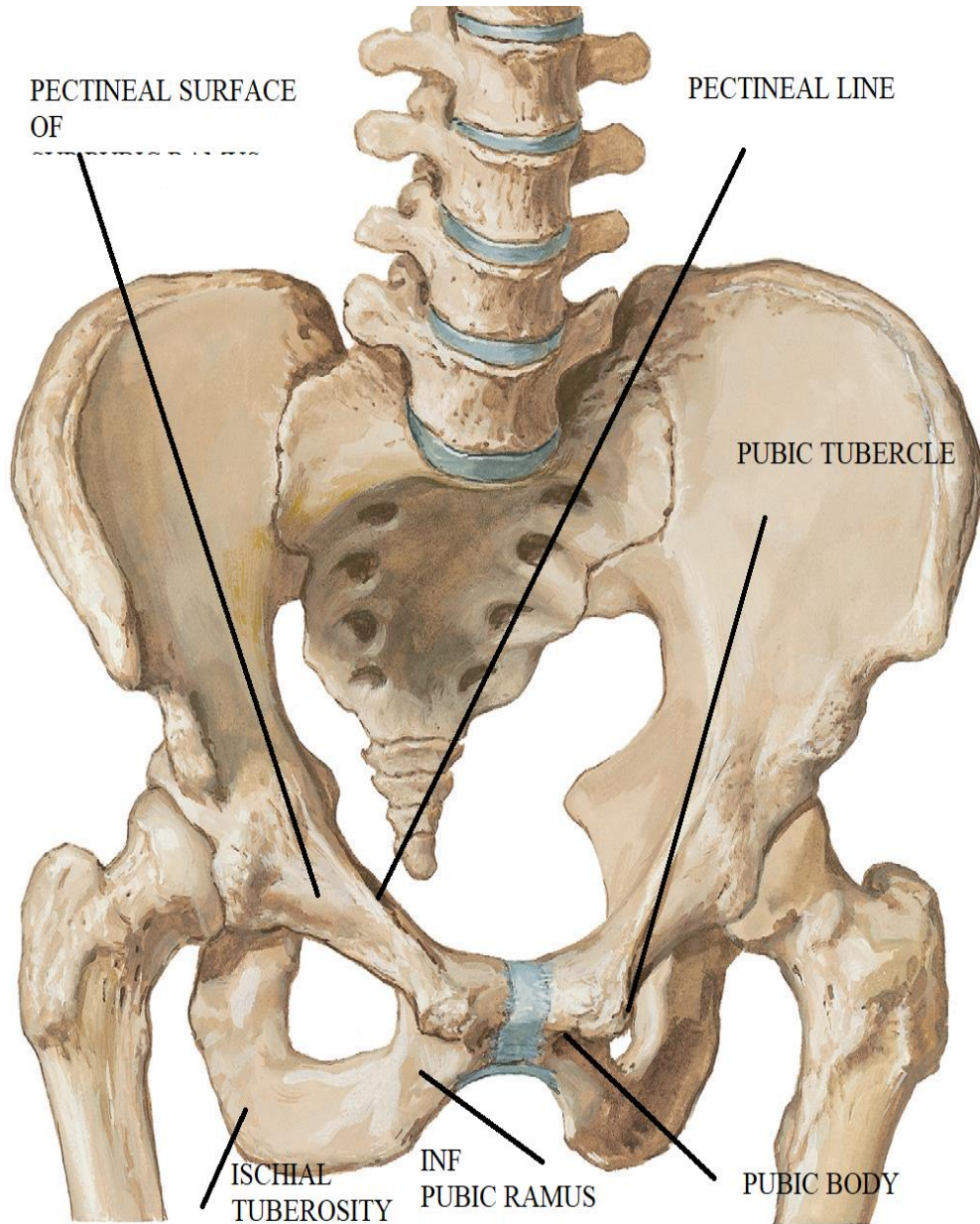
- 1-hip : through n. to rectus femoris
- 2-knee : through nerves to vasti

C-cutaneous:-

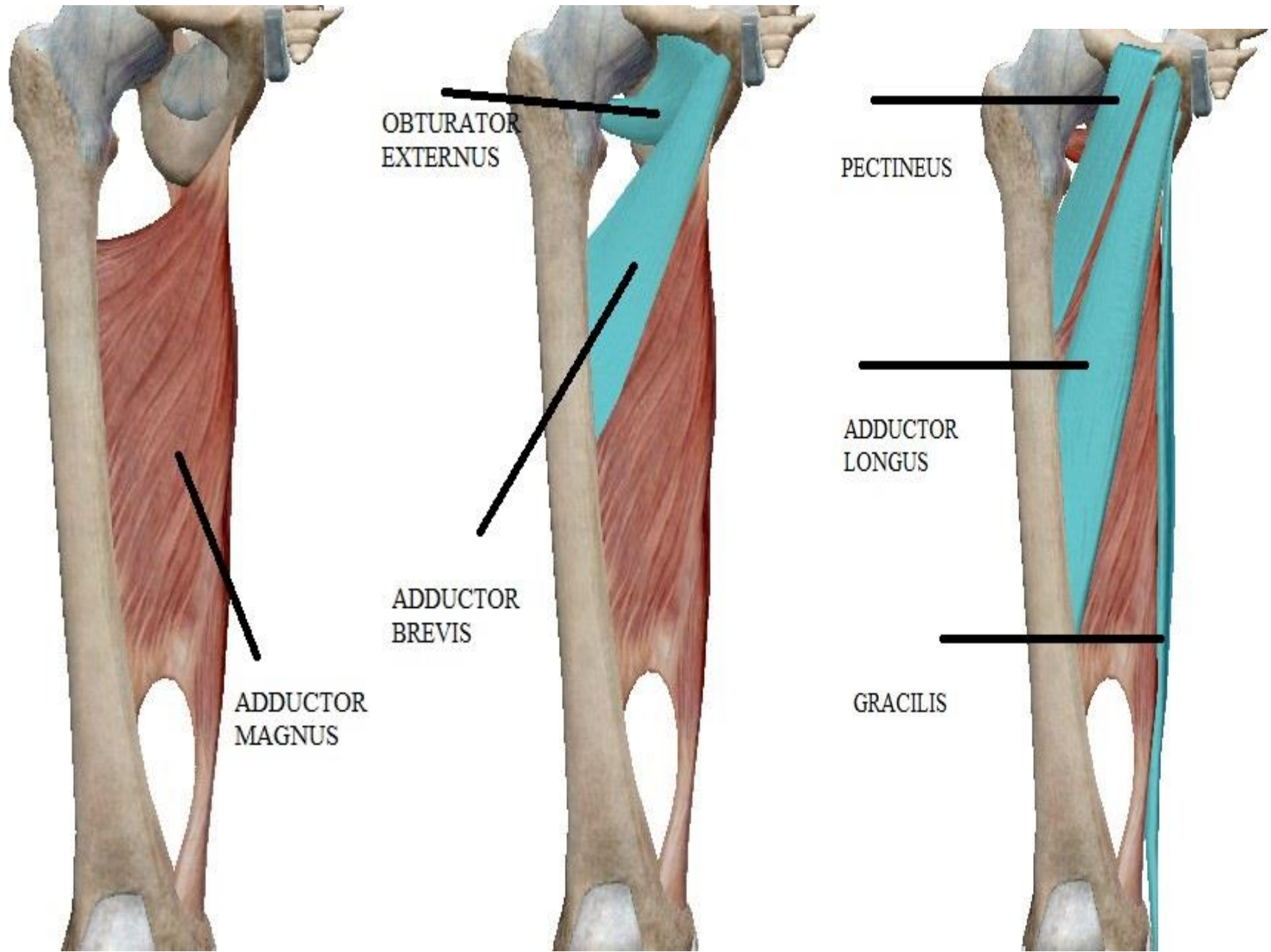
- 1-Intermediate cu n. of thigh :
- 2-medial cu n. of thigh :
- 3-Saphenous n.: longest cutaneous n. in body
supply medial side of the leg & foot



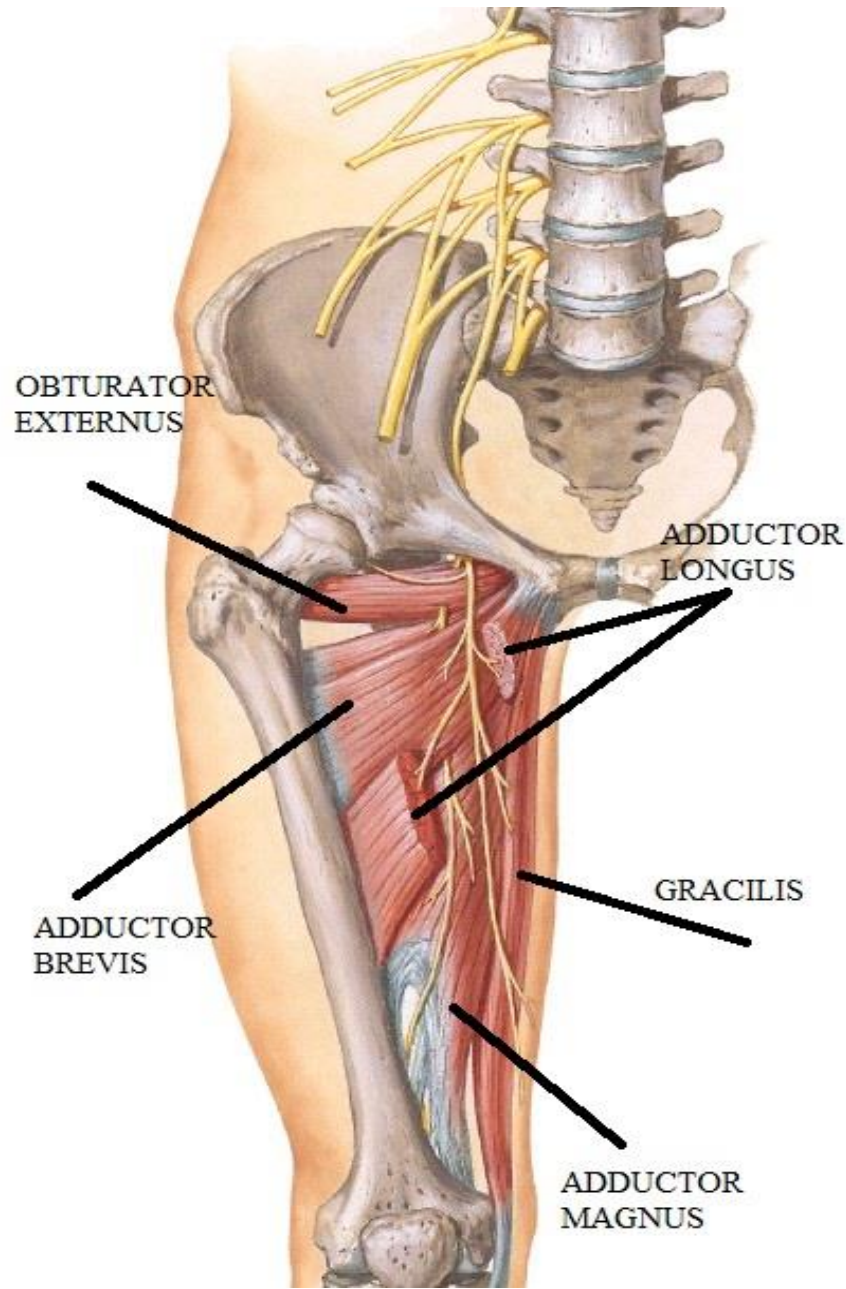
SKELETON



MUSCLES OF THE MEDIAL COMPART.



MUSCLES OF THE MEDIAL COMPART.



MUSCLES OF THE MEDIAL COMPART.

ADDUCTOR MAGNUS

Origin:-

Ischial(hamstring) part: Lateral part of lower area of the ischial tuberosity

Pubic (adductor) part: ischial ramus & inferior pubic ramus

Insertion:-

Ischial part: adductor tubercle

Pubic part:- Gluteal tuberosity
linea aspera
medial supracondylar line

Action:-


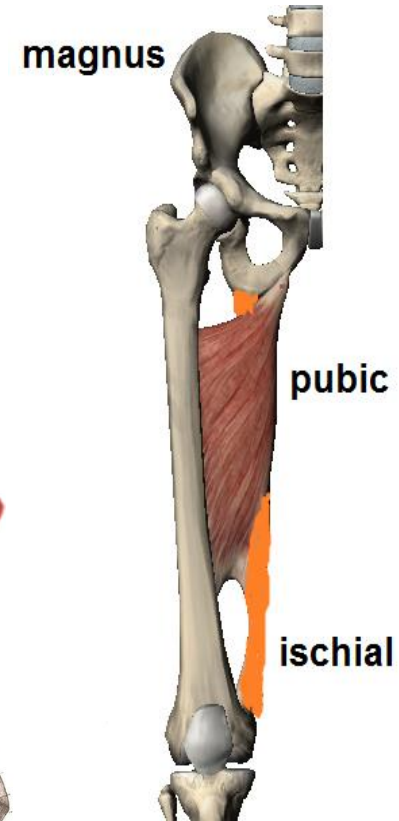
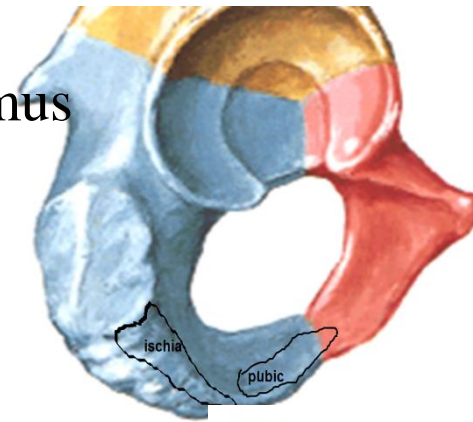
Pubic part:- adduction of thigh

Ischial part: extension of thigh

N.S.:-

Pubic part:- Obturator nerve

Ischial part: sciatic nerve



MUSCLES OF THE MEDIAL COMPART.

OBTURATOR EXTERNUS

Origin:-

Outer side of obturator membrane
& margin of obturator foramen

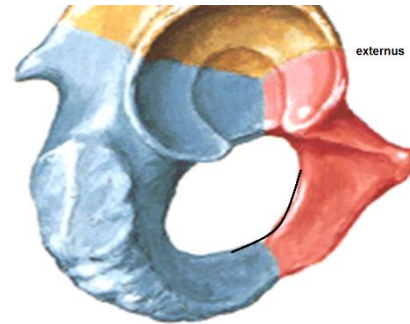
Insertion:-

trochanteric fossa

Action:-

Lateral rotation of thigh

N.S.:- Obturator nerve



externus

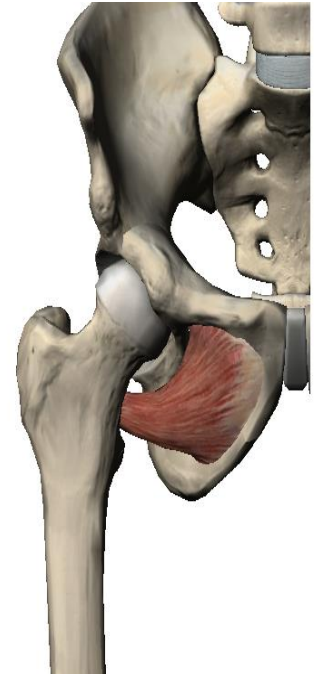
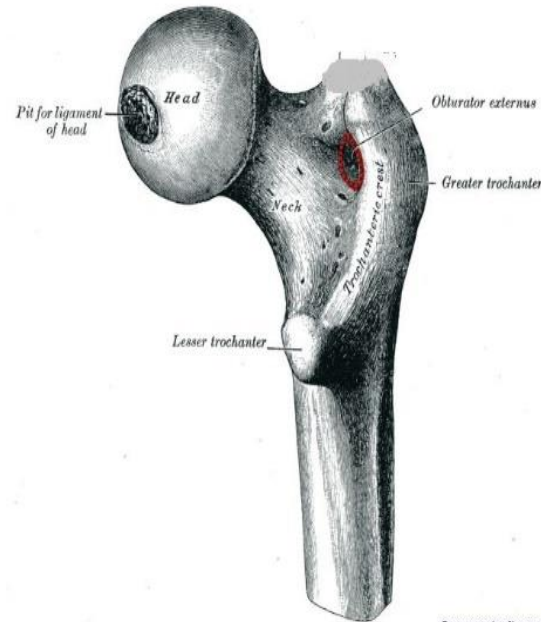


FIG. 455.—The upper part of the right femur. Viewed from behind.



MUSCLES OF THE MEDIAL COMPART.

ADDUCTOR BREVIS

Origin:-

Lateral part of front of inferior pubic ramus

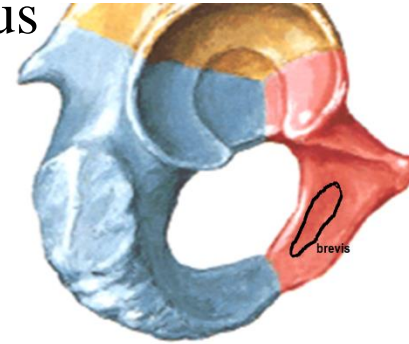
Insertion:-

Lower part of the pectineal line
& linea aspera

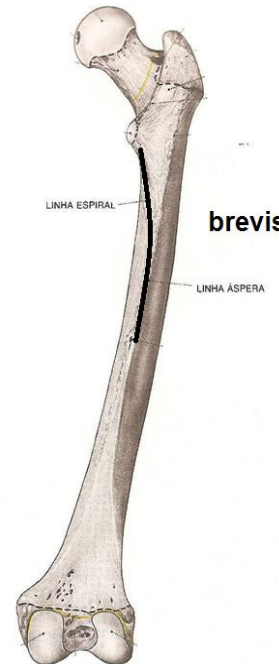
Action:-

adduction & flexion of thigh

N.S.:- Obturator nerve



brevis



MUSCLES OF THE MEDIAL COMPART.

PECTINEUS

Origin:-

pectineal line & surface of superior pubic ramus

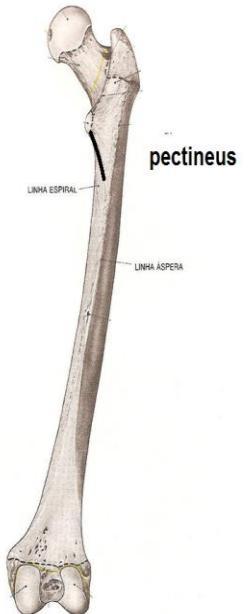
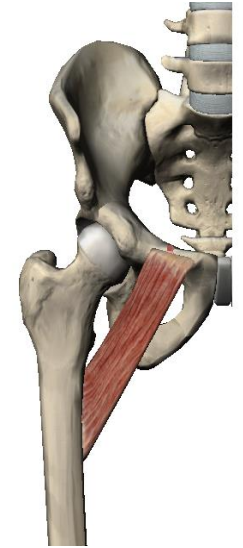
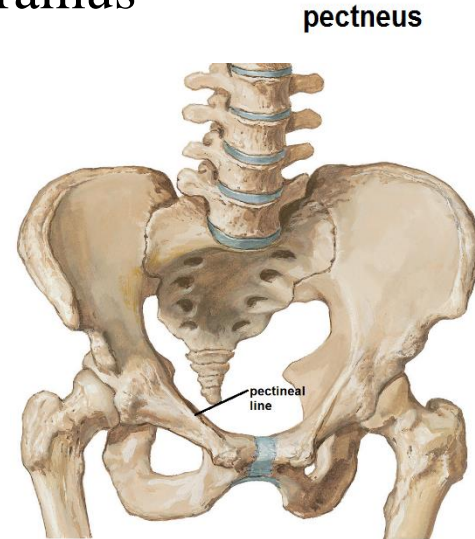
Insertion:-

Upper part of pectineal line of femur

Action:-

adduction & flexion of thigh

N.S.:- Obturator nerve
femoral nerve



MUSCLES OF THE MEDIAL COMPART.

ADDUCTOR LONGUS

Origin:-

front of body of pubis below pubic tubercle

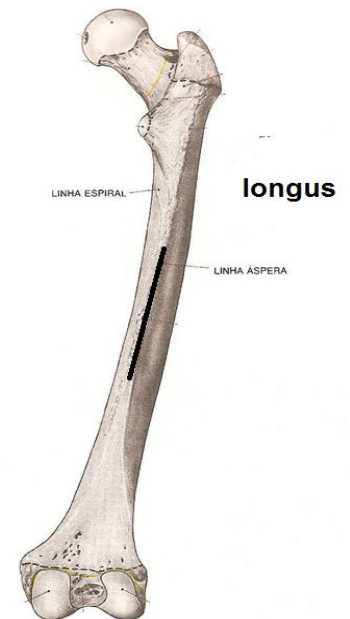
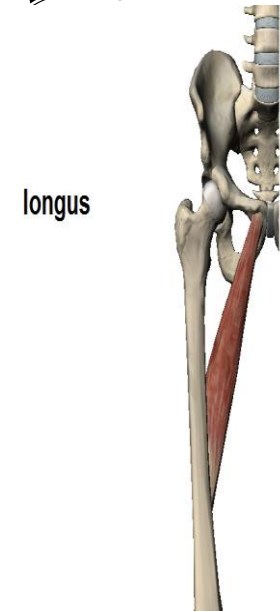
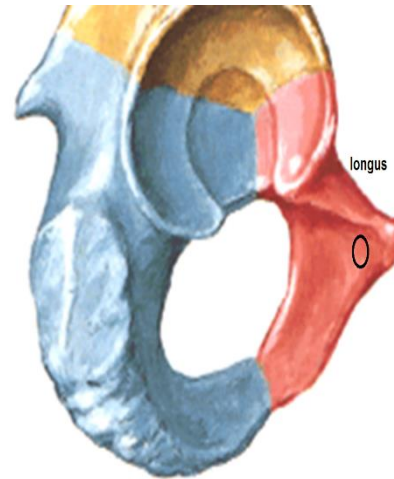
Insertion:-

linea aspera

Action:-

adduction & flexion of thigh

N.S.:- Obturator nerve



MUSCLES OF THE MEDIAL COMPART.

GRACILIS

Origin:-

medial part of front of inferior pubic ramus

Insertion:-

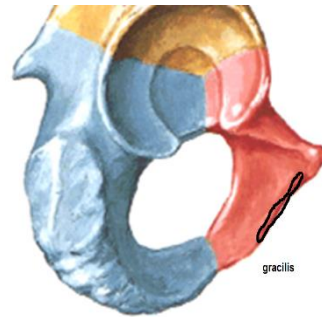
upper part of medial surface
of tibia behind Sartorius

Action:-

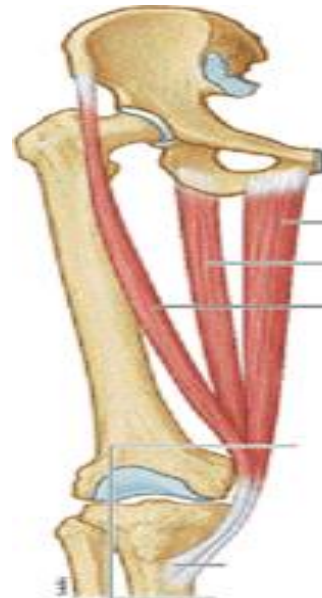
adduction of thigh & flexion of knee

guy rope??

N.S.:- Obturator nerve



gracilis



(A) Anterior view



OBTURATOR NERVE

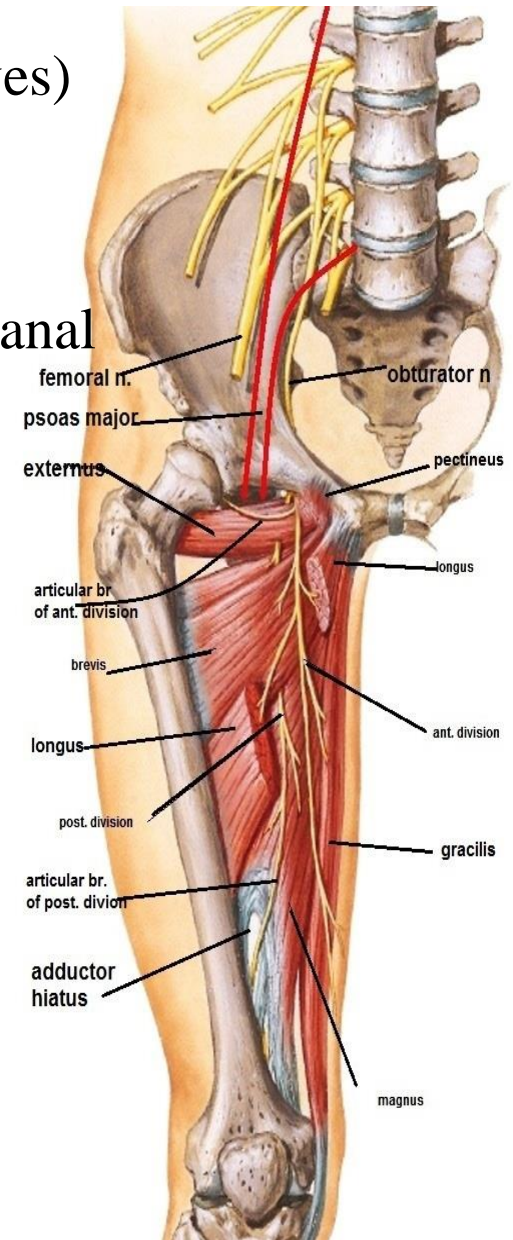
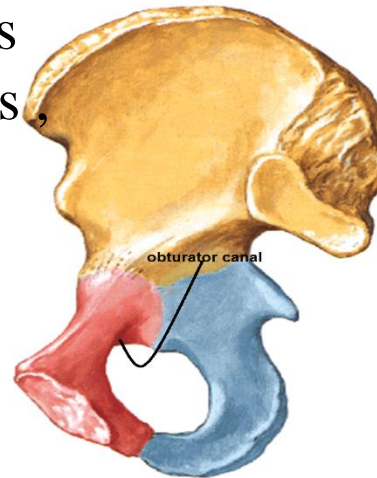
NERVE OF THE MEDIAL COMPARTMENT

O.: inside psoas major from lumbar plexus (L2, 3, 4 nerves)

C & r:

- emerges from medial border of psoas major
- runs forwards on side wall of pelvis to reach obturator canal
- leave pelvis through obturator canal
- at ant. end of canal → ant & post. divisions
- **ant. division** descend

behind pectineus & adductor longus
in front obturator ext. , adductor brevis
post. division pierce obturator externus,
then behind adductor brevis
in front of adductor magnus



OBTURATOR NERVE

NERVE OF THE MEDIAL COMPARTMENT

branches :

1-ant. division

muscular to

pectineus, adductor longus, gracilis
adductor brevis

articular to hip joint

cutaneous to medial side of thigh

2-post. division

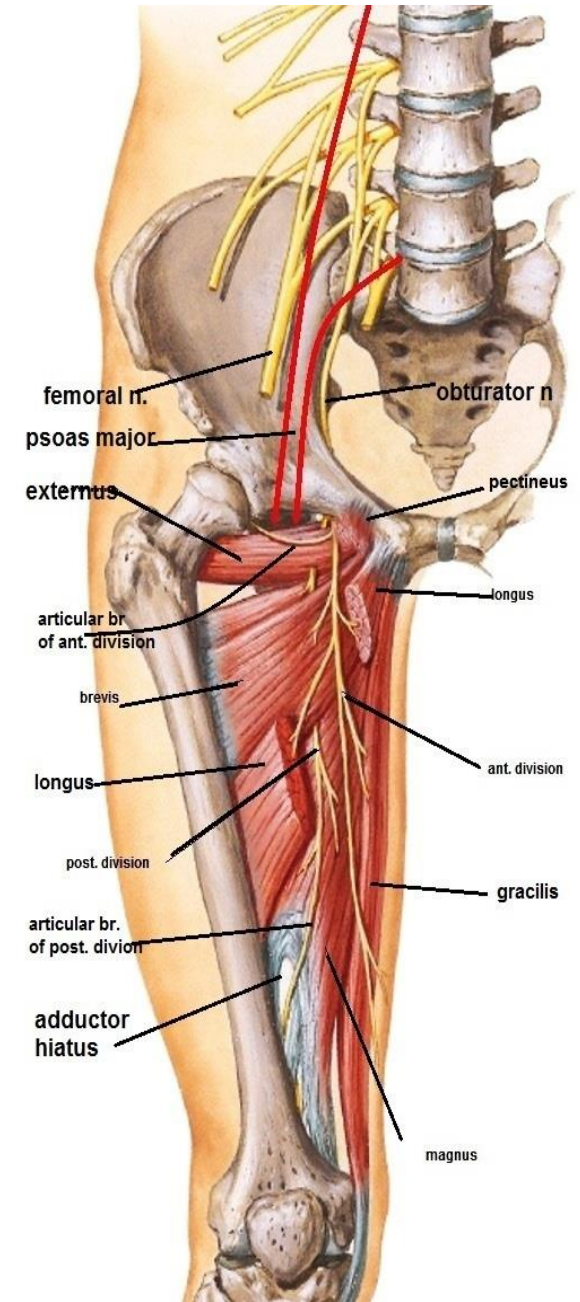
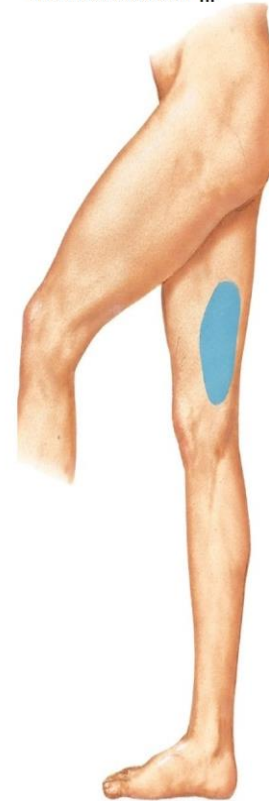muscular to

obturator externus
adductor magnus

articular br. to knee joint

(it is the terminal branch that pass through
adductor hiatus to knee joint)

area supplied by
cut. br. of obturator n.



THANQ

