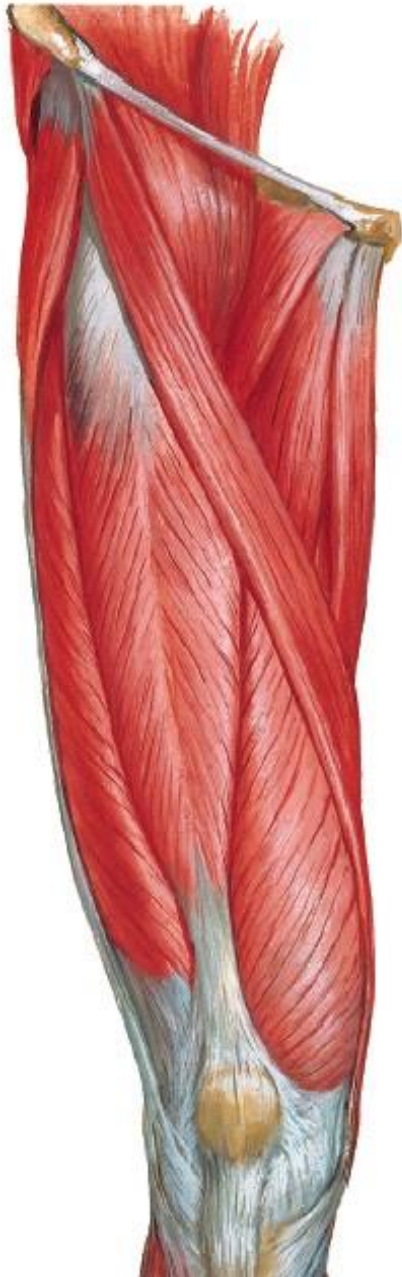

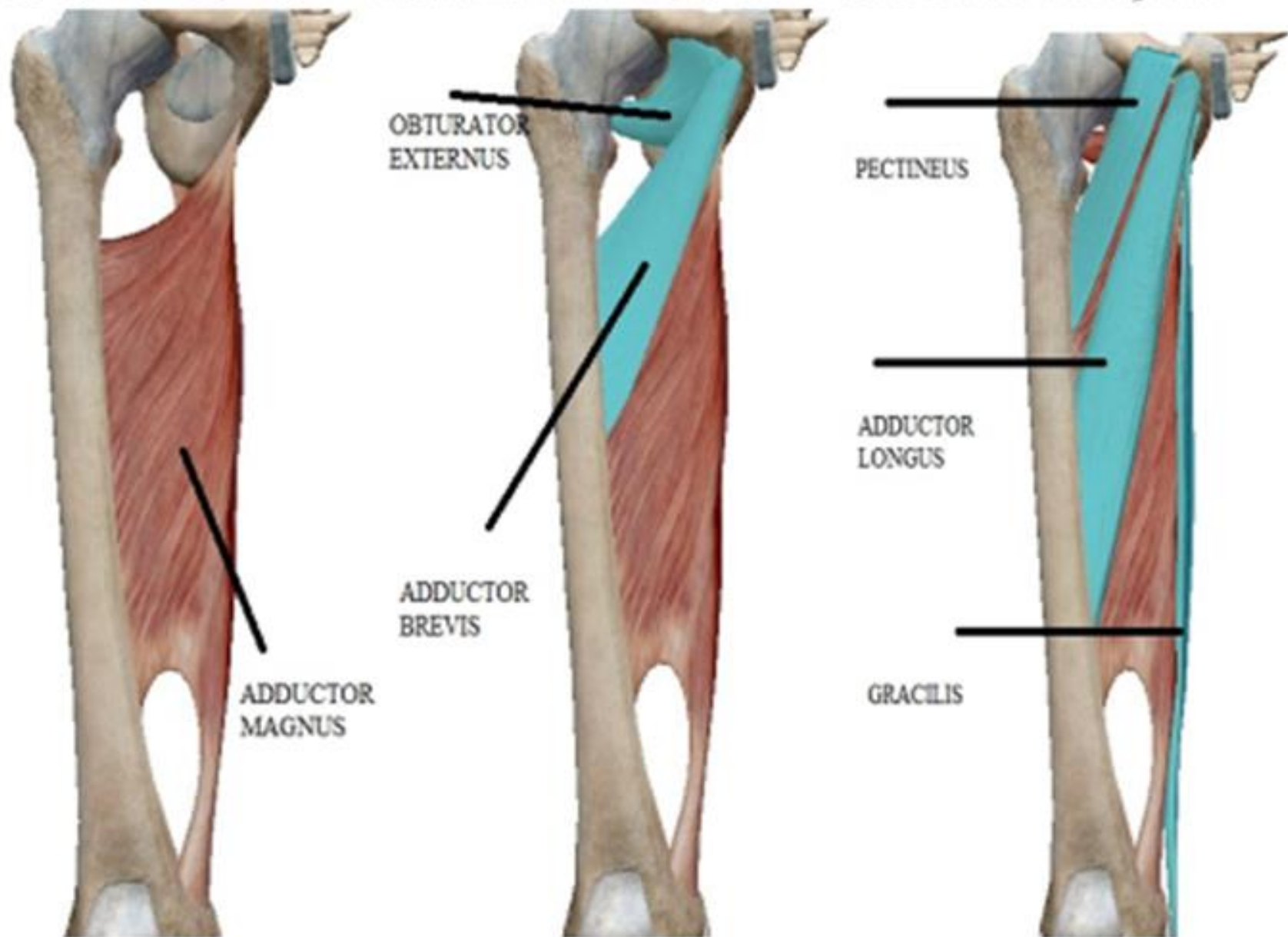
# FEMORAL TRIANGLE & ADDUCTOR CANAL

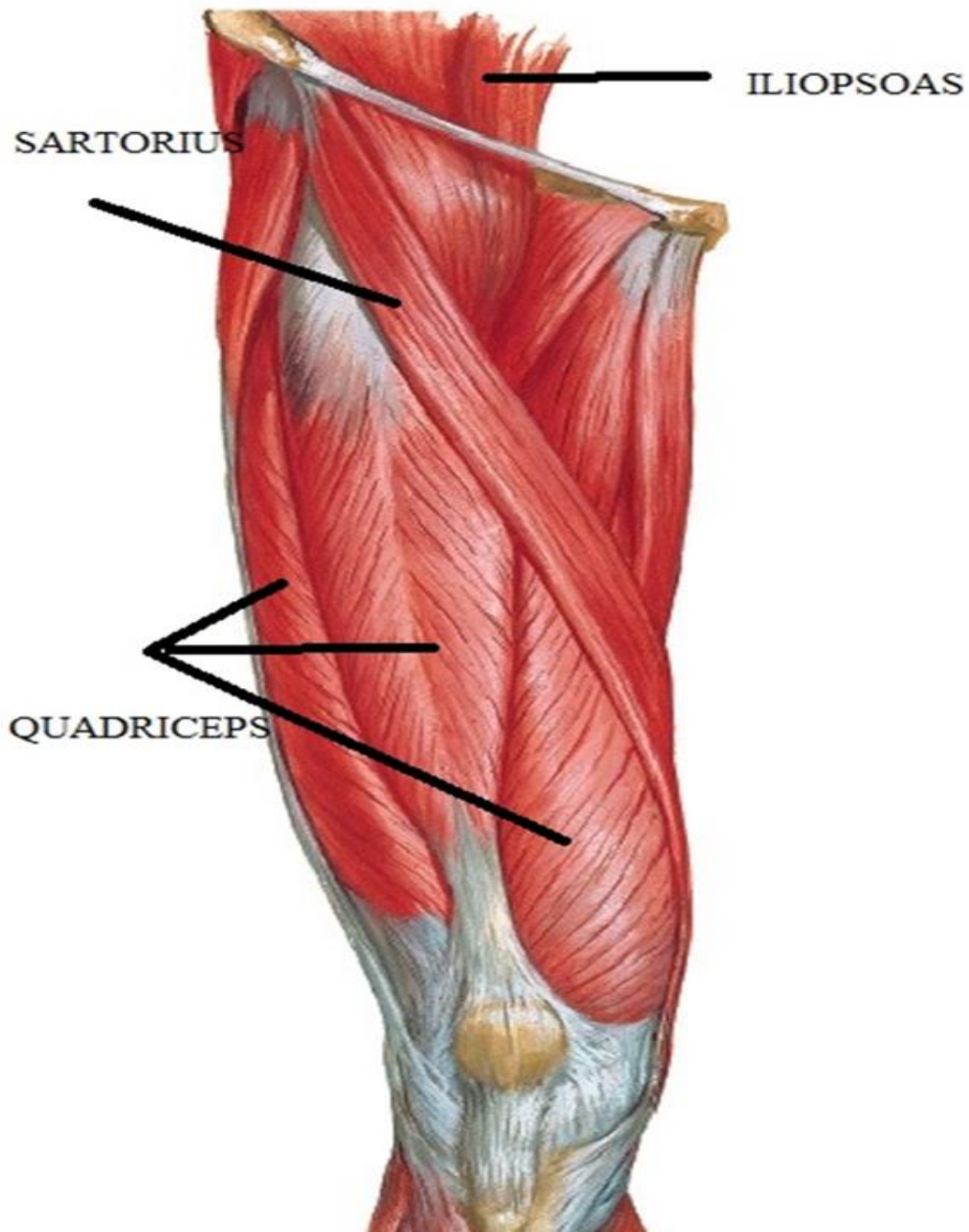


BY

DR ABULMAATY MOHAMED  
ASSISTANT PROFESSOR  
ANATOMY & EMBRYOLOGY  
MUTAH UNIVERSITY

# MUSCLES OF THE MEDIAL COMPART.





# FEMORAL TRIANGLE

## DEF. & SITE:

Tissue space in upper 1 /3 of thigh just below inguinal lig.

## BOUNDARIES :

**Base :** inguinal lig.

**Lateral:** medial border of sartorius

**Medial:** medial border of adductor longus

**Apex :** overlapping of sartorius on adductor longus

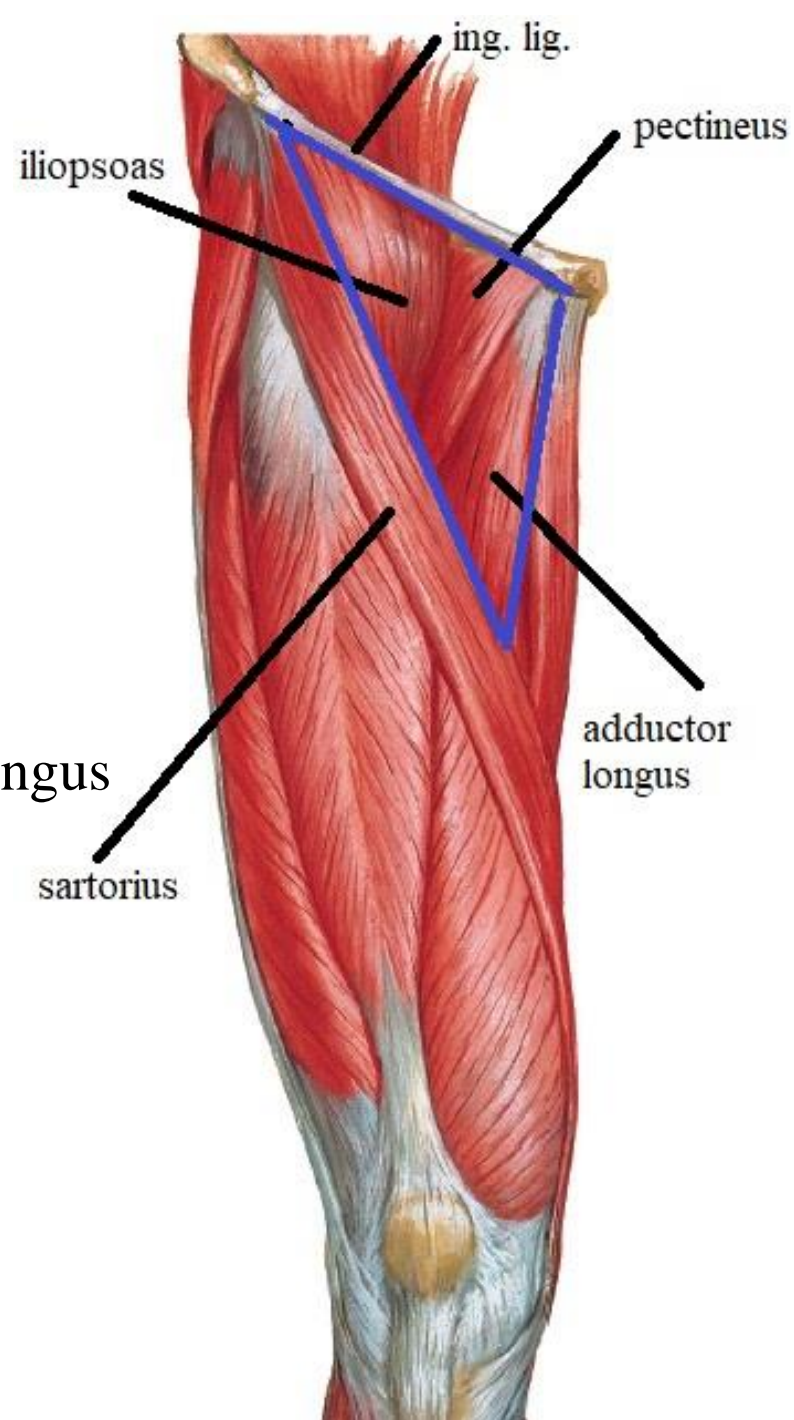
where it continues with adductor canal below

**Floor :**

-ilio psoas

-pectineus

-adductor longus



# FEMORAL TRIANGLE

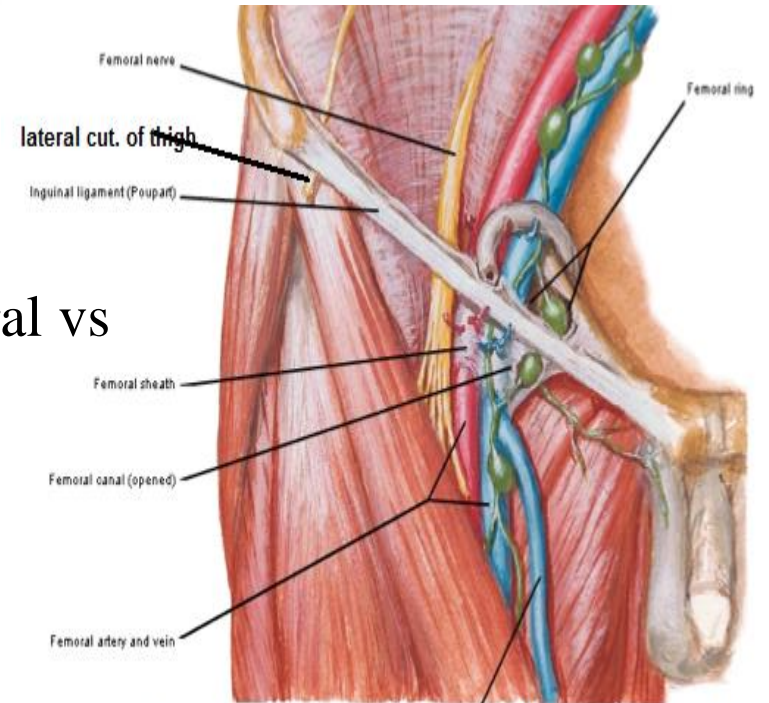
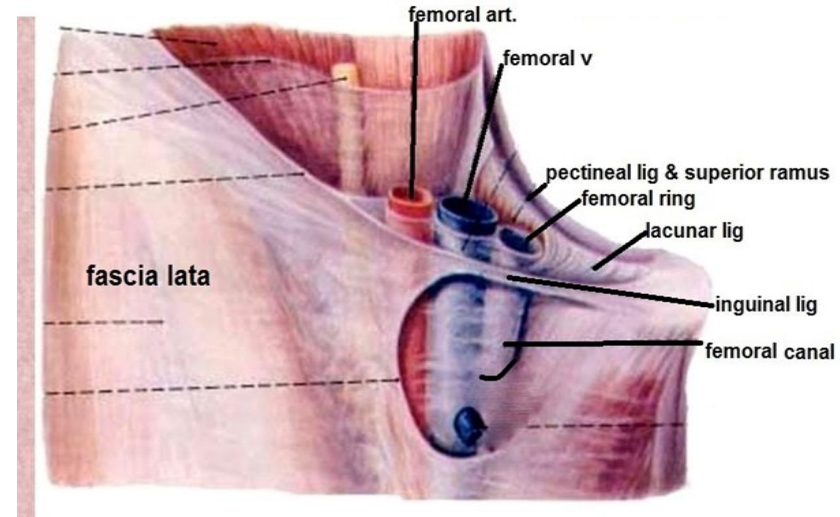
## BOUNDARIES :

### Roof :

- skin
- superficial fascia
- deep fascia: show saphenous opening.

## CONTENTS : from medial to lateral

- 1-deep inguinal LNs
- 2-femoral V. & its tributaries
- 3-femoral art. & its branches
- 4-femoral sheath around upper parts of femoral vs
- 5-femoral br. of genitofemoral n.
- 6-femoral n. & its branches
- 7- lateral cu. n. of thigh



contents of femoral triangle

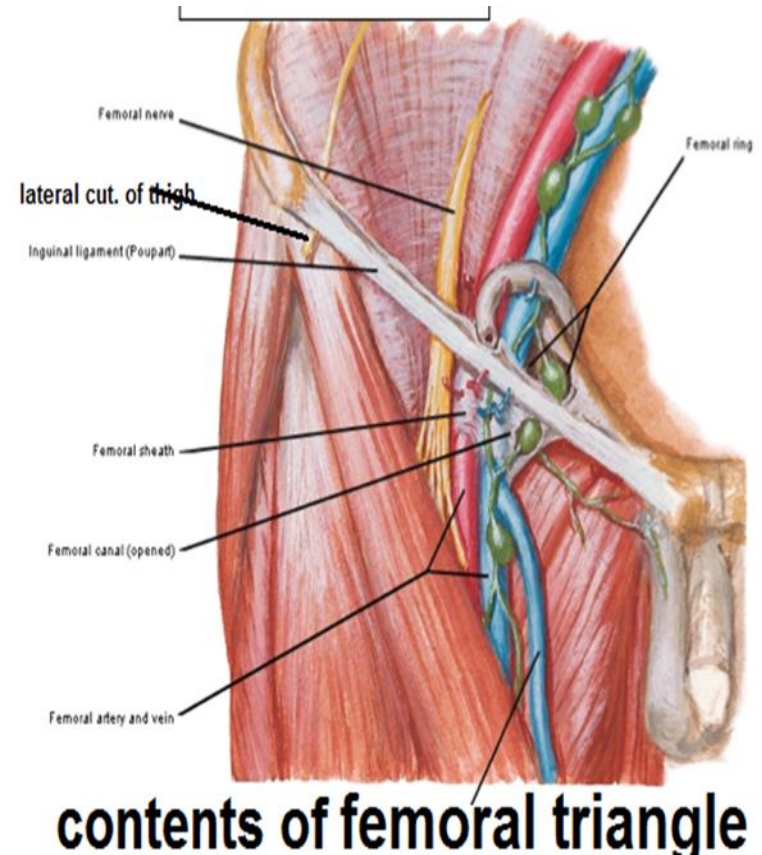
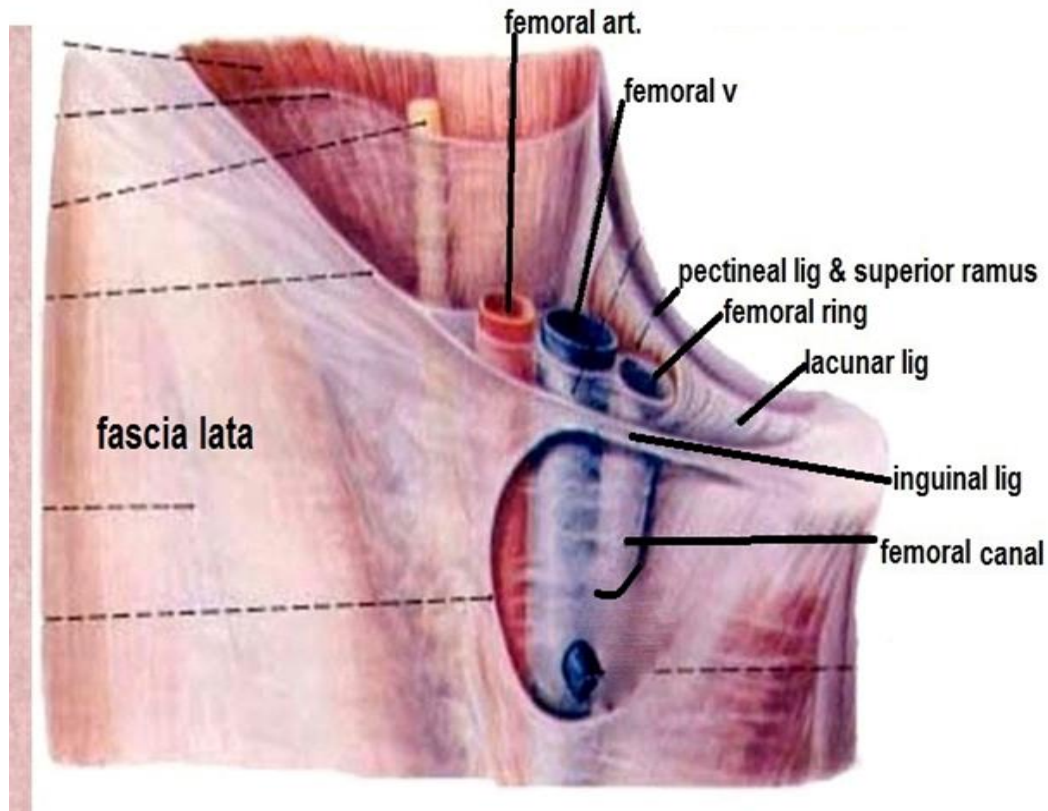
# FEMORAL SHEATH

**DEF.:** fascial sheath around upper 1 inch of femoral vessels

## FORMATION:

**Ant. Wall :** prolongation of fascia transversalis of abdomen

**Post. Wall :** prolongation of fascia iliaca of abdomen



# FEMORAL SHEATH

## COMPARTMENTS:

2 antero- post. septa divide sheath into 3 compartments

Lateral compartment :

contains -femoral art.

- femoral br. of genitor femoral n.

Intermediate compartment :

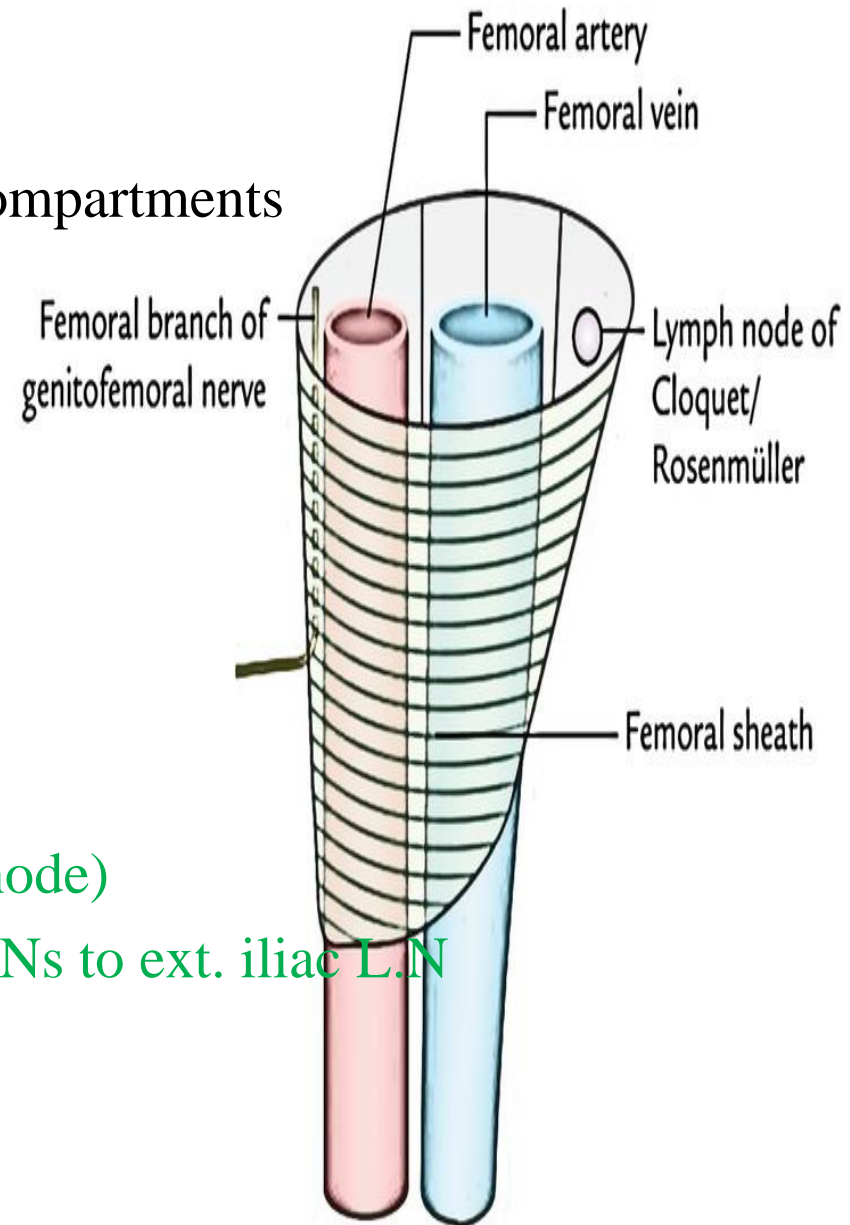
contains femoral v.

Medial compartment (femoral canal) :

contains - loose tissue (fat)

- deep inguinal L.Ns (one lymph node)

- lymphatics from deep inguinal L.Ns to ext. iliac L.N



# FEMORAL CANAL

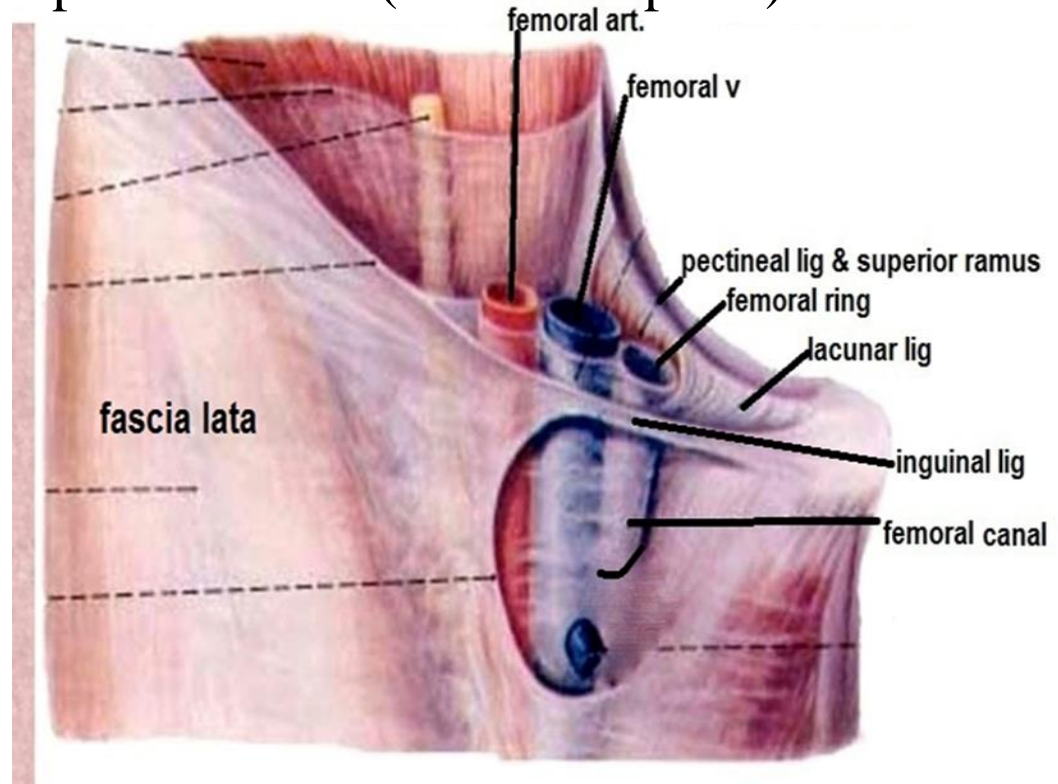
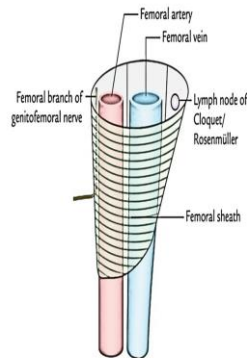
**DEF :** tissue space in the medial compartment of femoral sheath

**SHAPE:** conical canal with

**Apex :** downward & is closed by blending of its walls with adventitia of femoral v.

**Base :-** upward, called **femoral ring** that is continuous with abdominal cavity & normally is closed by ext. peritoneal fat (femoral septum)

- boundaries ant. : inguinal lig.
- post. : pectineal lig.
- medial : lacunar lig.
- lateral : femoral v.





# FEMORAL CANAL

**CONTENTS** : see before

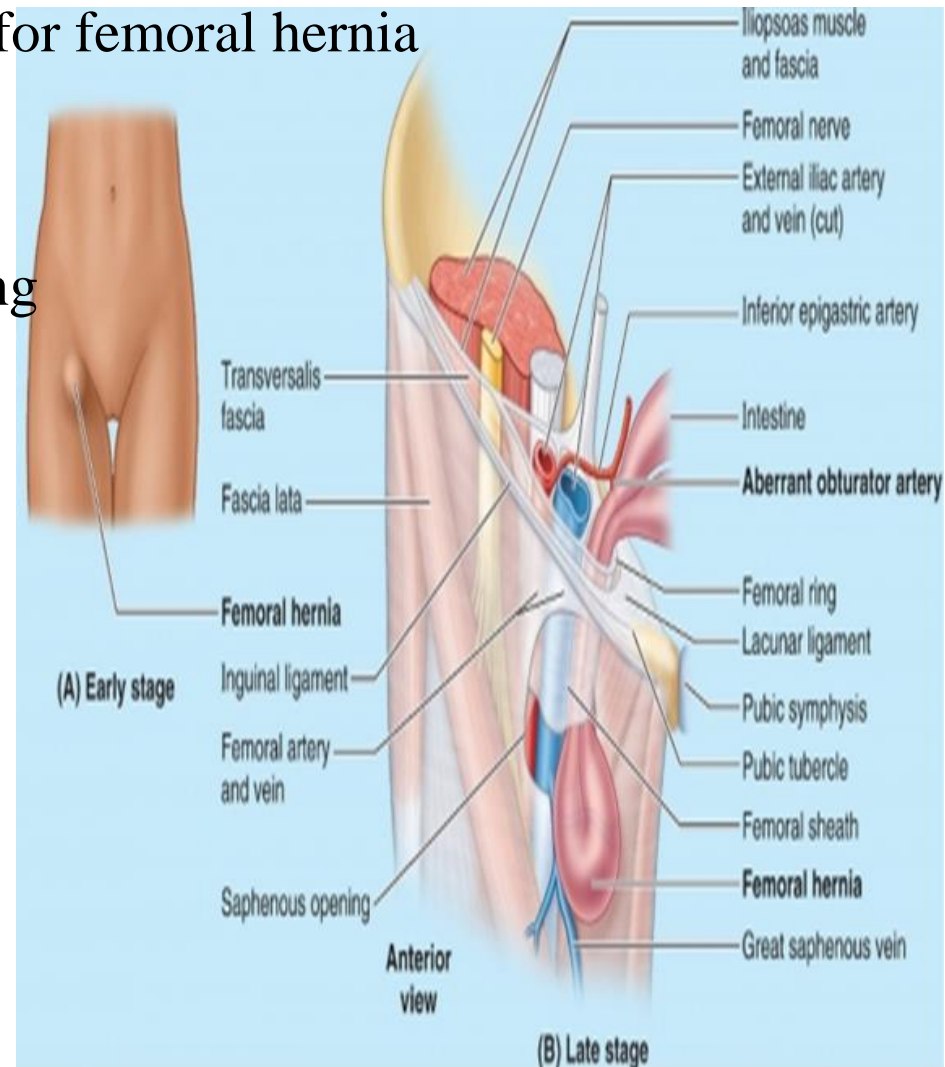
**VALUE** : give a space for distention of femoral vein during exercise

**SIGNIFICANCE** : May give passage for femoral hernia

direction of hernia:

downward in the canal then

forward through saphenous opening



# ADDUCTOR CANAL (SUB SARTORIAL , HUNTER 'S CANAL)

**DEF & SITE:** tissue space in middle 1/3 of medial side of thigh

**SHAPE & BOUNDARIES :**  $\Delta$  in cut section with

**Anterolateral wall :**

vastus medialis & covering fascia

**Post. Wall (floor):**

adductor longus ,magnus & covering fascia

**Anteromedial wall (roof):**

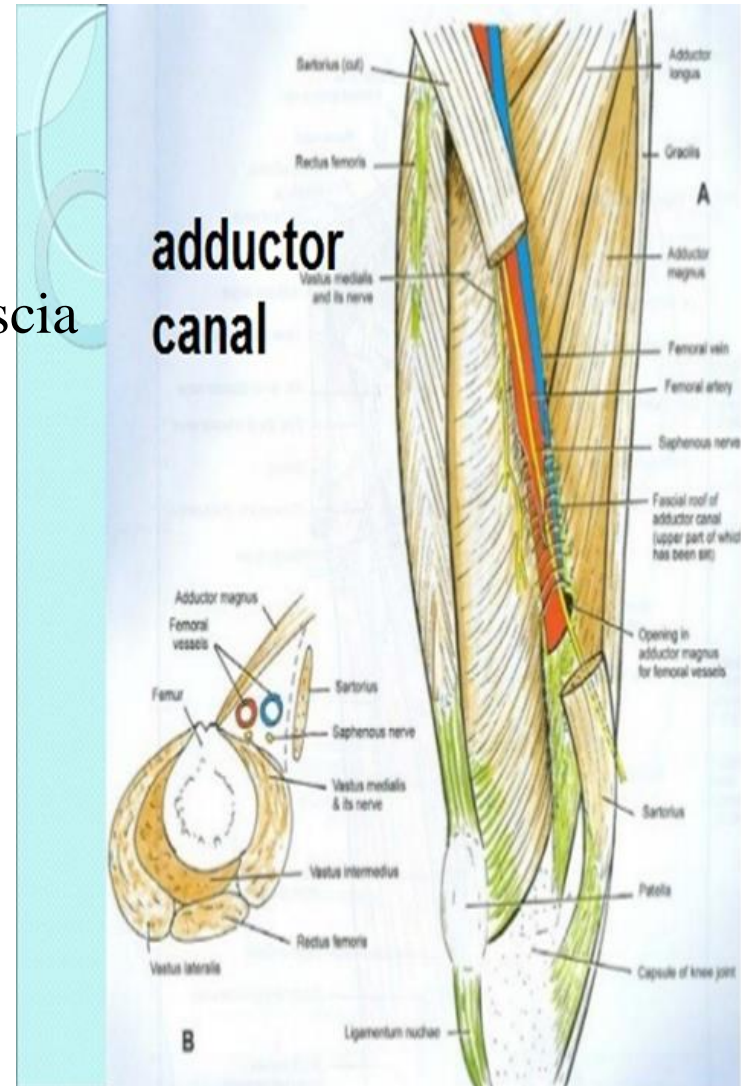
sartorius & underlying fascia

**Upper end:**

apex of femoral  $\Delta$  where the canal continues with femoral  $\Delta$

**Lower end:**

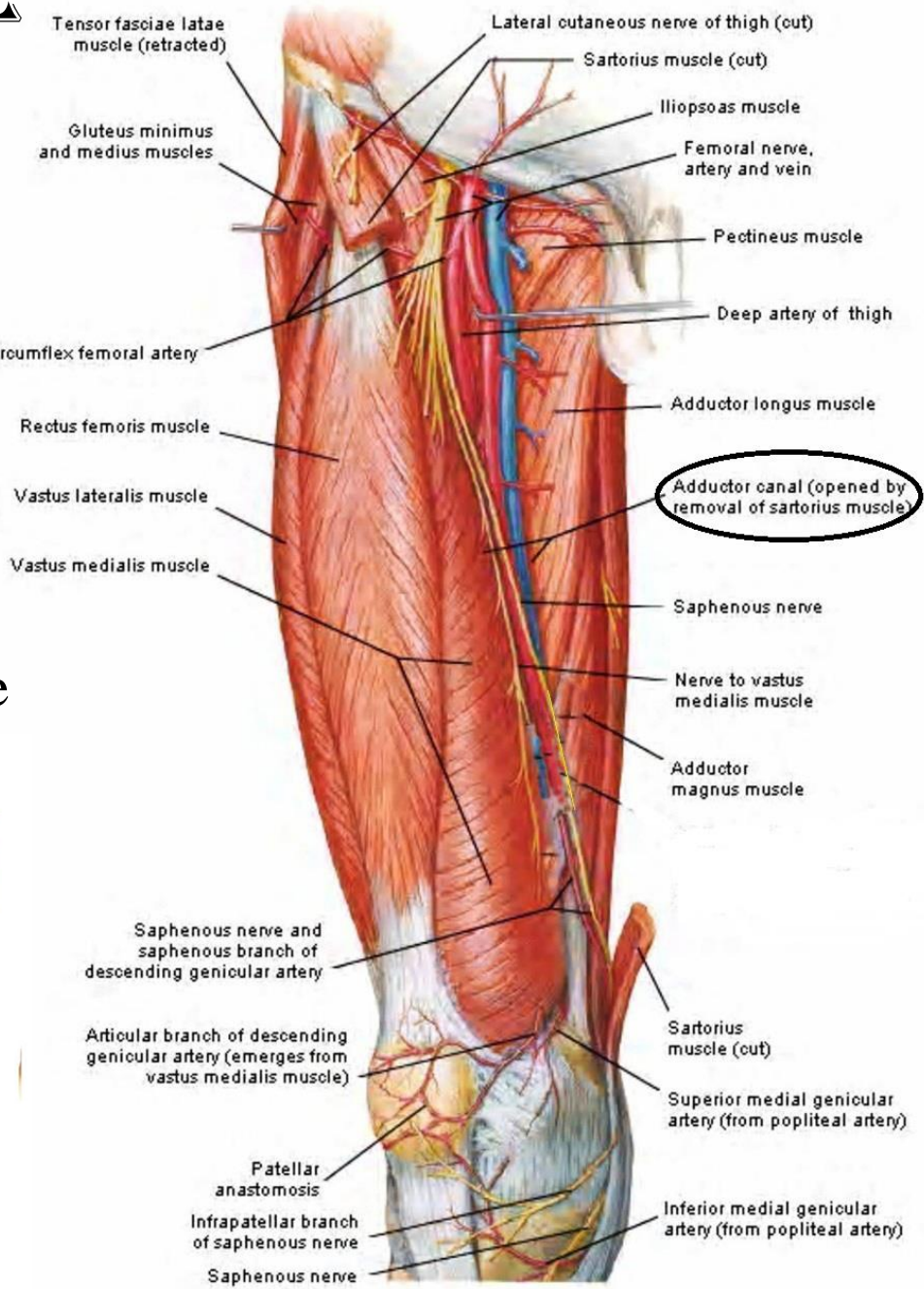
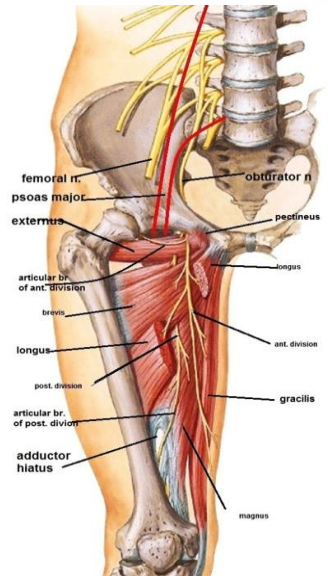
adductor opening( hiatus) where the canal continues with popliteal fossa



# ADDUCTOR CANAL

## CONTENTS :

- 1-femoral art : (terminal part)
- 2-femoral v :
- 3-descending genicular art.:
- 4-deep lymph vessels:
- 5-saphenous n. :
- 6-n. to vastus medialis:
- 7-terminal part of obturator nerve



THANQ

