

Introduction to clinical section

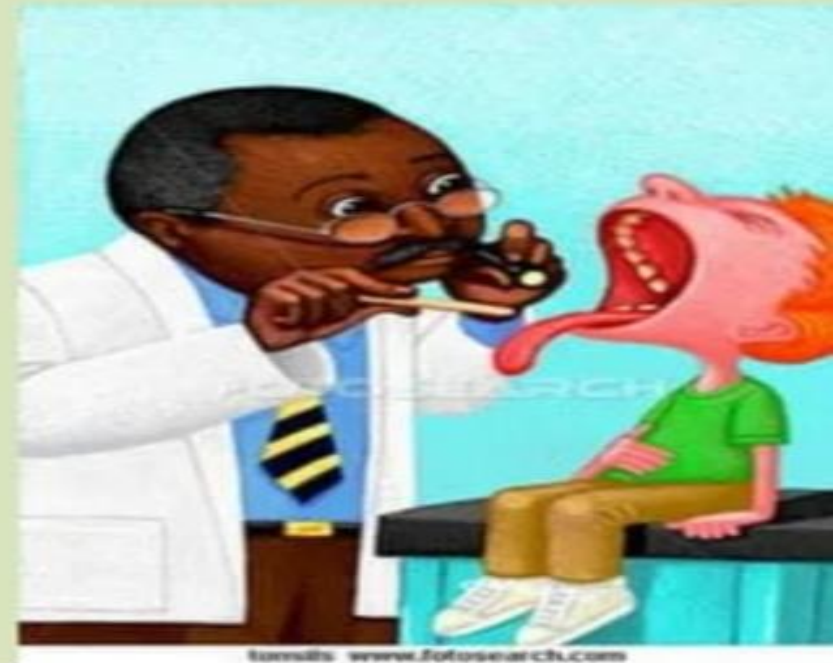
BY

DR MAHA ALSADIK

Definition



It is the systematic collection of objective information that is directly observed or is elicited through Examination Techniques.



Purposes



- ❖ To understand the physical and mental well being of the clients.
- ❖ To detect diseases in its early stage.
- ❖ To determine the cause and the extent of the disease.
- ❖ To understand any changes in the condition of diseases.
- ❖ To determine the nature of the treatment or nursing care needed for the client.
- ❖ To safeguard the client and his family by noting the early signs.
- ❖ To contribute to the medical research.
- ❖ To find out whether the person is medically fit or not for a particular task.

Techniques of Physical Examination



The four basic techniques used in physical examination are explained as follows.

- ❖ Inspection
- ❖ Palpation
- ❖ Percussion
- ❖ Auscultation
- ❖ Manipulation

Cont...



1. Inspection

It is the systematic visual examination of the client or it is the process of performing deliberate purposeful observations in a systematic manner. It involve observation of the color, shape, size, symetry, position and movements. It also use the sense of smell to detect odor and sense of hearing to detect sounds.

General Inspection.

- ❖ Overall appearance of health or illness
- ❖ Signs of distress
- ❖ Facial Expression and Mood
- ❖ Body Size
- ❖ Grooming and Personal Hygiene

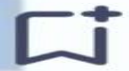
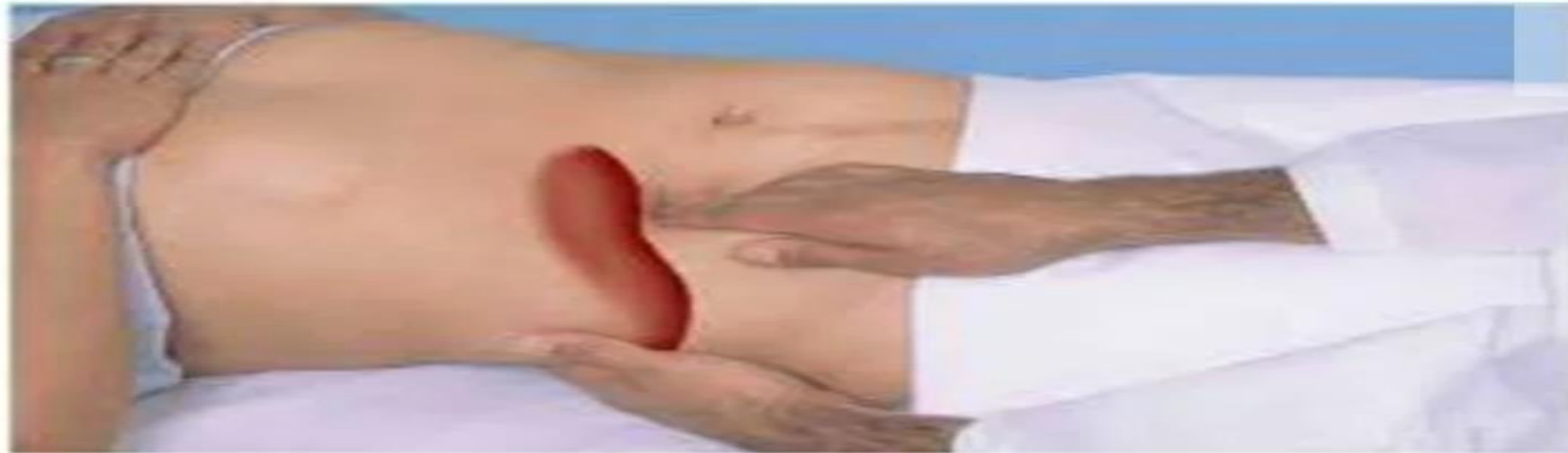
Cont...



2. Palpation

- ❖ It is use of the hands and fingers to gather information through touch. It is the assessment technique which uses sense of touch. It is feeling the body or a part with hands to note the size and position of the organs.
- ❖ The hands and fingers are sensitive tools and can assess temperature, turgor, texture, Moisture, Vibrations, Size, Position, Masses and Fluid.
- ❖ The dorsum (Back) surfaces of the hand and fingers are used to measure temperature.
- ❖ The palmar (Front) surfaces of the fingers and finger pads are used to assess texture, shape, fluid, size, consistency and pulsation. Vibration is palpated best with the palm of the hand.



Palpation

Cont..



3.Percussion

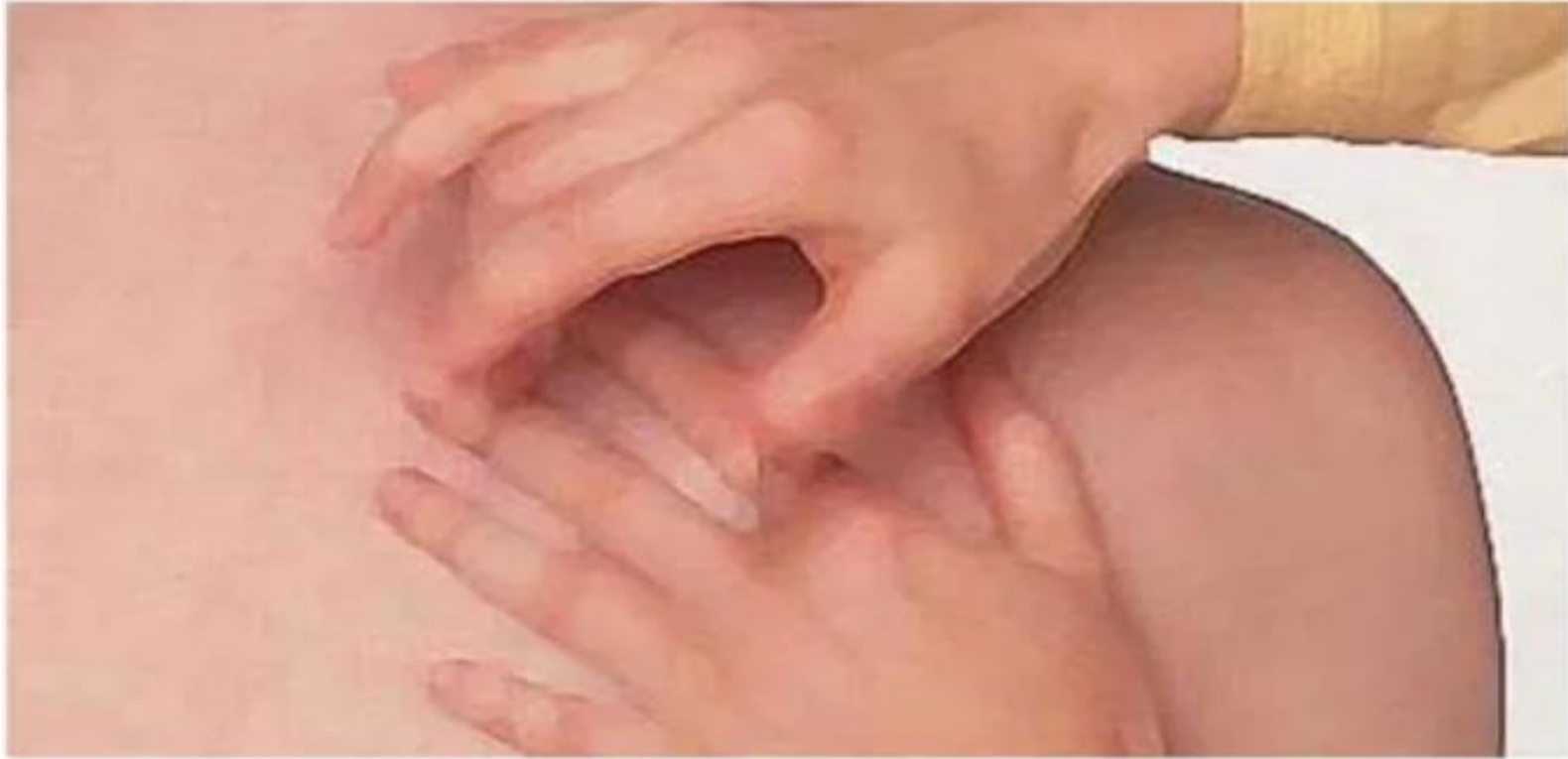It is the examination by tapping the fingers on the body to determine the condition of the internal organs by the sounds that are produced. Percussion is the act of striking one object against another to produce sound. The sound waves produced by the striking action over body tissues are known as percussion tones or percussion notes. Percussion is also used to determine if a structure is air filled, fluid filled or solid.

Cont..



The degree to which sound propagates is called Resonance. Percussion produces characteristic tones Tympanic, Hyper-resonant, Resonant, Dull and Flat.

Hyper Inflated Lung Tissue	-	Hyper resonant
Normal Lung Tissue	-	Resonant
Liver	-	Dull
Bone	-	Flat



Percussion

Cont...



4. Auscultation

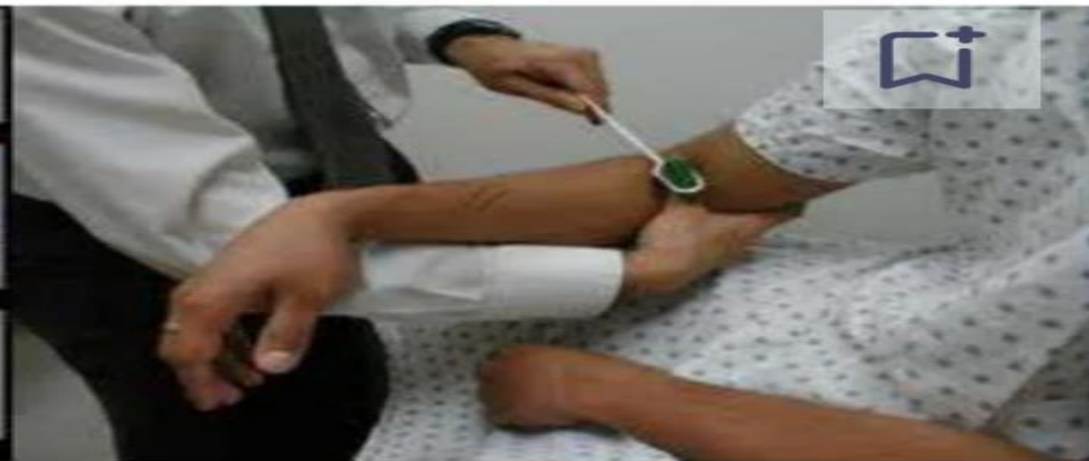It is the process of listening to sounds that are generated within the body. Auscultation is usually done with a **Sthethoscope**. The heart and blood vessels are auscultated for circulation of blood, the lungs are auscultated for moving air (Breath Sound), The abdomen is auscultated for movement of gastrointestinal contents (Bowel Sounds)

5. Manipulation

It is the moving of a part of the body to note its flexibility. Limitation of movement is discovered by this movement.

Testing of reflexes

The response of the tissues to external stimuli is tested by means of a percussion hammer, safety pin, wisp of cotton or hot and cold water.



General Examination **or** Head to Toe Examination



Role of Nurse in General Examination

❖ Preparation of Environment

■ Maintenance of Privacy

A separate examination room is needed, Keep the door closed. The relatives are not allowed.

■ Lighting

There should be Adequate Lighting.(Natural Lighting)

■ Comfortable Bed or Examination Table

The client should be placed comfortably throughout the examination

Cont...



- Preparation of the Equipment
- Preparation of the Client

Physical Preparation

Mental Preparation

Articles



Articles	Purpose
Sphygmomanometer	To measure B.P
Stethoscope	To listen the Body Sound
Foetoscope	To listen the F.H.S
T.P.R Tray	To assess the vital signs
Tongue Depressor	To examine the mouth and throat
Pharyngeal Retractor	To examine the pharynx
Laryngoscope	To examine the larynx
Tape Measure	To measure height, weight and abdomen circumference
Flash Light	To visualize any part
Weighing Machine	To check the weight
Ophthalmoscope	To examine the inner part of eye ball
Otoscope	To examine the ear
Turning Fork	To test the hearing

Cont....



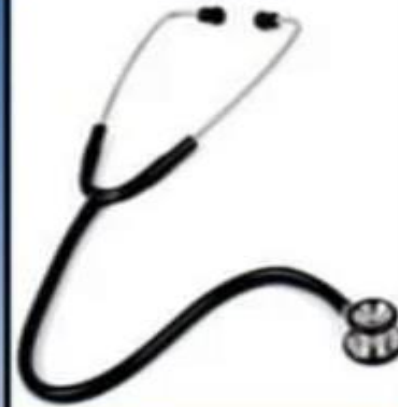Articles	Purpose
Nasal Speculum	To examine the Nostrils
Percussion Hammer	To test reflexes
Vaginal Speculum	To examine the genitals in women
Proctoscope	To examine the rectum
Gloves	To examine the pelvis internally
Sterile Specimen Bottles	To collect specimen if necessary



Sphygmomanometer



Foetoscope



Stethoscope



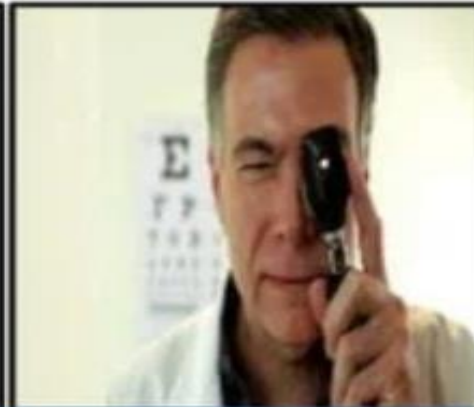Thermometer



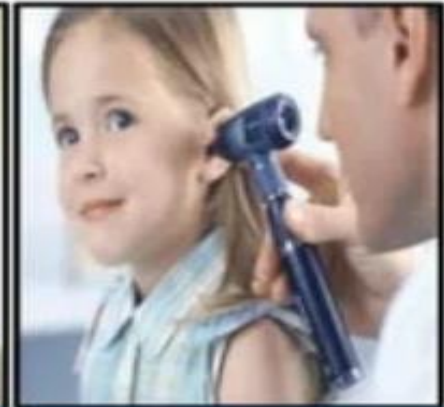Tongue Depressor



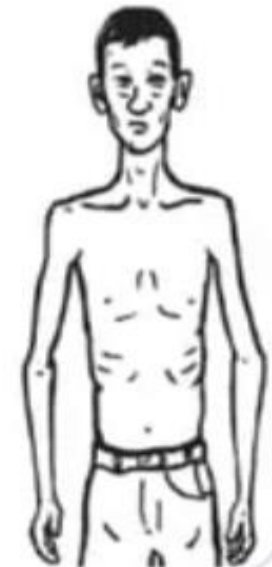
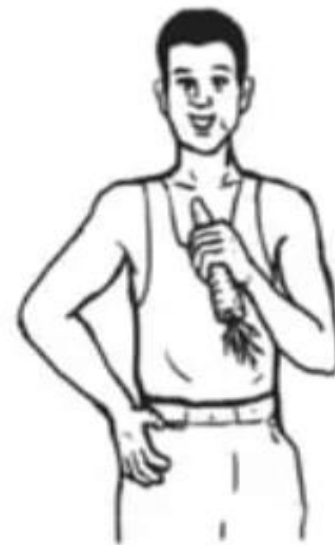Laryngoscope



Ophthalmoscope



Otoscope



Cont....



Posture

Body Curves: Lordosis, Kyphosis, scoliosis

Movement: Any limp.

Height and Weight

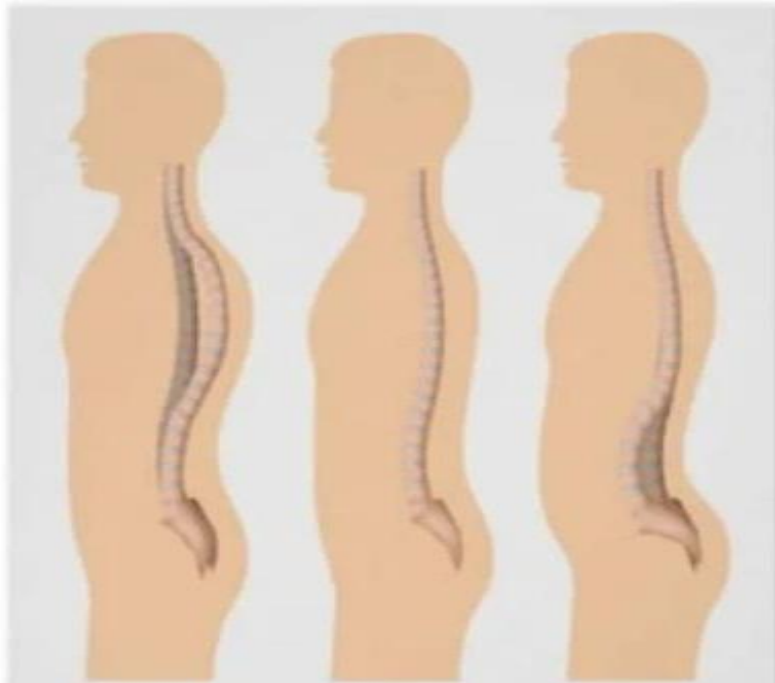
Skin Conditions

Colour : Pallor, Jaundice, Cyanosis, Flushing etc...

Texture : Dryness, Flaking, Wrinkling or Excessive moisture.

Temperature: Warm, Cold and Clammy.

Lesions : Macules, Papules, vesicles, wound etc...

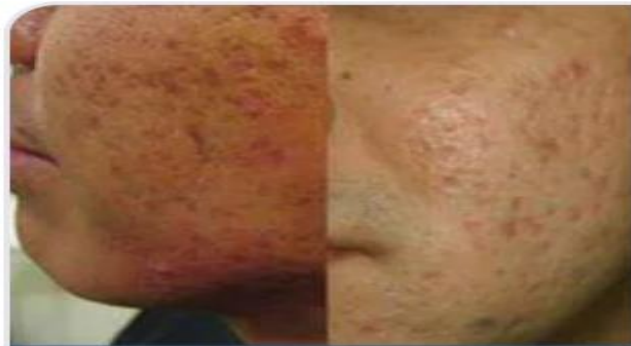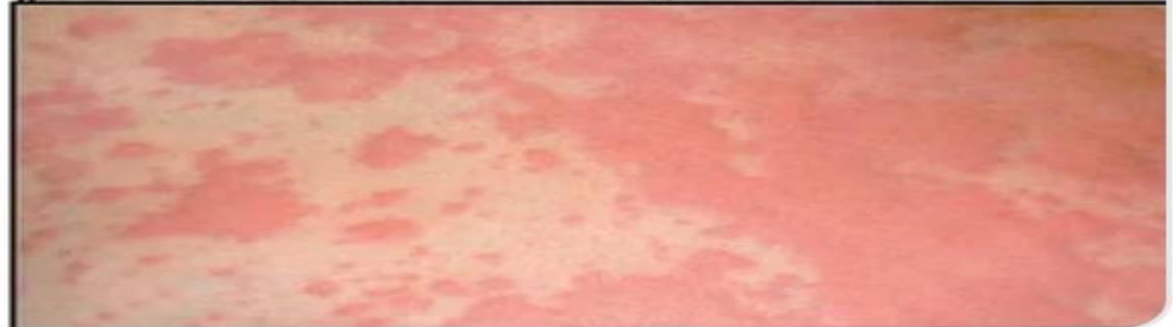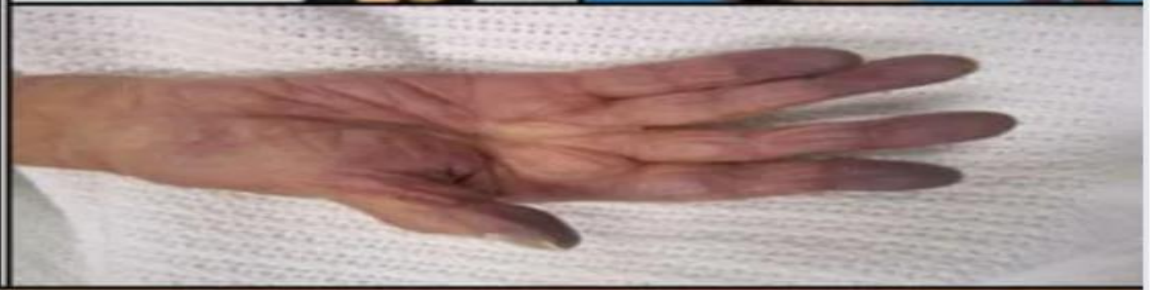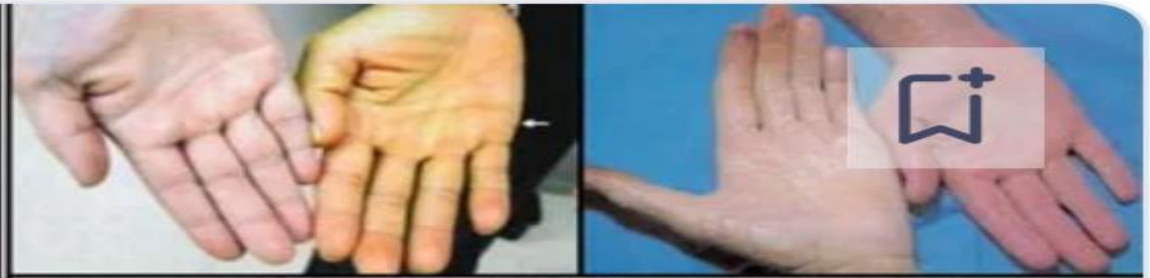


Kyphosis

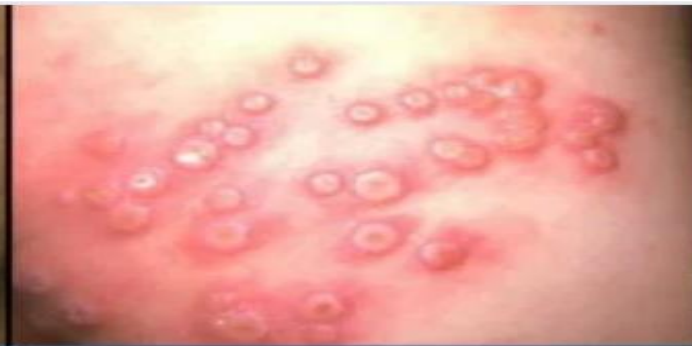Normal

Lordosis

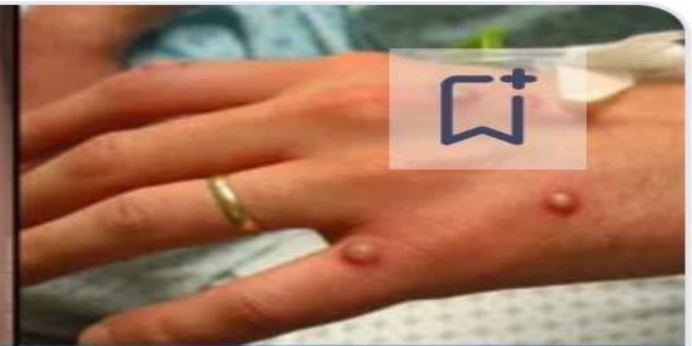© Alila Medical Images - www.alilamedicalimages.com



Macules



Papules



Vesicles

Head and Face

Shape of the Skull and Fontanelles (newborns)

Skull Circumference

Scalp: Cleanliness, Condition of Hair, dandruff, Pediculi or Infection.

Face: Pale, Flushed, Puffiness, Fatigue, Pain, Fear, Anxiety, Enlargement of Parotid Glands etc...

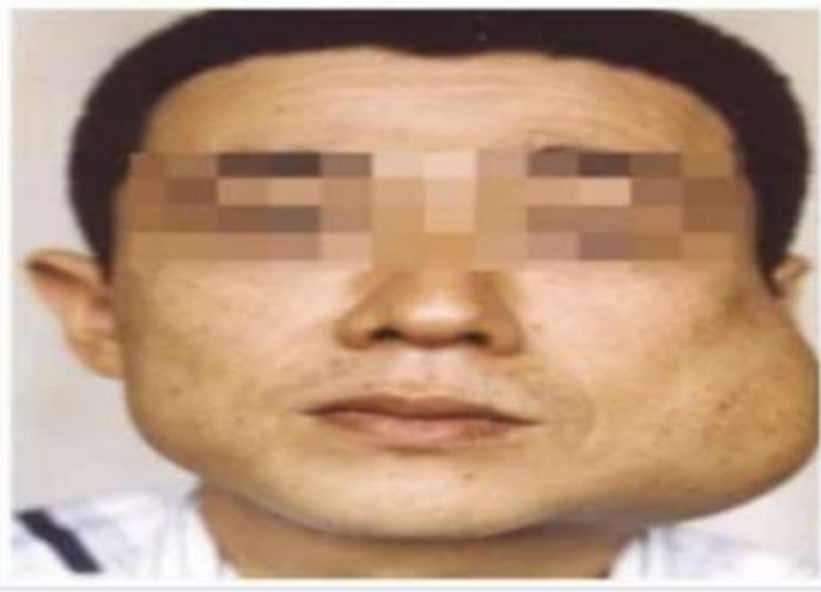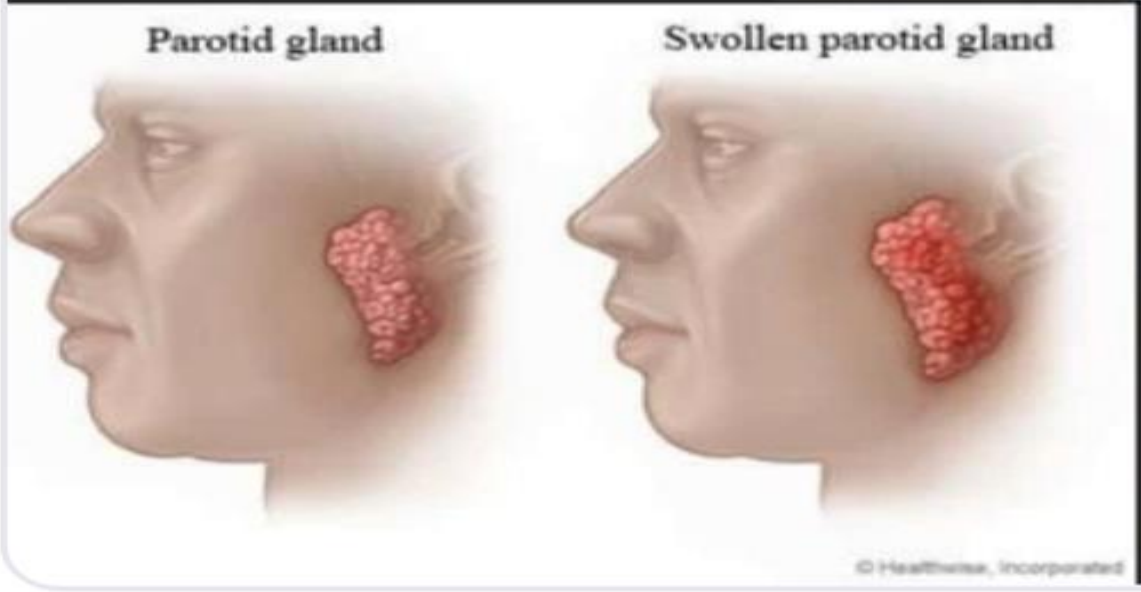
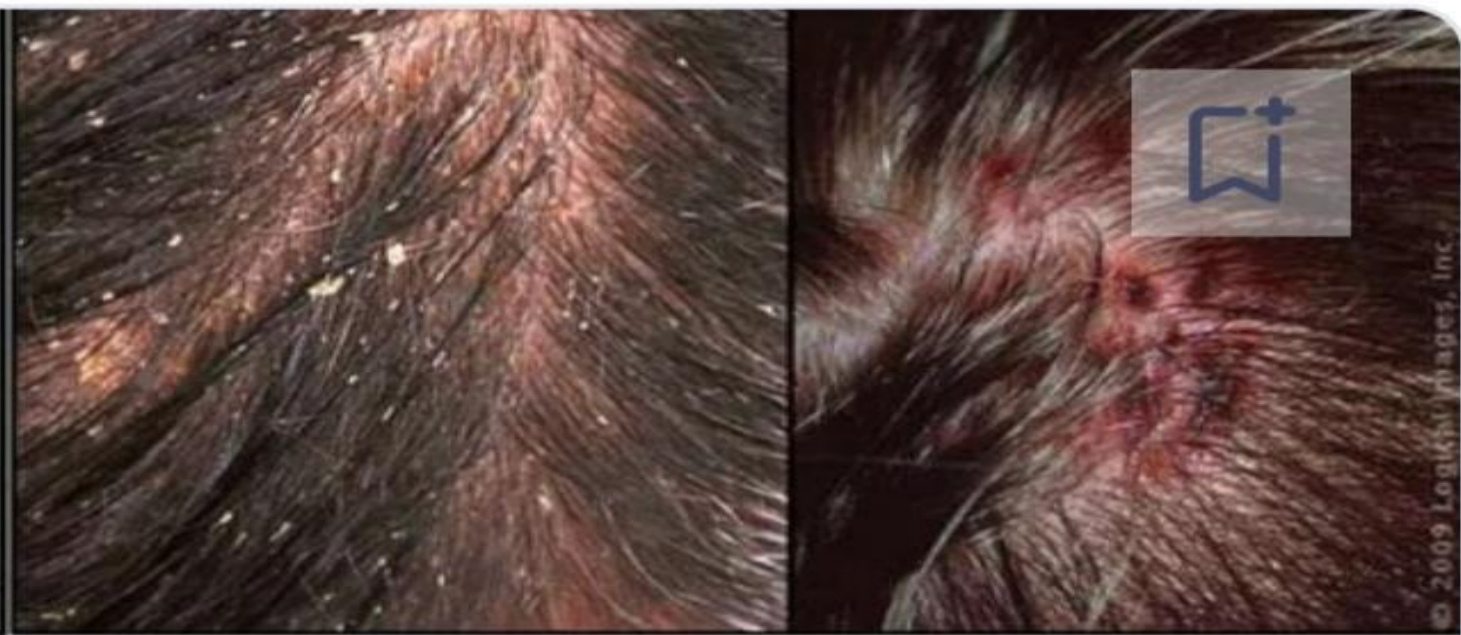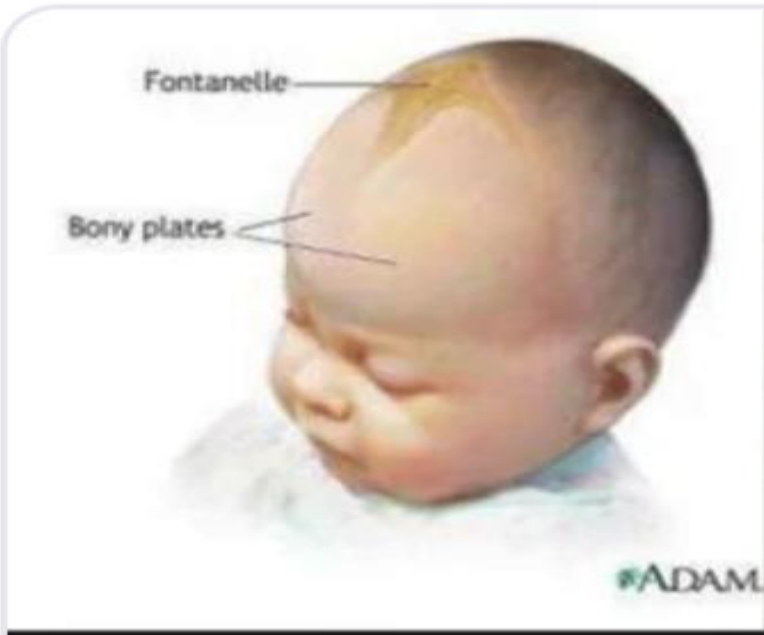


FIGURE 1: Kimura disease: subcutaneous masses in the neck, accompanied by increased volume of salivary glands
Source: Ackerman AB, Briggs PL. Differential diagnosis in dermatopathology. Vol III. Pennsylvania: Lea & Febiger, 1993. p.62-5.

Eyes:

Eye Brows : Normal or Absent

Eye Lashes : Infection, Sty.

Eye Lids : Oedema, Lesions, Ectropion (eversion),
Entropion (inversion)

Eyeballs : Sunken or Protruded

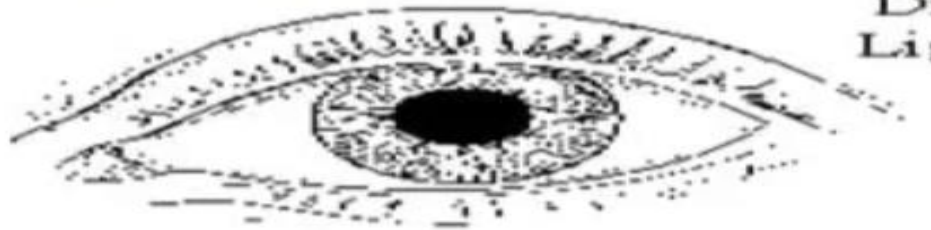
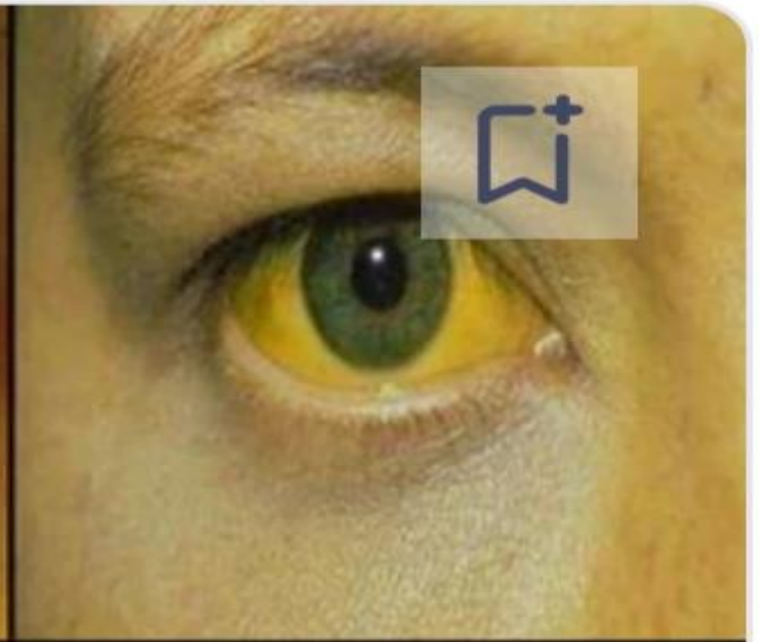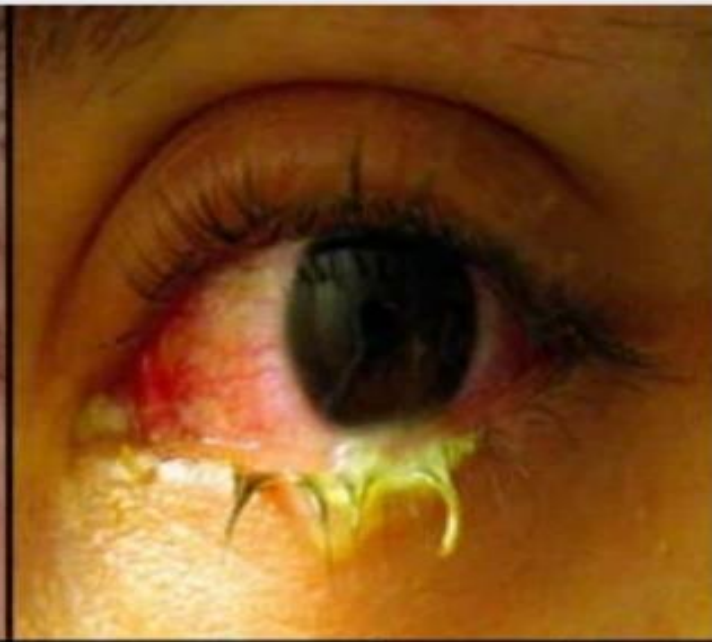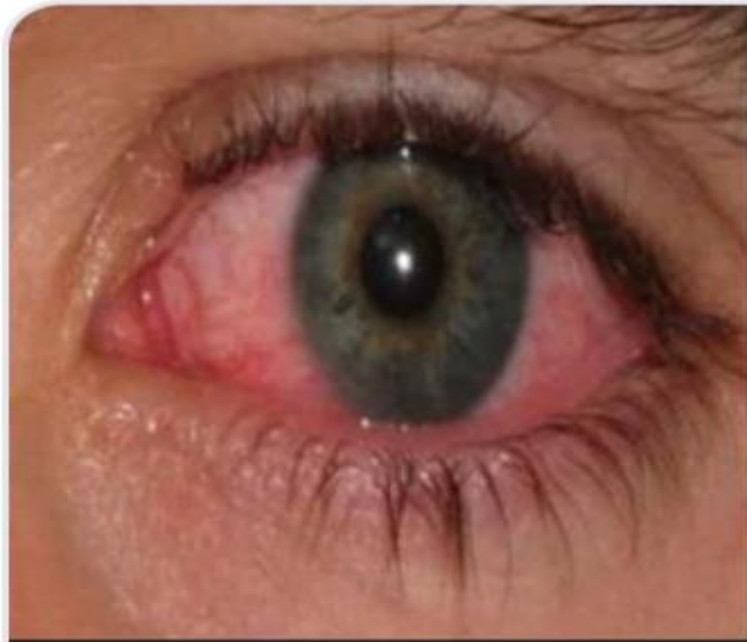Conjunctive : Pale, Red, Purulent.

Sclera : Jaundiced

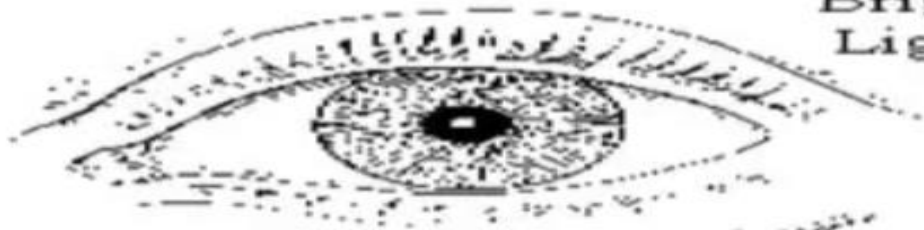
Cornea and Iris: Irregularities and abrasions

Pupils : Dilated, Constricted, Reaction to light

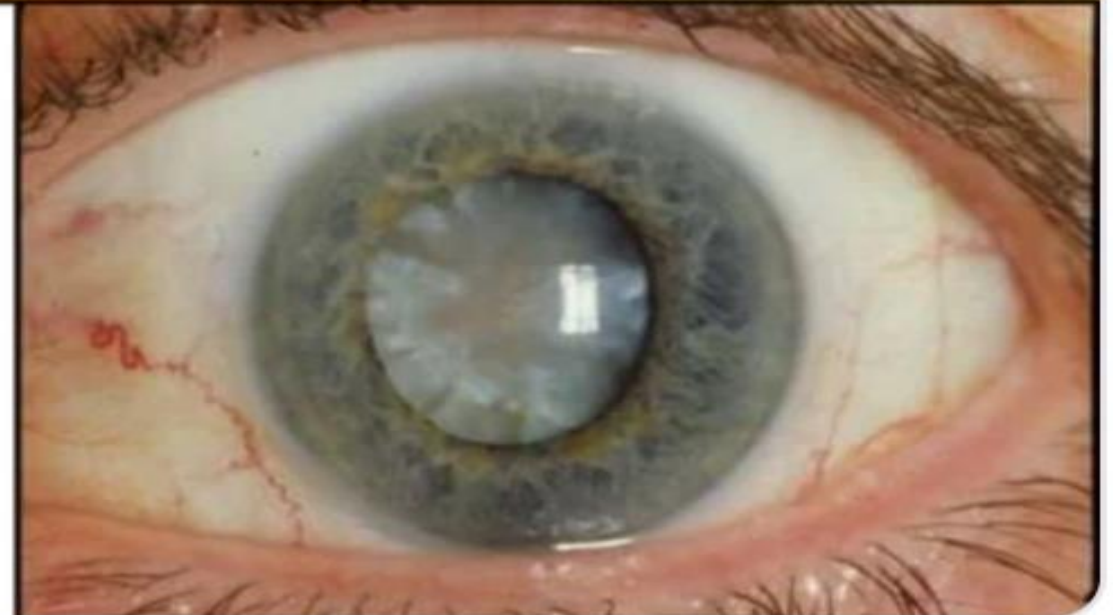
Lens : Opaque or Transparent



Dim
Light



Bright
Light



Cont....



Fundus : Congestion, Hemorrhagic Spots.

Eye Muscles : Strabismus (Squint)

Vision: Normal Myopia (Short Sight), Hyperopia (Long sight)

Ears:

External Ear : Discharges, Cerumen, Obstructing the ear
Passage.

Tympanic Membrane: Perforations, Lesions, Bulging.

Hearing : Hearing Acuity

Cont..



Nose:

External Nares: Crusts or Discharges

Nostrils: Inflammation of the Mucus Membrane, Septal Deviations.

Mouth and Pharynx:

Lips : Redness, Swelling, Crusts, Cyanosis, stomatitis.

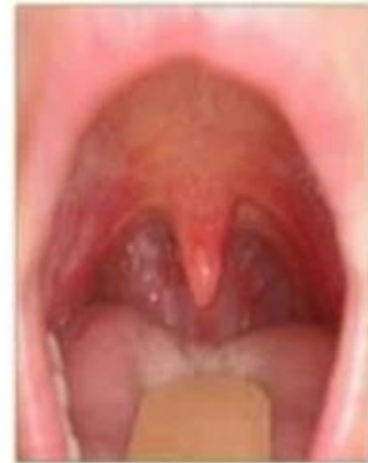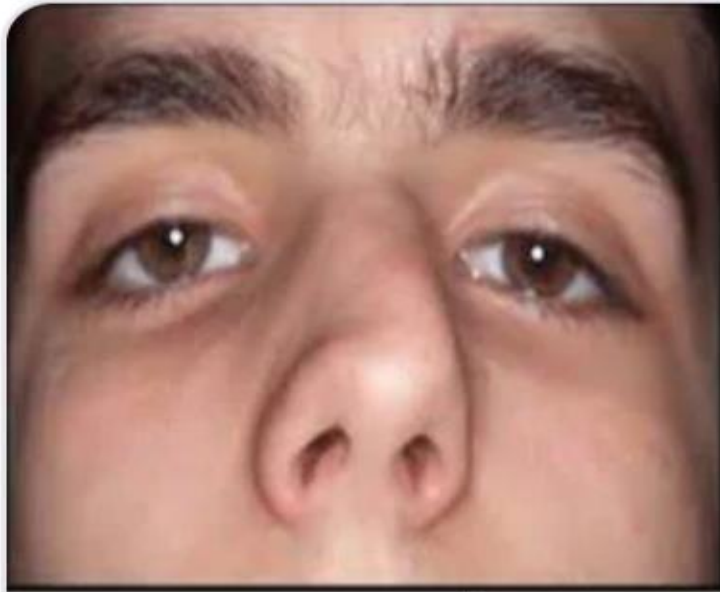Odour of the mouth : Foul Smelling

Teeth : Discoloration and dental caries

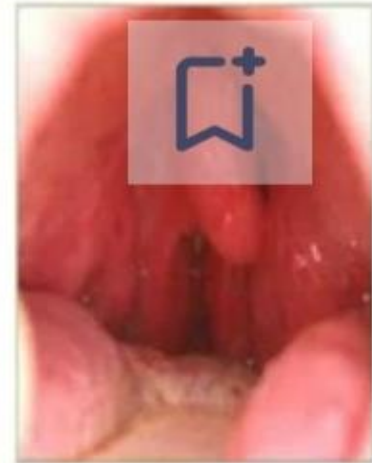Mucus Membrane : Ulceration and Bleeding, swelling.

Tongue: Pale, Dry, Lesions etc...

Throat and Pharynx : Enlarged Tonsils, Redness, Pus.



Normal Healthy Throat and Airway.



Enlarged Crowded Tonsils.



Cont.....



Neck:

Lymph Nodes: Enlarged, Palpable.

Thyroid Gland : Enlarged

Range of Motion : Flexion, Extension and Rotation.

Chest:

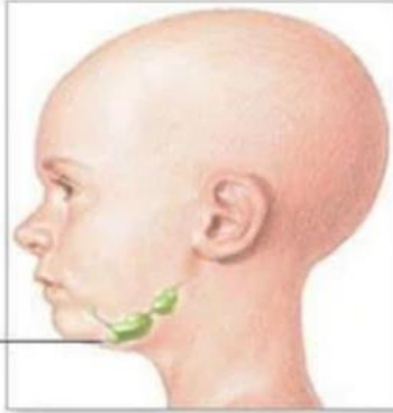
Thorax : Shape, Symmetry of expansion, Posture.

Breath Sound: wheezing, crepitations, pleural rub etc.,

Heart : Size and Location, Cardiac Murmur.

Breasts : Enlarged lymph nodes.

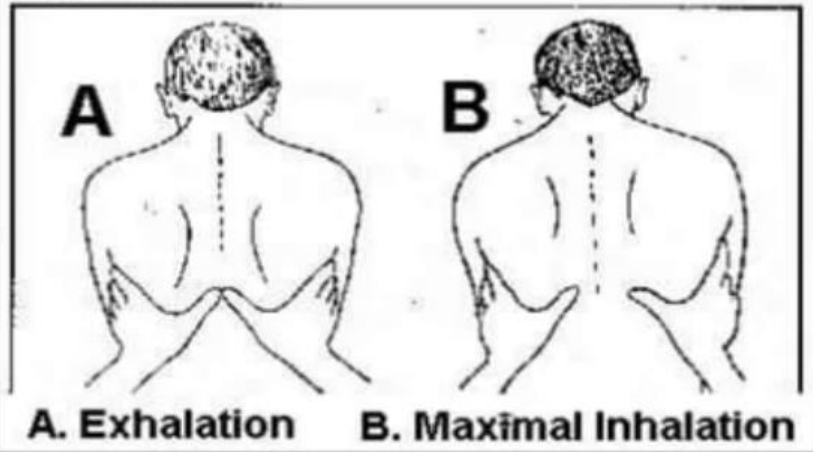
Neck lump
caused by
swollen
lymph nodes



© ADAM, Inc.

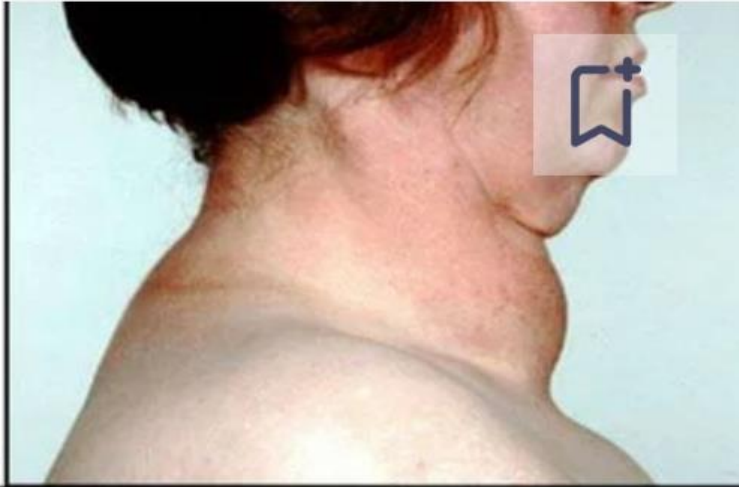

Figure 1



Cont.....



Abdomen:

Observation: Skinrashes,scar,hernia,ascites,distension,
pregnancy etc..

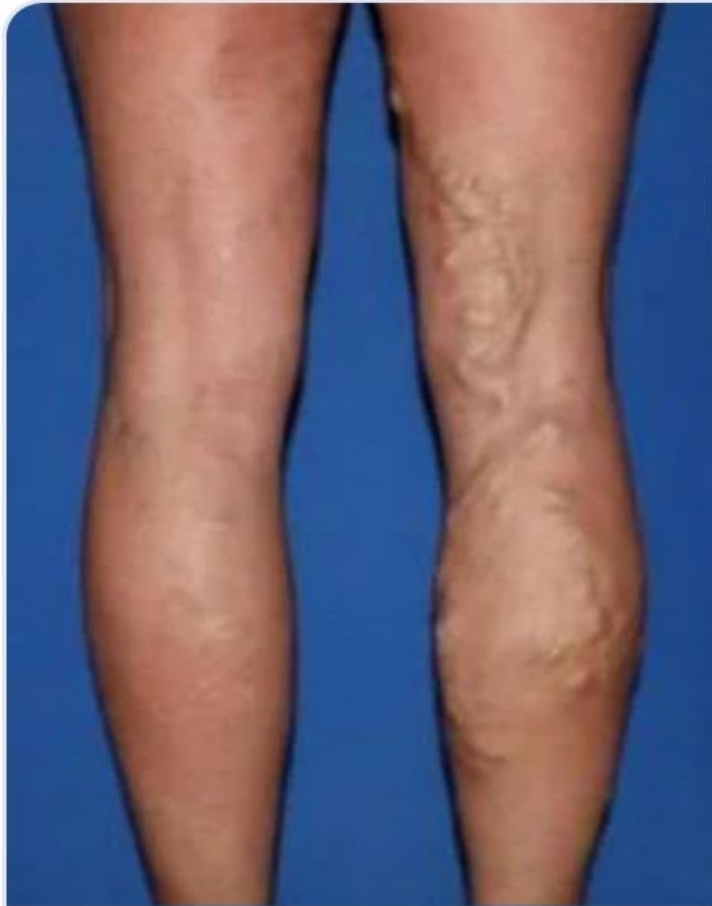Auscultation : Bowel sound and FHS

Palpation : Liver margin, Palpable spleen, tenderness at the
abdomen

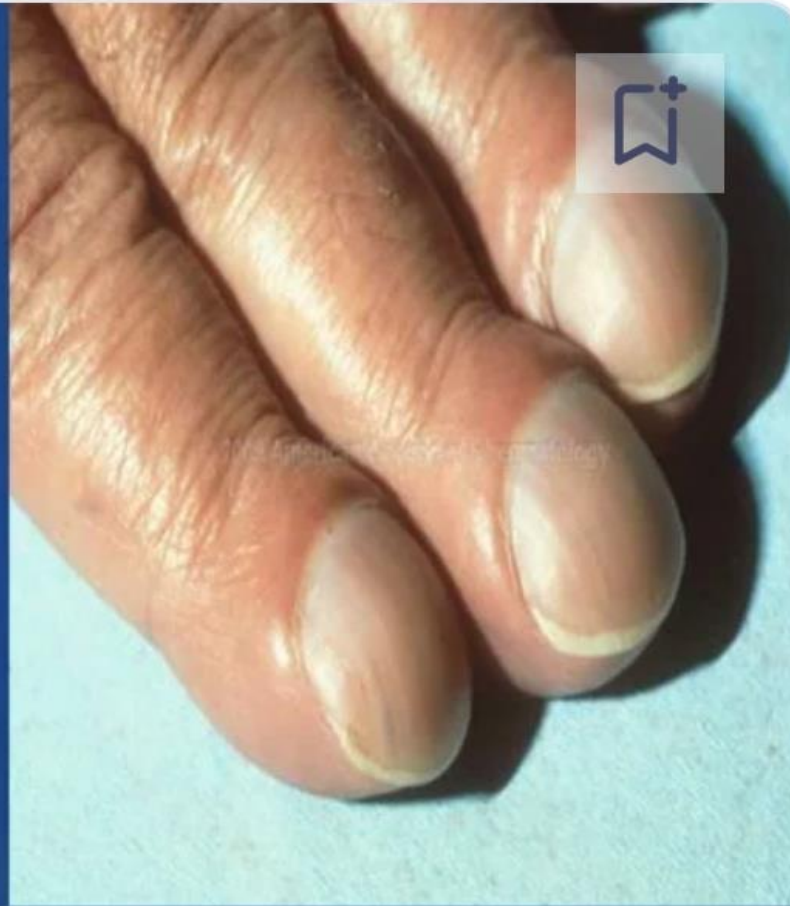
Percussion : Presence of Gas, Fluid or Masses.

Extremities:

Movement of joints,Tremors,Clubbing of fingers, Varicose
vein, reflexes etc...



Varicose Vein



Clubbing of Finger

Cont.....



Back.

Spina Bifida, Curves.

Genitals and Rectum.

Inguinal lymph glands : Enlarged, Palpable.

Patency of Urinary meatus and rectum.

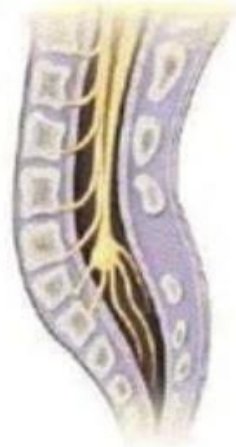Descent of the testes

Vaginal discharges

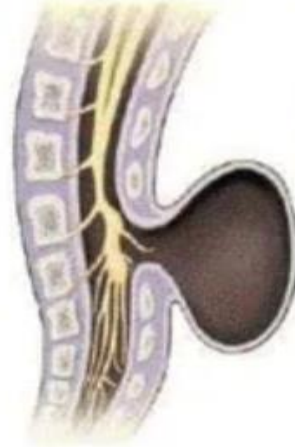
Presence of STD

Hemorrhoids

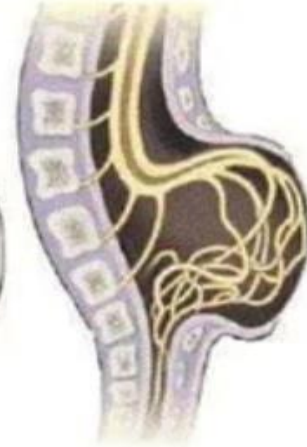Enlargement of Prostate Gland



Spina bifida occulta



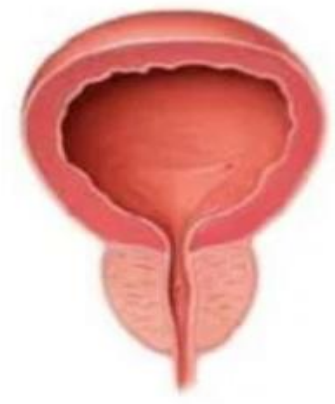Meningocele



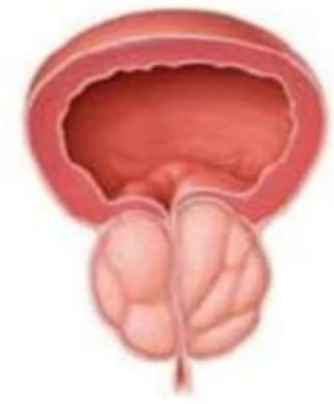
Myelomeningocele



Normal Prostate



Enlarged Prostate



Cont.....



Neurological Test:

Coordination Tests

Equilibrium Tests

Reflexes

Test for Sensations

