

Nervous System

Physical Examination

Examination of the cranial nerves

- The Olfactory nerve
- Check the nasal passages if they are clear
- Ask the patient to differentiate between different known odors while the eyes are closed.
- Examine each side

The optic nerve

- Visual acuity: for the neurological exam, ask the patient to count fingers only.

Detailed examination of the eye is done by the ophthalmologist by special and proper instruments. However, you should inspect the for the following:

1. Visual Acuity
2. Colour vision
3. Visual fields
4. Pupillary reflex
5. fundoscopy

The optic nerve

- For acuity, you can use Snellen or LogMar chart to examine for acuity
- The visual fields examination (homonymous defects, sensory inattention, peripheral visual fields, central visual field (red desaturation test), and the blind spot.
- Pupillary examination: direct light reflex and consensual light reflex and relative afferent pupillary defect, and accommodation reflex.

Optic nerve

- Accommodation (for optic and oculomotor nerves): Ask the patient to focus on an object and gradually bring the object closer.
Accommodation: convergence, pupils constrict, lens convexity increases.
- Ophthalmoscopic examination: the optic disc (swelling, paleness, haemorrhage), the macula

Oculomotor nerve, trochlear, and abducens

- Look for ptosis
- Mydriasis
- On looking at the eyes, if the eye is depressed and abducted (third nerve palsy). If the eye elevated and adducted (fourth nerve palsy)
- Examine the gaze (Horizontal, vertical) for any ophthalmoplegia.
- Ask the patient if he sees double vision during the gaze examination
- Look for nystagmus during movement
- Pupillary reflex
- Accommodation reflex

The trigeminal nerve

Sensory: examine the three divisions:

- Light touch
- Pain
- Crude touch

Motor: muscles of mastication (ask the patient to clench his teeth and feel the masseter. Ask the patient to open and close the mouth against resistance.

- Corneal reflex
- Jaw jerk

The facial nerve

- Please try to differentiate between upper and lower motor neuron facial nerve lesion
- First you should inspect for asymmetry, look at the nasolabial fold and the blinking
- Watch for any involuntary movements
- Inspect the ear for vesicles in case of facial shingles
- Ask the patient to wrinkle the forehead
- Ask patient to show the teeth
- Ask patient to whistle
- You can examine for power

Facial nerve

- Taste examination:

By using a cotton buds dipped in different tastes, ask the patient to identify the taste when applied to the anterior 2/3 of the tongue.

vestibulocochlear nerve

- Hearing loss:

Whispered voice test: stand behind the patient and whisper at 15 cm on one ear while rubbing the tragus of the opposite ear. Then repeat it at longer distance, if he can hear you whispering from 60 cm distance, then this is normal. Repeat it for the other side

vestibulocochlear nerve

- Weber's Test:

Put the tuning fork on the midline of the forehead and ask the patient where does he hear the sound?

Normally in the middle or pathologically in the middle when there is bilateral equal sensorineural loss.

If it is better on the right (lateralises to the right):
right conductive hearing loss or left sensorineural hearing loss (same thing applies for the left side)

vestibulocochlear nerve

- Rinne's Test:

Put the vibrating fork on the mastoid process of the ear, then after the patient can no longer hear it, place it near to his external auditory meatus, and ask if he still can hear it and which is better (when it was on the mastoid or when it is near the ear).

Normally, the patient should be able to hear it again when it is near the meatus (after it has been stopped being heard at the mastoid). This is a normal observation because air conduction is better than bone conduction and this is reported as positive Rinne's Test.

Vestibulocochlear nerve

Weber and Rinne's Tests

	Weber without lateralization	Weber lateralizes left	Weber lateralizes right
Rinne both ears AC>BC	Normal/bilateral sensorineural loss	Sensorineural loss in right	Sensorineural loss in left
Rinne left BC>AC		Conductive loss in left	Combined loss : conductive and sensorineural loss in left
Rinne right BC>AC		Combined loss : conductive and sensorineural loss in right	Conductive loss in right
Rinne both ears BC>AC	Conductive loss in both ears	Combined loss in right and conductive loss on left	Combined loss in left and conductive loss on right

The Vestibulocochlear nerve (Nystagmus)

Examination for nystagmus

Stand about 1 meter away from the patient,
then move your finger from the midline
upward, downward, left, and right

Do not move more than 30 degrees from the
medline

Wait for 5 seconds at each position.

The Vestibulocochlear nerve testing for positional nystagmus

- Dix-Hallpike positional test

While the patient seated, ask him to turn the head 45 degrees to one side and rapidly lower him so that his head is lower than the body at the edge of the table. Wait 30 seconds to watch for Nystagmus in case of positional vertigo. Repeat the test on the other side.

Nystagmus

Oscillation of the eye ball that is rhythmical and starts with slow phase in case of jerk nystagmus.

Similar to vertigo, nystagmus is divided into peripheral and central.

- Central nystagmus is caused by lesions in the brain stem or cerebellum (not fatigable)
- Peripheral nystagmus is caused by lesions of the vestibular nerve or the semicircular canal (fatigable).

Nystagmus

- It can be divided into pathological and physiological
- It can be pendular or jerk
- It can be spontaneous or gaze evoked

Pendular Nystagmus

- There is no slow or fast phase
- It can be vertical, horizontal, or rotatory
- Most common cases are congenital, but it can follow MS, strokes, encephalitis
- It is probably similar to cerebellar tremor pathology as it is associated with cerebellar signs and is also seen with internuclear ophthalmoplegia.

Jerk Nystagmus

- There is a slow pathological phase and followed by rapid corrective phase. The direction of nystagmus is named for the direction of fast phase.

The glossopharyngeal and vagus nerves

- You should know what do they supply
- Ask the patient to say AAH and then to cough
- Ask the patient to puff the cheeks out, while the lips are closed. If air escapes through the nose, then the palatal movement is weak. If air escaped from the mouth, then this is facial nerve
- You may elicit the gag reflex or ask the patient to swallow a glass of water
- Examine both sides in gag reflex

The accessory nerve

- Face the patient and inspect the SCM and the trapezius
- Assess the power of the trapezius
- Assess the power of the SCM. Remember, the left SCM causes flexion and right side rotation of the head.

The hypoglossal nerve

- Inspect the tongue for fasciculations, tremor (Parkinson) wasting or hypertrophy, and deviation (deviates to the affected side).
- Ask the patient to move the tongue from side to side
- Test power by asking the patient to push against the cheeks.

Examination of the motor system

- Inspection and palpation
- Assess the tone
- Reflexes
- Movement and power
- Co-ordination

Inspection

- Muscle Bulk
- Fasciculations
- Myoclonic jerks
- Tremor :
 1. physiological (fine and fast, seen with anxiety, hyperthyroid, alcohol and caffeine excess, and as a side effect of Beta agonists)
 2. Essential Tremor: Fine and can be coarse in advanced cases.
 3. Action tremor: coarse and violent. Can be seen in CVA and MS
 4. Resting tremor that is slow and coarse is typical of Parkinson
 5. Intention tremor: absent at rest and increases with movement. It is typical of cerebellum

Assessment of the Tone

- Hypotonia (flaccid) or hypertonic (spastic)
- Rigidity :
 1. lead-pipe: constant through the movement (parkinson without obvious tremor)
 2. Cog-wheel rigidity: when it is associated with tremor (parkinson with tremor)
 3. Clasp-knife rigidity: seen on attempting flexion of the limb in strokes, MS or any other type of UMNL.

Examination of tone

- The room should be warm
- Passively move the joints through full range of movement, try slow and fast movements
- Test for clonus of the knee and ankle

Deep tendon reflexes

- Brachioradialis tendon reflex
- Biceps tendon reflex
- Triceps tendon reflex
- Trapezius
- Jaw jerk
- Knee jerk
- Ankle jerk
- Hoffman reflex
- Finger jerk

Superficial reflexes

- Plantar reflex (Bibinski sign)
- Abdominal reflex
- The cremasteric reflex

Power

- make sure the patient is not in pain
 - You can examine the power of all muscles
 - Give it score from 0-5
- 0 no muscle contraction
 - 1 fasciculations with no movement
 - 2 movement when gravity is eliminated
 - 3 movement against gravity but not against the resistance
 - 4 movement against resistance but weaker than normal
 - 5 normal

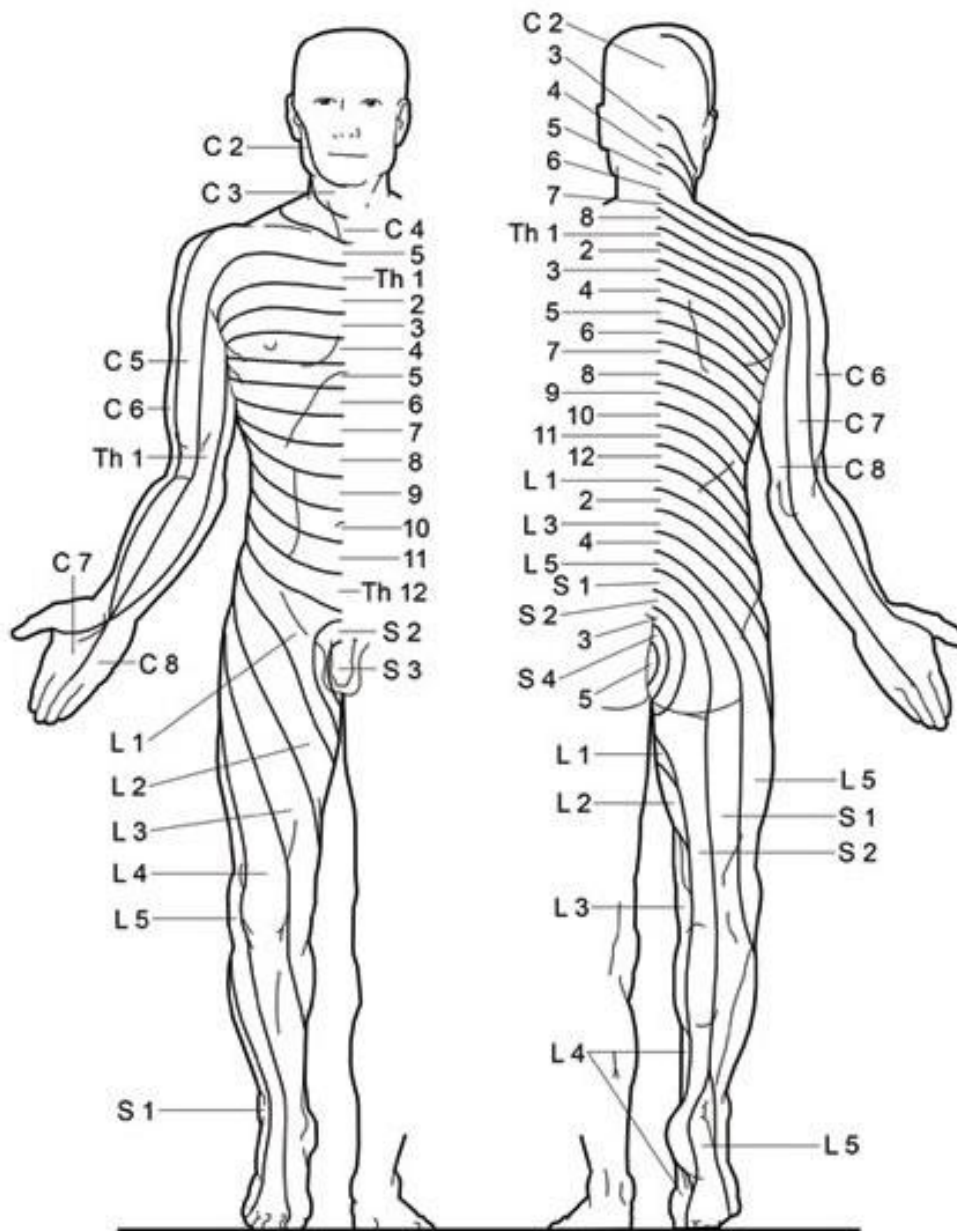
Coordination

- Gait
- Dysarthria
- Nystagmus
- Tendon reflexes if pendular
- Rebound phenomena
- Finger nose test (dysmetria)
- Heel-shin test
- Rapid alternating movement (Dysdiadochokinesia)

Sensory modalities

- Touch
- Pain (superficial and deep)
- Temperature
- Vibration
- Joint position sense
- Two point discrimination
- stereognosis, and graphesthesia
- Sensory inattention

Dermal Segmentation (Dermatomes)



Specific nerve lesions

- Median nerve: carpal tunnel syndrome

It is more common in women. The patient presents with parasthesia and pain of the hand associated with weakness. Symptoms may wake the patient at night. Thenar muscle wasting may be seen

Specific nerve lesions

- The radial nerve may be injured at the shaft of the humerus. Test for wrist drop and loss of sensation at the dorsum of the hand
- The ulnar nerve usually injured at the elbow . Test for weakness in the abduction and adduction of the hand and loss of sensation on the ulnar side of the hand,

Specific nerve lesions

- Lateral cutaneous nerve of the thigh

It can be trapped at the inguinal ligament. It causes meralgia paraesthetica), in which paraesthesia affects the area on the lateral aspect of the thigh. It is related to obesity and pregnancy

Specific nerve lesions

- Common peroneal nerve

Relate to the fracture or trauma of the head of the fibula

It results in foot drop. Test for loss of dorsiflexion, and eversion. Test also for loss of sensation over the dorsum of the foot and the lateral aspect of the leg.

THANK YOU