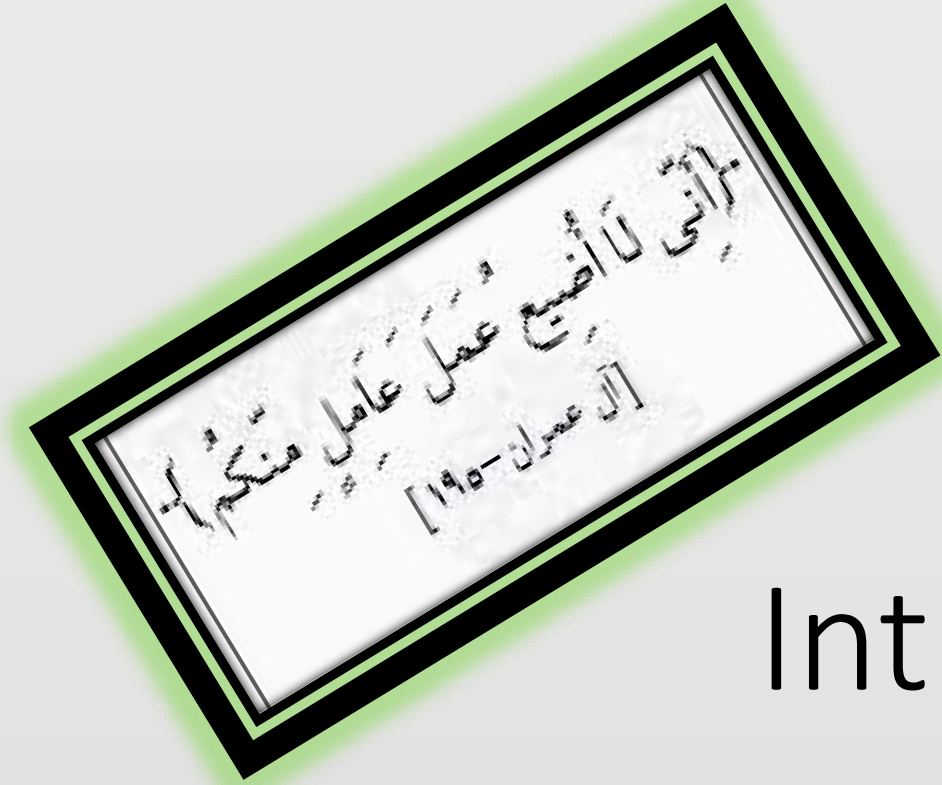


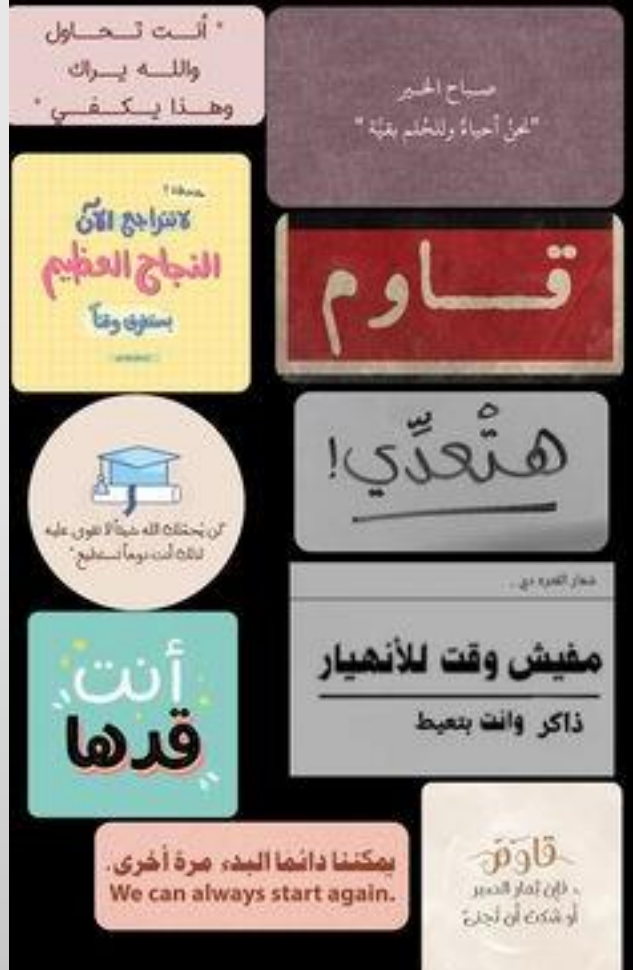
# مقدمة في طب الأسنان

## Introduction to Dentistry

د. امل عقيل البطوش

Dr. Amal Aqeel Albtoosh



# Basic Oral Structures and Tooth Terminology...1

مصطلحات فموية و سنية أساسية...1

و ما نيل المطالب بالتفني .....  
و لكن تأخذ الدنيا غلابا


# ..لا تنسى..

- استحضار النية عند كل عمل
- فهي تحول الأعمال إلى طاعات
- وأجعلها خالصة لله تعالى
- بعيدة عن شوائب الرياء والسمعة
- لذا تأني وتدبر وأنوي فيما تصنع
- وأجمع أكثر من نية في عمل واحد
- والنية بالقلب وليست بالتلفظ

قال النبي صلى الله عليه وسلم :

لَا تَعَلَّمُوا الْعِلْمَ لِتَبَاهُوا بِهِ الْعُلَمَاءَ أَوْ  
لِتُمَارُوا بِهِ السُّفَهَاءَ أَوْ لِتَصْرِفُوا وَجْهَ  
النَّاسِ إِلَيْكُمْ فَمَنْ فَعَلَ ذَلِكَ فَهُوَ فِي النَّارِ

صحيح ابن ماجه 210



## My commitment

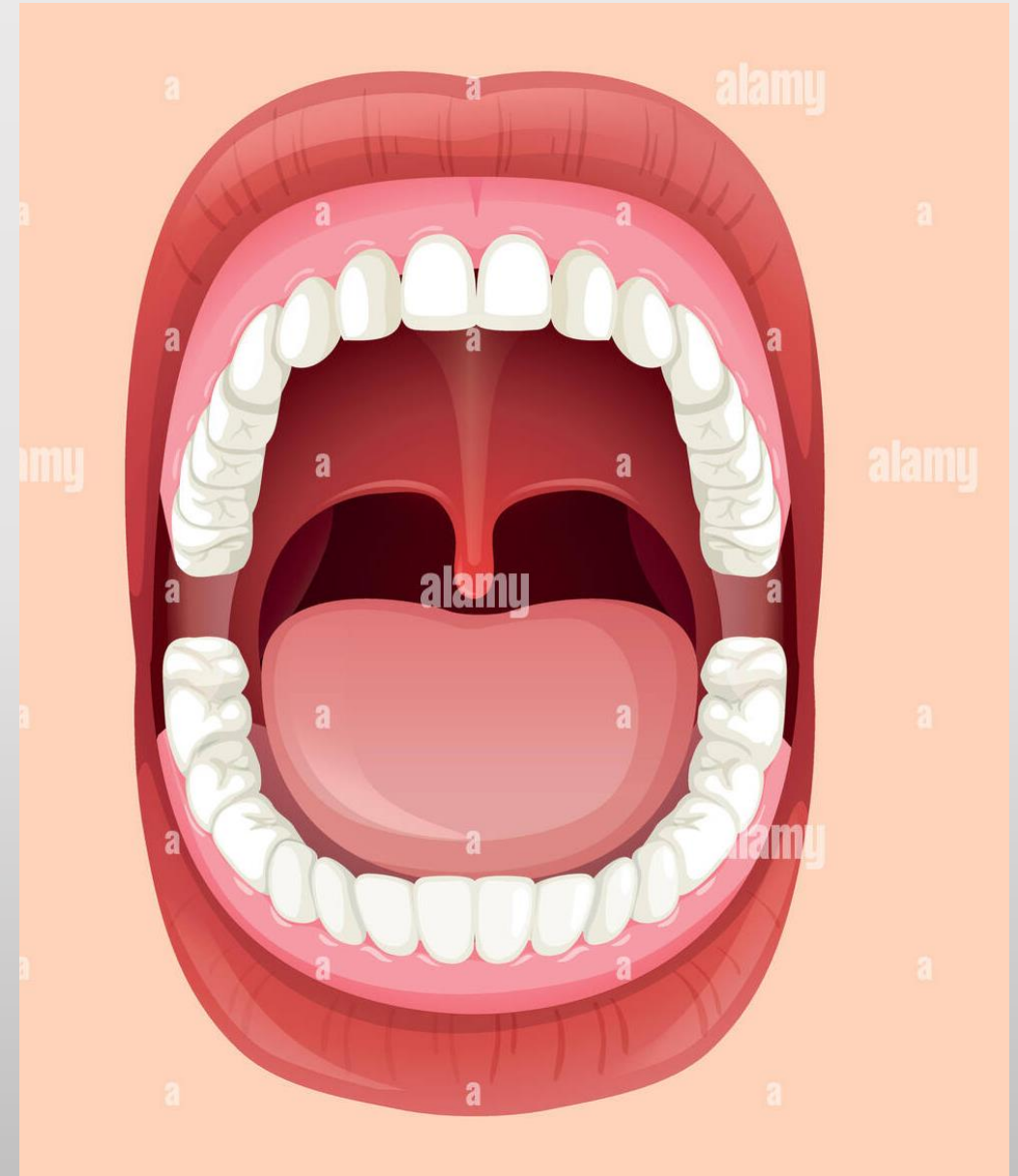
### I'm beginning my learning in FACULTY OF DENTISTRY

- I know learning can be hard, but I have the patience, determination, and discipline to reach my goals.
- When I'm stuck, I'll find a solution, like...
- Take a breath
- Break it down
- Ask for help
- Research
- Stay positive
- Talk through it
- Talk through it

## Overview of the Mouth

### What Is Mouth?

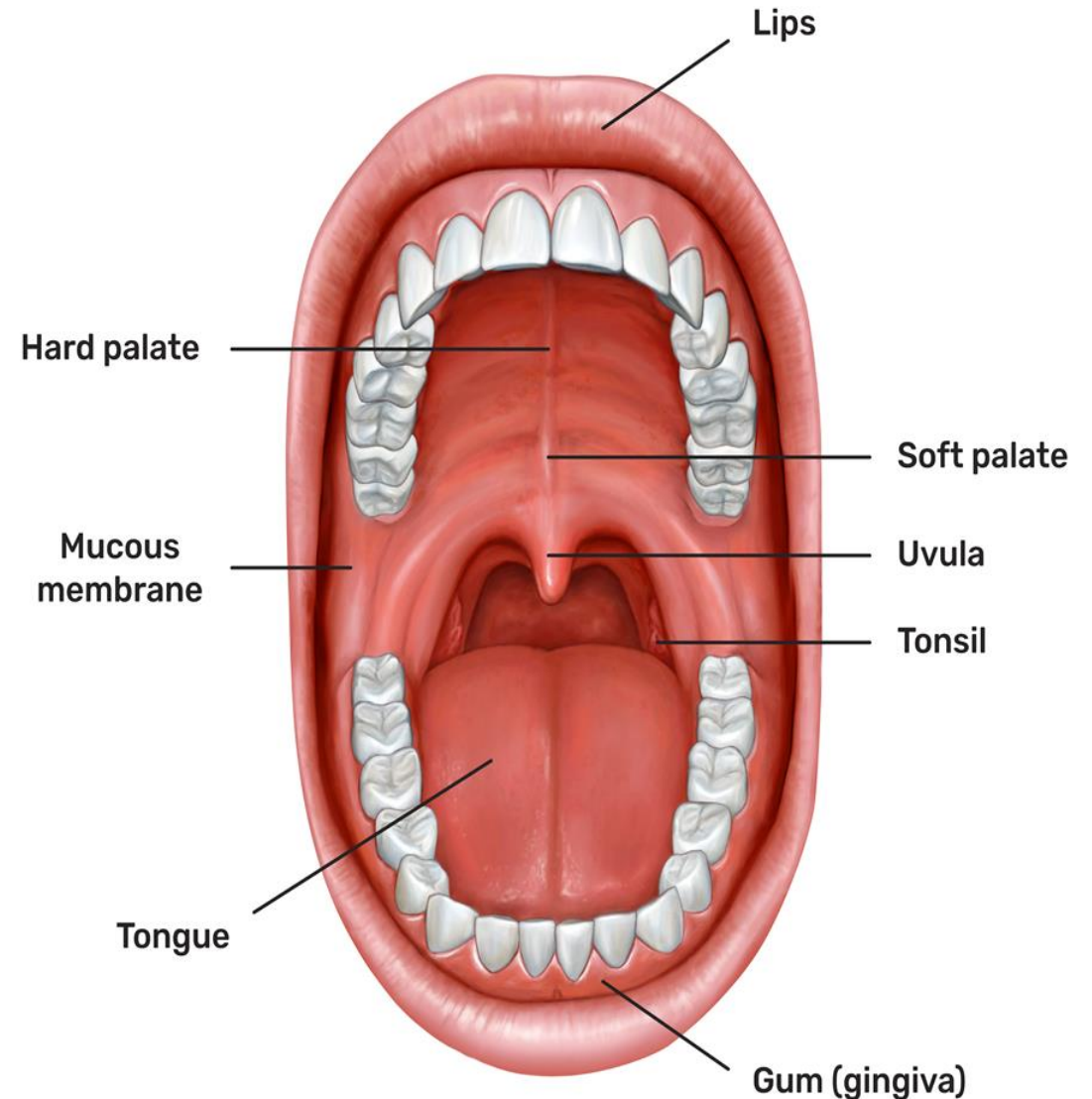
- Mouth is an oval-shaped opening that sits between the chin and nose.
- It is also referred to as the **oral cavity**.
- The mouth is the entrance to both the digestive and the respiratory systems.
- ❖ Functions:
  - ✓ breathing, talking, chewing, tasting, swallowing, eating and drinking.





## ✓ Basic Oral Structures

- **mucous membrane** (oral mucosa) : The lining inside of the mouth. When healthy, the lining of the mouth ranges in color from reddish pink to shades of brown or black.
  - The moist lining of the mouth continues outside, forming the pink and shiny portion of the lips.
- The **palate**: is the roof of the mouth and is divided into two parts.
  - ✓ **HARD PALATE** :The front part has ridges and is hard.
  - ✓ **soft palate**: The back part is relatively smooth and soft.
- The **uvula**: is a narrow tissue structure that hangs at the back of the mouth .
- The **tongue** lies on the floor of the mouth and is used to taste and mix food.
  - The tongue is covered with tiny bulges called **papillae** that contain taste buds, some of which sense the taste of food distinguishing sweet, sour, salty, bitter, and savory.
  - These tastes can be detected all over the tongue, but certain areas are more sensitive for each taste.



# Main structures of any tooth

1

Crown

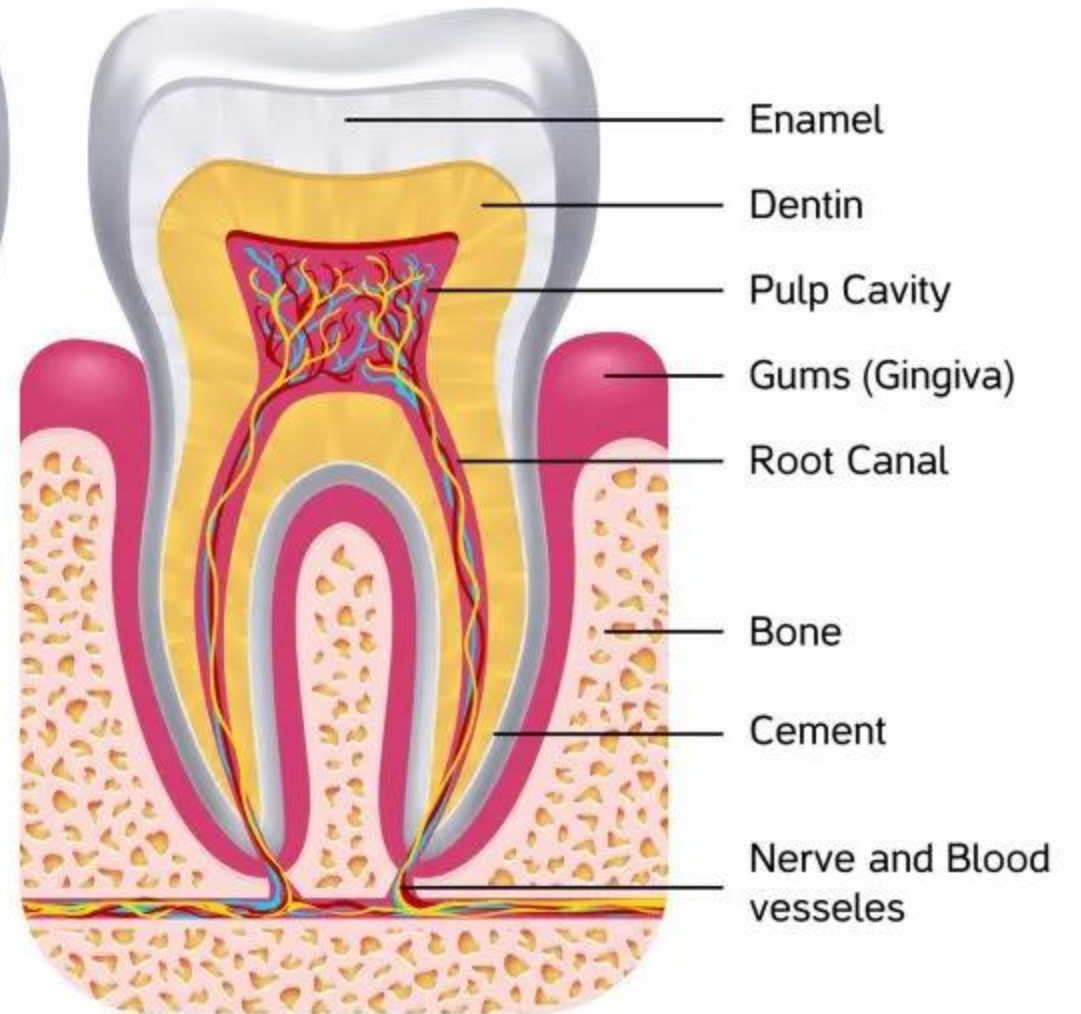
2

Neck

3

Root

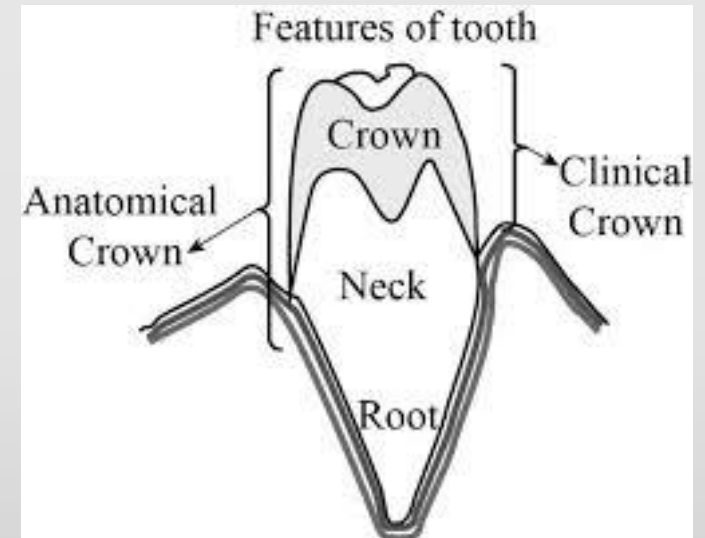
## TOOTH ANATOMY



## The Crown

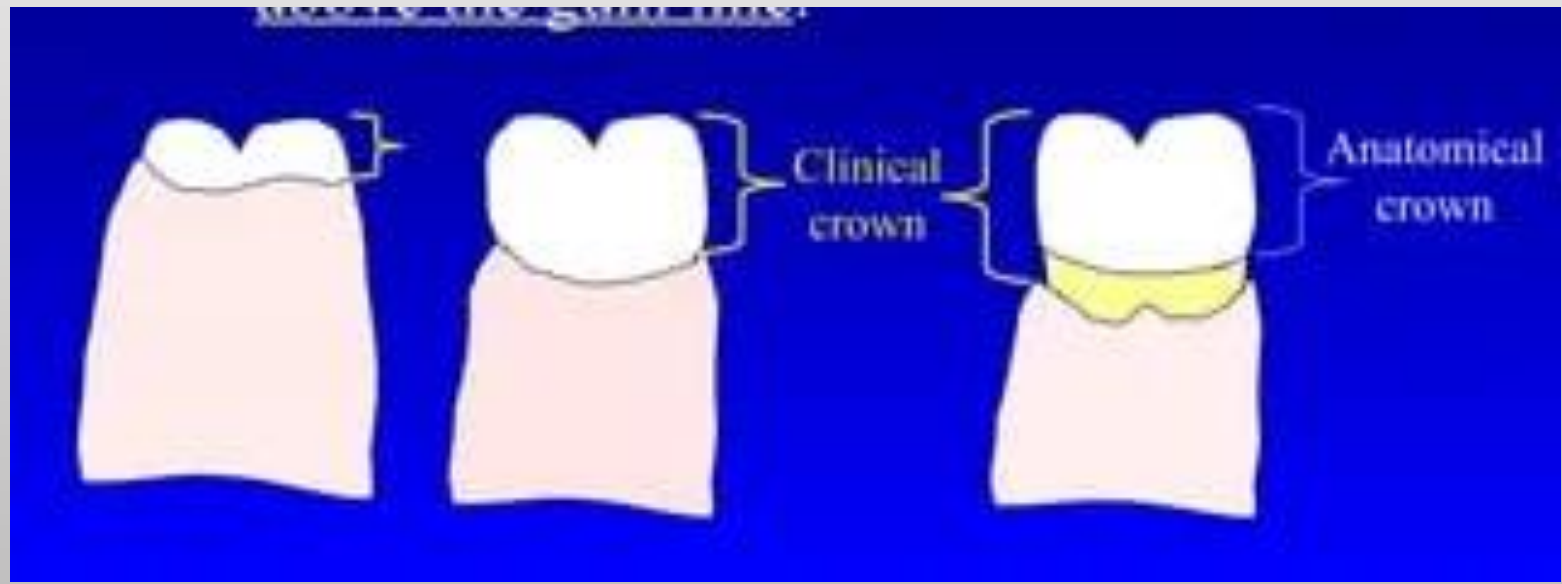
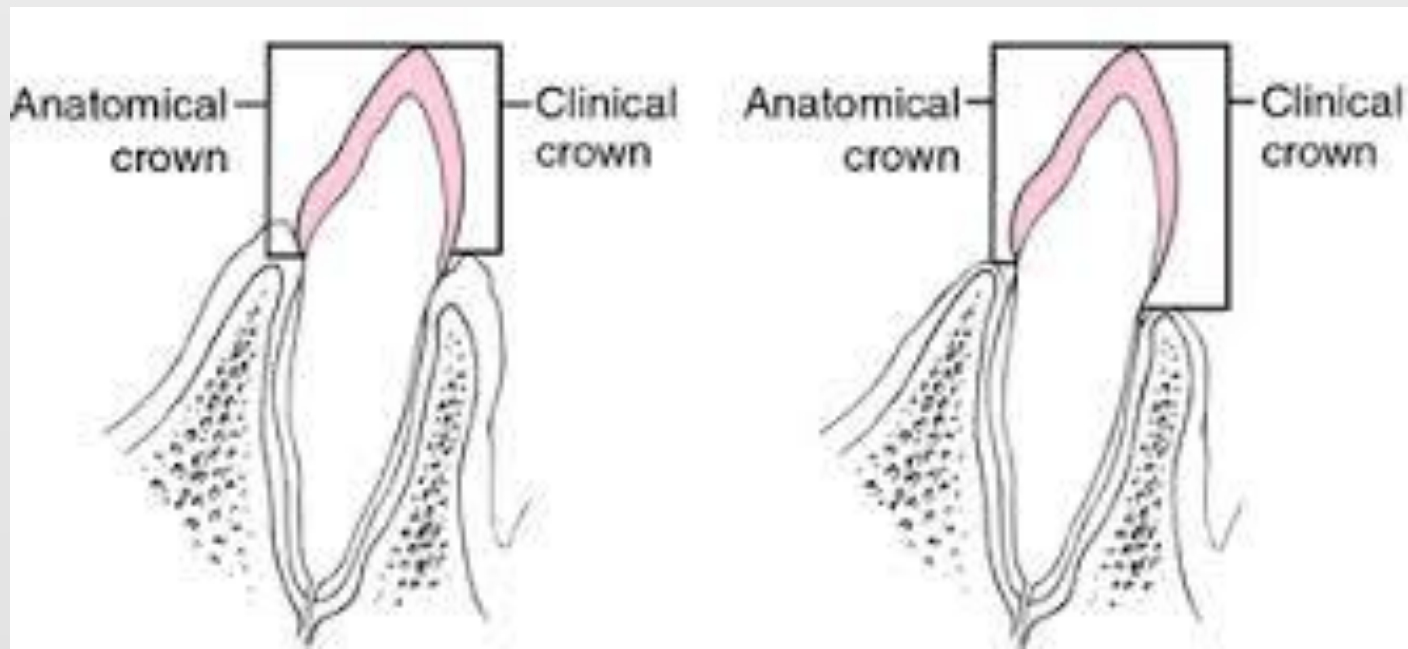
The crown contains three main parts: 1. Enamel 2. Dentin 3. The Pulp Chamber.

- The "anatomic crown" is the part of the crown covered with enamel, but all of it might not be visible in a healthy mouth. Some portion of the crown might be hidden under the gums or gingiva.
- The part of the crown that can be seen in the mouth is called the "clinical crown."



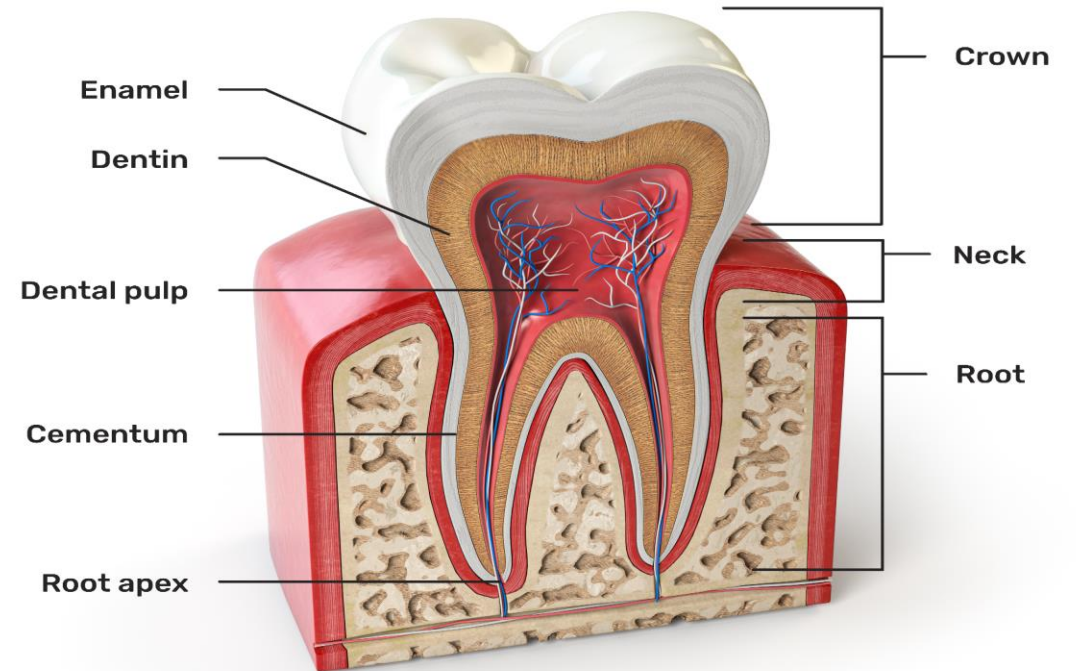
gums or gingiva, which is the pink tissue surrounding the tooth.





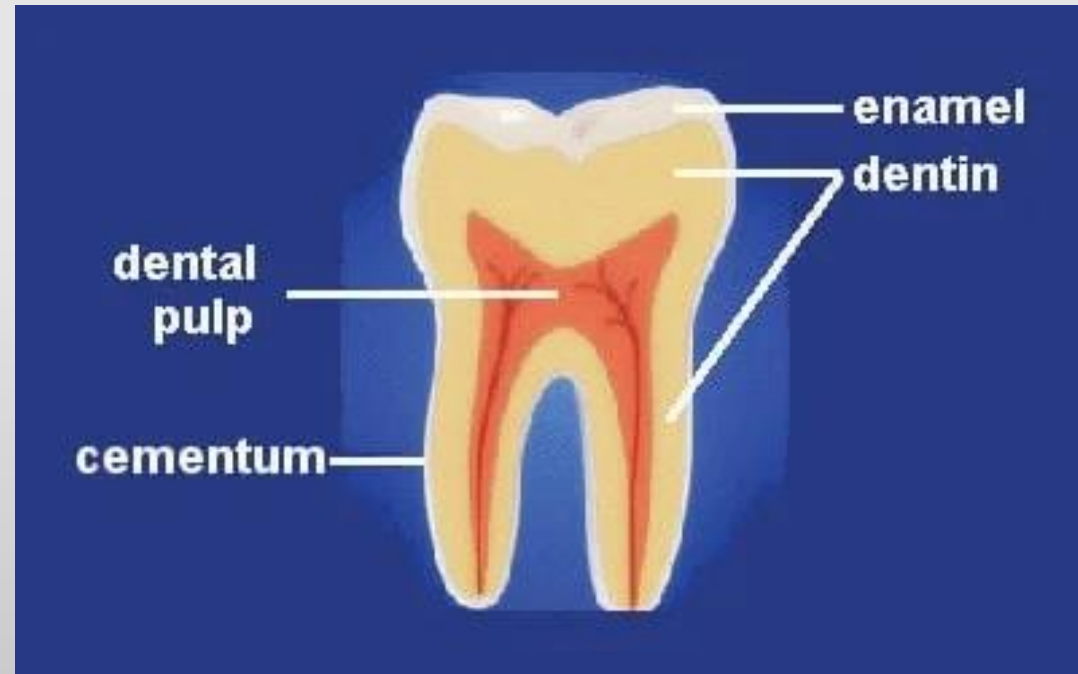# ENAMEL

- ❑ The crown is covered with a white outer layer called enamel, which protects the tooth.
- ❑ Enamel is the hardest substance in the body, but if it is damaged, it has very little ability to repair itself.
- ❑ It is designed to provide thermal insulation for a tooth and to protect the internal vital tissues from destruction.
- ❑ Enamel is susceptible to dental caries (cavities and decay), tooth wear, and acid dissolution.



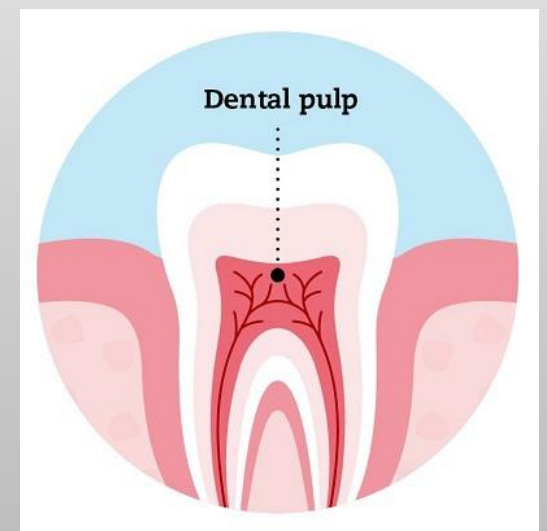
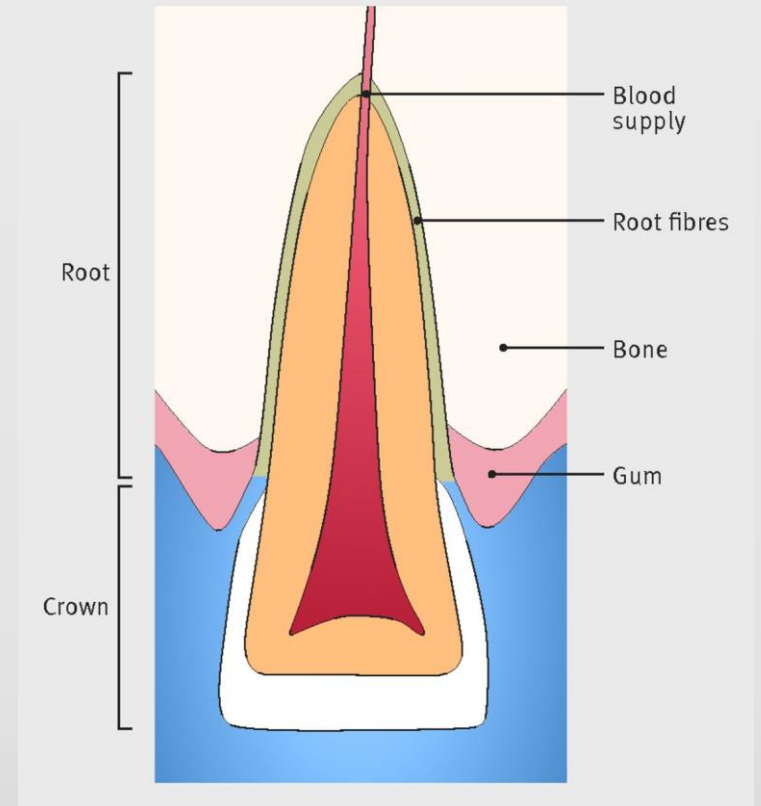
# DENTIN

- ❖ Just underneath the enamel is a layer called dentin.
- ❖ The part of the tooth where the dentin and enamel meet is called the DENTINO-ENAMEL JUNCTION (DEJ).
- ❖ Dentin is not as strong as enamel and sensitive to touch and temperature changes.
- ❖ Dentin surrounds the central chamber or "pulp chamber,"



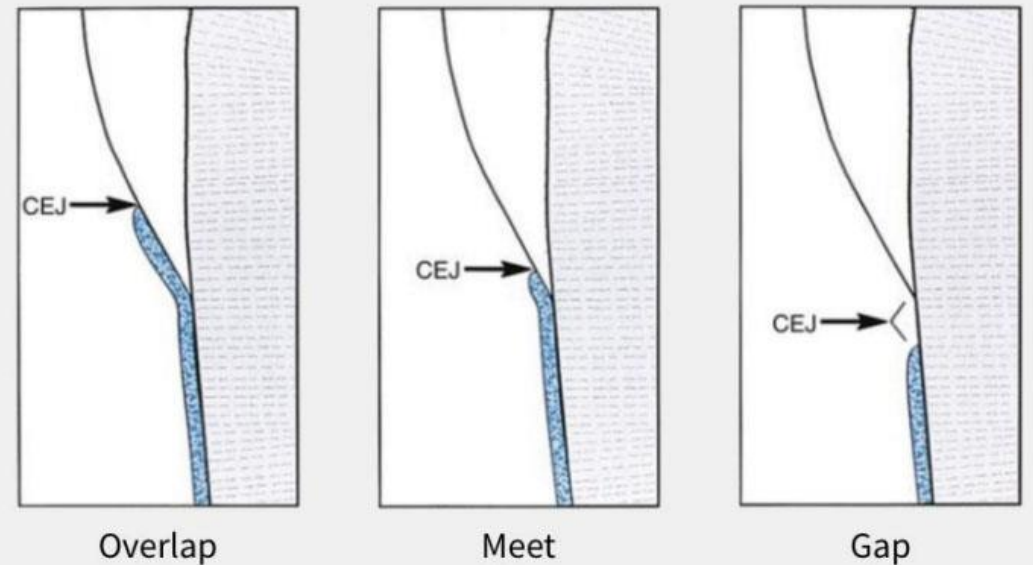
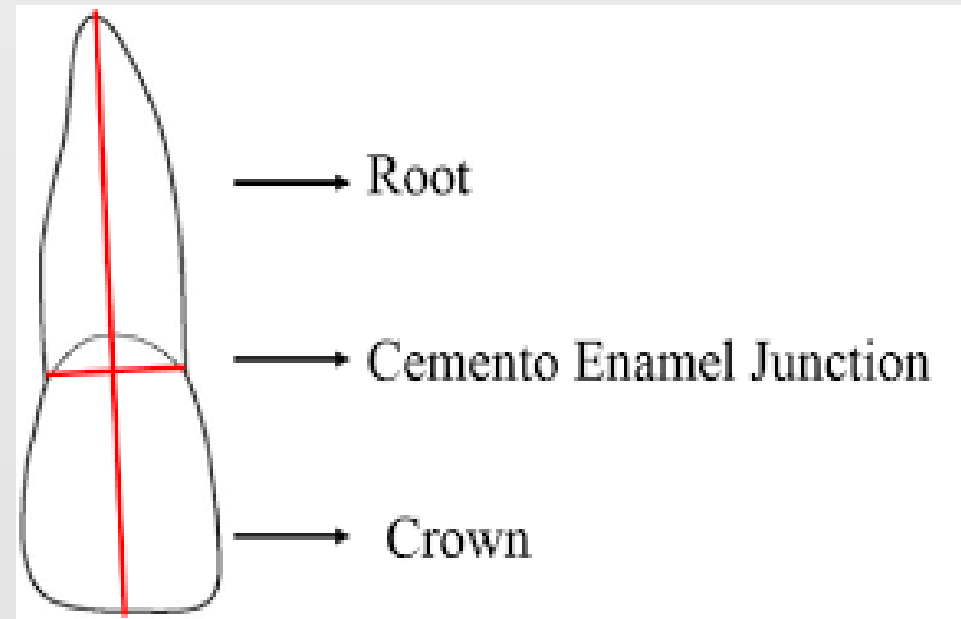
# Pulp

- ❖ The innermost layer of the tooth.
- ❖ The blood vessels and nerves enter the **PULP CHAMBER** through the root canals, which are also surrounded by dentin.
- ❖ The **PULP CAVITY** is the space within a tooth root that is filled with the vital dental pulp, a pink mass of innervated, vascular tissue.



# CEMENTO-ENAMEL JUNCTION

- ❑ The boundary where the anatomic crown meets the anatomic root is called the cemento-enamel junction (CEJ).
- ❑ Other terms for this boundary are the cervix of the tooth or cervical line.

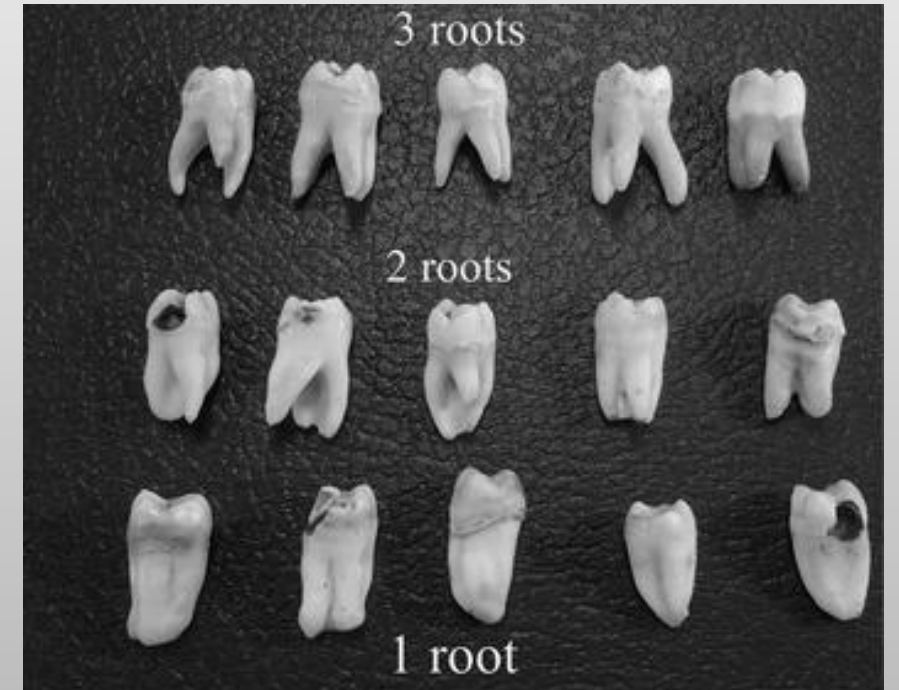
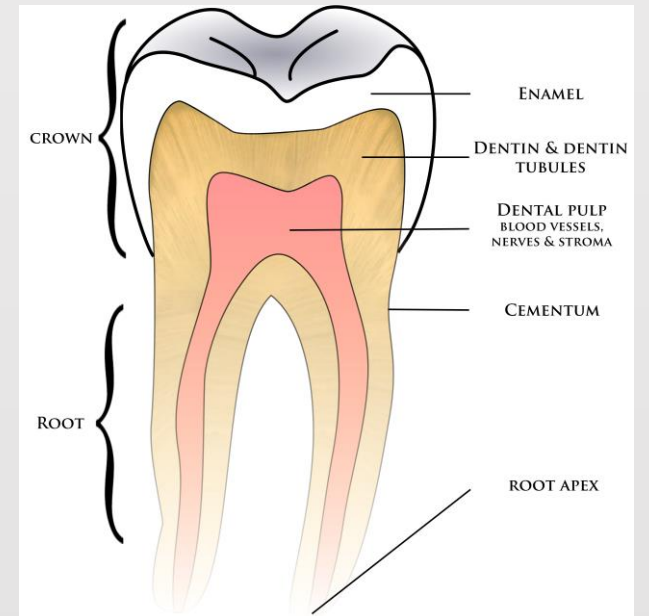




## THE ROOT

In the root portion of the tooth, dentin is also present, but instead of enamel, this dentin is covered by cementum, a thin bonelike substance.

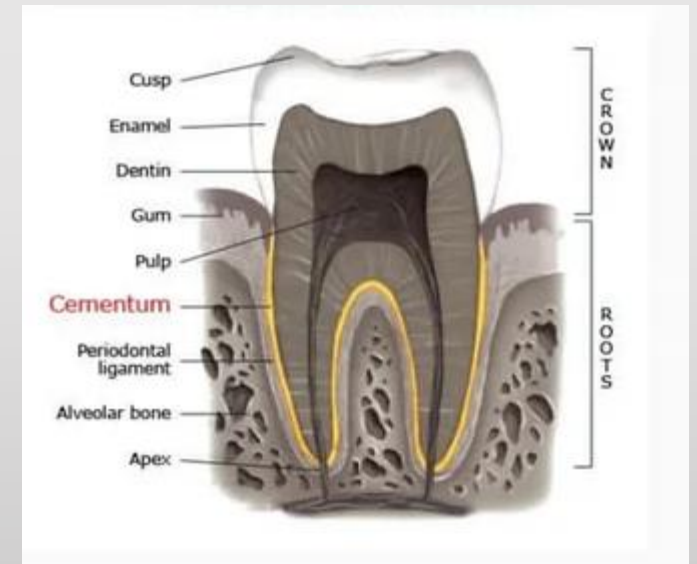
- ❖ The end of the root is called the apex.
- ❖ The apical foramen is the space at the apex through which blood vessels and nerves enter the dental pulp, and through which pulp infection may enter the alveolar bone.



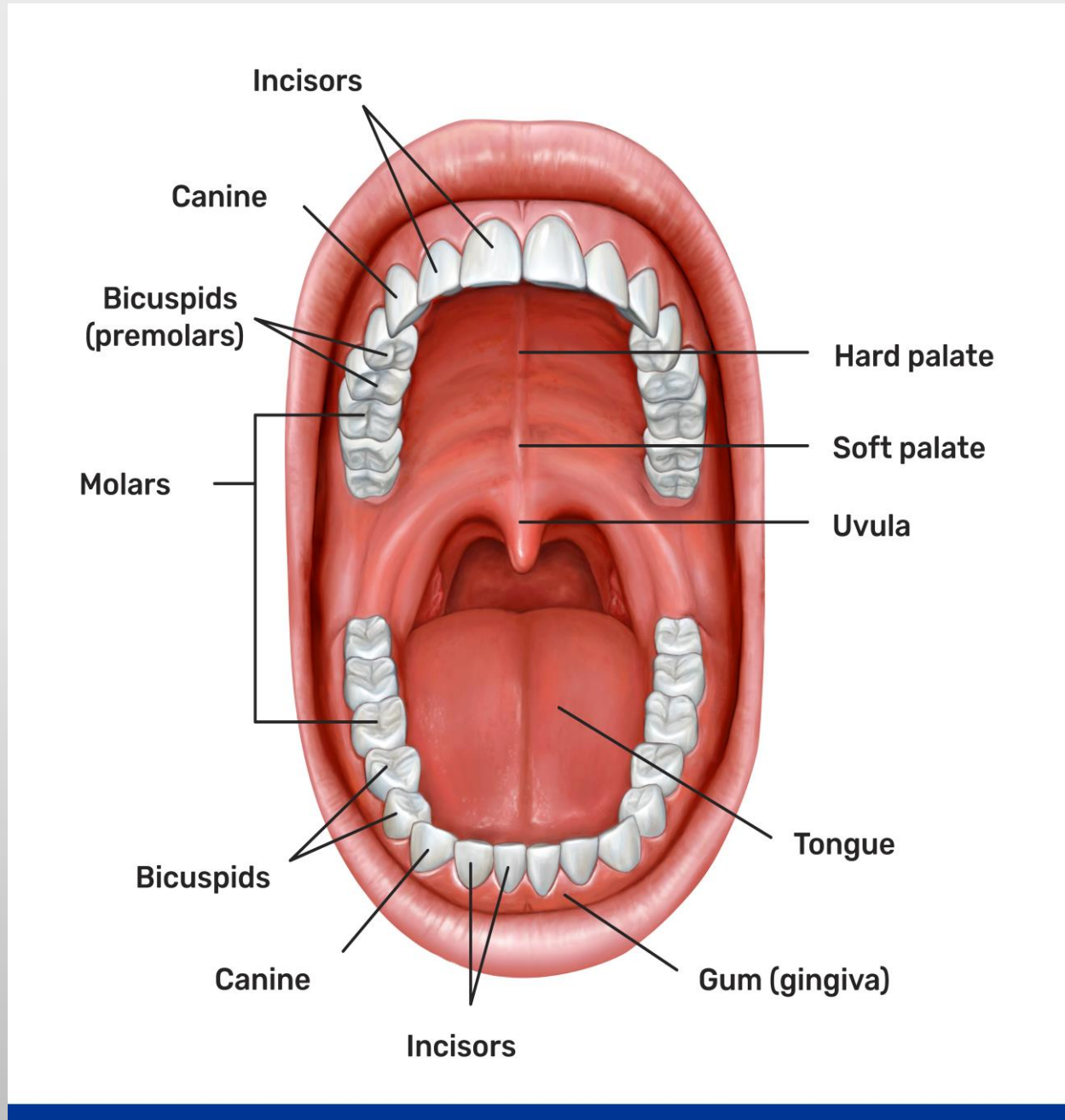
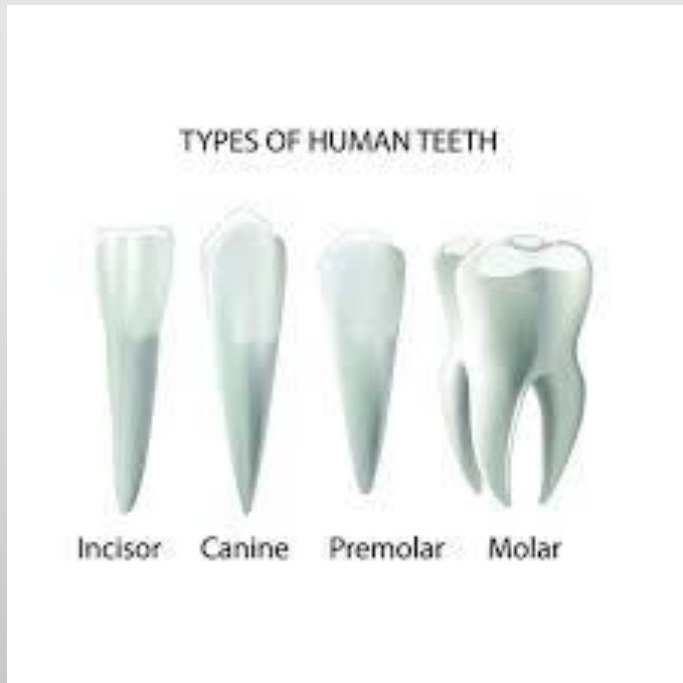# CEMENTUM

Cementum is surrounded by a membrane called the periodontal ligament that cushions the tooth. It attaches the cementum layer, and thus the whole tooth, firmly to the bone.

The anchorage support and protection of teeth is provided by various tissues collectively called the periodontium.



# Type of human teeth





لا تفكر في المذاكرة كعبء، بل  
انظر إليها كفرصة لتحقيق  
أحلامك

موقع ابدأ