

**Prolonged**  
 - severe type of pain  
 - vagus nerve → bradycardia  
 - AVN block  
 - Atrial enlargement

**shortens** :-  
 - sympathetic tone → tachycardia  
 - AV Nodal (Myxoma) (bradycardia)  
 - Wolff-parkinson white syndrome  
 WPWS

digitalis

PR interval

time of atrial depol. →  
 conduction of AV bundle

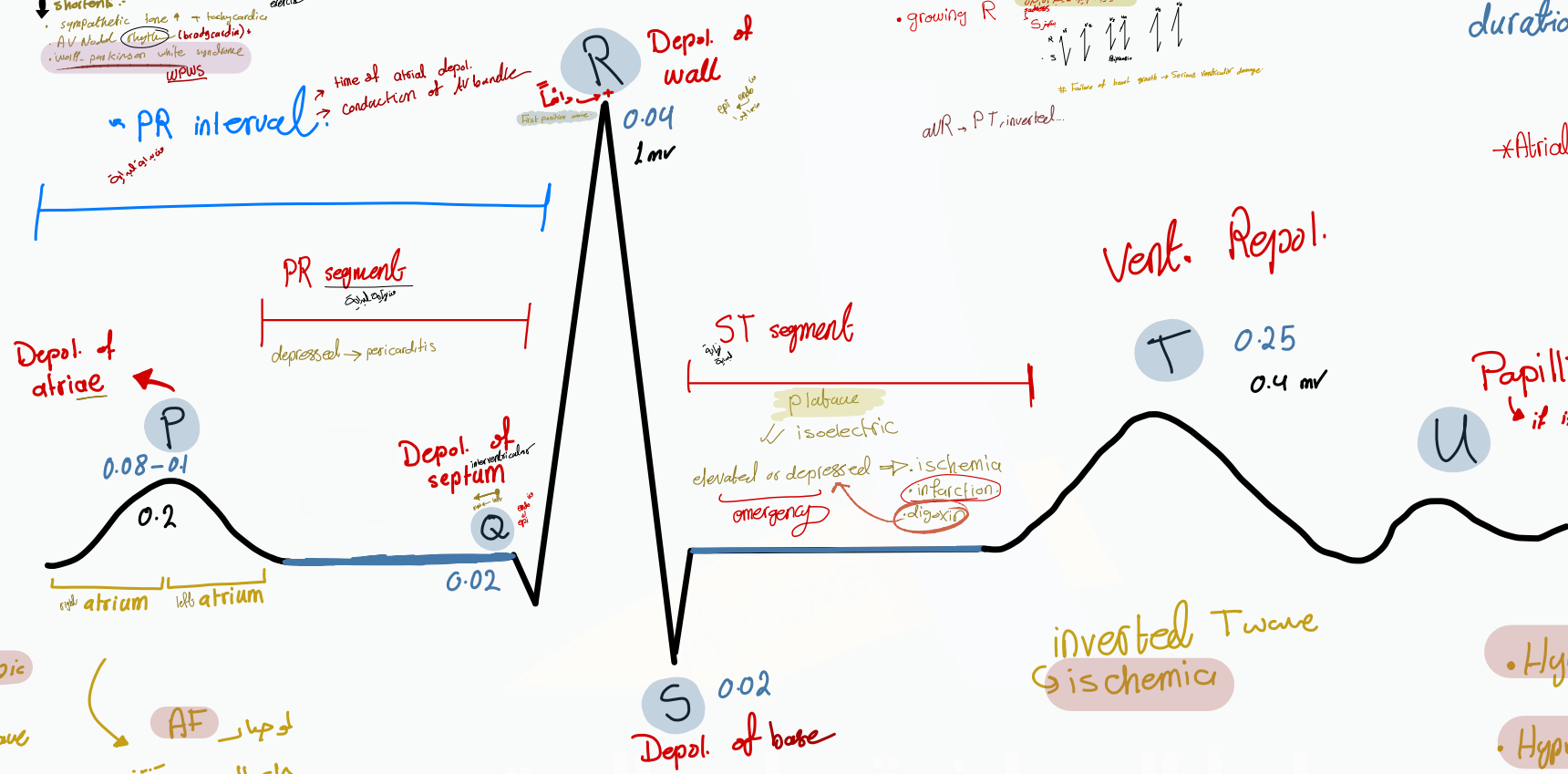
Depol. of wall  
 R 0.04  
 1mv

growing R  
 Factors of heart growth → serious ventricular damage  
 AVR → PT, inverted...

duration  $\propto \frac{1}{velocity}$

\*Atrial repolarization ⇒ NOT recorded

time →



atrial ectopic focus  
 → inverted P wave

AF  
 irregularly irregular waves

enlargement of atrium  
 ↳ disorder of tricuspid valve / mitral  
 ↳ enlargement of P wave



↑ QRS  
 ↳ Bundle branch block  
 - ventricular ectopic focus  
 - Hyperkalemia ↑K  
 - Depression  
 TCA overdose  
 Tricyclic antidepressant

inverted Twave  
 ↳ ischemic

Peaked wave  
 ↳ hyperkalemia

Flat  
 ↳ hypokalemia

\*T → Tent of K

- Hypokalemia ↓K<sup>+</sup>
- Hypercalcemia ↑Ca<sup>++</sup>
- Hyperthyroidism

Xanthine (Coffine)  
 stress

الموجودة