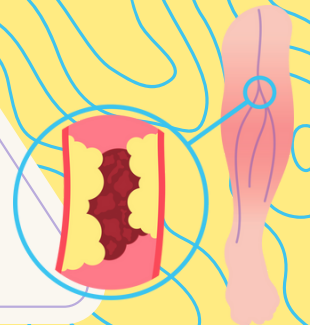


ANEURYSM & D.U.T

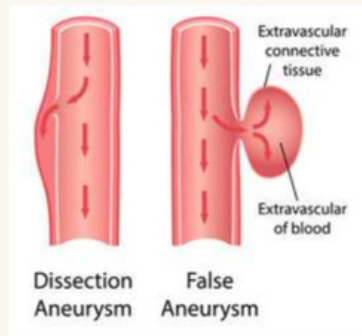
done by: Lujain alshrouf



<p>Aneurysm Definition</p>	<p>Localized, irreversible dilatation of blood vessel lumen that exceeds the diameter of the adjacent normal segment</p>
<p>True aneurysms</p>	<p>Involve all three layers of the artery (intima, media and adventitia) include:</p> <ul style="list-style-type: none"> • atherosclerotic and congenital vascular aneurysms. • ventricular aneurysms resulting from transmural myocardial infarctions. <div data-bbox="586 858 957 1225" data-label="Image"> </div> <p>“True” aneurysms are classified into:</p> <p>Saccular aneurysms: are discrete outpouchings ranging from 5 to 20 cm in diameter, often with a contained thrombus.</p> <p>Fusiform aneurysms : are circumferential dilations up to 20 cm in diameter; these most commonly involve the aortic arch, the abdominal aorta, or the iliac arteries.</p>

<p>False aneurysm</p>	<ul style="list-style-type: none"> • results when a wall defect leads to the formation of an extravascular hematoma that communicates with the intravascular space. <div data-bbox="586 1642 890 1950" data-label="Image"> </div>
------------------------------	--

Types:



Risk factors

- hyperlipidemia
- Elderly Man
- Infectious Diseases
- Smoking
- Atherosclerosis
- Gene mutations

Pathogenesis

- **Inadequate or abnormal connective tissue synthesis:**
 - mutations in TGF- β receptors result in defective elastin and collagen synthesis.
 - Loss of SMCs or change in the SMC synthetic phenotype: e.g. in :
Atherosclerosis and systemic hypertension , both of them leading to ischemia resulting in SMC loss .
- **Excessive connective tissue degradation:**
 - Increased matrix metalloprotease expression by macrophages in atherosclerotic plaque.

Clinical examples

- **Marfan syndrome** result from defective synthesis of the scaffolding protein fibrillin and progressive loss of elastic tissue leading to dilation.
- **Ehlers Danlos syndrome** result from defective in type III collagen synthesis leading to aneurysm formation

- Usually occur as a consequence of atherosclerosis , involving abdominal aorta (typically occur between the renal arteries and the aortic bifurcation)and common iliac arteries.
- occur more frequently in old smoker male (more than 50 years).

<p>Abdominal Aortic Aneurysm (AAA)</p>	<ul style="list-style-type: none"> • In the majority of cases, AAA results from ECM degradation mediated by proteolytic enzymes released from inflammatory infiltrates in atherosclerotic lesions <p>MORPHOLOGY</p> <p>The aneurysm sac usually contains bland, laminated, poorly organized mural thrombus, which can fill much of the dilated segment, usually extensive atherosclerosis is present</p> <ul style="list-style-type: none"> • Destruction of the tunica media which is thinned or no longer and replaced by hyalinized connective tissue. • The inflammatory reaction consists primarily of lymphocytes and macrophages. • Thrombus formation is invariably present on the luminal surface of
<p>Mycotic thoracic aortic aneurysm (MTAA)</p>	<ul style="list-style-type: none"> • Mycotic thoracic aortic aneurysm (MTAA) is an aneurysm of the aorta caused by infection of the vessel tissue through microbial inoculation of the diseased aortic endothelium. It is most commonly caused by bacteria or fungi. • The vascular intima usually is highly resistant to infection. However, MTAA can occur with: <ol style="list-style-type: none"> 1. Embolization of a septic embolus, usually as a complication of infective endocarditis 2. Extension of an adjacent suppurative process 3. Direct infection of an arterial wall by circulating organisms.
<p>Clinical consequences</p>	<p>The clinical consequences of AAA include the following:</p> <ul style="list-style-type: none"> • Ischemia following Obstruction of a vessel branching off the aorta (e.g., the renal, iliac). • Embolism of atheromatous material. Compression on adjacent structures . • Misdiagnosis as an abdominal mass . • Rupture into the peritoneal cavity leading to massive fatal hemorrhage (specially if larger than 5 cm).
<p>Thoracic Aortic Aneurysm</p>	<p>Usually associated with hypertension, bicuspid aortic valves, and Marfan syndrome. These aneurysms manifest with the following signs and symptoms:</p> <ul style="list-style-type: none"> • Compressive symptoms such as Respiratory or feeding difficulties due to airway or esophageal compression, respectively. • Persistent cough from irritation of the recurrent laryngeal nerves

<p>Thrombophlebitis and Phlebothrombosis</p>	<ul style="list-style-type: none"> ● Pain caused by erosion of bone (i.e., ribs and vertebral bodies) Aortic ● Thrombophlebitis is a condition in which inflammation of the vein wall has preceded the formation of a thrombus (blood clot). ● Phlebothrombosis is the presence of a clot within a vein, unassociated with inflammation of the wall of the vein. ● Thrombosis of deep leg veins (DVT) accounts for more than 90% of cases of thrombophlebitis and Phlebothrombosis
<p>Risk factors</p>	<ul style="list-style-type: none"> ● prolonged immobilization. ● congestive heart failure. ● pregnancy. ● oral contraceptive use. ● malignancy. ● obesity. ● male sex. ● age over 50 years.
<p>Signs and symptoms</p>	<ul style="list-style-type: none"> ● Hotness. ● Tenderness. ● Redness. ● Swelling. <p>-In many cases, the first manifestation of thrombophlebitis is a pulmonary embolus (serious clinical complication of DVT, resulting from fragmentation or detachment of the venous thrombus).</p> <p>Lab: D-DIMER?</p>
<p>Varicose Veins of the Extremities</p>	<ul style="list-style-type: none"> ● abnormally dilated tortuous veins produced by chronically increased intraluminal pressures and weakened vessel wall support. ● The superficial veins of the upper and lower leg typically are involved. <p>Risk factors:</p> <ul style="list-style-type: none"> • Obesity. • Pregnancy. • Familial.
	<p>Clinical Features of Varicose dilation result from venous valves incompetent :</p>

Clinical Features	<ul style="list-style-type: none">• Lower-extremity stasis.• Congestion,• Edema with secondary ischemic skin changes, including stasis dermatitis and ulcerations, poor wound healing and superimposed infections.• Pain.• Thrombosis.
Varicosities of Other Sites	<p>Liver cirrhosis related varices:</p> <ul style="list-style-type: none">• Gastroesophageal junction.• Rectum (forming hemorrhoids)• Periumbilical veins forming a caput medusae.

قَدْ تَخِيْطُ جِرَاحَ النَّاسِ وَأَنْتَ مُهْتَرِيٌّ! مَعَ
ذَلِكَ اسْتَمِرَّ! مَا جُورٌ عَلَيَّ أَنْفَاسِكَ إِنْ صَدَقْتَ