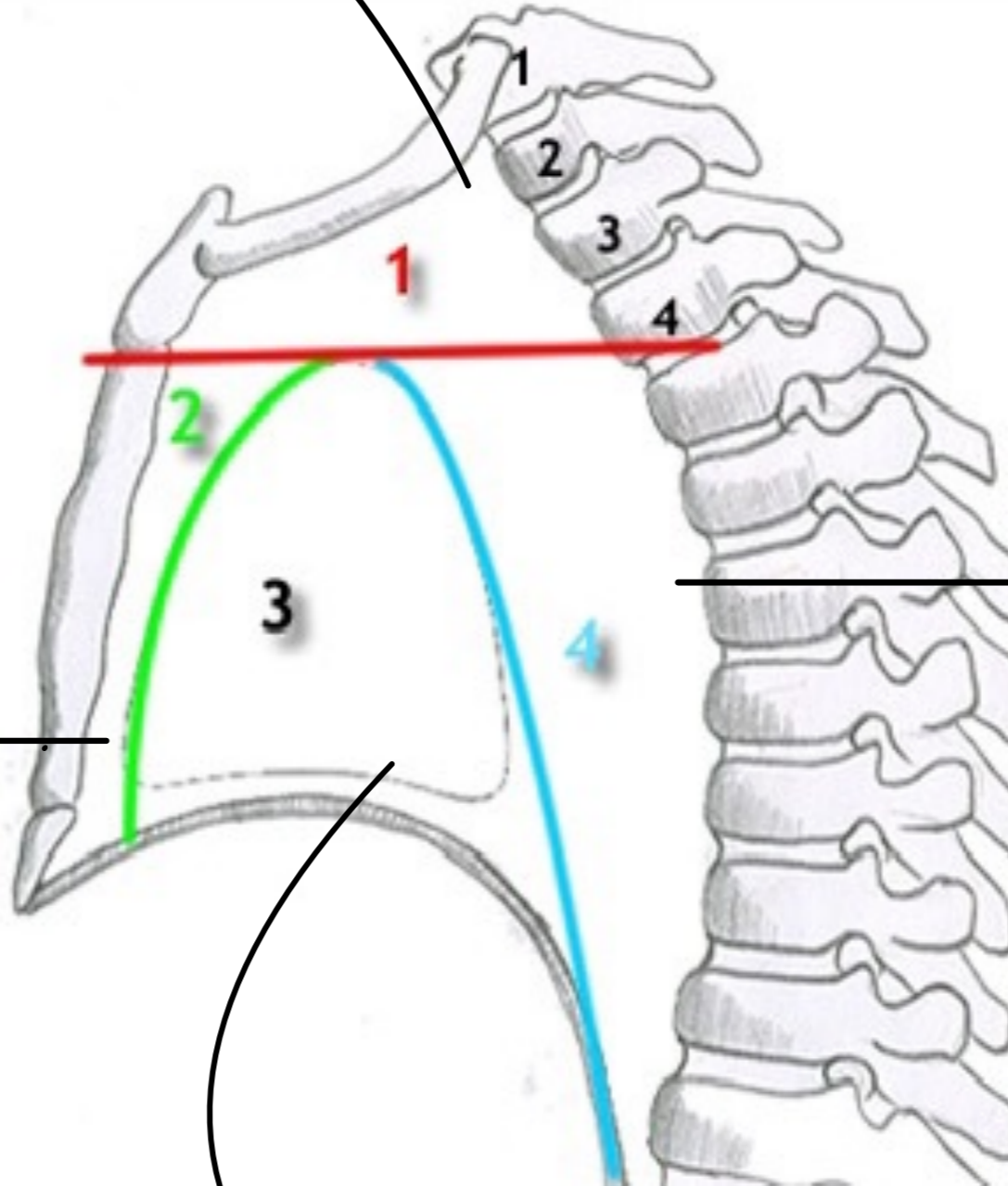


# Sup. Mediastinum

1. Sternohyoid & Sternothyroid M.
2. Thymus gland
3. Large Veins → RT & LT Brachiocephalic V.  
Upper half of SVC
4. Large Arteries → Arch of Aortic  
Brachiocephalic A  
IT CCA  
IT SCA
5. Oesophagus & Trachea
6. RT & LT vagus, phrenic N.
7. Thoracic duct.
8. Cardiac plexus
9. IT RLN
10. IT Sup. Intercostal V.



# Post. Mediastinum

1. Oesophagus & Oesophageal Nerve plexus
2. Descending thoracic aortic
3. Azygos, Hemiazygos, Acc. Hemiazygos V.
4. Thoracic duct
5. post. Mediastinal LN.
6. RT & Lt Vagus N.
7. Sympathetic chain.
8. prevertebral M.
9. Ant. longitudinal lig.

# Ant. Mediastinum

1. Thymus gland
2. Sup. & Inf. Sterno-pericardial lig.
3. Sternocostalis muscle
4. LN
5. loose alveolar CT.
6. Med. br. of Internal thoracic A.

# Mid. Mediastinum

1. Heart & pericardium
2. beginning of Aortic pulmonary trunk
3. Termination of SVC & IVC  
4 pulmonary V.