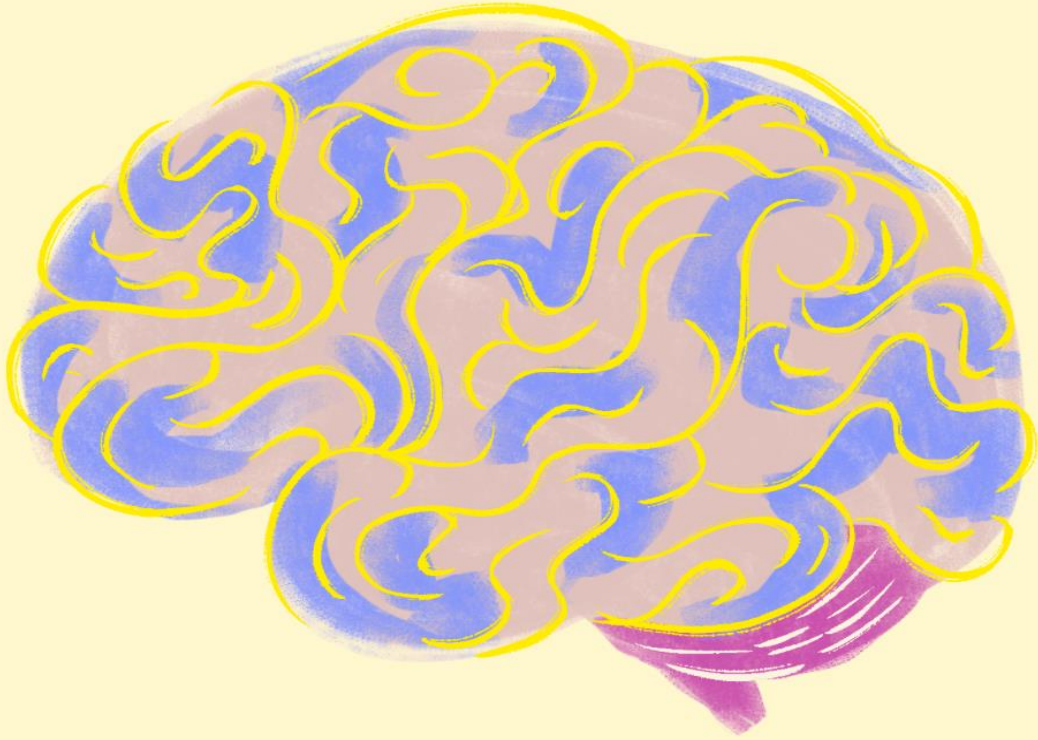


CNS ARCHIVE

Wateen - Lab



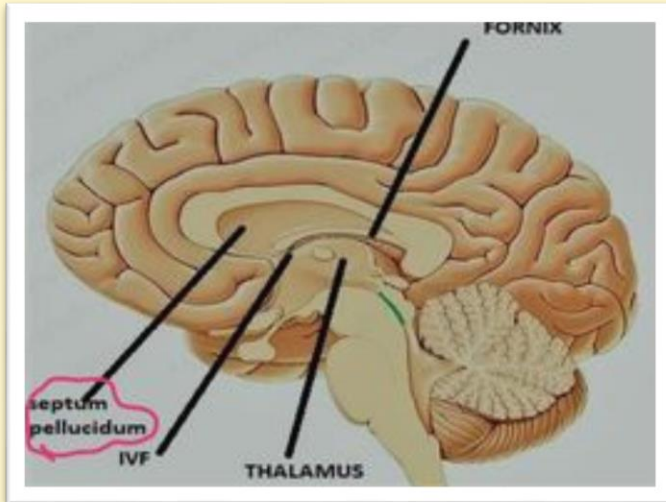
Done by ::

الفريق الأكاديمي



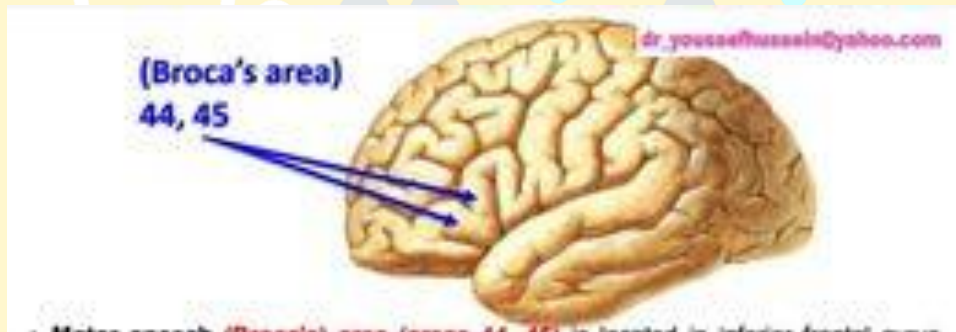
Q1: Identify the structure?

Answer : Septum pellucidum



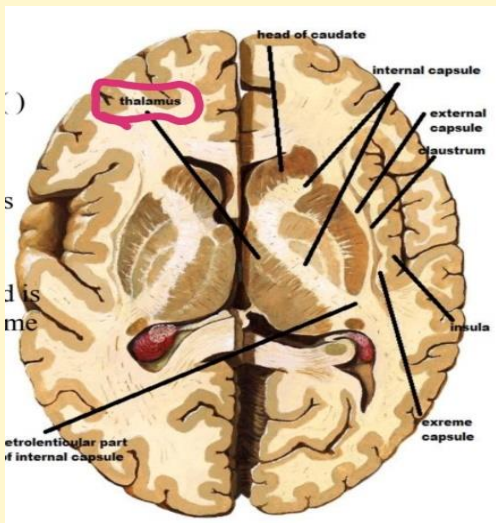
Q2: Identify the structure?

Answer : broca's area



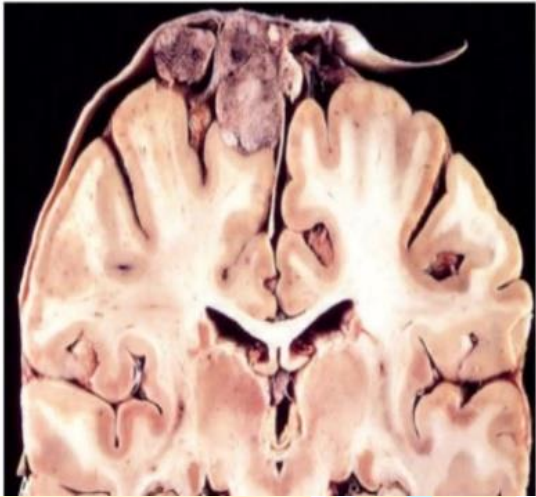
Q3: Identify the structure?

Answer : thalamus



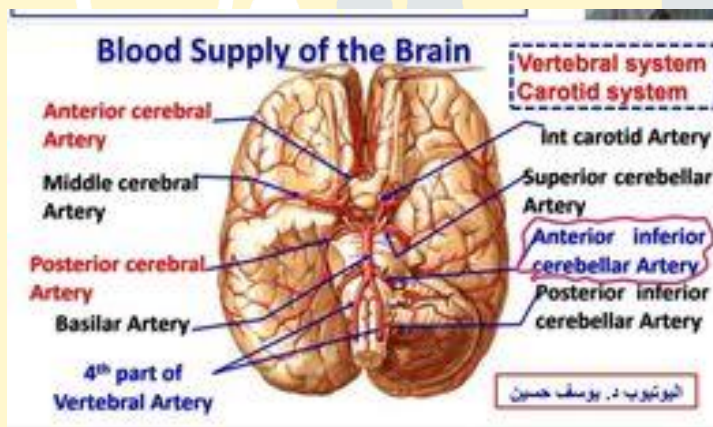
Q3: Identify the structure?

Answer : *Meningioma*



Q4: Identify the structure?

Answer : anterior inferior cerebellar artery

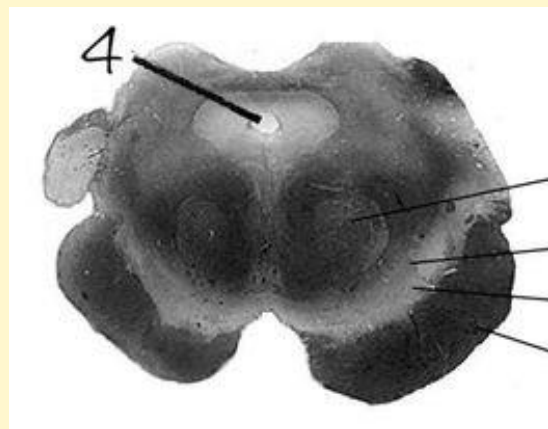


Q5: Identify the structure 4?

a. 4th ventricle

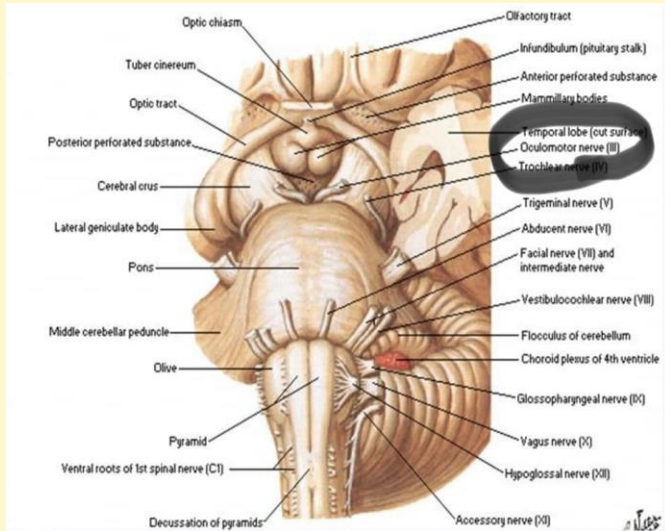
b. Cerebral aqueduct

c. Central canal



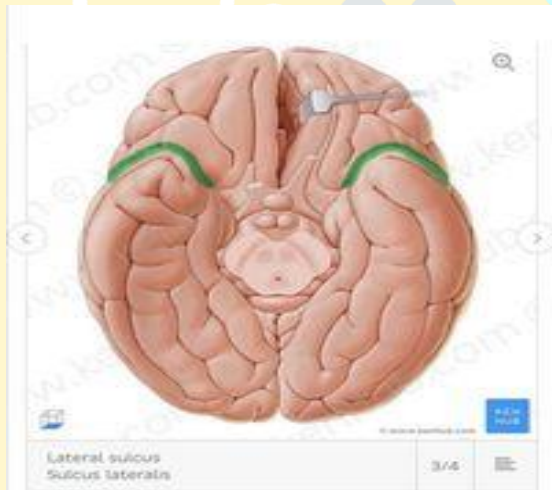Q6: Identify the structure ?

Answer : oculomotor nerve



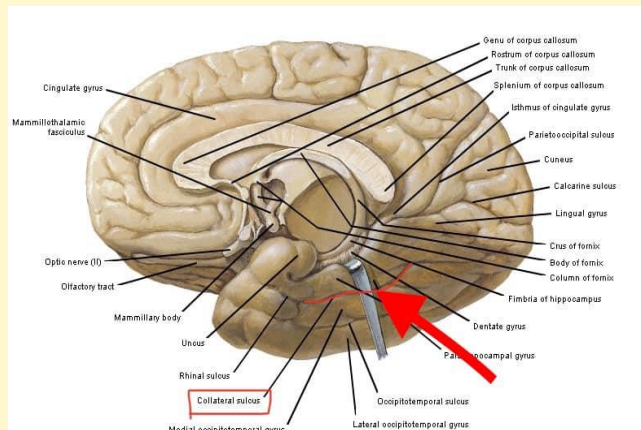
Q7: What is the artery in this sulcus ?

Answer : MCA



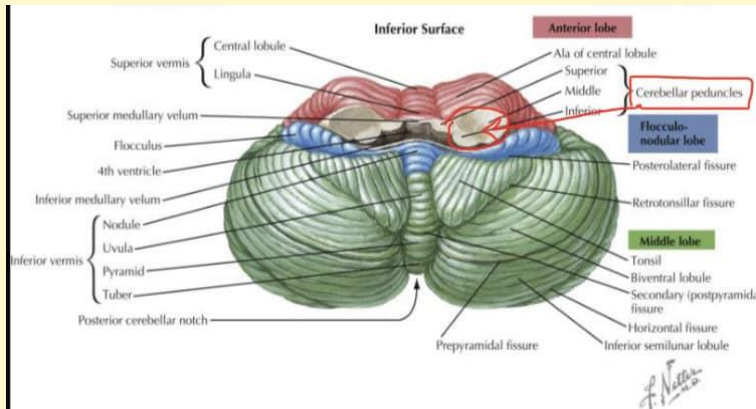
Q8: Identify the structure ?

Answer : collateral sulcus



Q9 : Identify the structure ?

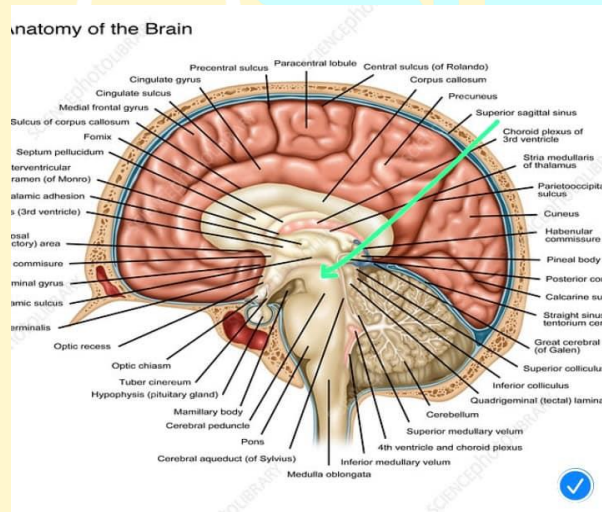
Answer : Cerebellar peduncles



Q10: The structure is :

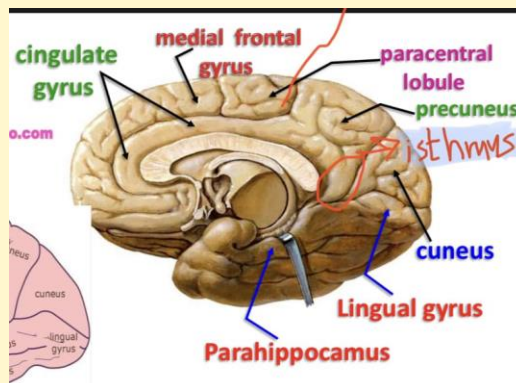
a. Superior cerebral peduncle ✓

b. Tectum



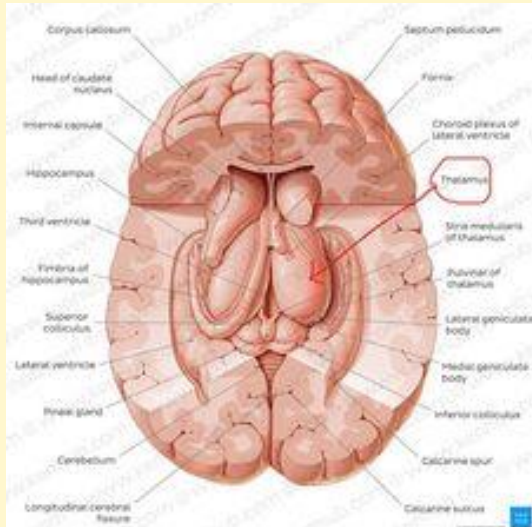
Q11: Identify the structure ?

Answer : isthmus



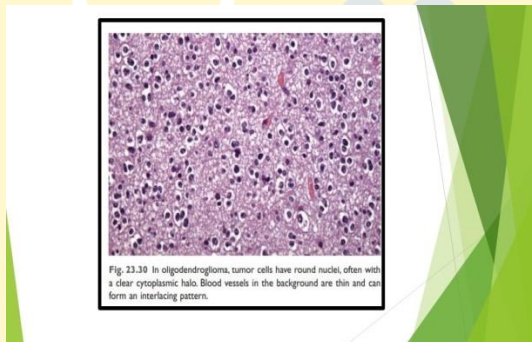
Q12: : Identify the structure ?

Answer : thalamus



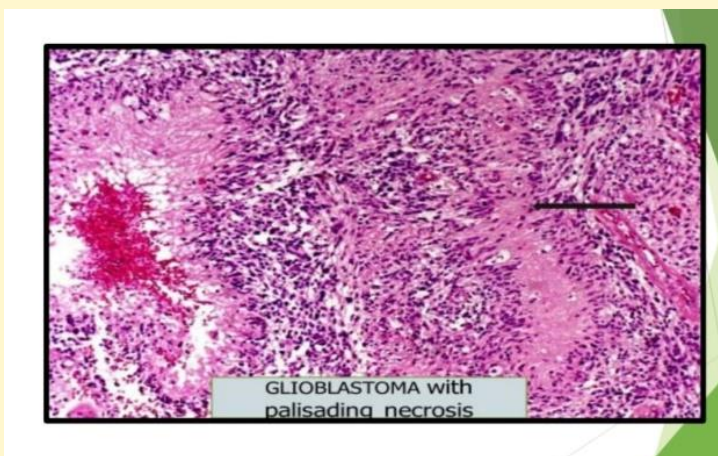
Q13: The type of tumor?

Answer :Oligodendroglioma

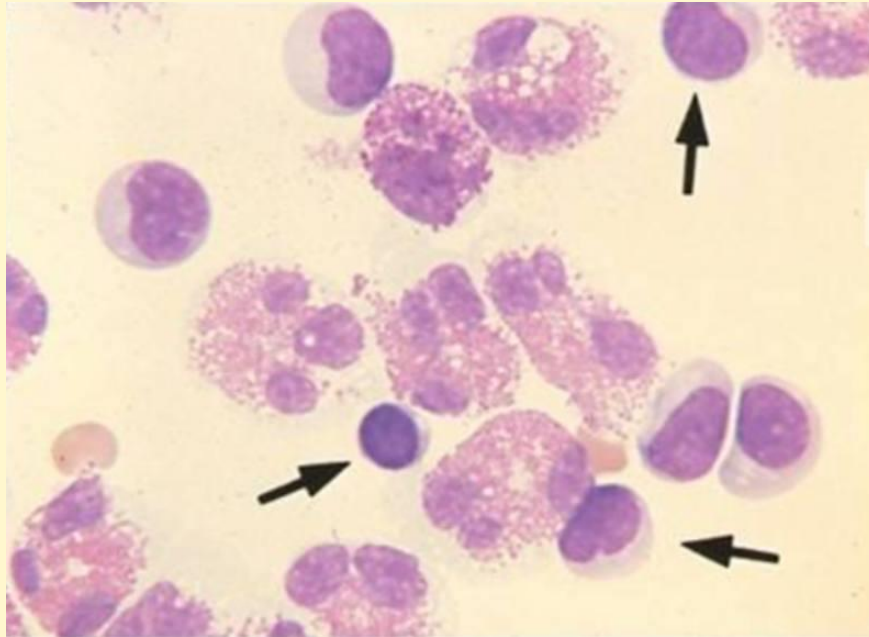


Q13: The type of the tumor ?

Answer :Glioblastoma




Q14: This CSF stained smear indicates? Select one:



- a. Viral infection.
- b. Parasitic infection.
- c. Bacterial infection.
- d. Tubercular infection.
- e. Bacterial infection and tubercular infection.

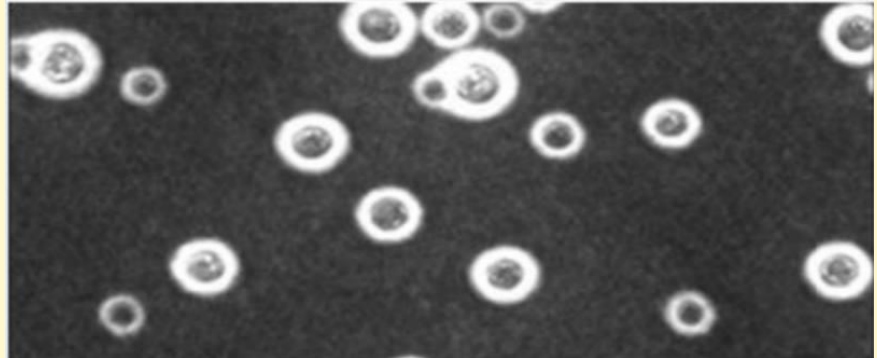
Q15: The tube of CSF that should be submitted to count RBs and WBCs is the tube number? Select one:

- a. 1.
- b. 2.
- c. 3.
- d. 1 or 2.
- e. Any tube.



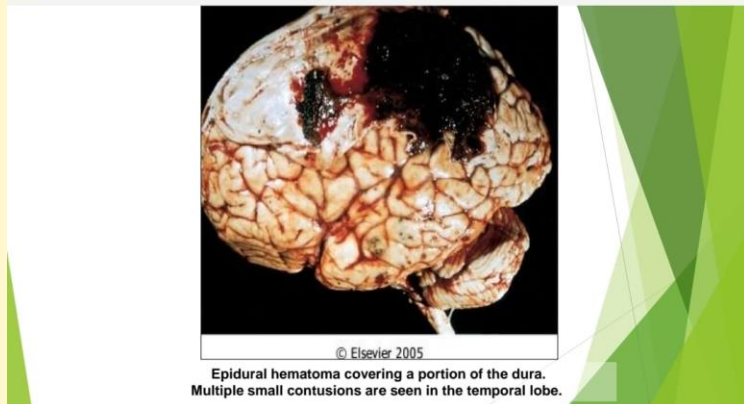
Q16: This microscopic image indicates? Select one:

- a. M. tuberculosis.
- b. S. pneumonia.
- c. S. aureus.
- d. N. meningitides.
- e. C. neoformans.



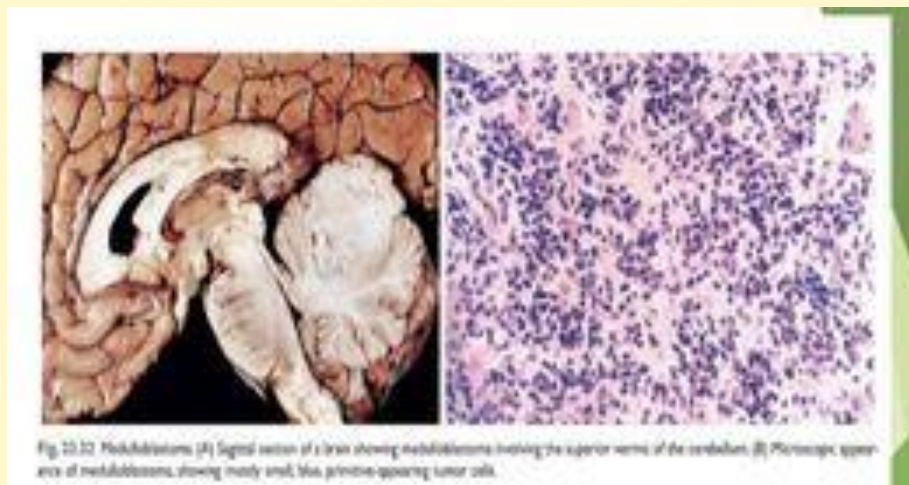
Q17: Artery that damage and cause this hemorrhage is :

Answer : middle meningeal artery

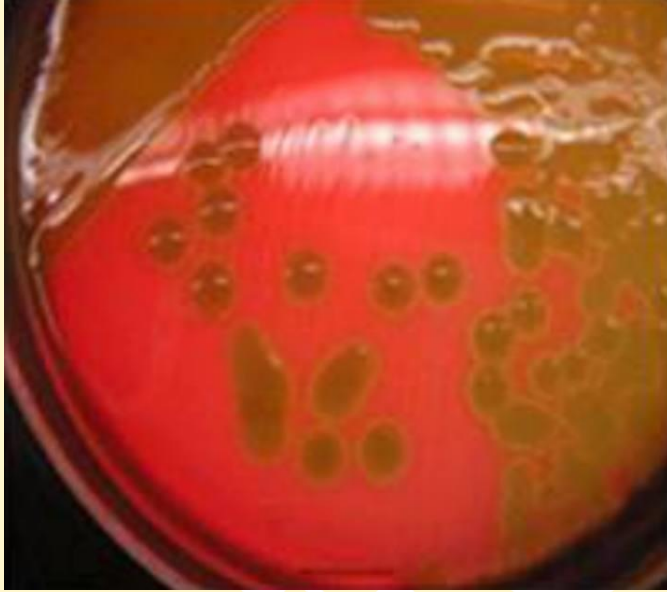


Q18: favorable prognosis of this tumor is ?

Answer : WNT+



Q19: This CSF growth pattern indicates? Select one:



a. M.tuberculosis.

b. S.pneumoniae.

c. S.aureus.

d. N.meningitides.

e. C.neoformans.

Q20: This pattern of infection indicates? Select one:

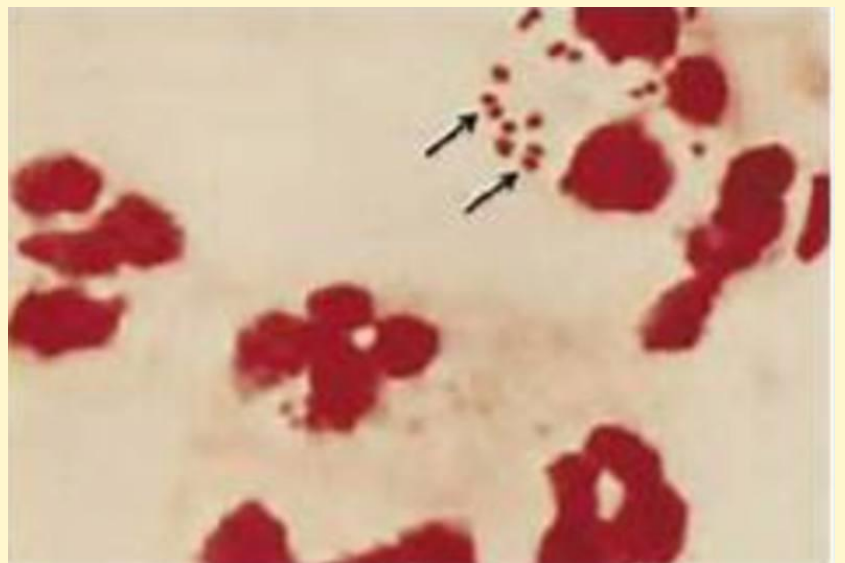
a. N. meningitidis.

b. S. pneumoniae.

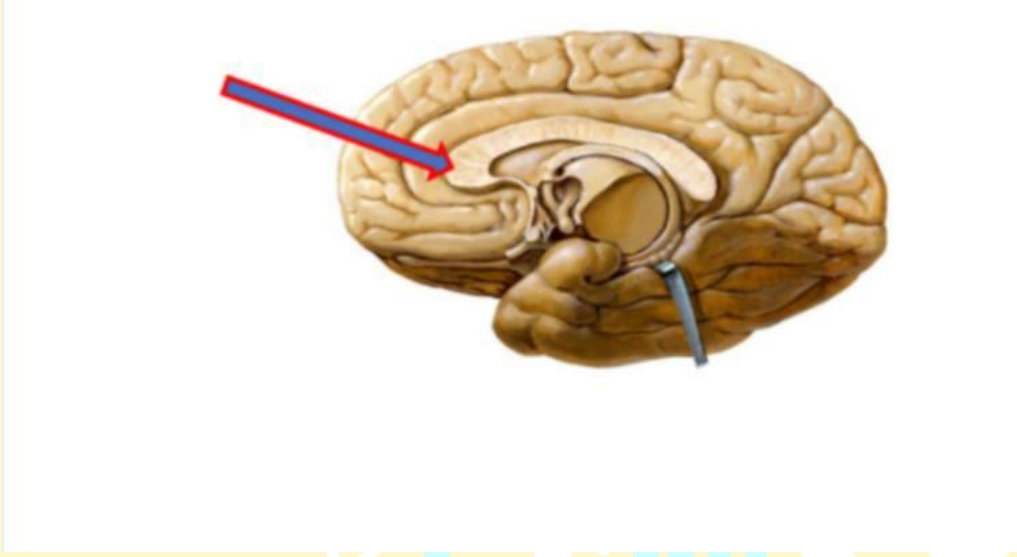
c. S. aureus.

d. L. monocytogenes.

e. C. neoformans.



Q21: What is the labeled structure? Select one:



- a. Body of fornix
- b. Genu of corpus callosum
- c. Splenium of corpus callosum
- d. Septum pellucidum
- e. Thalamus

اللّهم ليس بجدي و اجتهادي و إنّما
توفيقك و عونك يا معين