



GIT – Anatomy

Archive

Lecture"1"

Oral Cavity

Done by :

عُبادَةُ الخوالدة

Anatomy'Lecture"1"

1.)One of the following is true according to the sublingual papilla:

- A.)It receives opening from the Sublingual duct.
- B.)It receives opening from the Parotid duct.
- C.)It receives opening from the Submandibular duct.
- D.)It lies lateral to Sublingual fold.
- E.)It lies in the vestibule opposite to the upper 2nd molar tooth.

Answer:"C.)It receives opening from the Submandibular duct."

2.)Which muscle that form the Palatine Aponeurosis:

- A.)Levator Palati.
- B.)Platopharyngeus Muscle.
- C.)Musculus Uvula.
- D.)Palatoglossus Muscle.
- E.)Tensor Palati.

Answer:"E.)Tensor Palati."



GIT – Anatomy

Archive

Lecture"2"

Tonge

Done by :

عُبادَةُ الخوالدة

Anatomy'Lecture"2"

1.)Taste sensation of the tip of the tongue by:

- A.)Hypoglossal nerve.
- B.)Chorda tympani.
- C.)Glossopharyngeal nerve.
- D.)Lingual nerve.
- E.) Vagus Nerve.

Answer:"B.)Chorda tympani."

2.) The main lymphatic drainage to the tip of the tongue :

- A.)Submental lymph nodes.
- B.)Sublingual lymph nodes.
- C.)Submandibular lymph nodes.
- D.)Deep cervical lymph nodes.
- E.)Deep lingual lymph nodes.

Answer: "A.)Submental lymph nodes."

Anatomy'Lecture"2"

3.)One of the following is true:

- A.)Sensory nerve of the anterior 2/3 of the tongue is Glossopharyngeal.
- B.)Nerve of General sensation of the Anterior 2/3 is Chorda Tympani.
- C.)Motor nerve of the Tongue Muscle is Accessory Nerve.
- D.)Vallate Papilla are supplied by Glossopharyngeal Nerve.
- E.)Most lower part of the Pharyngeal part is supplied by Glossopharyngeal.

Answer:"D.)Vallate Papilla are supplied by Glossopharyngeal Nerve."

An anatomical illustration of the human digestive system, showing the esophagus, stomach, and small and large intestines in a light blue and pink color scheme, overlaid on a faint human silhouette.

GIT – Anatomy

Archive

Lecture(3)

submandibular & sublingual glands

Done by :

Banan Al-khawaldeh

Anatomy-Lecture(3)

1.Sublingual papillae represent which one of the following :

- A- Opening of the sublingual duct.
- B- Opening of the submandibular duct.

Answer: B

2. Which structure of the following not related to medial surface of submandibular gland:

- A- Lingual nerve.
- B- Hyoglossus muscle.
- C- Mylohyoid muscle.
- D- Hypoglossal nerve.
- E- Sublingual ganglia.

Answer: E

3.Which of the following isn't found in the submandibular gland?

Centro-acinar cells

4.Regarding submandibular duct, which is false?

- A. Lateral relation is sublingual gland
- B. It has trible relations to the hypoglossal nerve
- C. It ends in the sublingual papilla
- D. Medial relation is genioglossus muscle
- E. Its length 5 cm

ANSWER: B



GIT – Anatomy

Archive

Lecture(4)

The parotid region

Done by :

Aya Ayman

Anatomy-Lecture(4)

1.All the following structures emerge from the anterior border of the parotid gland EXCEPT?

- A. Zygomatic branch of the facial nerve
- B. Transverse facial artery
- C. Cervical branch of the facial nerve
- D. Parotid duct
- E. Buccal branch of the facial nerve

ANSWER:C

2.All The following structures are related to the anteromedial surface of the parotid gland EXCEPT:

- A. the masseter muscle
- B. the facial nerve
- C. the ramus of the mandible
- D. the maxillary artery
- E. the medial pterygoid muscle

answer: b

*3.The most superficial part of parotid gland is :

- A- Facial artery.
- B- Facial nerve.
- C- Facial vein.
- D- Retromandibular vein.
- E- External carotid artery.

Answer: B

Anatomy-Lecture(4)

4. Which carry the parasympathetic nerve supply of parotid gland:

- A. Great auricular
- B. Facial nerve
- C. Middle meningeal plexus
- d. Glossopharyngeal

Answer:d

Note: it is the same as when we say the Preganglionic fibers

*5. One is wrong about parotid gland ?

- a. Nuclei are rounded & central
- b. Serous demilune
- c. Lined e short pyramidal cells
- d. Narrow lumen

Answer:b



GIT – Anatomy

Archive

Lecture"5"

Pharynx

Done by :

عُبادَةُ الخوالدة

Anatomy'Lecture"5"

1.)All of the following are features of nasopharynx except :

- A.Opening of auditory tube.
- B.Tubal elevation.
- C.Pharyngeal tonsil.
- D.Salpingopharyngeal fold.
- E.Palatoglossal fold.

Answer:"E"

2.).Which ofthe following is a false relationship for a superior constrictor muscle :

- A.palati muscles.
- B.levator palati.
- C.Inferior laryngeal nerve.
- D.facial artery.

Answer:"C"

Anatomy'Lecture"5"

3.)All ofthe followings are features ofthe nasopharynx except?

- A. Pharyngeal recess.
- B. Palatoglossal fold.
- C.Opening of Eustachian tube.
- D. Salpingo-pharyngeal fold.
- E. Tubal elevation.

Answer:"B"

4.)One is correct about tonsillar fossa:

- A.Floor / superior constrictor.
- B.Anterior / palatopharyngeal arch.
- C.Posterior /palatoglossal arch.
- D.Roof /middle constrictor.

Answer:"A"



GIT – Anatomy

Archive

Lecture(6)

Esophagus and stomach

Done by :

Razan fawwaz

Anatomy-Lecture(6)

1. One of the following is incorrect regarding the esophagus

A- Muscular tube.

B- Begins at T6 as a continuation of pharynx.

G- Ends at T10.

D- Back to midline at level of T4.

E- Pharyngoesophageal junction is the most tight junction.

ANSWER: C

2. Which one is false :

A. Esophagus has constriction at 22.5 from incisor teeth due to aortic arch

B. Esophagus has constriction at 40 from incisor teeth due to diaphragm

C. Esophagus has constriction at 15 from incisor teeth due to Pharyngo oesophageal junction

D. Esophagus has constriction at 27.5 from incisor teeth due to aortic arch

ANSWER: D

Anatomy-Lecture(6)

3. The esophagus shows a constriction 22.5 cm from the incisors due to?

- A. Aortic arch
- B. Diaphragm
- c. left main bronchus
- D. Inferior vena cava
- E. left atrium

ANSWER:A

4. All the following structures form the stomach bed EXCEPT?

- A. Liver
- B. Left suprarenal gland
- c. Left kidney
- D. Spleen
- E. Body of the pancreas

ANSWER: A

5. Stomach?

- A. The splenic artery supplies the lesser curvature
- B. left and right gastric arteries

ANSWER:B

Anatomy-Lecture(6)

6. The abdominal part of the esophagus is?

Supplied by the celiac trunk

اللهم استعملنا ولا تستبدلنا واجعل لنا اثرا جميلا ☺
يذكر من خلفنا ... لا تنسونا من صالح دعائكم
اللهم فرج على اخواننا في غزة كربتهم وكن معهم يا عزيز يا جبار



GIT – Anatomy

Archive

Lecture(7)

peritoneum

Done by :

Aya Ayman

Anatomy-Lecture(7)

1. The mesentery that divides the infra-colic compartment into right and left:

The mesentery of the small intestine

2. Behind the right lobe of the liver and in front of the right kidney is the?

- A. Right infracolic space
- B. Morison Pouch
- C. Right anterior subphrenic space
- D. Left anterior subphrenic space
- E. Lesser sac

ANSWER: B

مهم الدكتور حكاية بالاب وركز عليه 😊

3. In an open surgery of the abdomen, the doctor was dealing with stomach and he pass his finger behind it by getting inside a peritoneal opening. Considering the entrance to the space posterior to stomach, what is the structure posterior to the doctor's finger within this opening (entrance)?

- A. Duodenum
- B. Portal artery and vein
- C. Caudate process of caudate lobe
- D. Inferior vena cava
- E. Head of pancreas

answer : d

Anatomy-Lecture(7)

4. A surgeon performed an operation and put his finger in epiloic foremen, the posterior relation is:

- a. First part of duodenum
- b. inferior vena cava
- c. hepatic artery
- d. portal vein

Answer: b

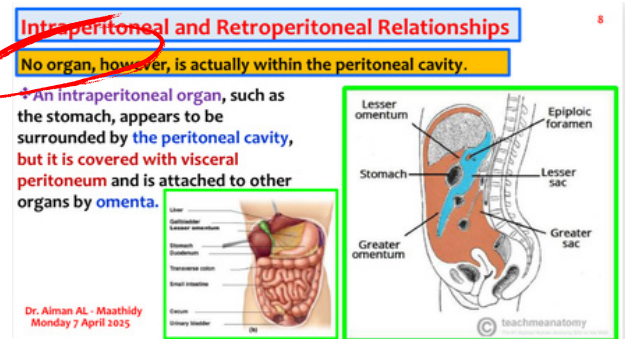
انذكر مرتين ارشيف وبرضو الدكتور ركز وذكرها بأكثر من محاضرة

5. Which one is false : Which one is false:

- a. Some organs within peritoneal cavity
- b. The peritoneum is a thin serous membrane
- c. The peritoneal cavity is the largest cavity in the body
- d. the peritoneal fluid, which lubricates the surfaces of the peritoneum and allows free movement between the viscera.

Answer: a

هاد حرفي من السلايد



Anatomy-Lecture(7)

6. One of the following is correct regarding the relations of the lesser sac :

- A- Small and lies behind the duodenum.
- B- It's left margin formed by the splenicorrenal ligament.
- C- It extends downward as far as diaphragm.
- D- It's opening bounded inferiorly by inferior vena cava.
- E. Separates the stomach from anterior border of the pancreas.

Answer: E

هذا السؤال وارد فيه الخيار الاول لأنه فعلاً وراء اول جزء منه بس الاول مش الـ duodenum كامل وهذا اللي رجح الاختيار الاخير



GIT – Anatomy

Archive

Lecture(8)

small intestine

Done by :

Aya Ayman

Anatomy-Lecture(8)

1. The following relations of the third part of the duodenum are true except?

- A. Posteriorly: The left ureter
- B. Anteriorly: The root of the mesentery of the small intestine
- C. Posteriorly: The inferior vena cava and the aorta
- D. Superiorly: The head of the pancreas
- E. Anteriorly: The superior mesenteric vessels

ANSWER: A

2. The correct statement regarding small intestines is:

- A. Jejunum has more plicae circularis than duodenum or ileum
- B. Peyer's patches are mainly found in ileum along antimesenteric border
- C. Tenia coli are longitudinal structures on wall of small intestines
- D. The entire small intestines have mesentery unlike large intestines
- E. Ileum wall is thicker than jejunum wall

Answer: B

Anatomy-Lecture(8)

3. Which of the following is correct regarding third part of the duodenum :

- A- Cross by superior mesenteric vessels.
- B- Runs upward and to the left to the duodenojejunal flexure.
- C- Related posteriorly to the right hilum of the kidney.
- D- Begins at the pylorus.
- E- Related superiorly to the epiploic foramen.

Answer: A

4. All of the following is a true difference between jejunum and ileum:

- A- Ileum form only one or two arcades.
- B- Jejunum is thicker walled and wider bored than ileum.
- C- The jejunal mesentery is attached below and to the right of the aorta.
- D- Ileum lies in the upper part of peritoneal cavity while jejunum in the lower part.
- E- The plicae circularis absent in the middle part of ileum.

Answer: B



GIT – Anatomy

Archive

Lecture(9)

THE LARGE INTESTINE

Done by :

zaid freihat

Anatomy-Lecture(9)

1) The sigmoid colon has the following features except?

- A. Having the teniae coli
- B. Retroperitoneal organ
- C. End at level of the third sacral (S3) vertebra
- D. Posterior to the urinary bladder in the male
- E. The veins drain into the inferior mesenteric vein

ANSWER: B

2) One of the following is not posterior relation to ascending colon : One of the following is not posterior relation to ascending colon :

- a. ilioinguinal nerves
- b. femoral nerve
- c. quadratus lumborum
- d. lower pole of the right kidney

Answer : b

3) The most common site of the appendix is :

- .A- Retrocecal
- .B- Postileal
- .C- Perileal
- .D- Subcecal
- .E- Pelvic

Answer: A

4) Appendix. Select the false statement of the followings?

- A. The appendicular vein drains eventually to portal vein
- B. The lymph vessels drain into the superior mesenteric nodes
- C. Has a complete peritoneal covering
- D. Attached to the posteromedial surface of the cecum
- E. The appendicular artery is a branch of the anterior cecal artery

ANSWER: E