



GIT- pathology

Archive

Lecture 1

DISEASE OF THE ORAL CAVITY
AND ESOPHAGUS

patho - lecture (1)

1. One of the following is characteristic of esophageal infection caused by CMV :

- A- Nuclear and cytoplasmic inclusion in capillary endothelium and stromal cells.
- B- Central part of ulcer deeper than peripheral part.
- C- Nuclear viral inclusion in biopsy.
- D- Coudry bodies A showing in histological pattern.
- E- Composed of matted fungal hyphae and inflammatory cells.

Answer: A

2. Esophageal stenosis occurs due to :

- A- Posterior displacement of tracheoesophageal septum.
- B- Anterior displacement of tracheoesophageal septum.
- C- Distal displacement of tracheoesophageal septum.
- D- Proximal displacement of tracheoesophageal septum.

Answer: A

patho - lecture (1)

3. The most common malignant salivary gland tumor is?

- A. Adenoid cystic carcinoma.
- B. Warthin tumor.
- C. Pleomorphic adenoma.
- D. Mucoepidermoid carcinoma.
- E. Adenocarcinoma.

ANSWER: D

4. All of the following regarding achalasia are true except?

- A. Primary causes are more common.
- B. May result in functional esophageal obstruction.
- C. Decreased lower esophageal sphincter (LES) tone.
- D. Esophageal aperistalsis.
- E. patient could present with epigastric pain

ANSWER: C

5. Regarding tracheoesophageal fistula, which is false?

- A. Proximal part of esophagus continues with trachea and distal part ends as blind sac.
- B. Proximal and distal parts of esophagus continue with trachea by single tube.
- C. Proximal part of esophagus ends as a blind sac and distal part continues with the trachea.
- D. Proximal and distal parts of esophagus continue together.
- E. Proximal and distal parts of esophagus continue with trachea separately by double tubes.

ANSWER: D

patho - lecture (1)

6. 55yrs man came with food impaction and dysphagia, upper endoscopy was made and there was cell hyperplasia ... and neutrophils more than 15 cells/zone, which is correct?

A. Not associated with barret esophagus

B. Autoimmune esophagitis

C. Respond well to PPI D. Has rings in its upper and mid esophagus

Answer: C

اسئلة خارجية (مش من الارشيف)

1. a 50-year-old woman with long-standing rheumatoid arthritis complains of weakness and fatigue. She states that her stools have recently become black after taking a new nonsteroidal anti-inflammatory drug (NSAID). Gastroscopy shows numerous superficial, bleeding mucosal defects.

Which of the following is the most likely diagnosis?

(A) Acute erosive gastritis

(B) Early gastric cancer

(C) Helicobacter pylori gastritis

(D) Ménétrier disease

(E) Peptic ulcer disease

answer: a

patho - lecture (1)

2. A 70-year-old woman presents with difficulty swallowing and a 9-kg (20-lb) weight loss over the past several months. Endoscopy reveals irregular narrowing of the lower third of the esophagus. A biopsy shows markedly atypical cuboidal cells lining irregular gland-like structures. Which of the following is the most likely diagnosis?

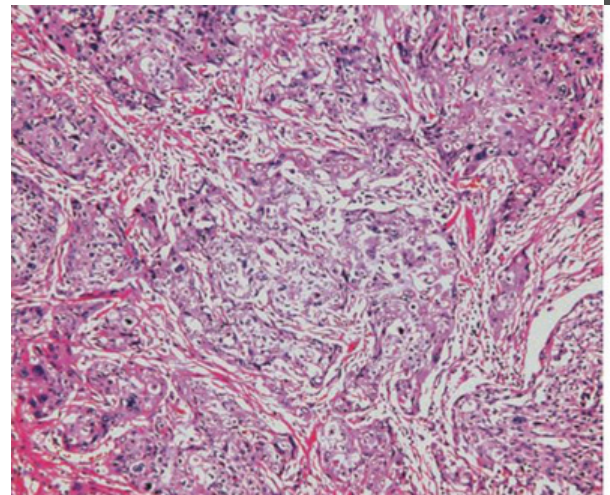
- (A) Adenocarcinoma
- (B) Esophageal stricture
- (C) leiomyosarcoma
- (D) Scleroderma
- (E) Squamous cell carcinoma

answer: a

3. A 60-year-old man presents with a 5-week history of difficulty swallowing. Physical examination is unremarkable. Upper endoscopy shows a large mass in the upper third of the esophagus. A biopsy is shown in the image. What is the appropriate histologic diagnosis for this esophageal mass?

- (A) Adenocarcinoma
- (B) Glandular metaplasia
- (C) Malignant melanoma
- (D) Squamous cell carcinoma
- (E) Transitional cell carcinoma

answer: d



patho - lecture (1)

3. A 30-year-old man with AIDS complains of severe pain on swallowing. Upper GI endoscopy shows elevated, white plaques on a hyperemic and edematous esophageal mucosa. Which of the following is the most likely diagnosis?

- (A) Barrett esophagus
- (B) Candida esophagitis
- (C) Herpetic esophagitis
- (D) Reflux esophagitis
- (E) Squamous cell carcinoma in situ

answer : b

4. The patient described in Question 4 is at increased risk of developing which of the following diseases of the esophagus?

- (A) Achalasia
- (B) Adenocarcinoma
- (C) Candidiasis
- (D) Plummer-Vinson syndrome
- (E) Varices

answer: b

patho - lecture (1)

5. A 35-year-old man complains of difficulty swallowing and a tendency to regurgitate his food. Endoscopy does not reveal any esophageal or gastric abnormalities. Manometric studies of the esophagus show a complete absence of peristalsis, failure of the lower esophageal sphincter to relax upon swallowing, and increased intraesophageal pressure. Which of the following is the most likely diagnosis?

- (A) Achalasia
- (B) Barrett esophagus
- (C) Esophageal stricture
- (D) Mallory-Weiss syndrome
- (E) Schatzki ring

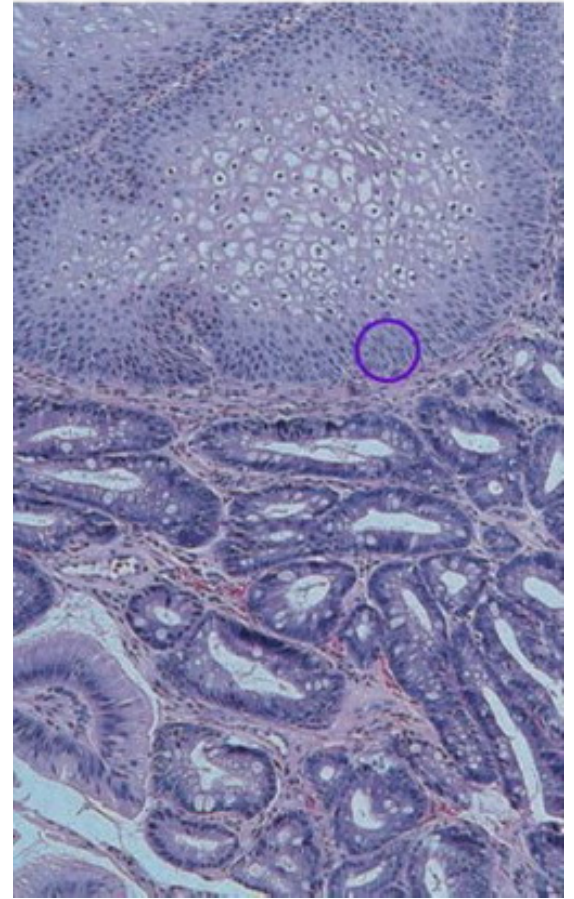
answer: a

6. A 54-year-old man with a long history of indigestion and heartburn presents with upper abdominal pain. He was treated with proton-pump inhibitors for gastroesophageal reflux 3 years previously. An endoscopic biopsy of the lower esophagus is shown in the image. Which of the following best describes these pathologic findings?

patho - lecture (1)

- (A) Candida esophagitis
- (B) Esophageal diverticulum
- (C) Esophageal varices
- (D) Glandular metaplasia
- (E) Schatzki ring

answer: d





GIT- pathology

Archive

Lecture 2

Pathology of the stomach

Done by :

أمني العميرة

patho - lecture (2)

1. One of the following is characteristic of esophageal infecti by CMV :

- A- Nuclear and cytoplasmic inclusion in capillary endothelium andstromal cells.
- B- Central part of ulcer deeper than peripheral part.
- C- Nuclear viral inclusion in biopsy.
- D- Coudry bodies A showing in histological pattern.
- E- Composed of matted fungal hyphae and inflammatory cells.

Answer: A

2. Which is incorrect regarding autoimmune gastritis:

- A- Antibodies to parietal cells and intrinsic factor.
- B- Antral endocrine cell hyperplasia.
- C- Impaired gastric acid production.
- D- Increased serum pepsinogen I.
- E- Vit-B12 deficiency.

Answer: D

patho - lecture (2)

3. Which of the following etiologies is least likely to cause acute gastric ulcer?

- A. Intracranial disease.
- B. Allergy.
- C. Burns.
- D. Stress.
- E. Trauma.

ANSWER: B

4. All of the following describes chemical gastropathy except?

- A. Foveolar hyperplasia.
- B. Background of inflammation.
- C. Smooth muscle fiber hyperplasia.
- D. Vasodilation.
- E. Edema and congestion of capillaries.

ANSWER: B

5. Which is false matching :

- a. Stress ulcers - severe trauma.
- b. Stress ulcers - severe burns.
- c. Cushing ulcers - high incidence of perforation.

Answer: B

patho - lecture (2)

اسئلة خارجية (مش من ضمن الاراشيف)

1.A 3-week-old boy is brought to the physician by his parents,who report that he vomits forcefully immediately after nurs-ing. Physical examination reveals an "olive-like" palpable mass and visible peristaltic movements within the infant's abdomen.What is the most likely cause of projectile vomiting in this infant ?

- (A) Appendicitis
- (B) Congenital pyloric stenosis
- (C) Hirschsprung disease
- (D) Meconium ileus
- (E) Tracheoesophageal fistula

answer :a

2.A 45-year-old woman presents with a 6-month history of fatigue and swelling in her neck. Physical examination shows a goiter. A CBC discloses megaloblastic anemia and a normal reticulocyte count. Additionally, there is an elevated serum level of TSH and antithyroid antibodies. Needle aspiration of the left lobe of the thyroid reveals benign follicular cells and numerous lymphocytes. Anemia in this patient is most likely caused by antibodies directed to which of the following targets?

patho - lecture (2)

- (A) Chief cells
- (B) Intrinsic factor
- (C) Paneth cells
- (D) TSH receptor
- (E) Vitamin D

Answer: b

3. A 40-year-old woman presents with a 2-month history of burning epigastric pain that usually occurs between meals. The pain can be relieved with antacids or food. The patient also reports a recent history of tarry stools. She denies taking aspirin or NSAIDs. Laboratory studies show a micro-cytic, hypochromic anemia (serum hemoglobin = 8.5 g/dL). Gastrosocopy reveals a bleeding mucosal defect in the antrum measuring 1.5 cm in diameter. An endoscopic biopsy shows that the lesion lacks mucosal lining cells and is composed of amorphous, cellular debris and numerous neutrophils. Which of the following is the most important factor in the pathogenesis of this patient's disease?

- (A) Achlorohydria
- (B) Acute ischemia
- (C) Autoimmunity
- (D) Gastrinoma
- (E) Helicobacter pylori infection

answer: e



GIT- pathology

Archive

Lecture 3

Pathology of the stomach

Done by :

Razan fawwaz

patho - lecture (3)

1. Second most common primary gastric lymphoma :

- A- Hodgkin lymphoma.
- B- Diffuse large B cell lymphoma.
- C Non-hodgkin lymphoma.
- D- Marginal zone B cell lymphoma.
- E- Adenocarcinoma.

Answer. B

2. Which is incorrect regarding autoimmune gastritis :

- A- Antibodies to parietal cells and intrinsic factor.
- B- Antral endocrine cell hyperplasia.
- C- Impaired gastric acid production
- D- Increased serum pepsinogen I.
- E- Vit-B12 deficiency.

Answer. D

3. man with peptic ulcer have milk release from nipple what is the drug may cause it:

- a. Omeprazole
- b. Metoclopramide
- c. H₂ histamine
- d. cimetidine

Answer: d

4. The most common primary gastric lymphoma is?

- A. Diffuse large B cell.
- B. Extra nodal marginal zone B cell.
- C. T cell lymphoma
- D. Follicular lymphoma.

ANSWER: B

patho - lecture (3)

5. Which of the following etiologies is least likely to cause acute gastric ulcer?

- A. Intracranial disease.
- B. Allergy.
- C. Burns.
- D. Stress.
- E. Trauma.

ANSWER: B

اللهم آتنا في الدنيا حسنة وفي الآخرة حسنة وقنا عذاب النار
بالتوفيق



GIT- pathology

Archive

Lecture 4

Pathology of the small intestine 1

Done by :

Razan fawwaz

patho - lecture (4)

1. 70 years old man had a history with congestive heart failure and ulcers in colon. What is the most likely diagnosis

- A- Hemorrhoids.
- B- Celiac disease.
- C- Diverticulosis.
- D- ischemic bowel disease.
- E- Hirschsprung disease.

Answer. D

2. One of the following is incorrect about celiac disease

- A- Caused by HLA-DQ2 mutation.
- B- Crypt hyperplasia is the most specific feature.
- C- Gluten insensitivity.
- D- Increased risk of enteropathy associated T cell lymphoma.
- E- Diagnosed by small bowel biopsy.

Answer. C

3. Which is incorrect regarding hirschsprung disease

- A- Rectum is always involved.
- B- Treated by surgical resection of aganglionic dilated part.
- C- Congenital aganglionic megacolon.
- D- Neonatal failure to pass meconium.
- E- Can lead to fluid and electrolyte disturbances.

Answer. B

patho - lecture (4)

4. celiac disease :

- a.HLA - DQ8
- b.MTP mutation
- c. normal finding on biopsy
- d.is treated by oral enzyme supplementation

Answer a

5. Osmotic diarrhea in :

- a. Lactose deficiency
- b.Infection
- c.celiac disease
- d.cystic fibrosis

Answer:a

6. The primary pathophysiologic mechanism of malabsorption in α -beta lipoproteinemia involves?

- A. Lymphatic abnormalities
- B. Villous atrophy of small intestinal mucosa
- C. Bacterial overgrowth in the small intestine
- D. An epithelial cell biochemical defect/ transepithelial transport defect of TG and FAs
- E. Defective fat digestion due to lipase deficiency

Answer d

7. Which of the following is true regarding Hirschberg disease?

- A. Aganglionic part is proximal to the dilated part
- B. Aganglionic part is distal to the dilated part
- C. Dilated part is the aganglionic part

Answer:B



GIT- pathology

Archive

Lecture 5

Small and Large Intestinal
pathology, part 2

patho - lecture (5)

Main feature that found in Crohn's disease and not in ulcerative colitis :

- A- Crypt abscesses.
- B- Paneth cell metaplasia.
- C- Smoking improve disease.
- D- Limited to colon and rectum.
- E- Inflammation extend from mucosa to muscularis

Answer:E

which of the following isn't in ulcerative colitis :

- A.Toxic megacolon
- B.Diffuse distribution
- C.Always rectal involvement
- D.Noncaseating granuloma

Answer:d

A 55-year-old white female with a 30-year history of ulcerative colitis returns for a follow-up visit. She recently recovered from an acute exacerbation for which she was hospitalized and given immunosuppressive therapy, to which she responded. She knows about her increased risk for adenocarcinoma of the colon. Which of the following is more common in patients who suffer from UC than Crohn's disease?

- A. Toxic megacolon
- B. Malabsorption
- C. Fistula formation
- D. Granulomas
- E. Small intestinal ulcers

ANSWER: A

patho - lecture (5)

Which of the following is characteristic of Crohn's disease and not of ulcerative colitis.?

- A. rectal blood
- B. rectum is often spared
- C. is diffuse
- D. fistulas less common
- E. usually only affects the mucosa and the submucosa

Answer: B

2. which of the following is more specific for ulcerative colitis than Crohn's disease.?

Answer: In rectum with continuous pattern



GIT- pathology

Archive

Lecture 6

Small and Large Intestinal
pathology, part 3

patho - lecture (6)

First stage of pancreatic carcinoma caused by mutation in :

- A- P53.
- B- KRAS.
- C- P16.
- D- SMAD4.
- E- BRCA2

Answer: B

In the colon, which is benign and has no significant tendency to undergo malignant transformation?

- A. Familial polyposis
- B. Tubulovillous adenoma
- C. Carcinoid tumors
- D. Villous adenoma
- E. Juvenile polyp

Answer: E

Which gene mutation causes FAP

Answer: APC gene



GIT- pathology

Archive

Lecture 7+8

Done by :
Alaa hdayat

patho - lecture (#)

) About HAV , the correct statement is :

- A- Transmitted by sexual activity.
- B- Envelope with glycoprotein.
- C- Protease inhibitors treatment of choice.
- D- Risk factor for MALT lymphoma.
- E- Transmitted feco-orally.

Answer: E

22. One of the following is incorrect :

- A- HDV needs HBV to infect.
- B- HAV can be chronic disease.
- C- HBV have double stranded DNA structure.
- D- HCV transmitted sexually.
- E- HEV can be acute only

Answer: B

38. What type of collagen replaces in liver cirrhosis :

- A- Collagen type 1/2.
- B- Collagen type 2.
- C- Collagen type 1.
- D- Collagen type 1/3.
- E- Collagen type 2/3.

Answer: D

patho - lecture (#)

3) hepatocellular carcinoma is :

- A_ Arelatively frequent tumor in the U.S population
- B_ Associated with cirrhosis
- C_ Associated with ulcerative colitis
- D_ Associated with gallstones

Answer ;B

4)which disease is most commonly associated with the development of hepatocellular carcinoma :

- A_ Autoimmune hepatitis
- B_ primary sclerosing cholangitis
- c_ heptitis B
- D_ primary biliary cirrhosis

Answer :c

6)which of the following hepatitis viruses has a higher case fatality rate particularly in pregnant women?

- A_ hepatitis A
- B_ hepatitis B
- C_ hepatitis C
- D_ hepatitis D
- E_ hepatitis E

Answer:E

7)all of the following cause chronic hepatitis expect ;

- A_ hepatitis A virus
- B_ hepatitis c virus
- c_ drugs
- D_ hepatitis B virus
- E_ Autoimmune hepatitis

Answer :A

patho - lecture (#)

8). Steatohepatitis (fatty liver) is usually caused by which of the following injuries?

- A) Obstruction to extrahepatic bile ducts
- B) Alcohol abuse
- C) Hemochromatosis
- D) Hepatitis C
- E) Superinfection with Hepatitis D virus

Answer ;B

9) Alcoholic liver disease is characterized by

- A) Mallory bodies
- B) Piecemeal necrosis
- C) Granuloma formation
- D) Ground glass cells

Answer ;A

10) The most frequent result of infection with hepatitis A virus is

- A) Chronic active hepatitis
- B) Massive hepatic necrosis
- C) Hepatocellular carcinoma
- D) Acute self-limited hepatitis

Answers ;D

11) If you acquire hepatitis C from a patient, your risk of developing chronic hepatitis is approximately

- A) 10%
- B) 30%
- C) 50%
- D) 90%

Answer ;c

patho - lecture (#)

12)Alcoholic hepatitis is characterized by all EXCEPT:

- A) Fatty change
- B) Accumulation of keratin in hepatocytes
- C) A neutrophilic infiltrate in the lobule
- D)intranucler inclusions

Answer:D

13)Prescription in severe liver diseases should be very careful in presence of all the following, EXCEPT?

- A) Fluid retention
- B) Hepatic encephalopathy
- C)Hyperalbuminemia
- D) Renal impairment
- E) Reduced clotting factor

Answer ;c

14)year-old woman has become increasingly lethargic in the last week. On examination, she has jaundice, rigidity, confusion and asterixis. She has no fever and normal blood pressure. Laboratory revealed prolonged PT and PTT and elevated serum levels of transaminases and bilirubin. Which of the following is mostly responsible for her neurological symptoms?

- A) Alkaline phosphatase
- B) Amylase
- C) Antimitochondrial antibodies
- D) Anti-HCV
- E) Ammonia

Answer ;e

patho - lecture (#)

15) Which of the following findings does not related to chronic hepatitis :

- A- Bridging necrosis.
- B- Portal fibrosis.
- C- Bridging fibrosis.
- D- Interface hepatitis.
- E- Cholestasis.

Answer:E

16)Allthe following pairs between signs and cause in cirrhotic patient are true, except?

- A.Hypoalbuminemia - ascites.
- B. Clotting factors deficiency-Hematoma.
- C. Excess ammonia- coma.
- D.Hyperestrogenism - Palmer erythema
- E. Clotting factors deficiency- hematemesis.

ANSWER:E