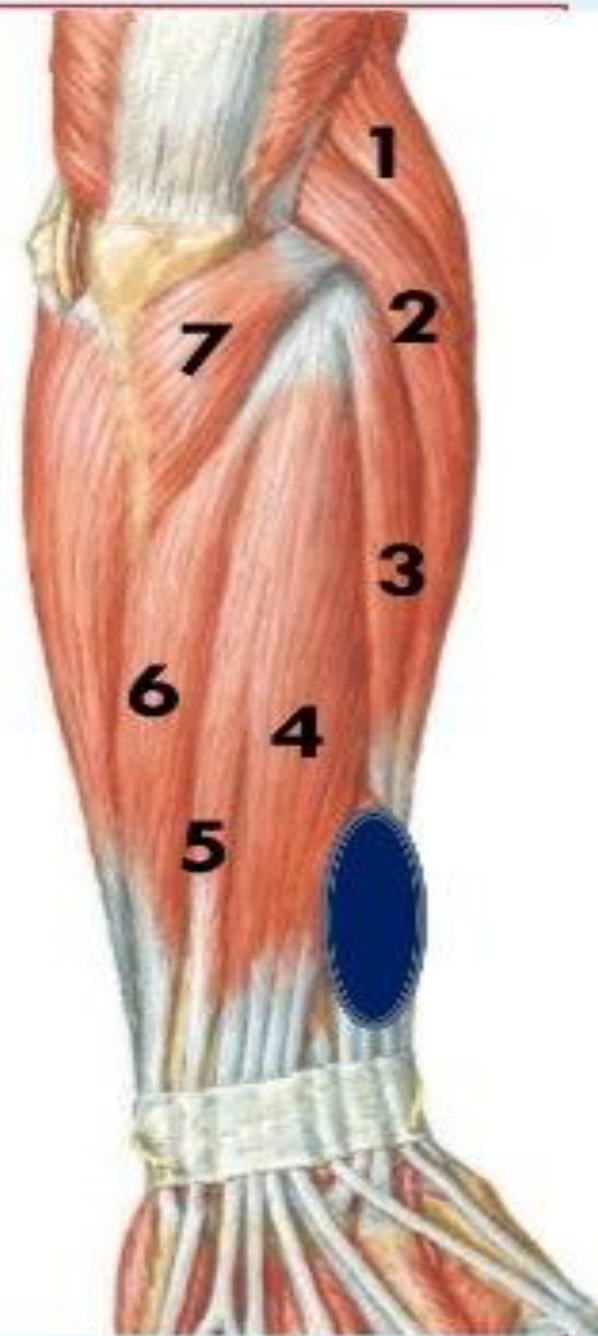


Muscles of back of forearm

Superficial group (7)

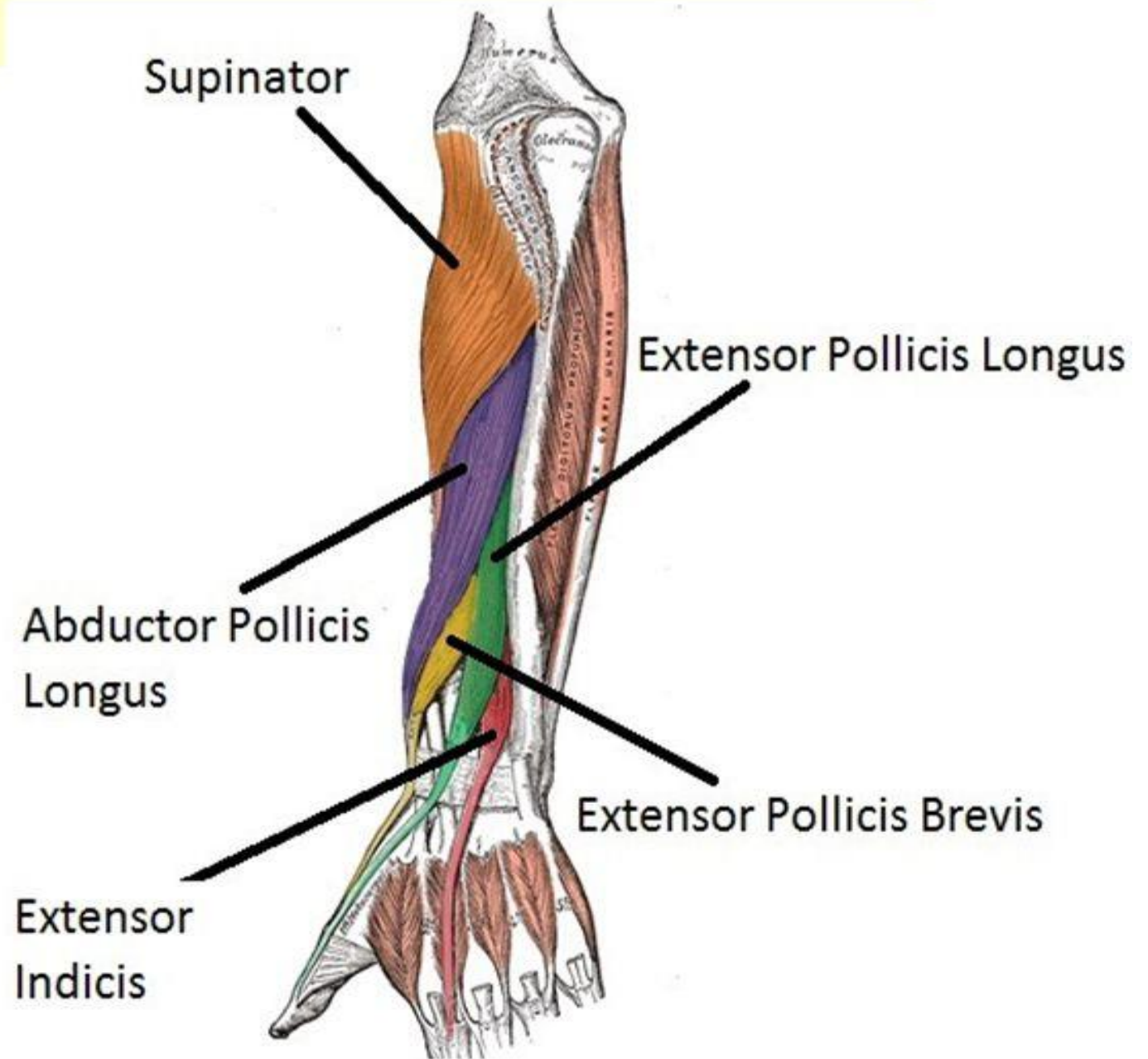
1. Brachioradialis
2. Extensor carpi radialis longus
3. Extensor carpi radialis brevis
4. Extensor digitorum
5. Extensor digiti minimi
6. Extensor carpi ulnaris
7. anconeus

Deep group (5)



Deep Group

- Supinator
- Abductor pollicis longus
- Extensor pollicis brevis
- Extensor pollicis Longus
- Extensor indicis
- Except for the supinator muscle, all these deep layer muscles originate from the posterior surfaces of the radius, ulna, and interosseous membrane and pass into the thumb and fingers.



1- Brachioradialis

Origin:

Upper 2/3 of lateral supracondylar ridge of the humerus.

Insertion:

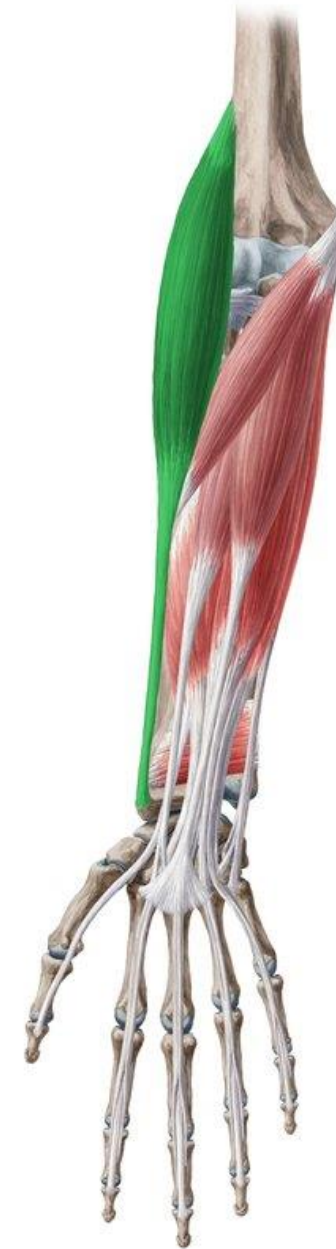Base of styloid process of radius.

Nerve supply:

Radial nerve.

Action:

Flexion of elbow at midprone position.



2- Extensor carpi radialis longus

Origin:

Lower 1/3 of lateral supracondylar ridge of the humerus.

Insertion:

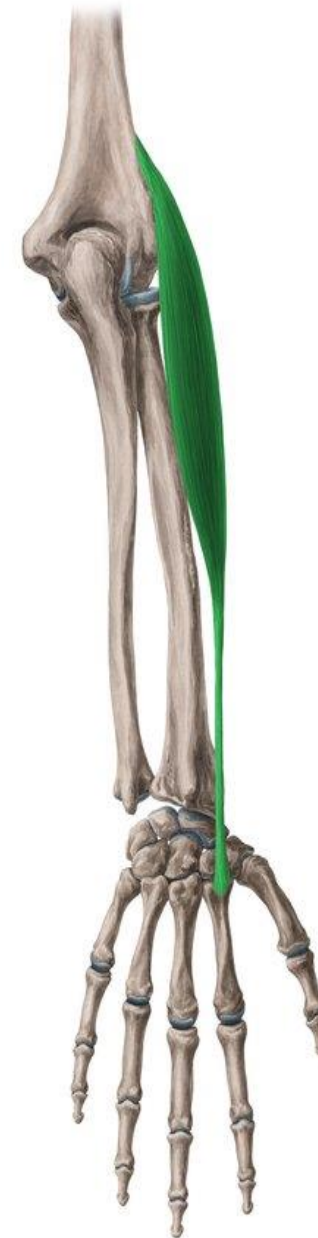Posterior surface of base of 2nd metacarpal bone.

Nerve supply:

Radial nerve.

Action:

Extension and abduction of wrist.



3- Extensor carpi radialis brevis

Origin:

Common extensor origin
(**front** of lateral epicondyle of the humerus).

Insertion:

Posterior surface of base of
3rd metacarpal bone.

Nerve supply:

Posterior interosseous nerve.

Actions:

Extension and abduction of
wrist.



4- Extensor digitorum

Origin: Common extensor origin.

Insertion:

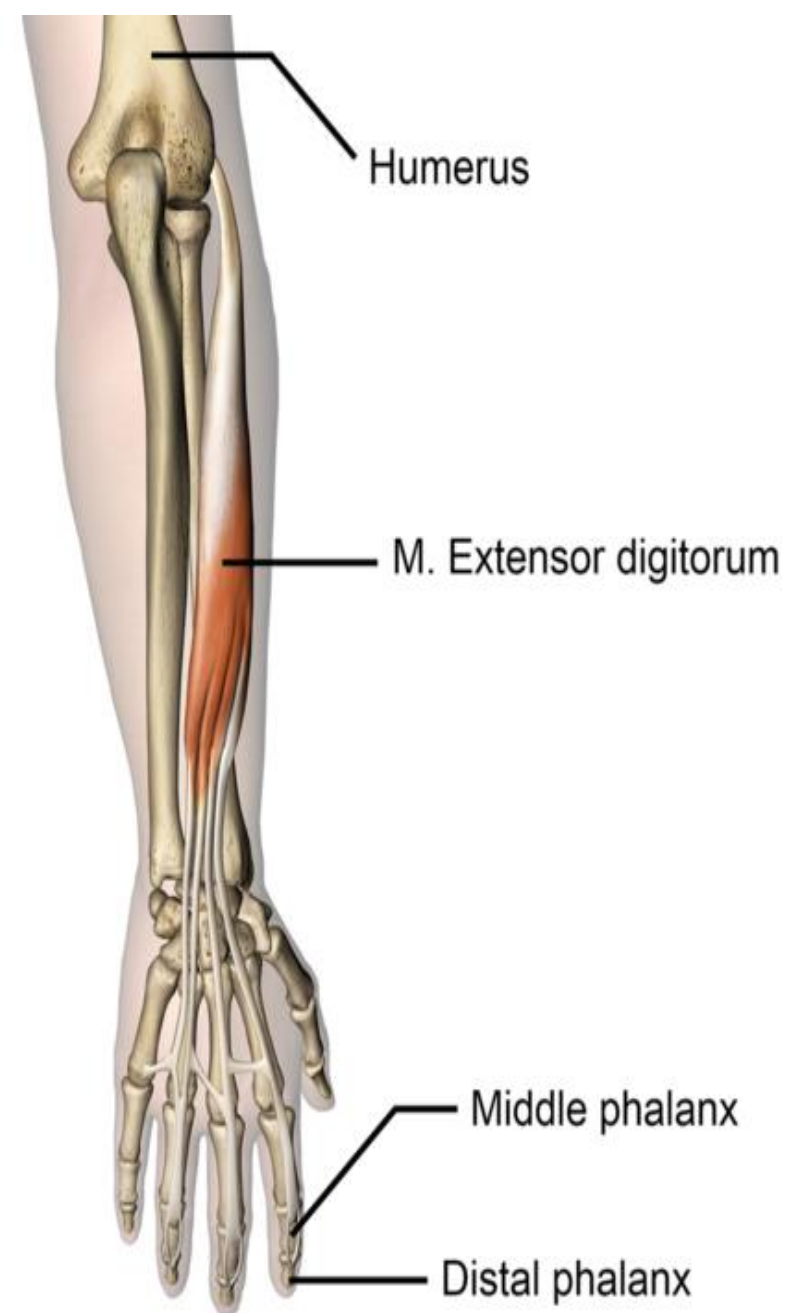
The tendons expands on the posterior surface of proximal phalanges of the medial 4 fingers forming the **extensor expansion**. Each extensor expansion splits into 3 slips: a central slip inserted into the base of the middle phalanx, and 2 lateral slips which are inserted into the base of distal phalanx.

Nerve supply: Posterior interosseous nerve.

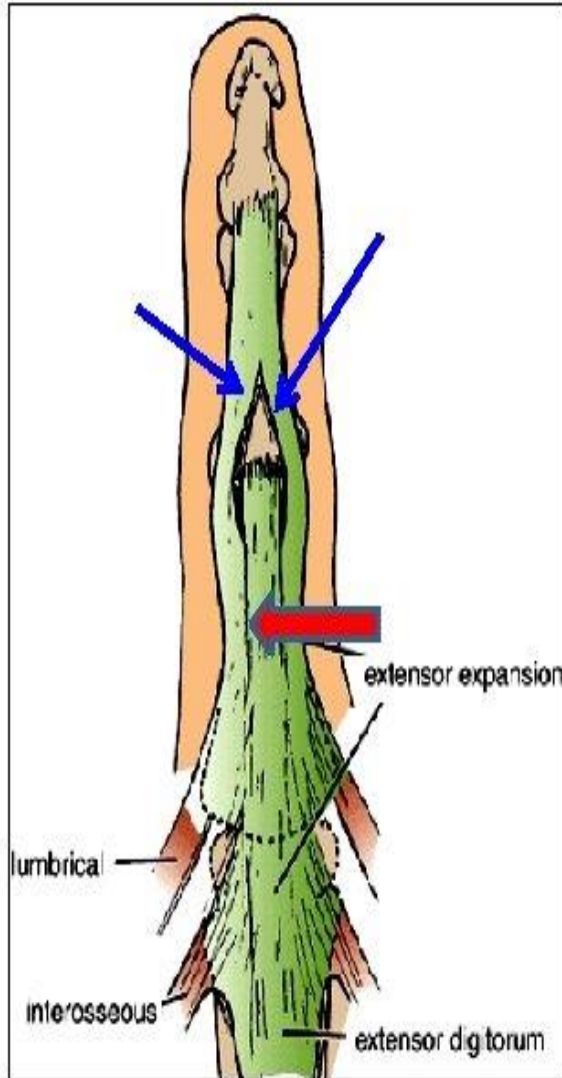
Actions:

Extension of all joints of the medial 4 fingers.

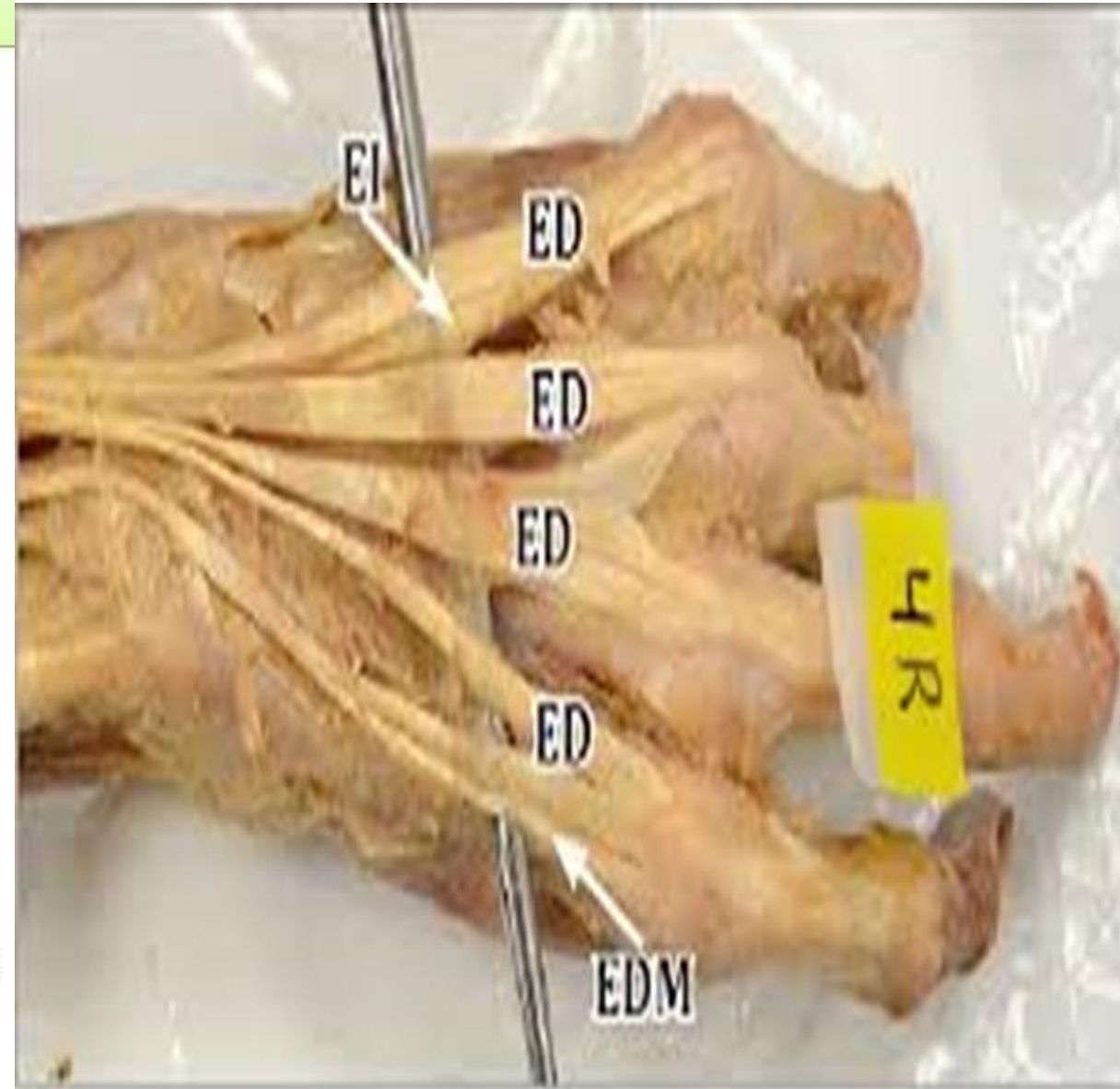
It helps in extension of the wrist.



Extensor Expansion



- Formed from the expansion of extensor digitorum tendons
- At the *PIJ*, the expansion splits into **3 parts**
 - **One Central** inserted into the base of *Middle phalanx*.
 - **Two laterals** inserted into the base of the *Distal phalanx*.
- The Expansion Receives the insertions of:
 - **Corresponding Interosseous muscle (on each side).**
 - **Lumbrical muscle (on the lateral side).**



5- Extensor digiti minimi

Origin:

- **Common extensor origin.**

Insertion:

- **Extensor expansion of the little finger.**

Nerve supply:

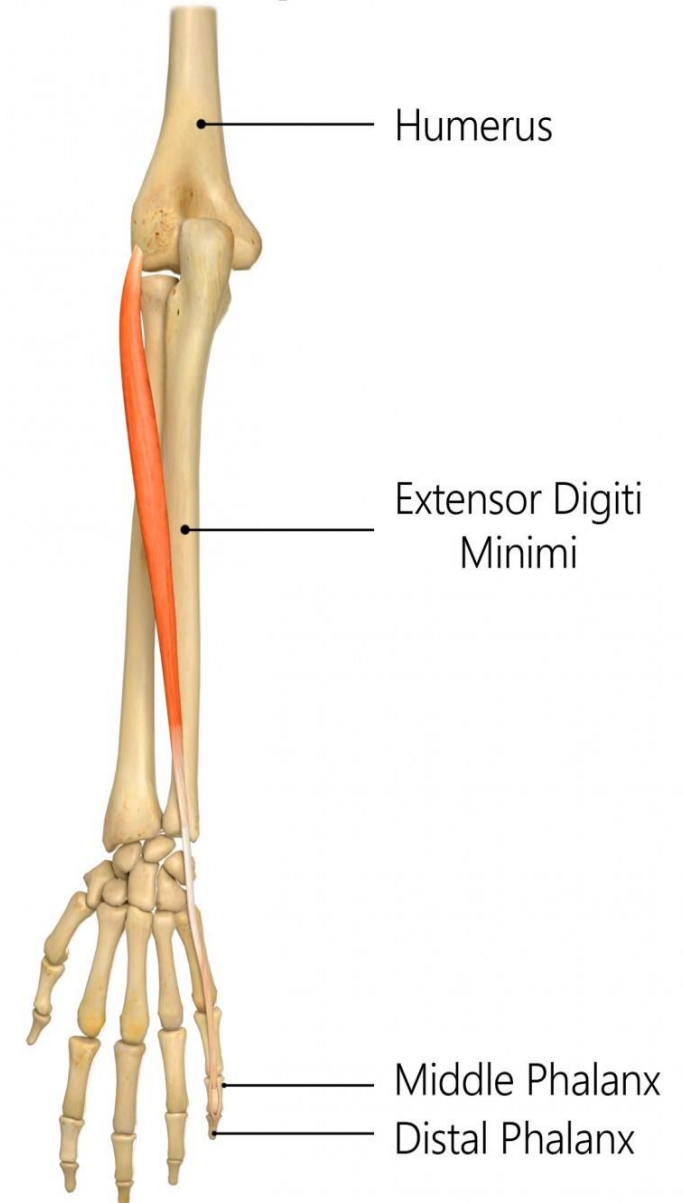
- **Posterior interosseous nerve.**

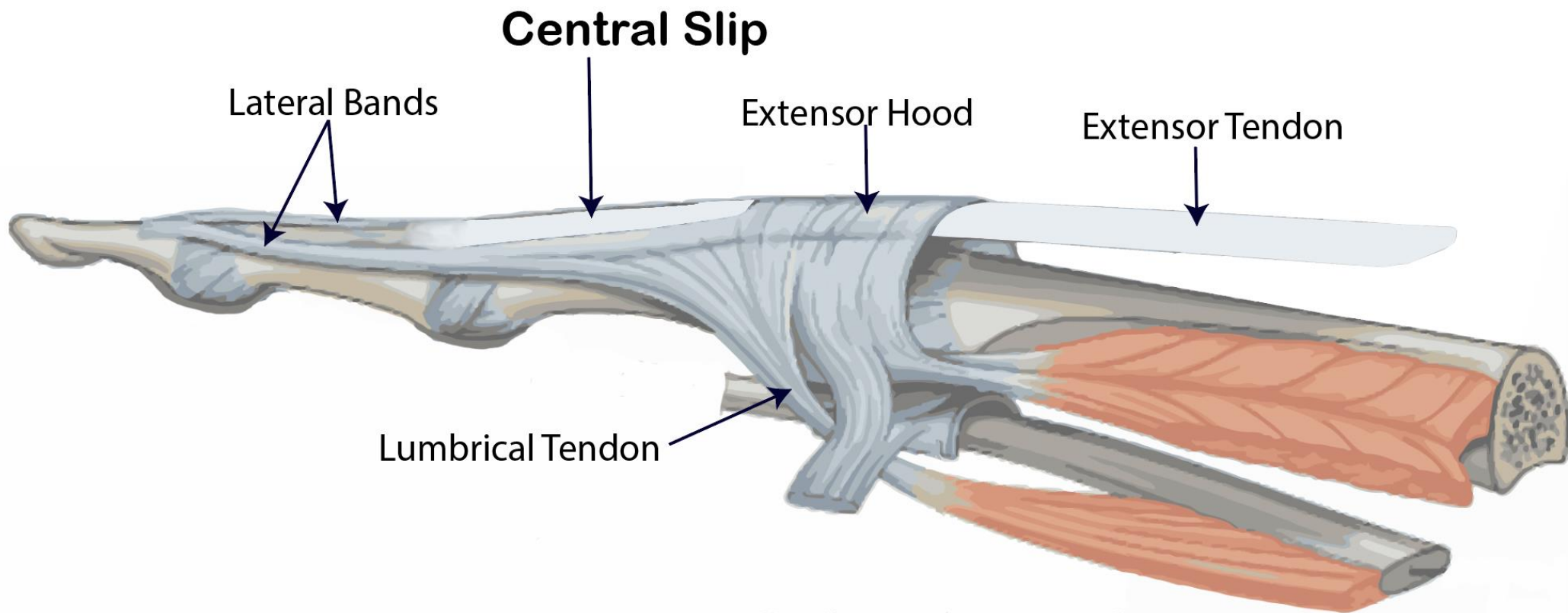
Actions:

- **Extension of all joints of little finger**
- **Extension of wrist.**

REHAB
My Patient.com

Extensor Digiti Minimi





6- Extensor carpi ulnaris:

Origin:

Common extensor origin.

Posterior border of ulna.

Insertion:

Posterior surface of the base of 5th metacarpal bone.

Nerve supply:

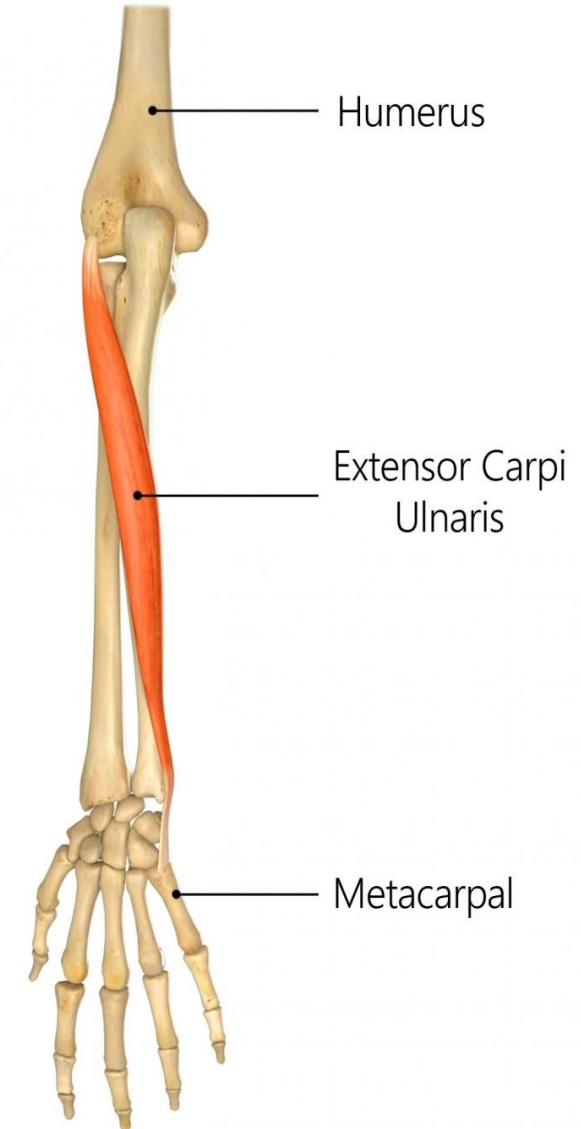
Posterior interosseous nerve.

Actions:

Extension and adduction of the wrist.

REHAB
My Patient.com

Extensor Carpi Ulnaris



7- Anconeus

Origin:

- **Posterior aspect** of lateral epicondyle of humerus.

Insertion:

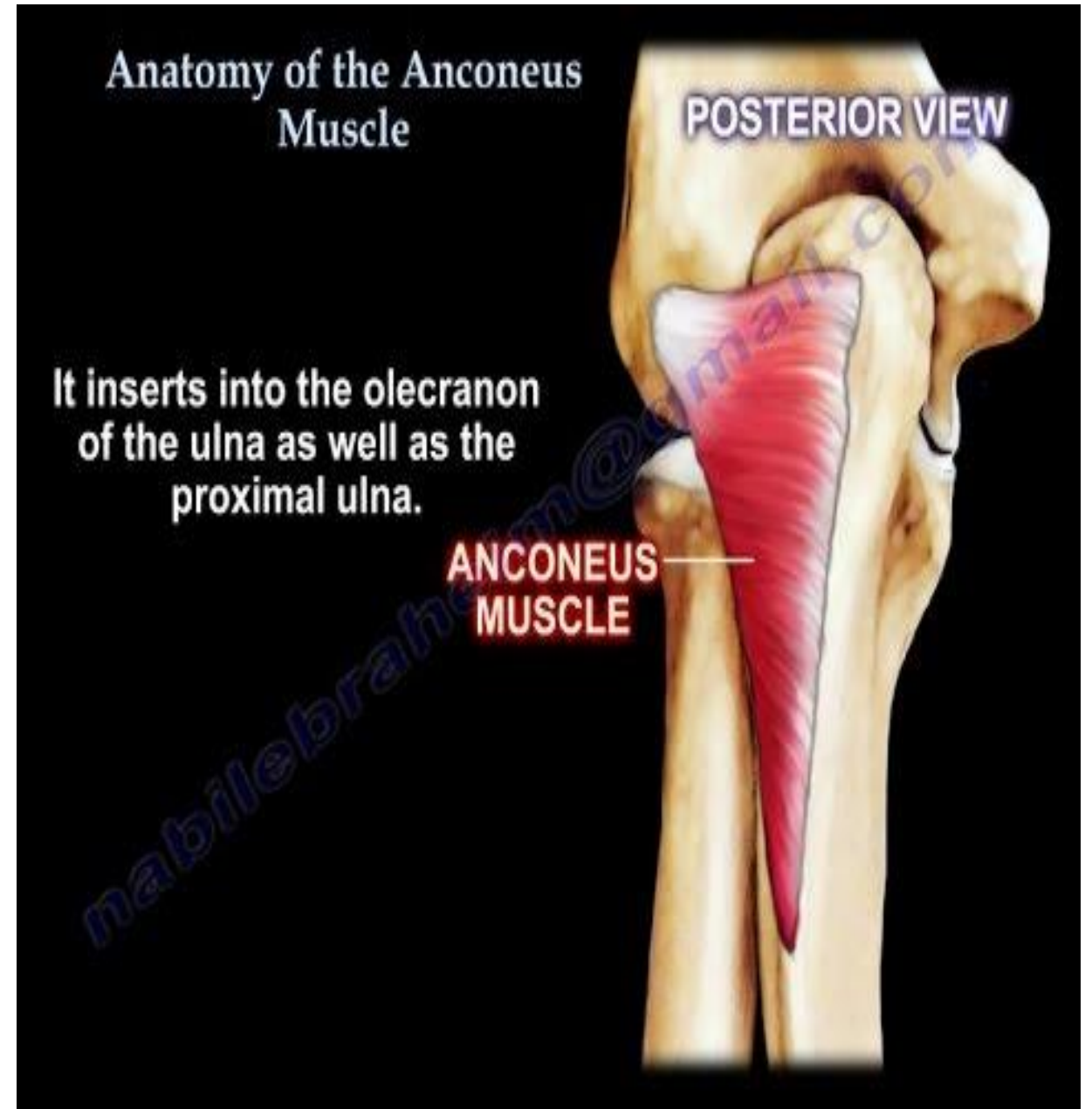
- **Lateral surface** of olecranon process of ulna

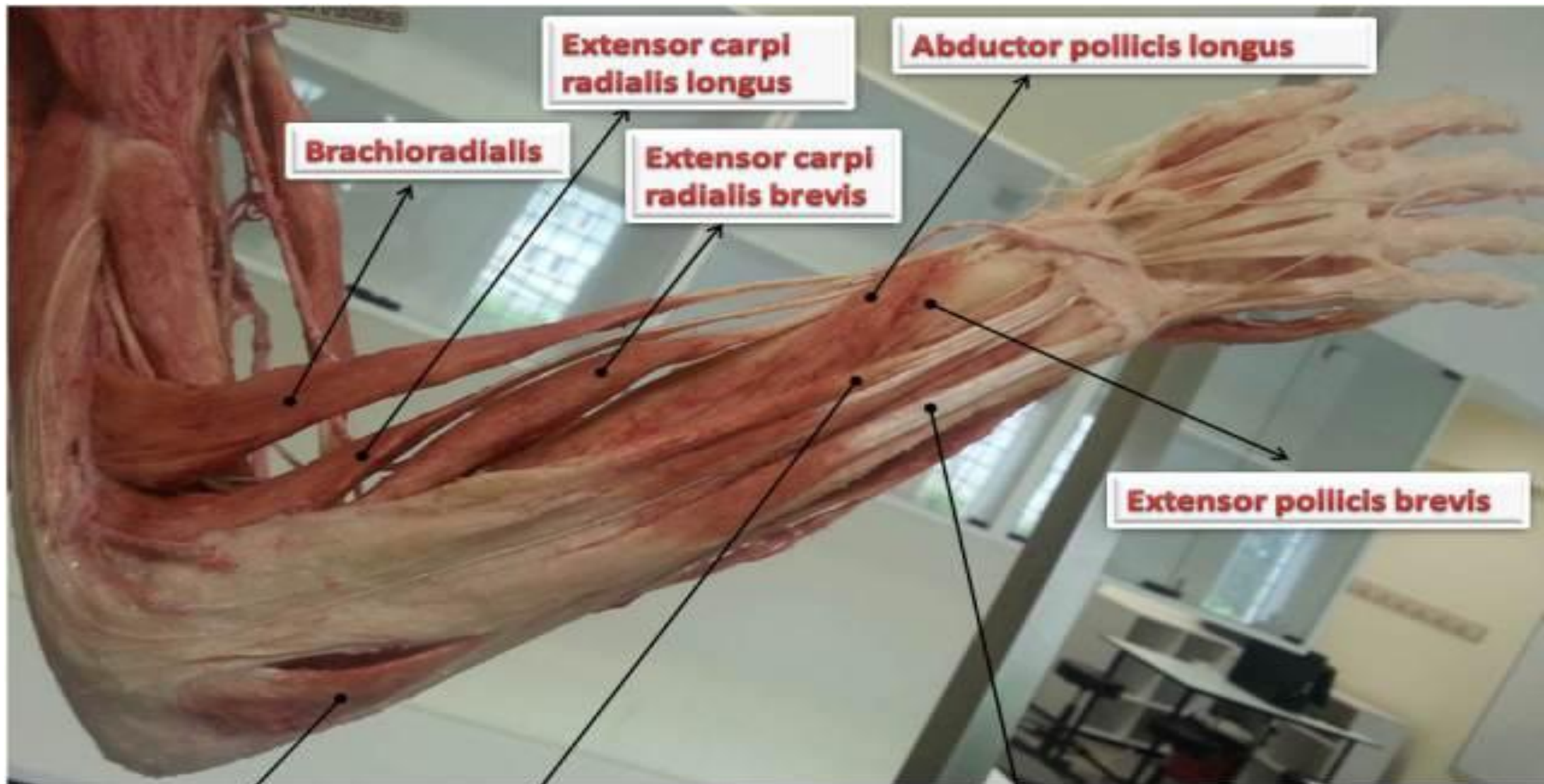
Nerve supply:

- **Radial nerve.**

Action:

- **It helps in extension of elbow.**





Extensor carpi radialis longus

Abductor pollicis longus

Brachioradialis

Extensor carpi radialis brevis

Extensor pollicis brevis

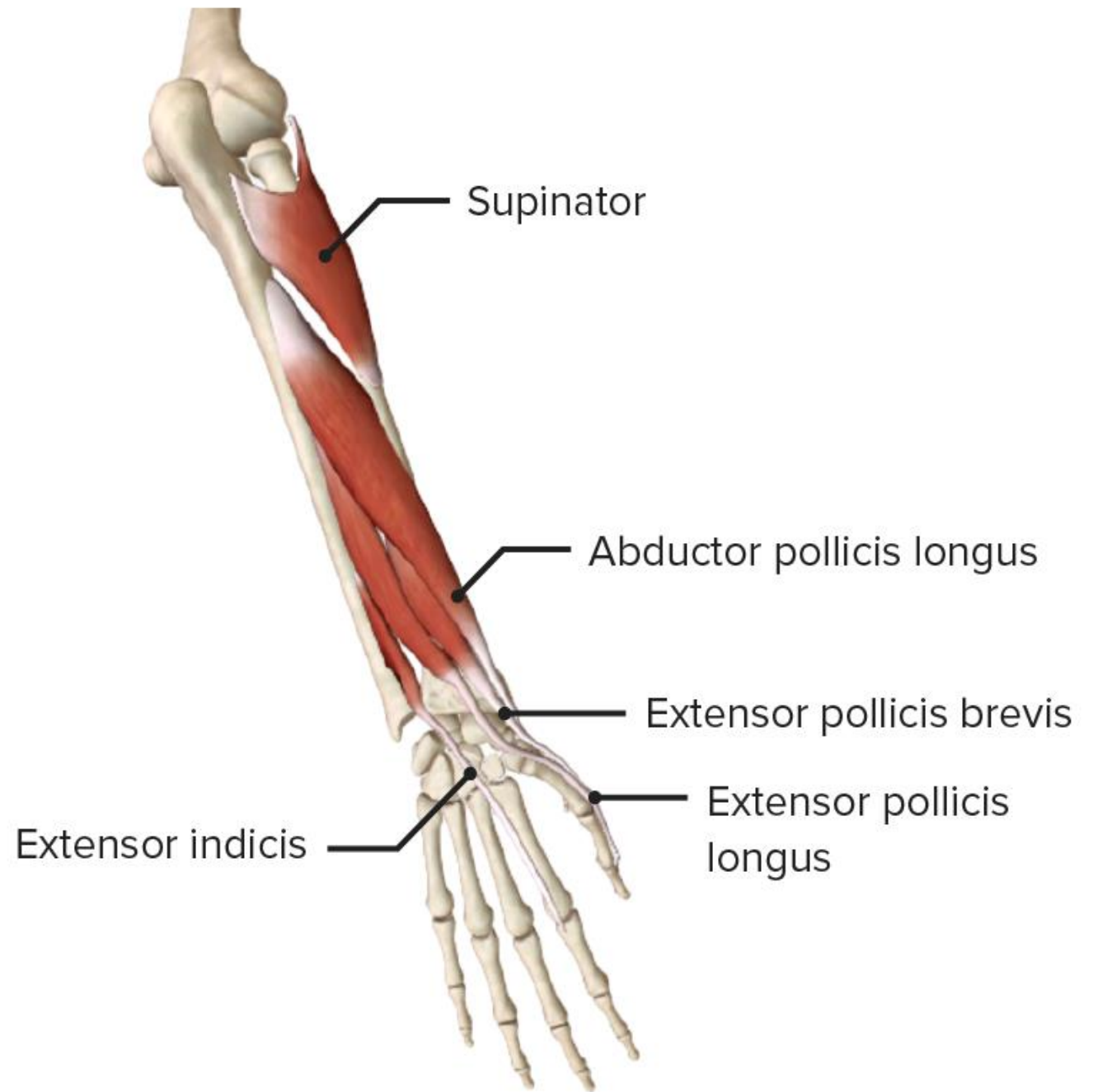
Anconeus

Extensor digitorum

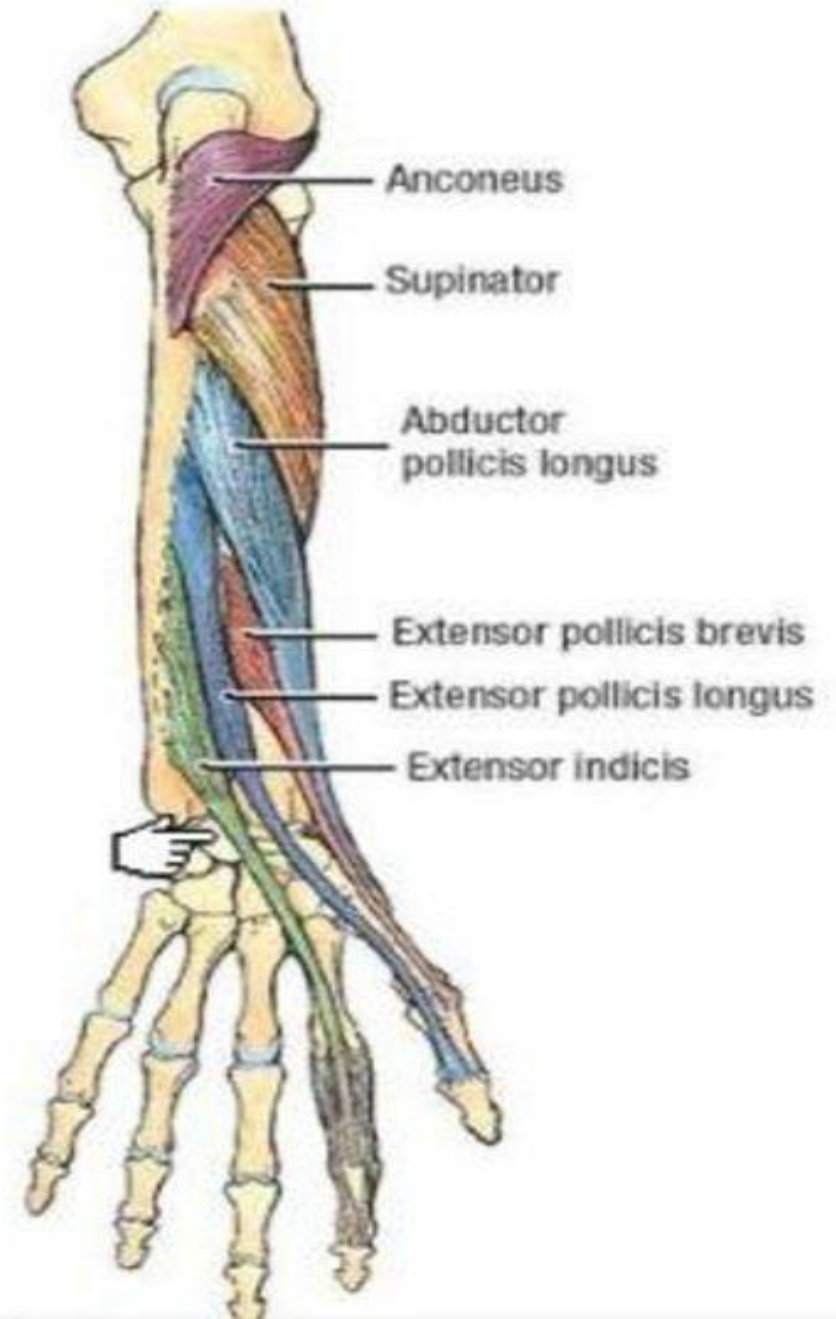
Extensor carpi ulnaris

II- Deep group of extensor muscles:

1. **Supinator.**
2. **Abductor pollicis longus.**
3. **Extensor pollicis brevis.**
4. **Extensor pollicis longus.**
5. **Extensor indicis.**



- Except for the supinator muscle, all these deep layer muscles originate from the posterior surfaces of the radius, ulna, and interosseous membrane and pass into the thumb and fingers.
- All muscles of the deep layer are innervated by the posterior interosseous nerve, the continuation of the deep branch of the radial nerve.



1- Supinator:

Origin:

Supinator crest and fossa in ulna.

Lateral epicondyle of humerus.

Lateral ligament of elbow joint.

Annular ligament.

Insertion:

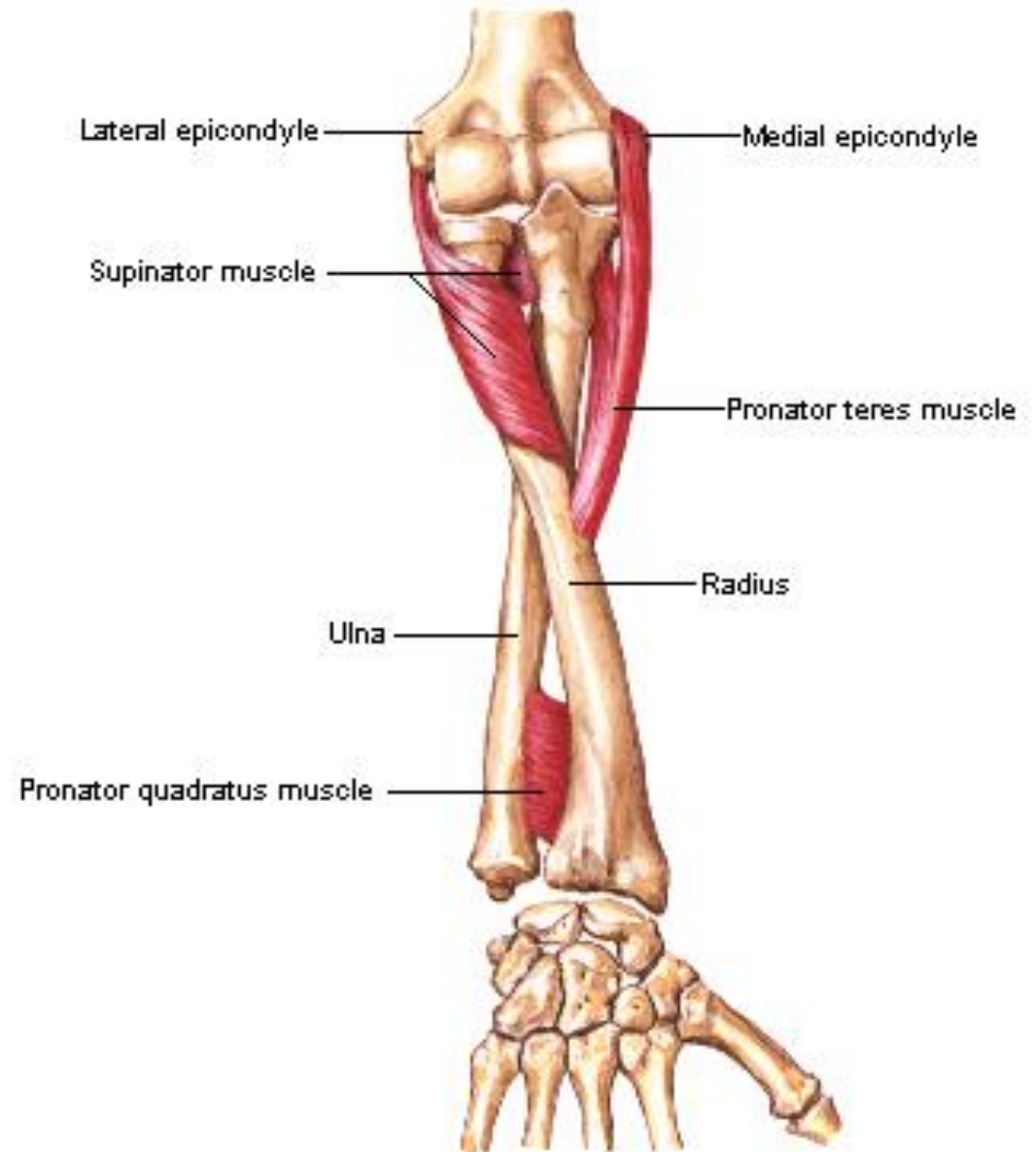
Upper 1/3 of shaft of radius.

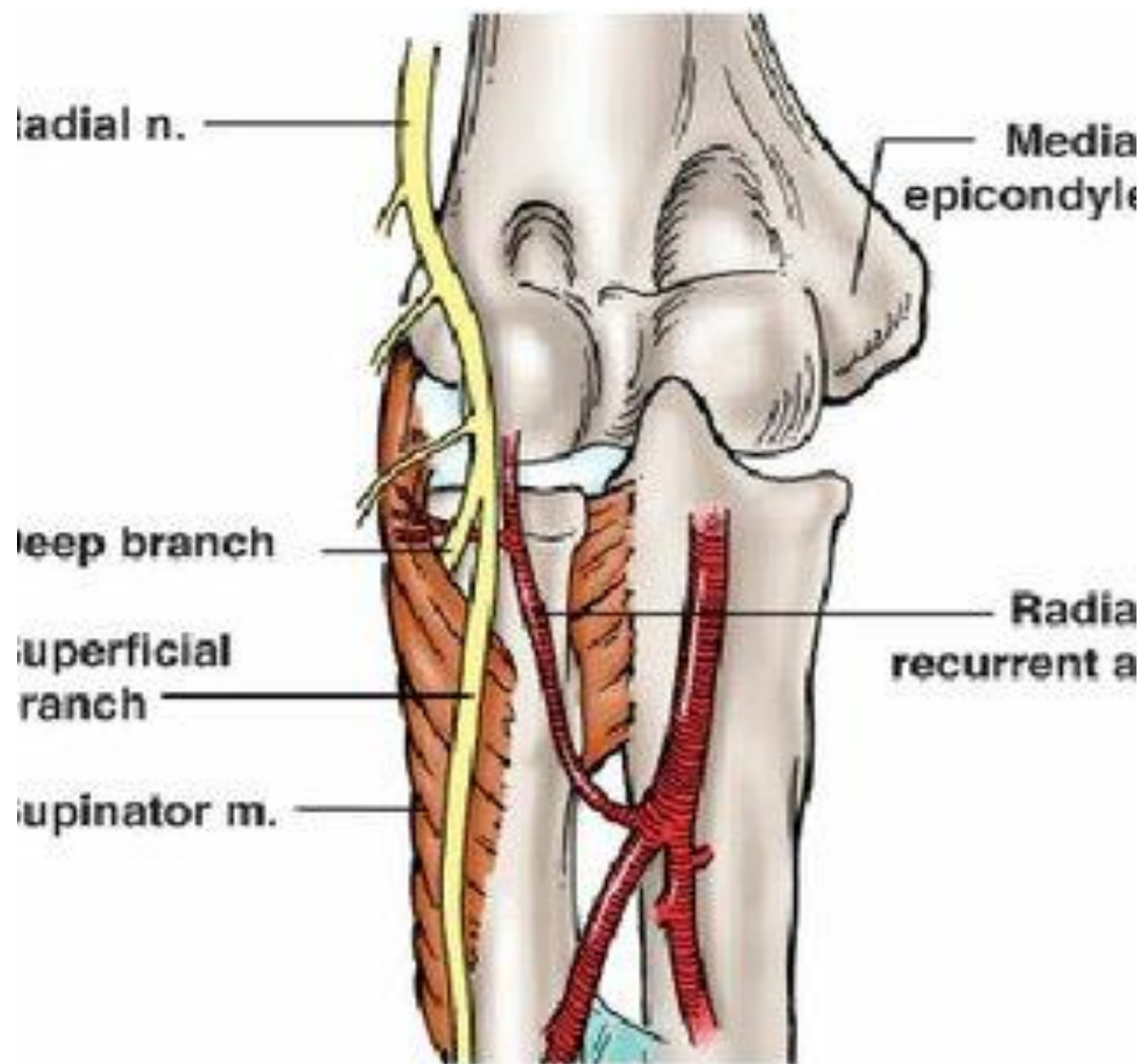
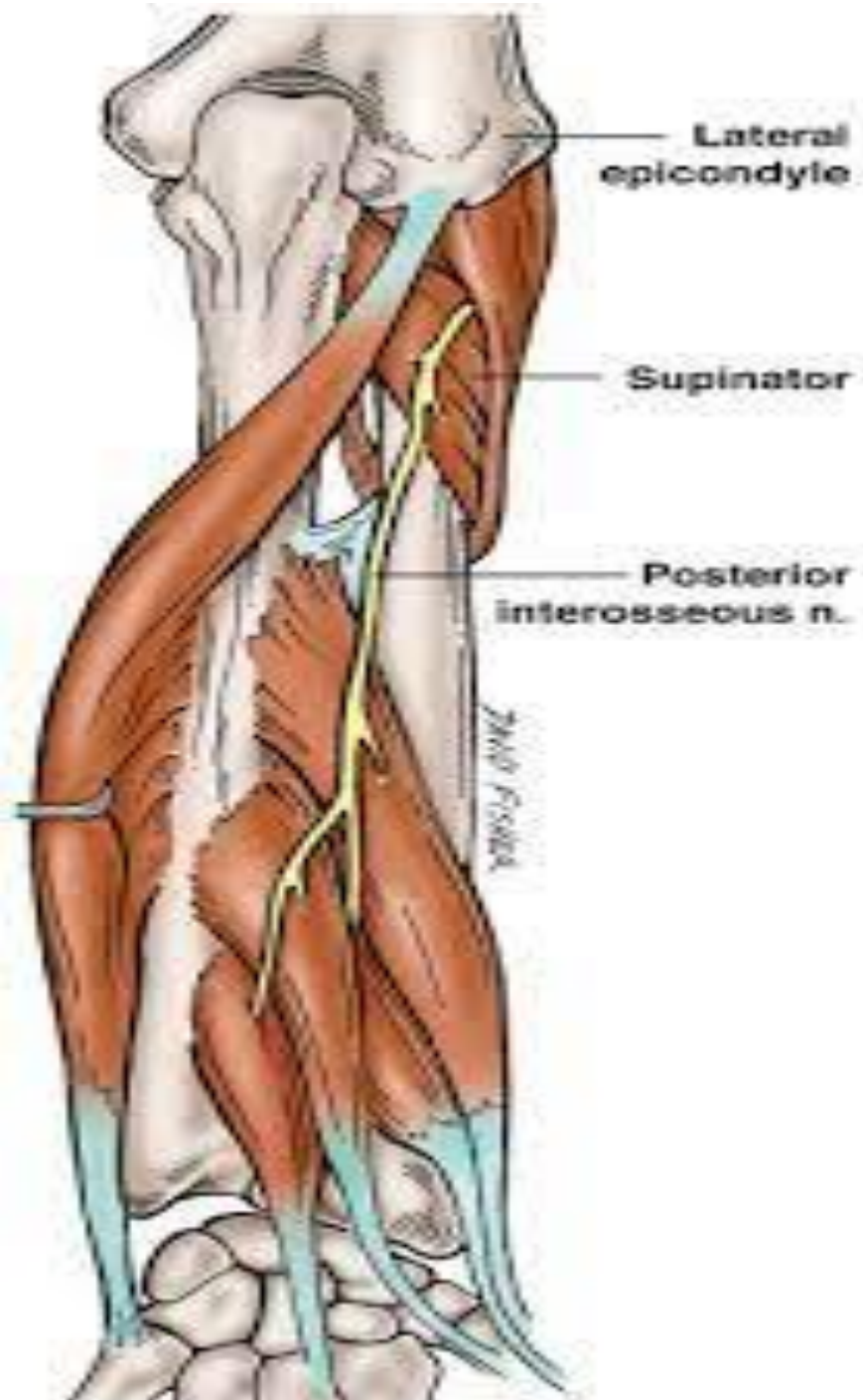
Nerve supply:

Posterior interosseous nerve.

Action:

Supination of the forearm.





2- Abductor pollicis longus

Origin:

**Posterior surface of ulna.
Posterior surface of radius.
Interosseous membrane.**

Insertion:

**Posterior surface of the base of 1st
metacarpal bone.**

Nerve supply:

Posterior interosseous nerve.

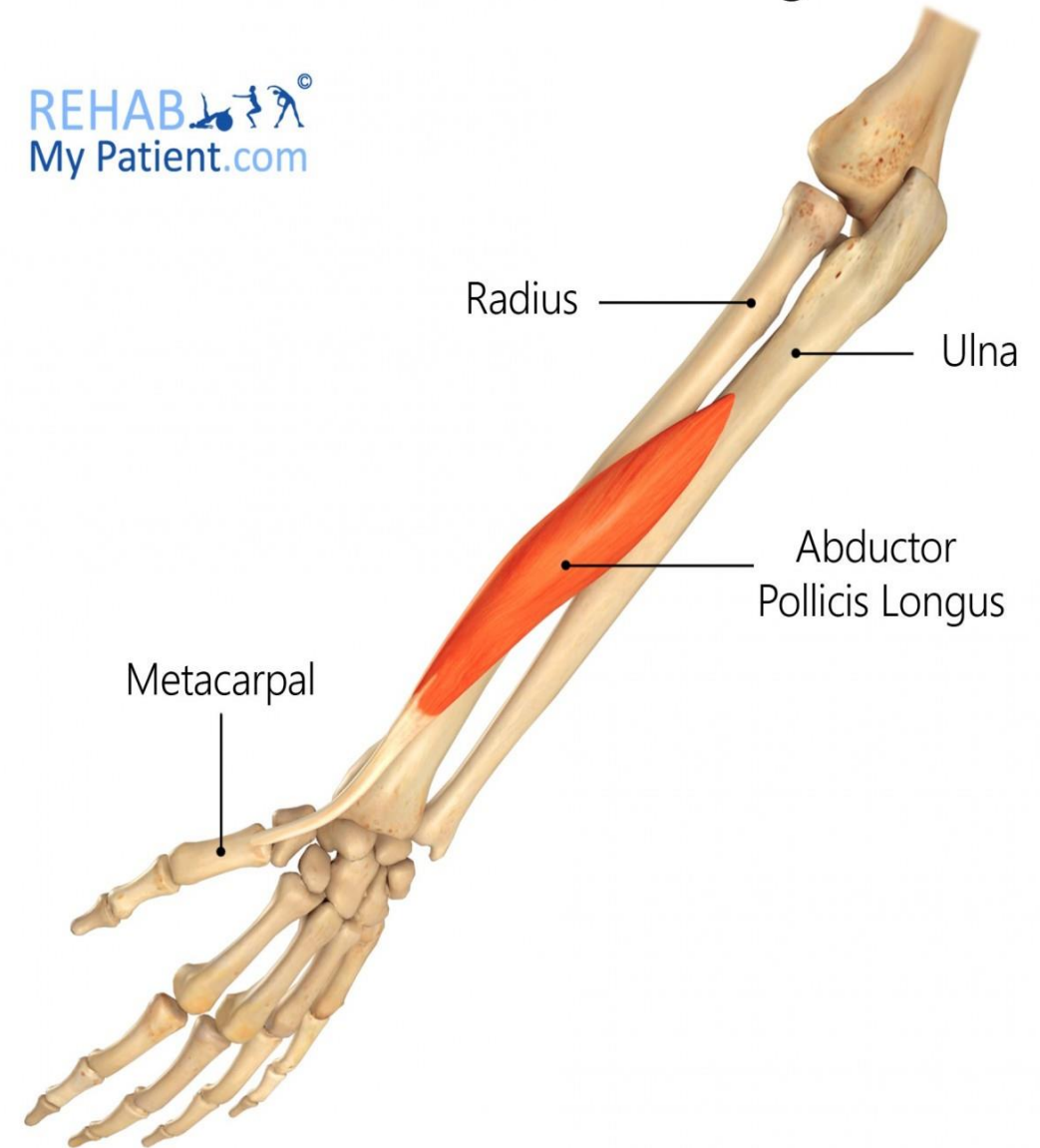Action:

Abduction of the thumb.

**Helps in Extension of the thumb at the
carpometacarpal joint.**

Abductor Pollicis Longus

REHAB
My Patient.com



3- Extensor pollicis brevis

Origin:

**Posterior surface of radius
Interosseous membrane.**

Insertion:

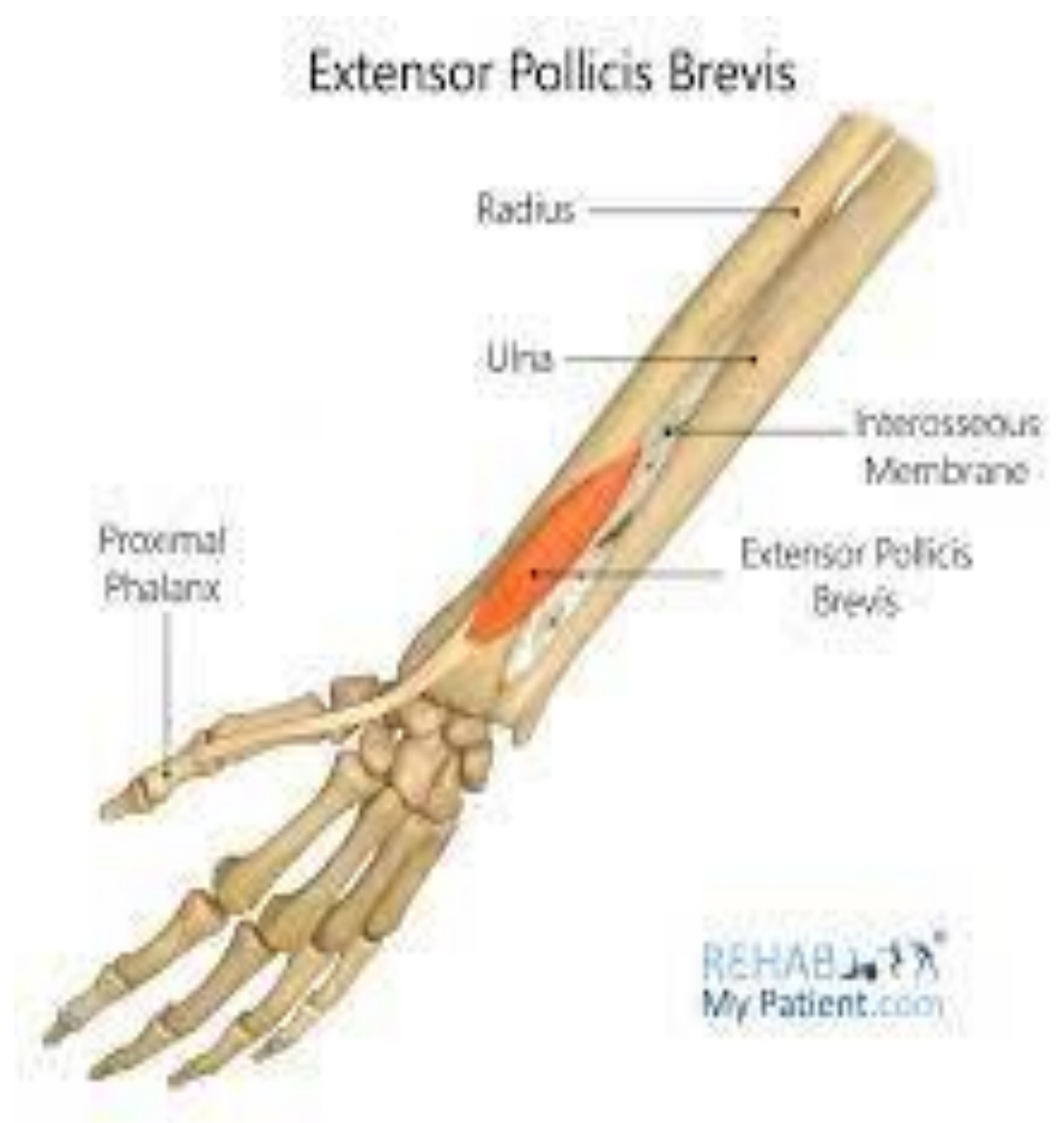Proximal phalanx of the thumb.

Nerve supply:

Posterior interosseous nerve.

Action:

**Extension of
metacarpophalangeal and
carpometacarpal joints of the
thumb**



4- Extensor pollicis longus:

Origin:

**Posterior surface of ulna
Interosseous membrane.**

Insertion:

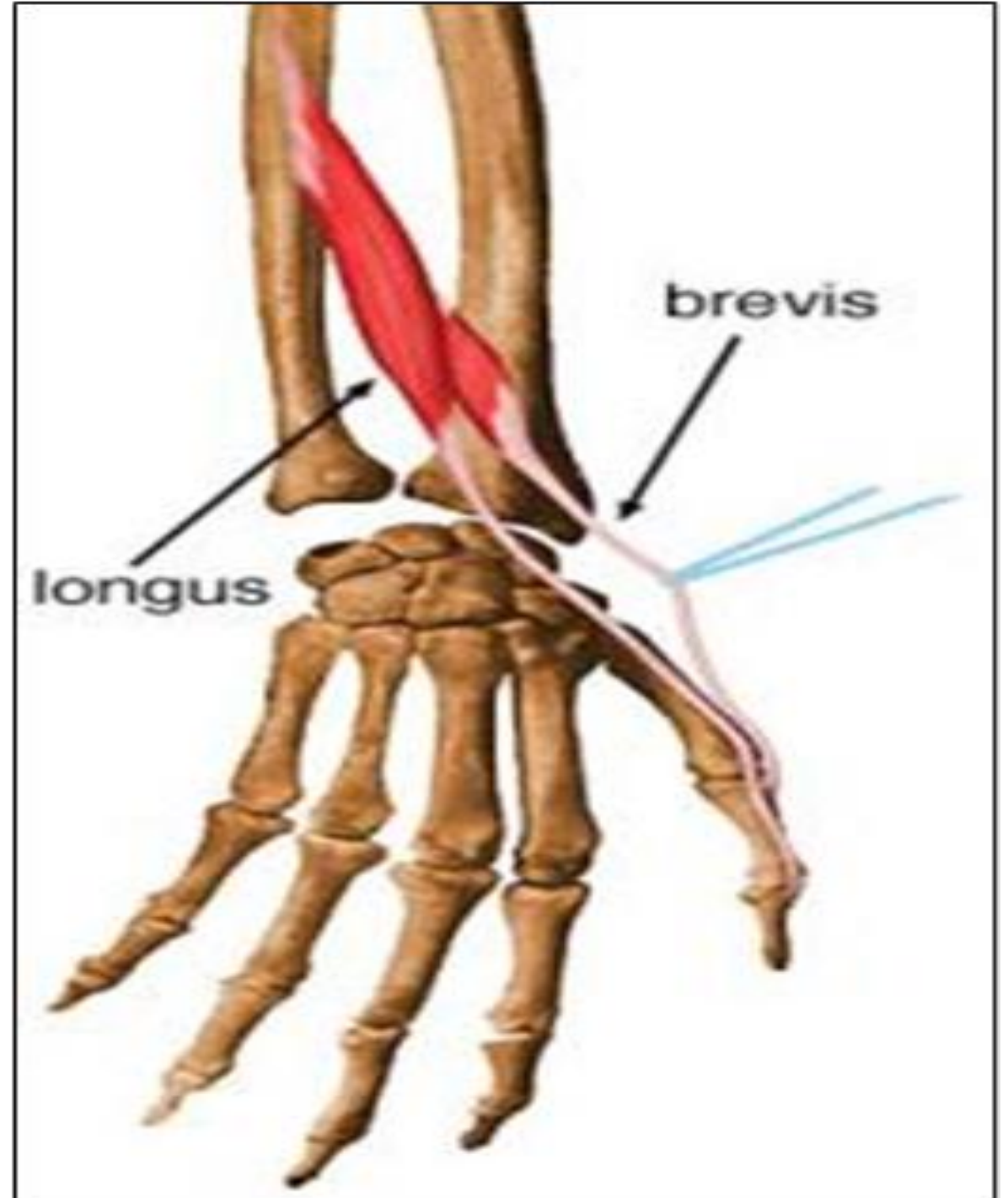
Distal phalanx of the thumb.

Nerve supply:

Posterior interosseous nerve.

Action:

Extension of all joints of the thumb.



5- Extensor indicis

Origin:

**Posterior surface of ulna
Interosseous membrane.**

Insertion:

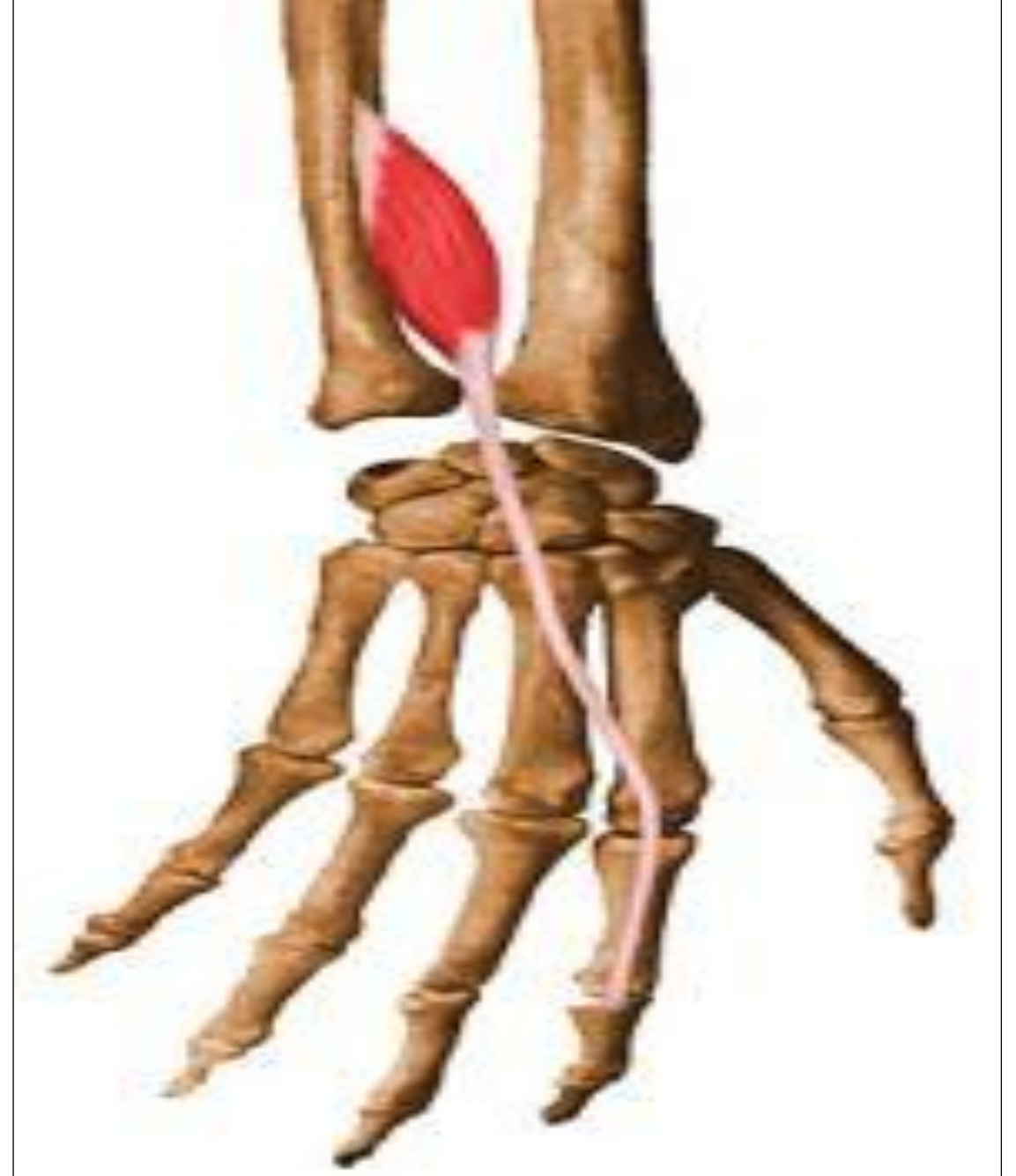
**Extensor expansion of the
index finger.**

Nerve supply:

Posterior interosseous nerve.

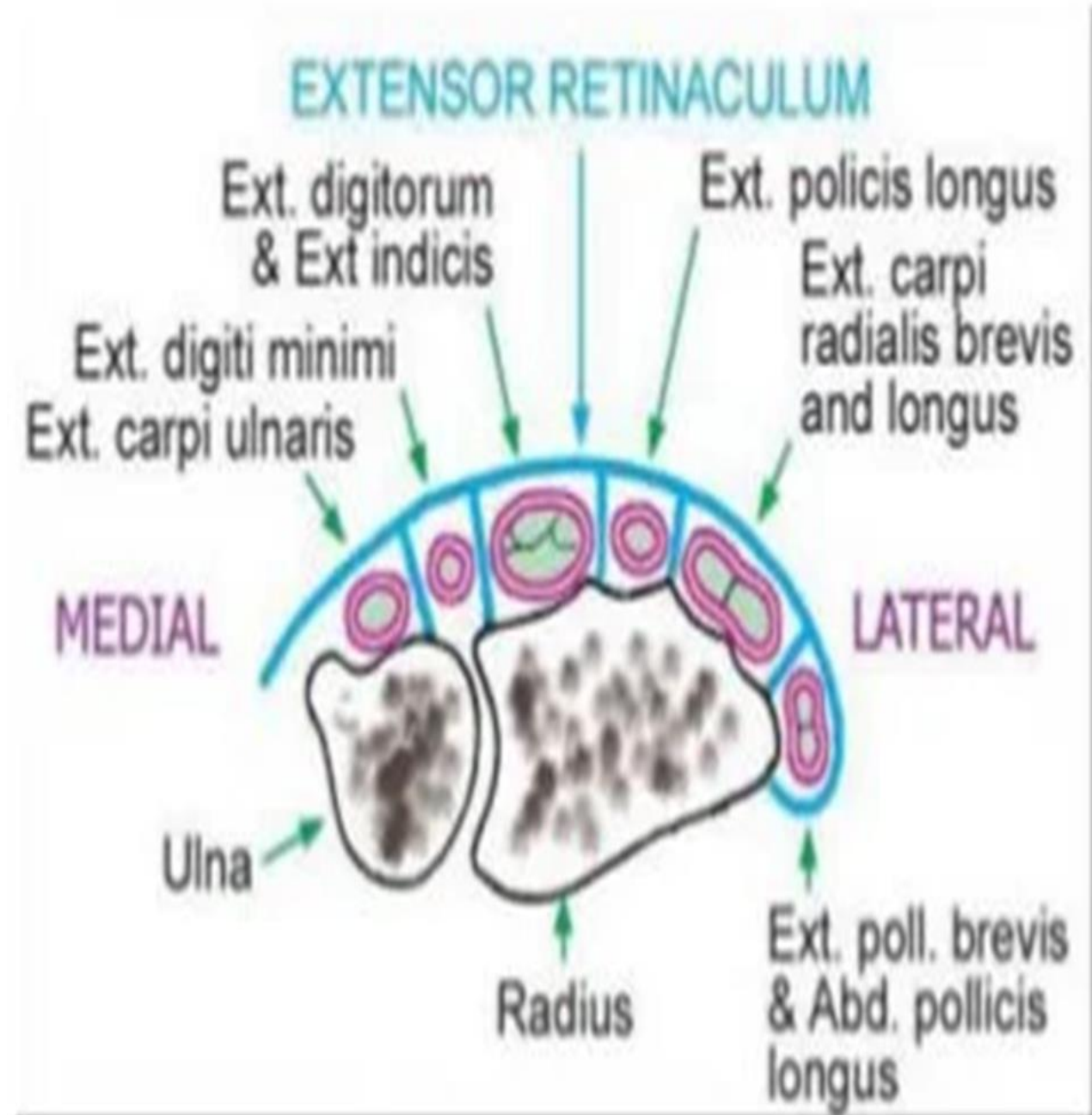
Action:

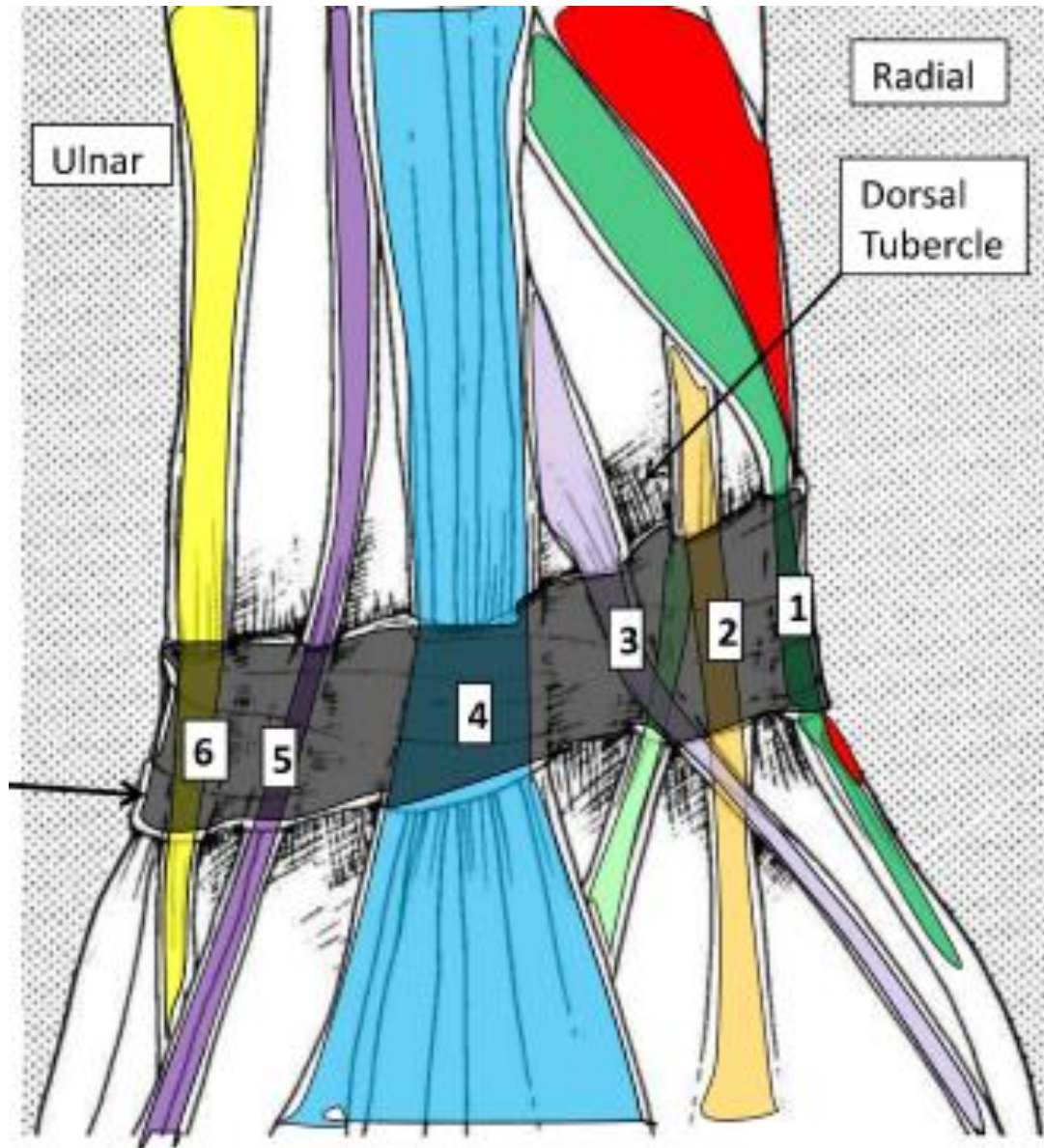
**Extension of all joints of index
finger.**



Extensor retinaculum

- It is a thickening of the deep fascia at the back of the wrist.
- It is attached laterally to the anterior border of the radius and medially to the triquetral and pisiform bones.
- It sends septa to the back of the lower end of the radius and ulna forming 6 extensor compartments.





• **Structures superficial to the extensor retinaculum:**

1. **Basilic vein.**
2. **Dorsal cutaneous branch of ulnar nerve.**
3. **Superficial radial nerve**

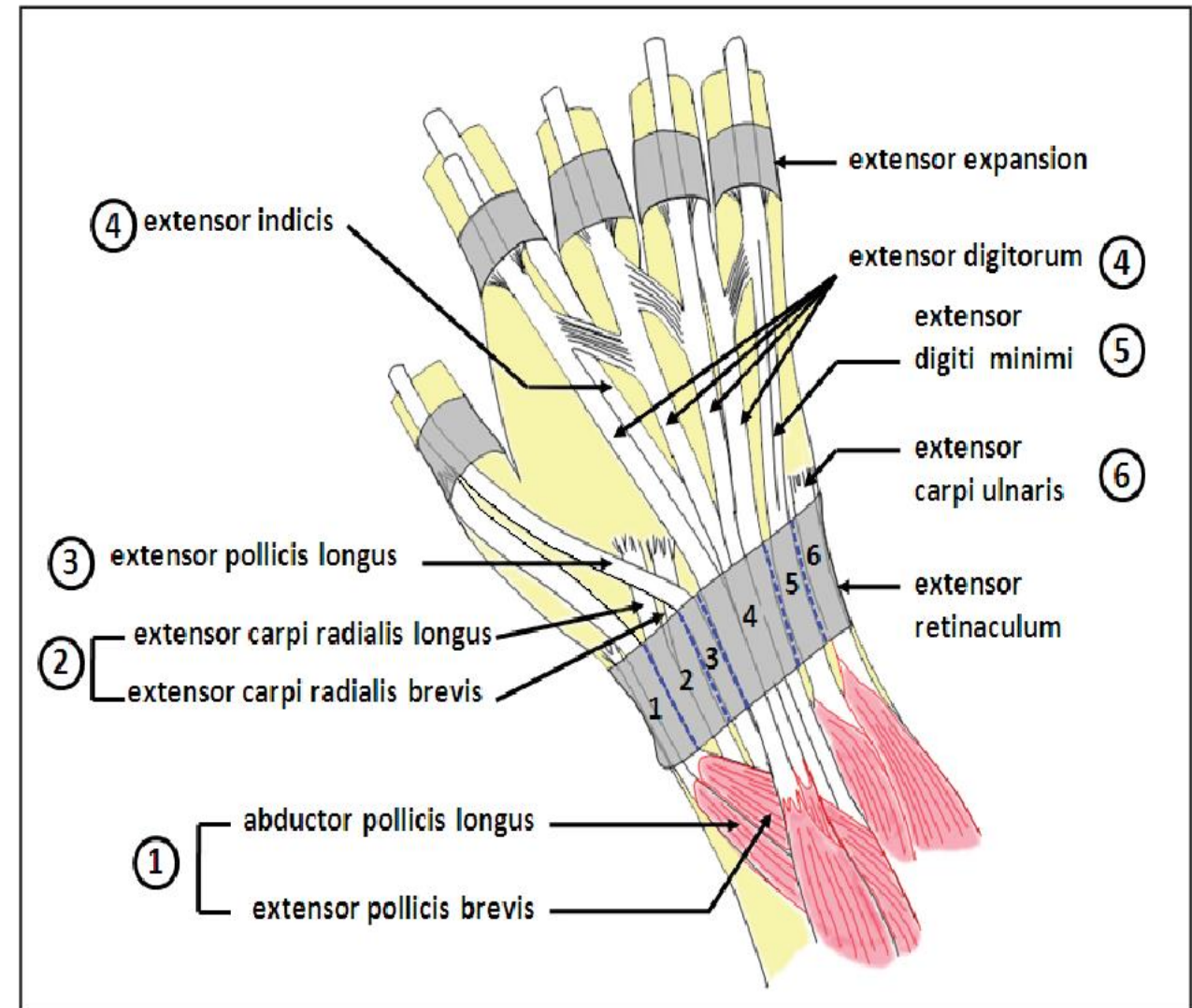


Fig. 4.9. Subcutaneous dissection of the wrist, showing the location of the tendons (1-6) of the muscles of the hand.