

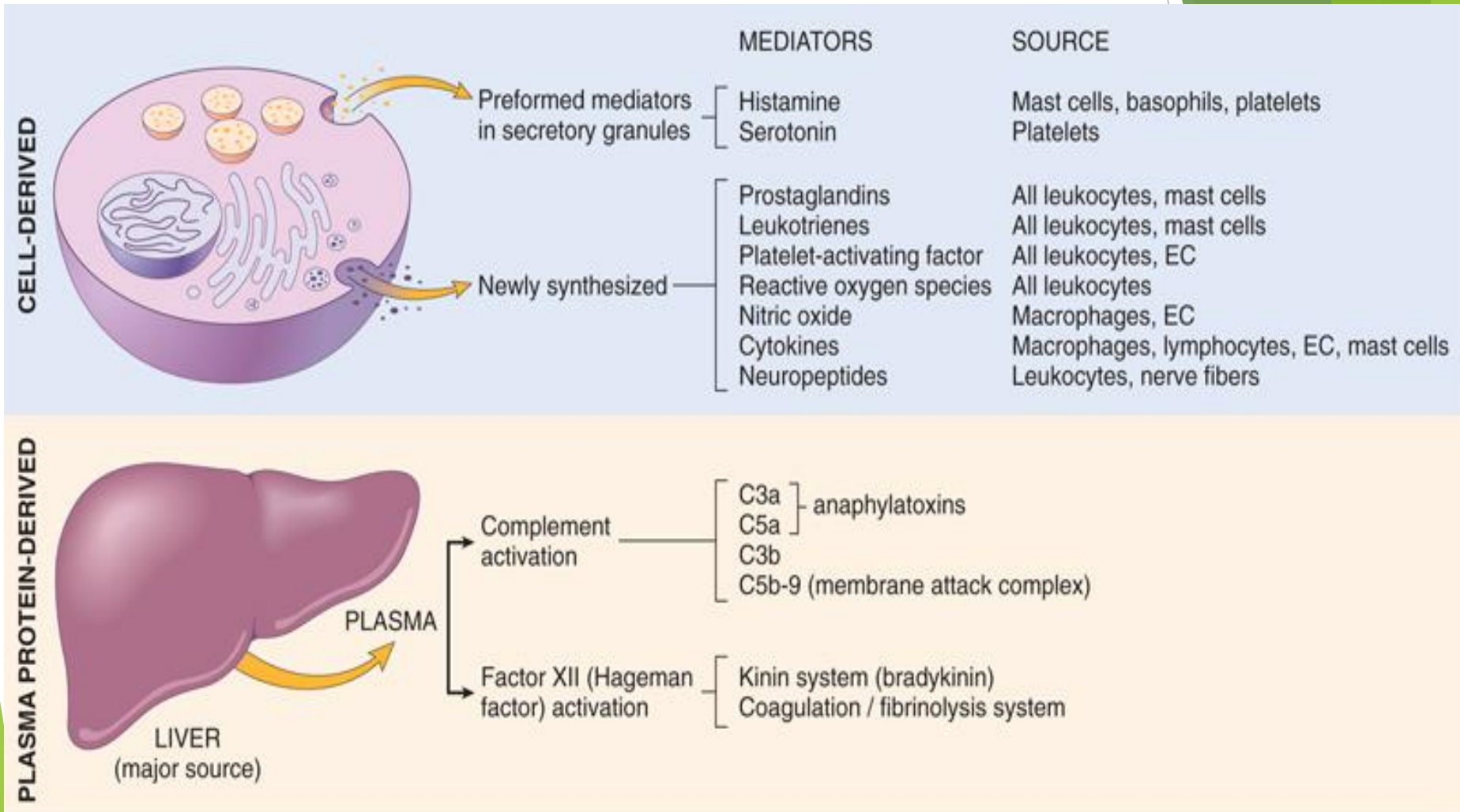
Inflammation IV

Morphology of Inflammation

Dr. Sura Al-Rawabdeh M.D.

6-11-2023

Systemic Mediators of Inflammation



Products of Coagulation

- ▶ Studies performed more than 50 years ago suggested that inhibiting coagulation reduced the inflammatory reaction to some microbes, leading to the idea that coagulation and inflammation are linked processes.
- ▶ This concept was supported by the discovery of **protease-activated receptors (PARs)**, which are activated by **thrombin** (the protease that cleaves fibrinogen to produce a fibrin clot).

Products of Coagulation

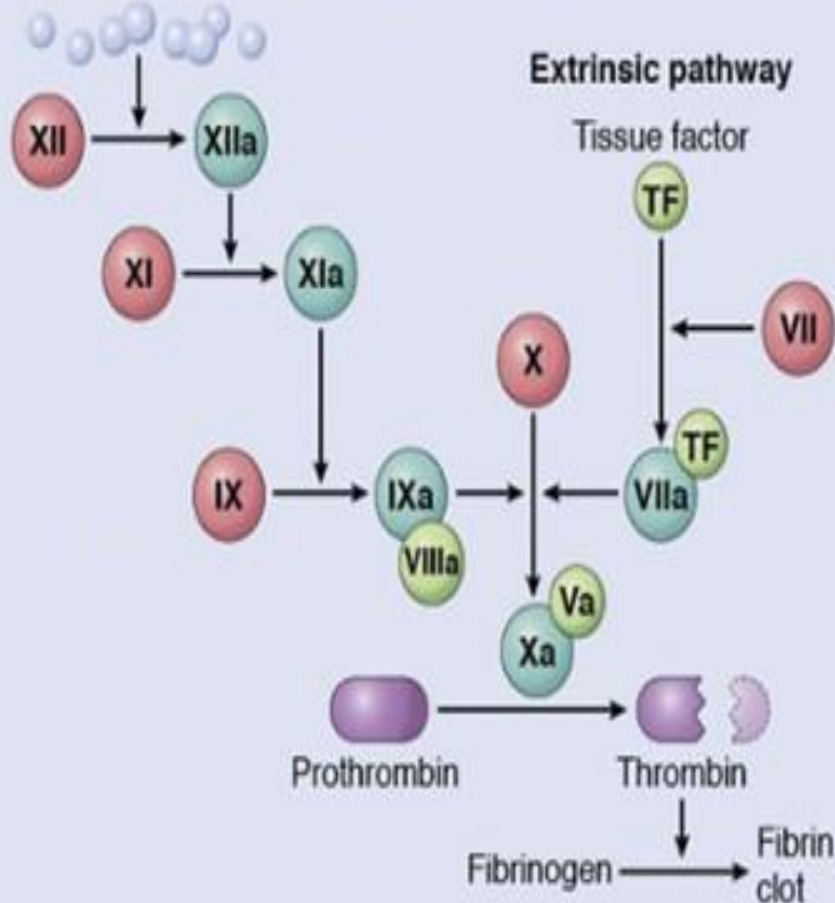
- ▶ **PARs** are expressed on **leukocytes**, suggesting a role in inflammation, but their clearest role is in **platelets**, in which thrombin activation of a PAR known as the thrombin receptor is a potent trigger of platelet aggregation during the process of clot formation.
- ▶ All forms of tissue injury that lead to clotting also induce inflammation, and inflammation causes changes in endothelial cells that increase The likelihood of abnormal clotting.

Clotting / Fibrinolytic system

CLOTING IN THE LABORATORY

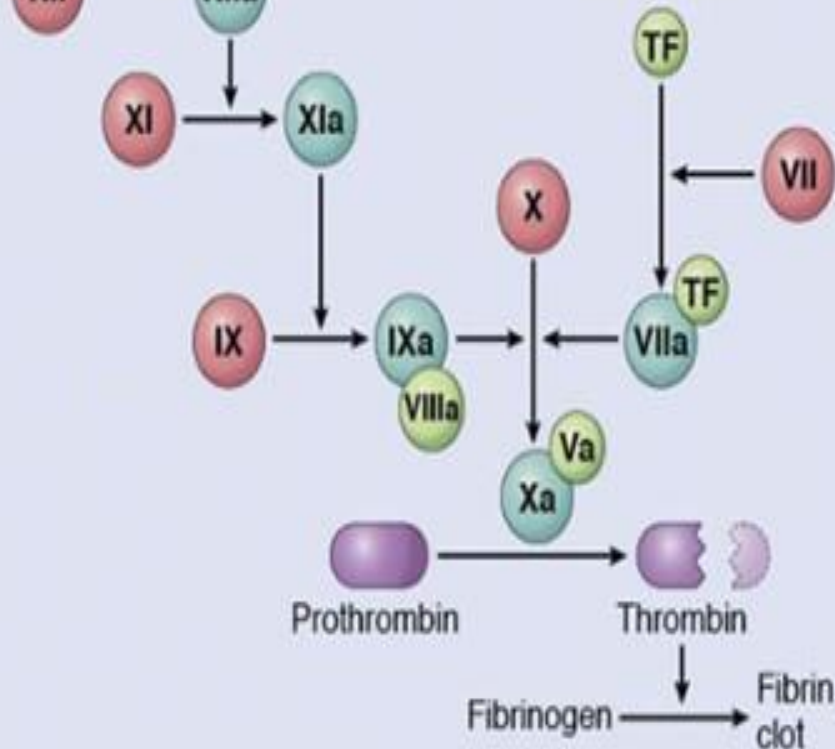
Intrinsic pathway

Negatively charged surface
(e.g., glass beads)



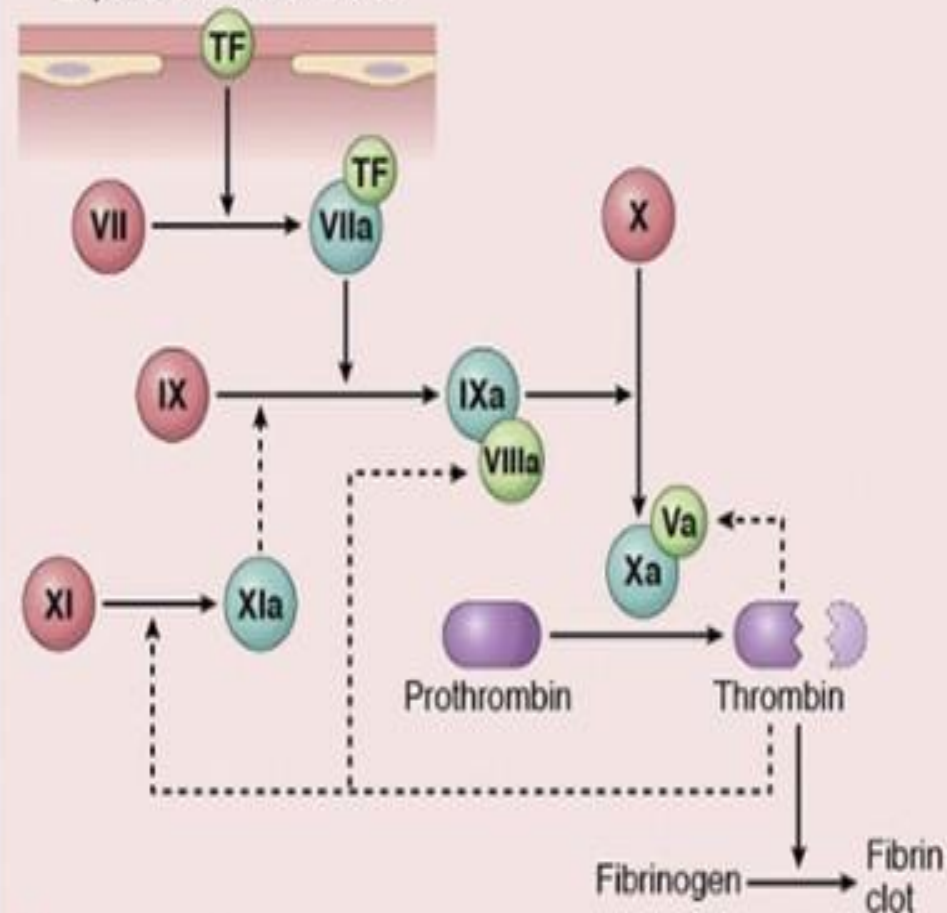
Extrinsic pathway

Tissue factor



CLOTING IN VIVO

Vascular damage
Exposure of tissue factor



A

B

Clotting / Fibrinolytic system

- ▶ **Fibrin clot** at site of injury helps in containing the cause.
- ▶ **Fibrin clot** provides a framework for inflammatory cells.
- ▶ **Xa** causes increased vascular permeability and leukocytes emigration
- ▶ **Thrombin** causes leukocytes adhesion, platelets aggregation, generation of fibrinopeptides, and is chemotactic.
- ▶ Fibrinopeptides are chemotactic & induce vasopermeability.

Clotting / fibrinolytic system

- ▶ **XIIa** also activates the fibrinolytic pathway to prevent widespread thrombosis.
- ▶
- ▶ **Fibrin split products** increase vascular permeability.
- ▶ **Plasmin** cleaves **C3 to form C3a**, leading to dilatation and increased permeability.
- ▶ **Plasmin** activates XIIa amplifying the entire process.

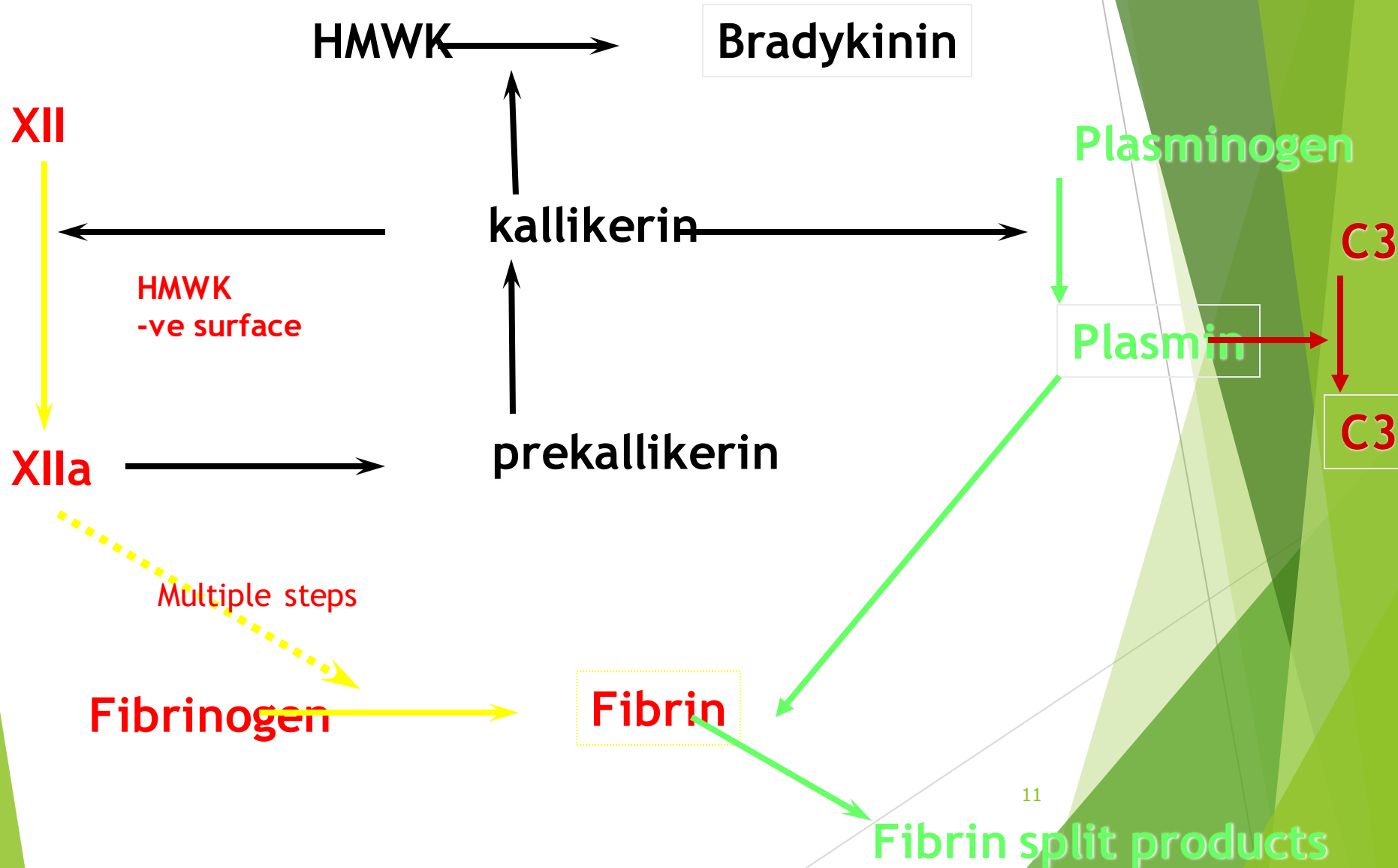
Thrombin as an Inflammatory Mediator

- ▶ Binds to protease-activated receptors (PARs) expressed on platelets, endothelial cells, smooth muscles leading to:
 - ▶ P-selectin mobilization
 - ▶ Expression of integrin ligands
 - ▶ Chemokine production
 - ▶ Prostaglandin production by activating cyclooxygenase-2
 - ▶ Production of PAF
 - ▶ Production of NO

Kinin System

- ▶ Vasoactive peptides derived from plasma proteins, called **kininogens**, by the action of specific proteases called **kallikreins**.
- ▶ Leads to formation of **bradykinin** from **HMWK**.
- ▶ Effects of bradykinin
 - ▶ Increased vascular permeability
 - ▶ Arteriolar dilatation
 - ▶ Bronchial smooth muscle contraction
 - ▶ Pain
- ▶ Short half-life (inactivated by kininases)

Interaction between the four plasma mediator systems



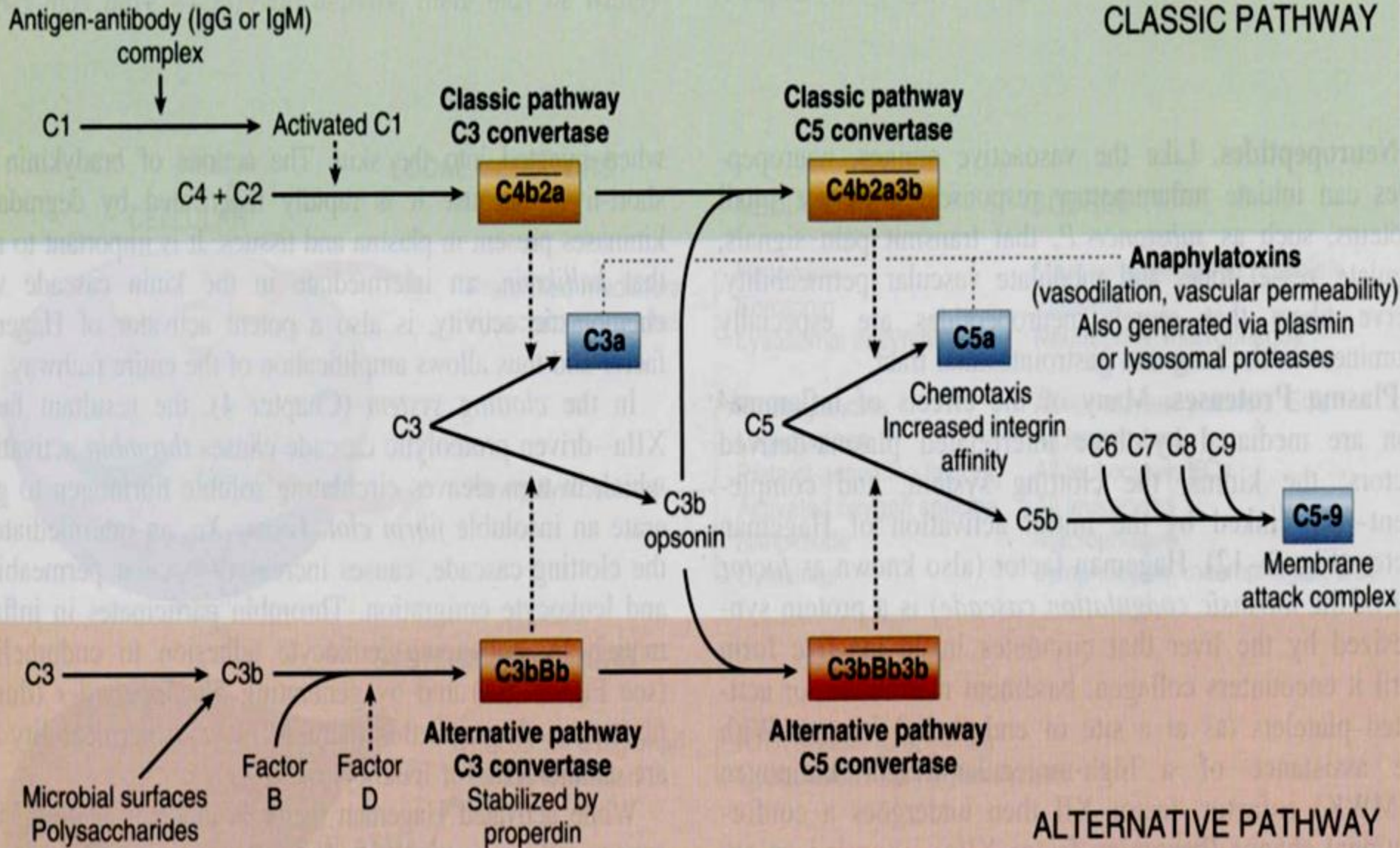
The Complement System in Inflammation

- ▶ The complement system is a collection of soluble proteins and their membrane receptors that function mainly in host defense against microbes and in pathologic inflammatory reactions.
- ▶ More than 20 complement proteins, some of which are numbered C1 through C9.
- ▶ They function in both innate and adaptive immunity for defense against microbial pathogens.
- ▶ Several cleavage products of complement proteins are elaborated that cause **increased vascular permeability, chemotaxis, and opsonization.**

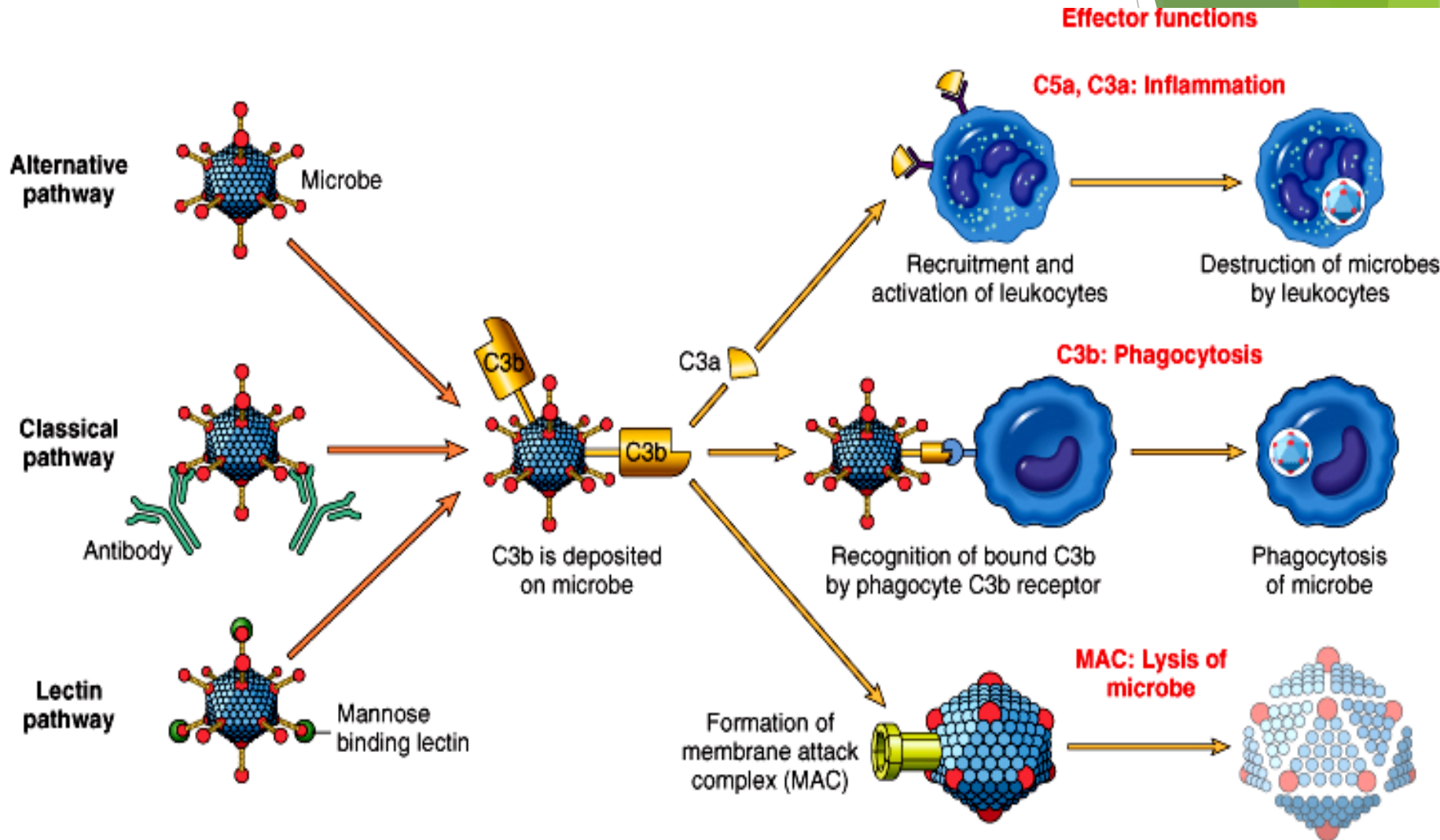
The Complement System in Inflammation

- ▶ C3a and C5a (**anaphylatoxins**) increased vascular permeability, and cause mast cell to secrete histamine
- ▶ C5a activates lipoxygenase pathway of AA
- ▶ C5a activates leukocytes, increased integrins affinity
- ▶ C5a is **chemotactic**
- ▶ C3b and iC3b are **opsonins**
- ▶ Plasmin and proteolytic enzymes split C3 and C5
- ▶ Membrane attack complex (C5-9) **lyse** bacterial membranes

Complement Activation Pathways



Complement Role in Inflammation



Defects in the Complement System

- ▶ Deficiency of C3 → susceptibility to **infections**.
- ▶ Deficiency of C2 and C4 → susceptibility to **SLE**.
- ▶ Deficiency of late components → low MAC → **Neisseria infections**.
- ▶ ↓ inhibitors of C3 and C5 convertase (↓ DAF) → **hemolytic anemia (PNH)**
(**Decay-accelerating Factor or CD55**)
- ▶ ↓ C1 inhibitor → **angioneurotic edema**

Reaction of Inflammation	Principal Mediators
Vasodilation	Histamine Prostaglandins
Increased vascular permeability	Histamine C3a and C5a (by liberating vasoactive amines from mast cells, other cells) Leukotrienes C ₄ , D ₄ , E ₄
Chemotaxis, leukocyte recruitment and activation	TNF, IL-1 Chemokines C3a, C5a Leukotriene B ₄
Fever	IL-1, TNF Prostaglandins
Pain	Prostaglandins Bradykinin

Morphologic Appearance of Acute Inflammation

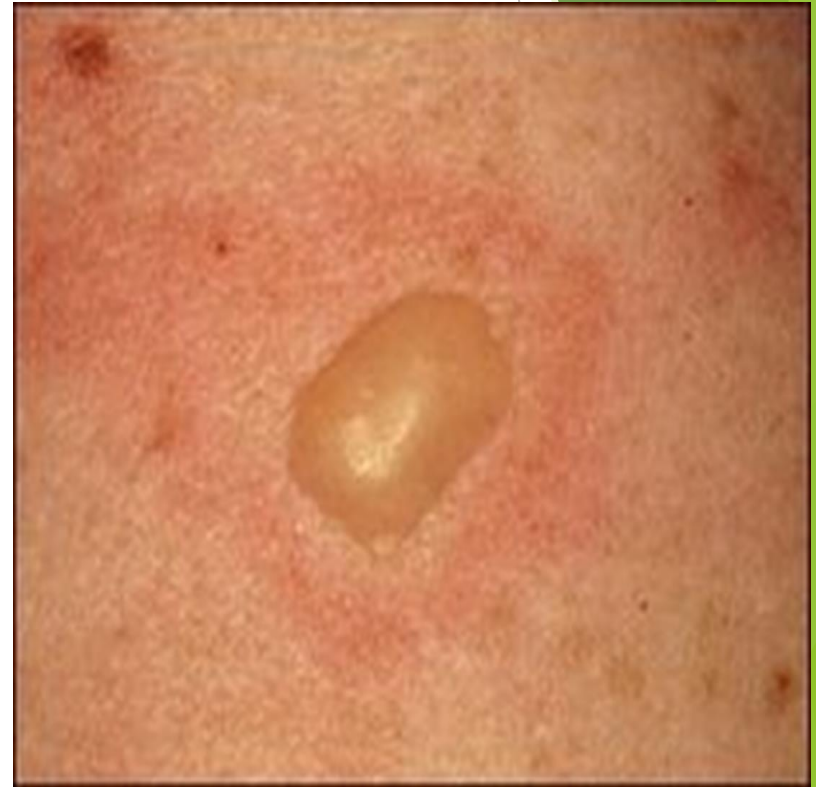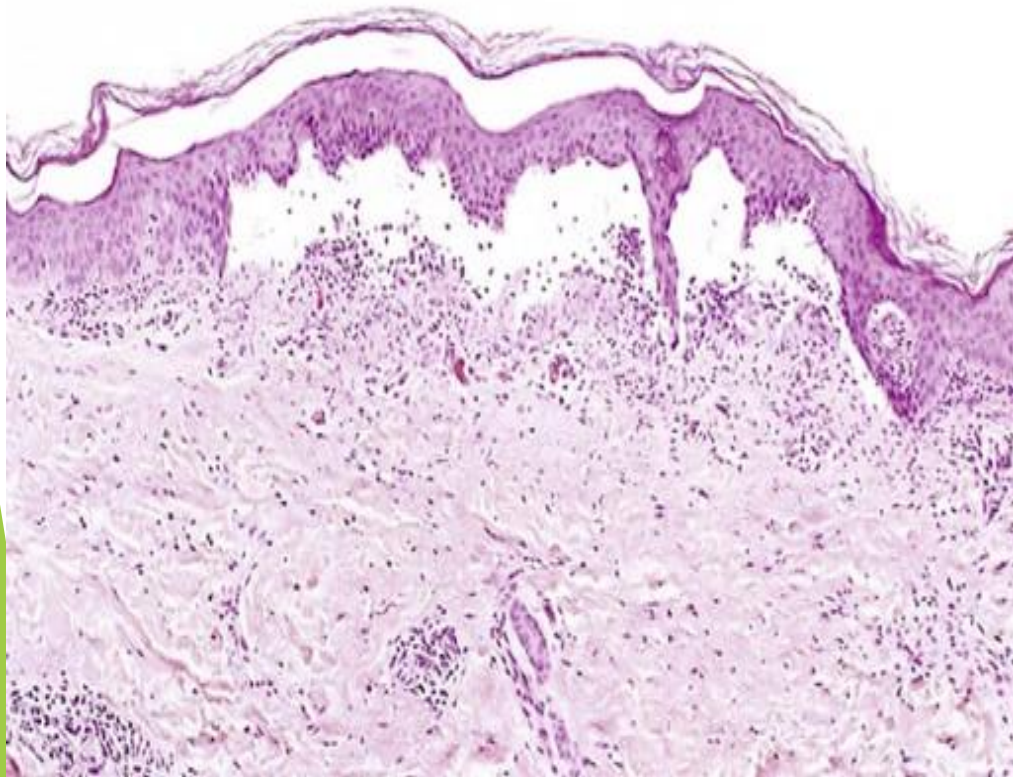
- ▶ The morphologic hallmarks of acute inflammatory reactions are dilation of small blood vessels and accumulation of leukocytes and fluid in the extravascular tissue.
- ▶ Special morphologic patterns are often superimposed on them, depending on the severity of the reaction, its specific cause, and the particular tissue and site involved
- ▶ The importance of recognizing distinct gross and microscopic patterns of inflammation is that they often provide valuable clues about the underlying cause.

Morphologic Appearance of Acute Inflammation

- ▶ **Catarrhal**
 - ▶ Acute inflammation + mucous hypersecretion (e.g. common cold).
- ▶ **Serous**
 - ▶ Abundant protein-poor fluid with low cellular content, e.g. skin blisters and body cavities.
- ▶ **Fibrinous:**
 - ▶ Accumulation of thick exudate rich in fibrin, may resolve by fibrinolysis or organize into thick fibrous tissue (e.g. acute pericarditis).

Serous inflammation

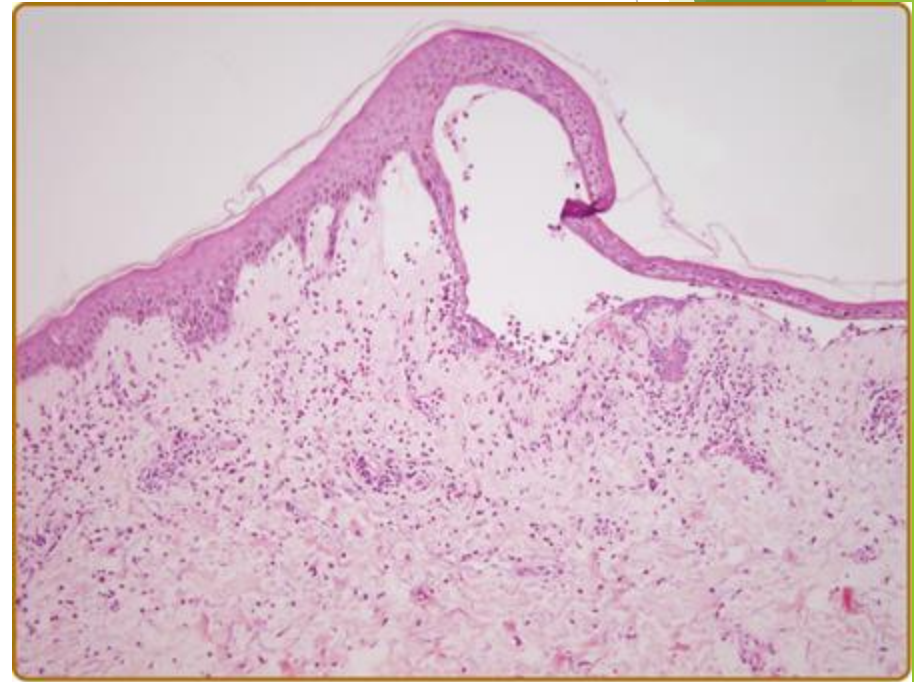
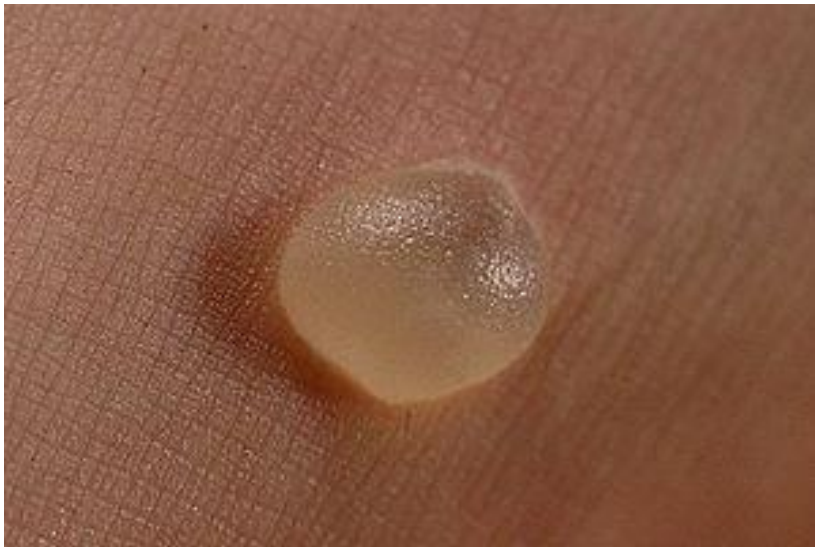Marked by the exudation of cell-poor fluid into spaces created by injury to surface epithelia or into body cavities lined by the peritoneum, pleura, or pericardium.



Burn Bister

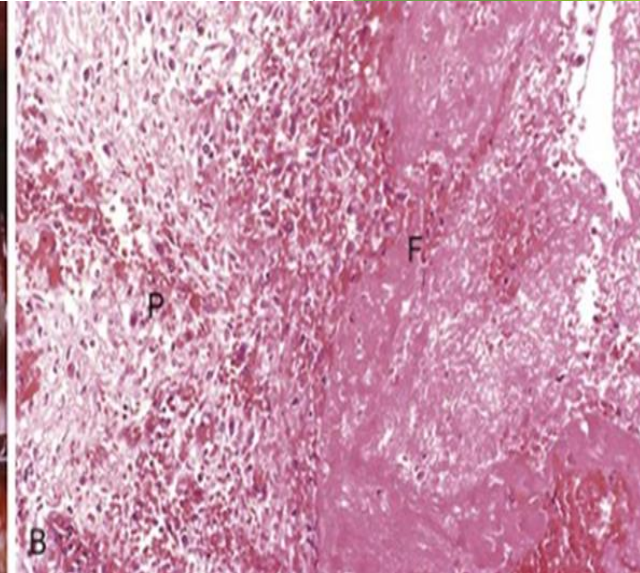
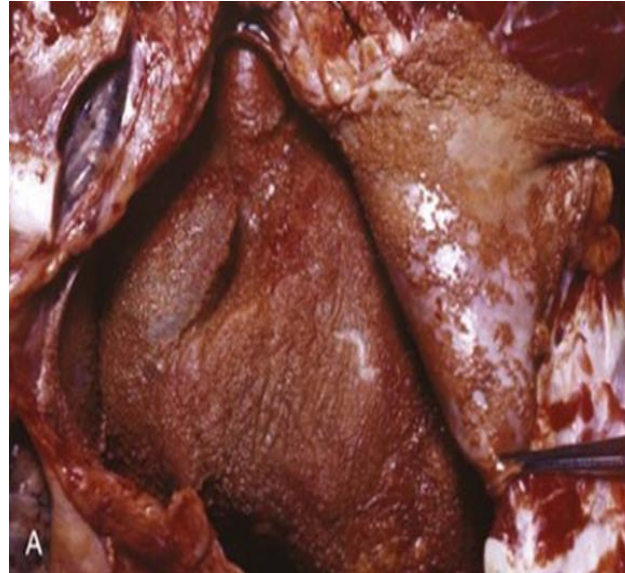
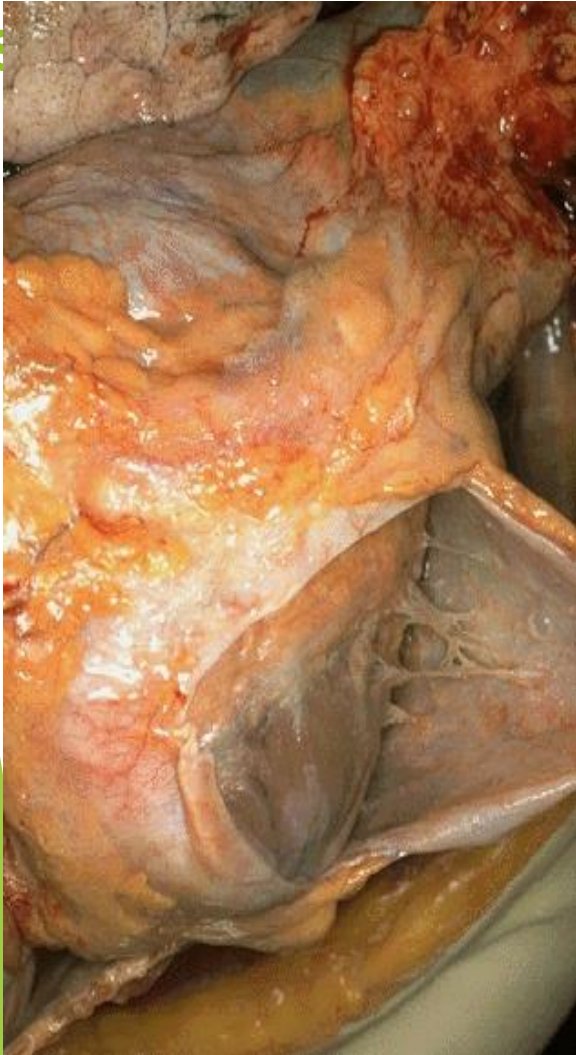❖ skin blister

- ▶ Resulting from a burn or viral infection.
- ▶ Represents accumulation of serous fluid within or immediately beneath the damaged epidermis of the skin



Fibrinous Pericarditis

A fibrinous exudate develops when the vascular leaks are large or there is a local procoagulant

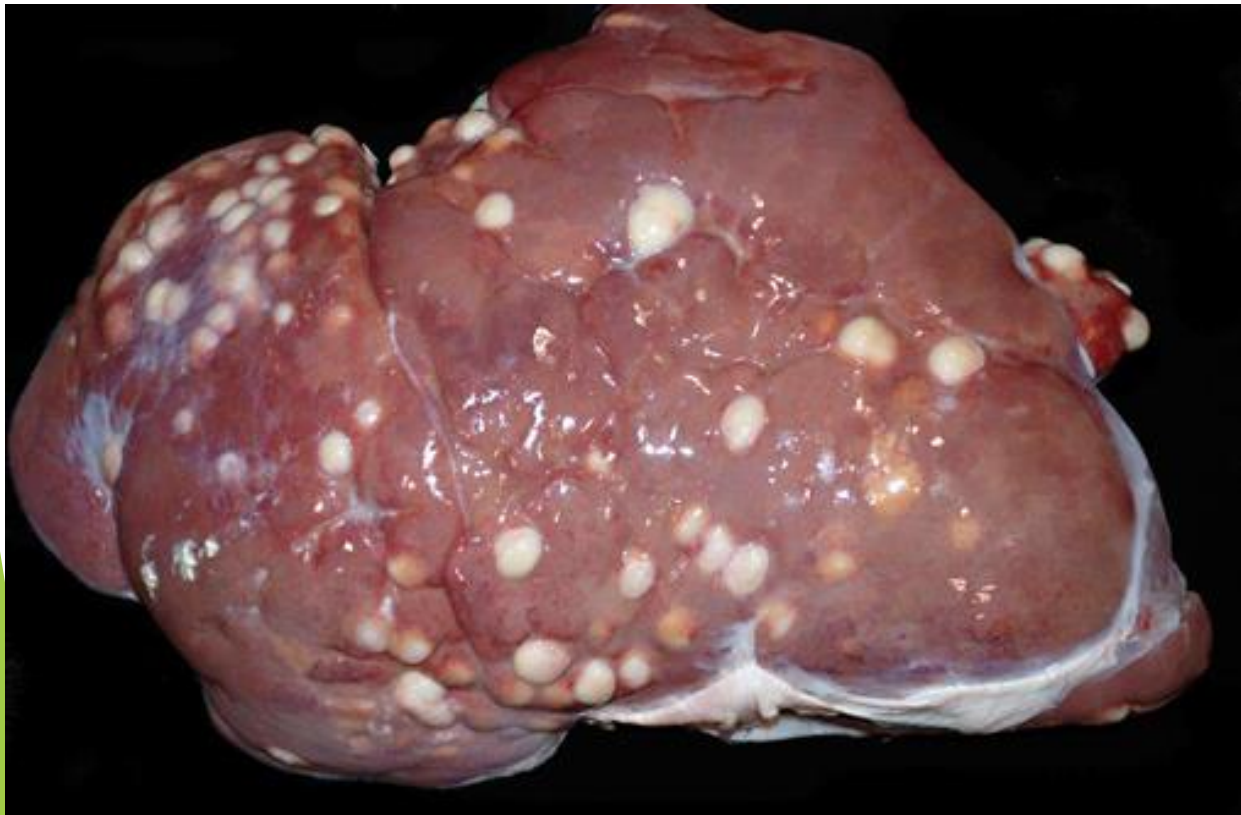


Morphologic Appearance of Acute Inflammation

- ▶ **Suppurative (purulent):**
 - ▶ Pus: Creamy yellow or blood stained fluid consisting of neutrophils, microorganisms & tissue debris e.g. acute appendicitis
 - ▶ Abscess: Focal localized collection of pus
 - ▶ Empyema: Collection of pus within a hollow organ
- ▶ **Ulcers:**
 - ▶ Defect of the surface lining of an organ or tissue
 - ▶ Mostly GI tract or skin

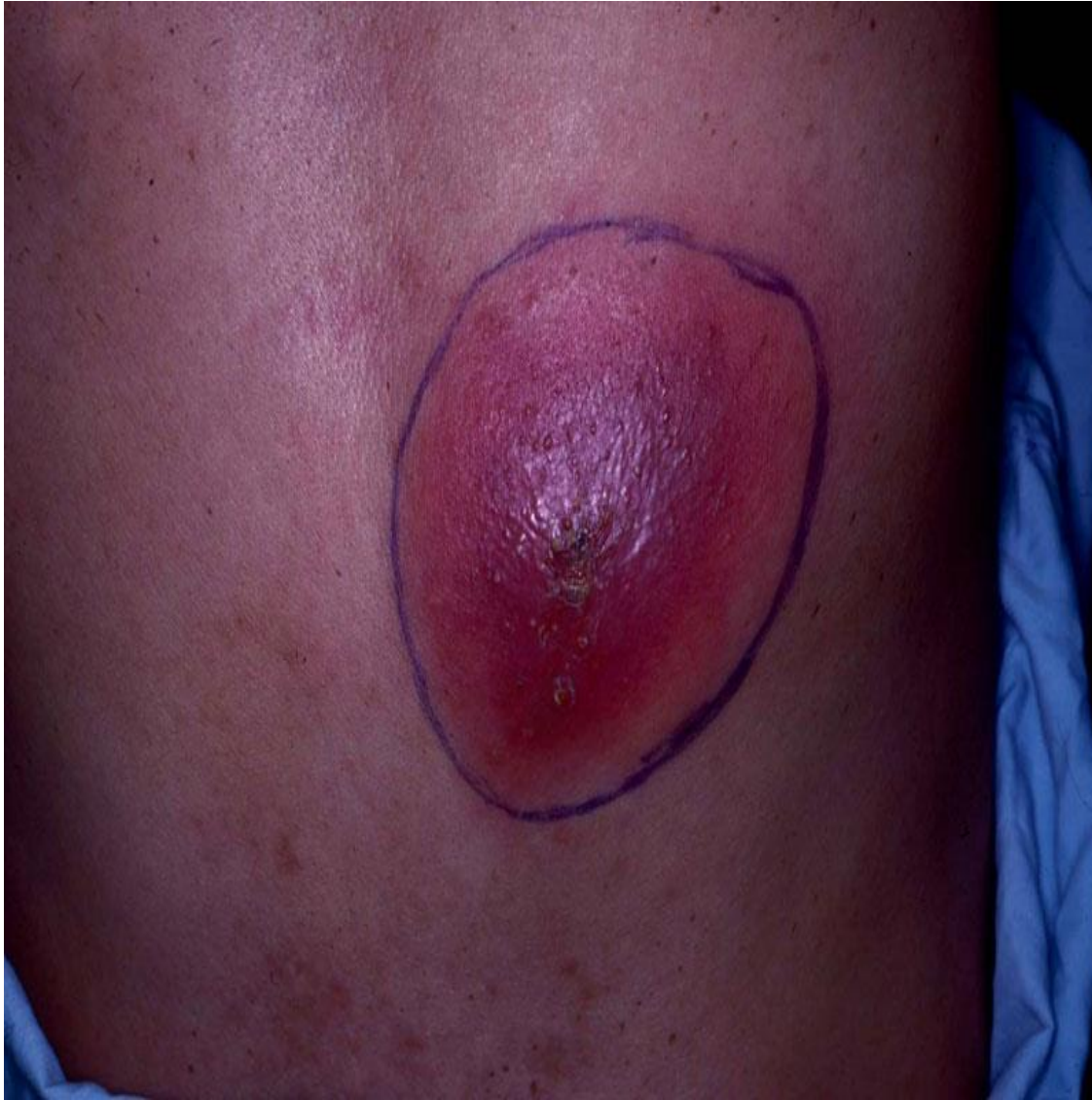▶ **Abscesses:**

- ▶ are localized collections of pus caused by suppuration buried in a tissue, an organ, or a confined space.
- ▶ They are produced by seeding of pyogenic bacteria into a tissue . In time the abscess may become walled off and ultimately replaced by connective tissue

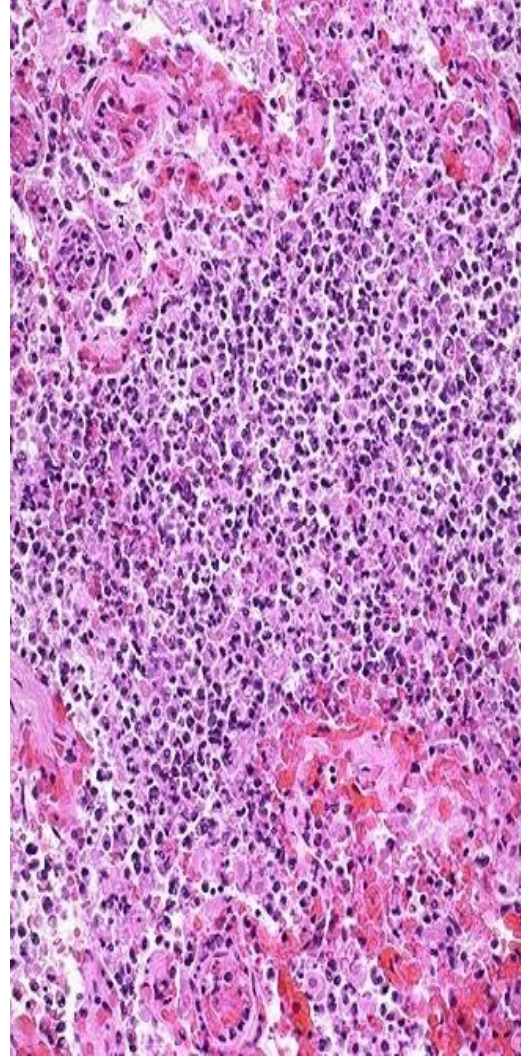
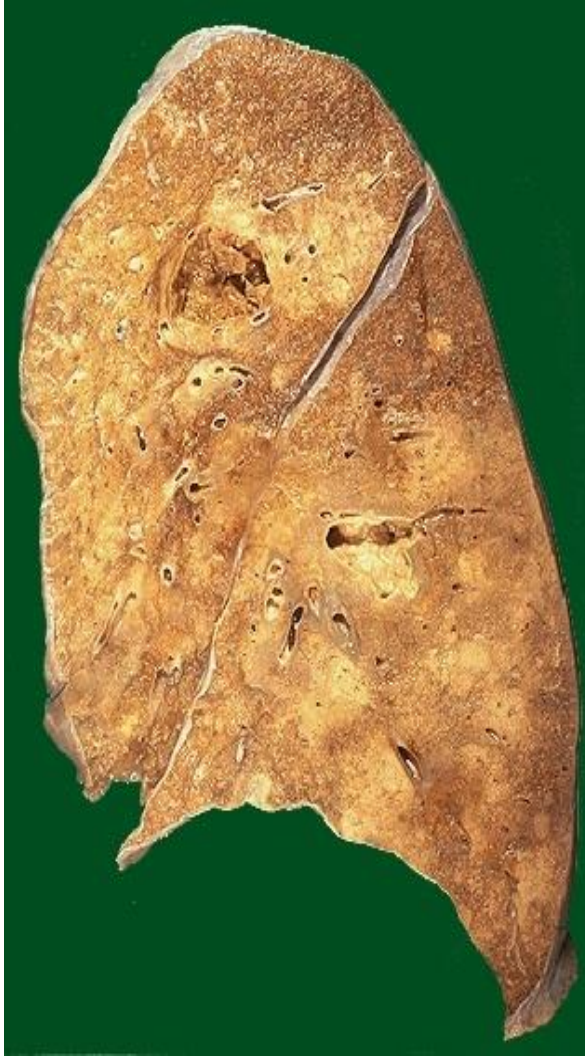

Variably sized abscesses are distributed randomly throughout all lobes of the liver.

Subcutaneous Abscess



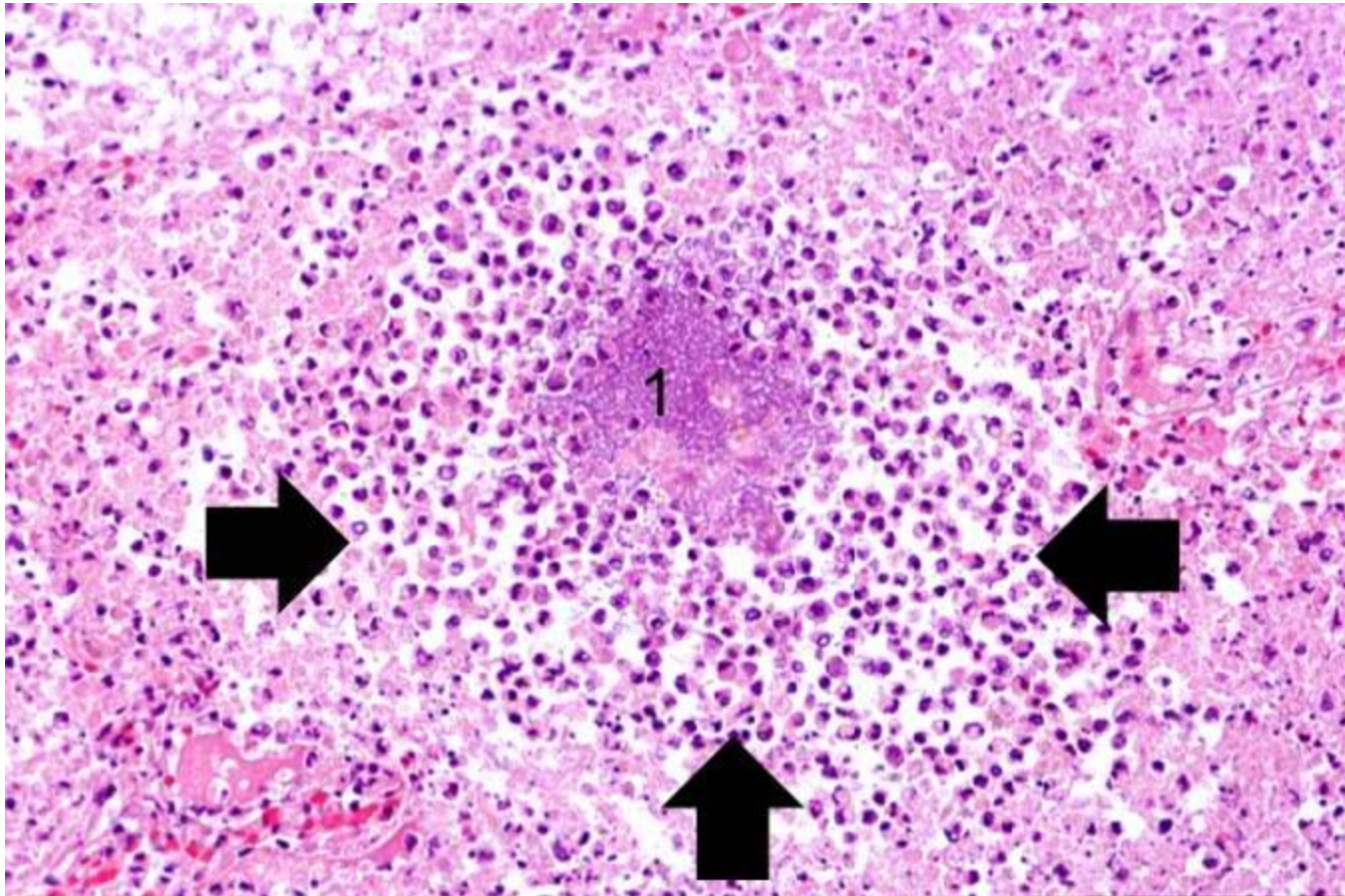
Lung Abscess



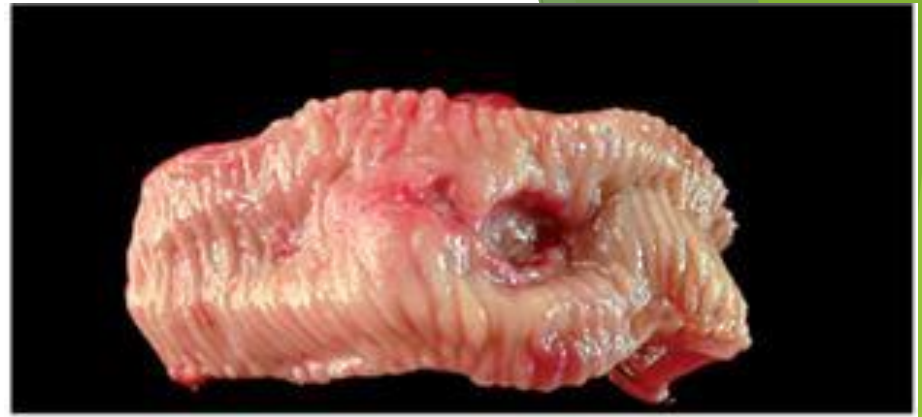Abscesses have a central region that appears as a mass of necrotic leukocytes and tissue cells.

There is usually a zone of preserved neutrophils around this necrotic focus.

outside this region there may be vascular dilation and parenchymal and fibroblastic proliferation, indicating chronic inflammation and repair.

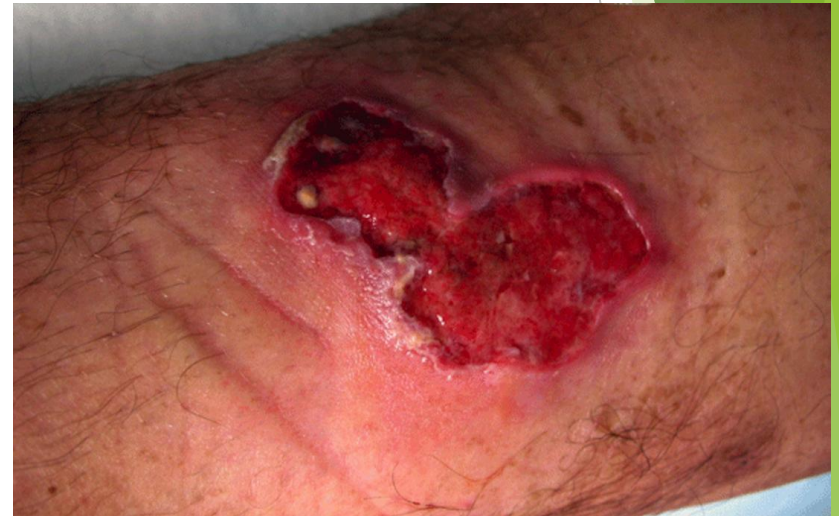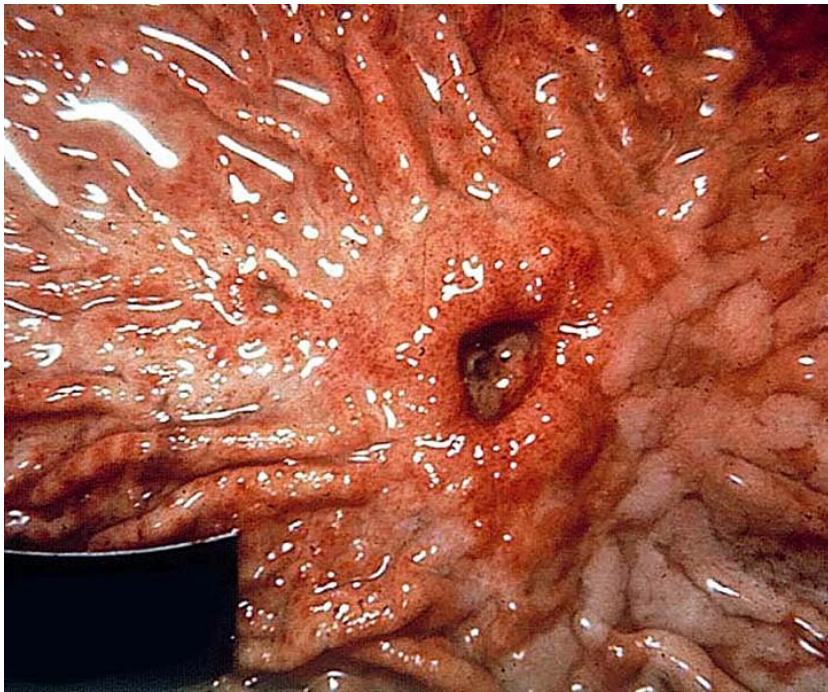


Ulcers

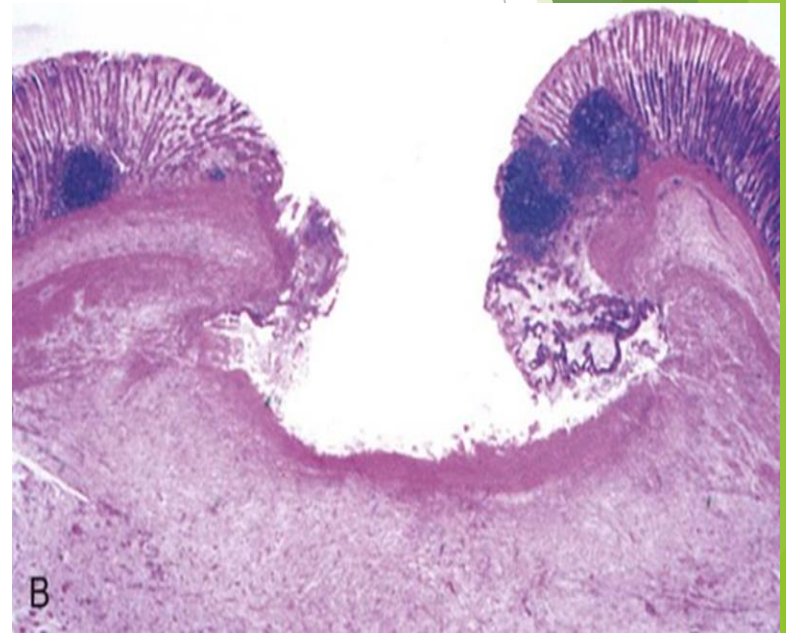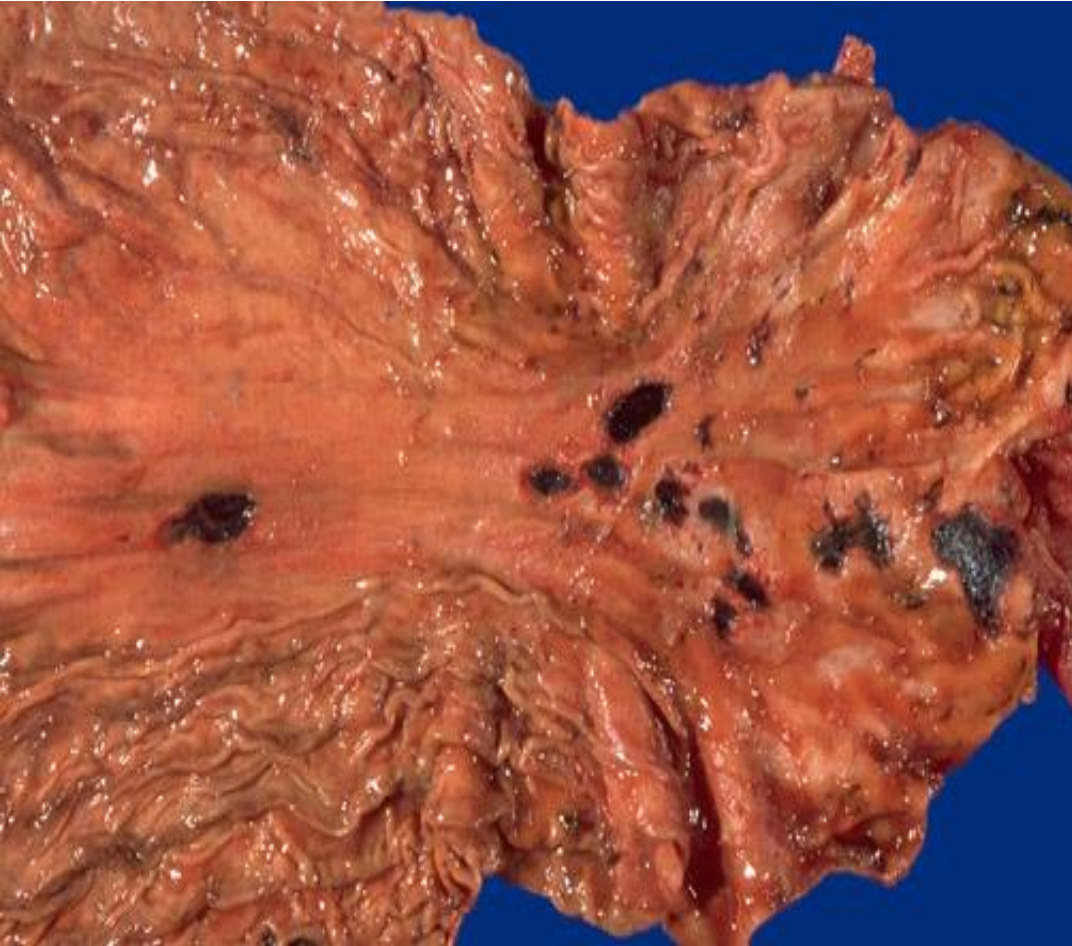


- ▶ An ulcer is a local defect, or excavation, of the surface of an organ or tissue that is produced by the sloughing (shedding) of inflamed necrotic tissue.
- ▶ Ulceration can occur only when tissue necrosis and resultant inflammation exist on or near a surface

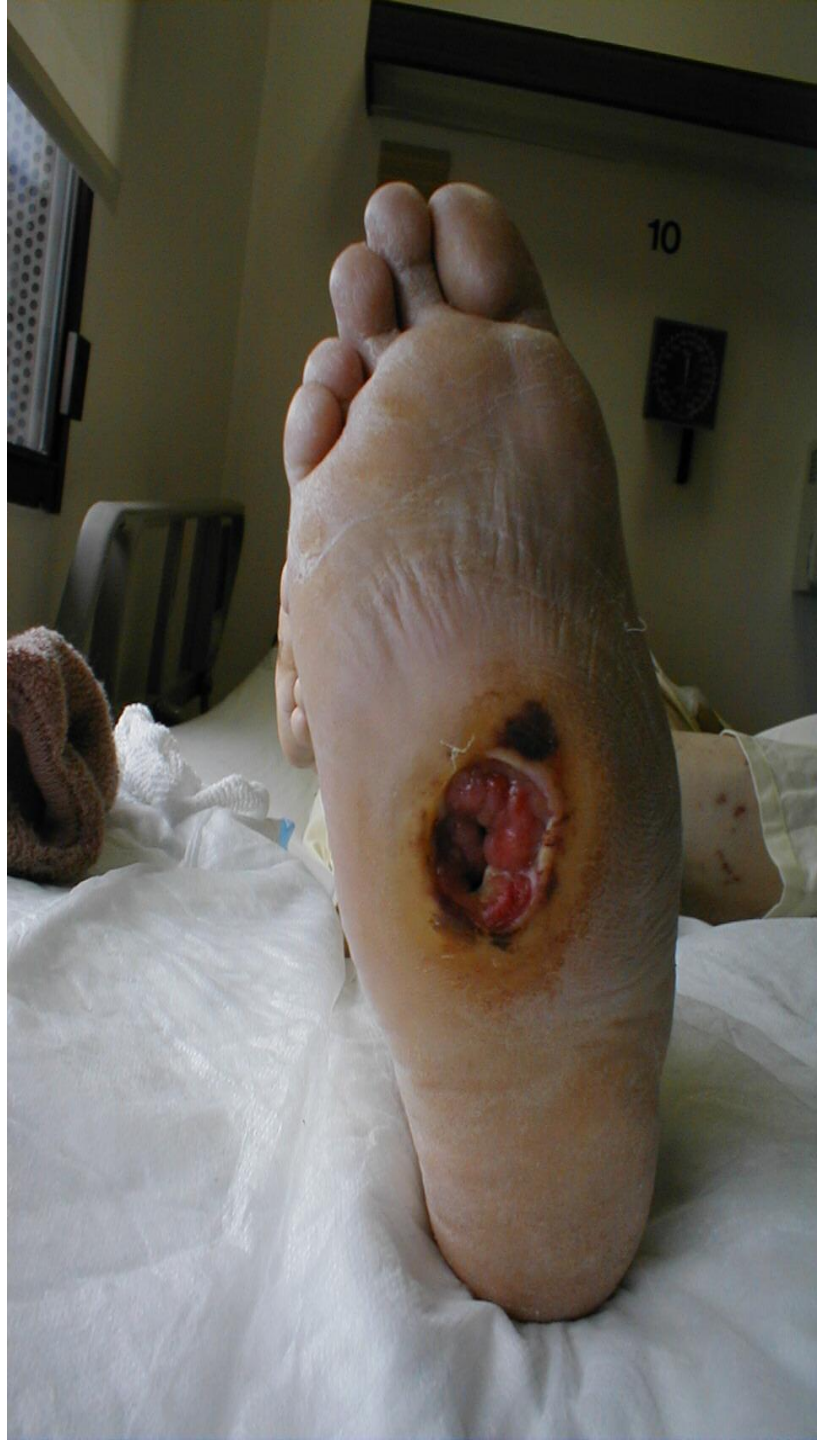- ▶ It is most commonly encountered in:
- ▶ (1) the mucosa of the mouth, stomach, intestines, or genitourinary tract.
- ▶ (2) the skin and subcutaneous tissue of the lower extremities in older persons



Gastric Ulcers



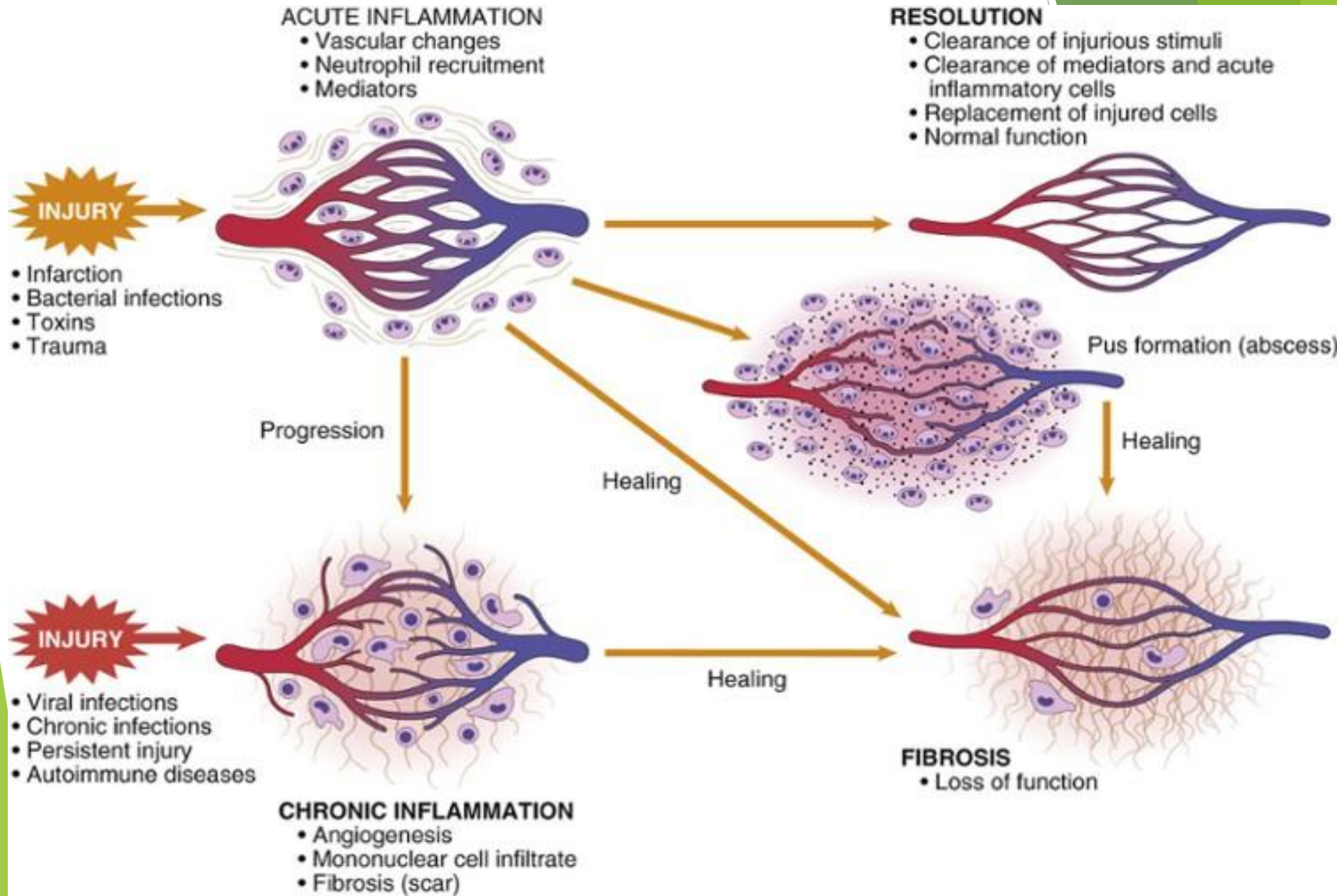
Foot Ulcer



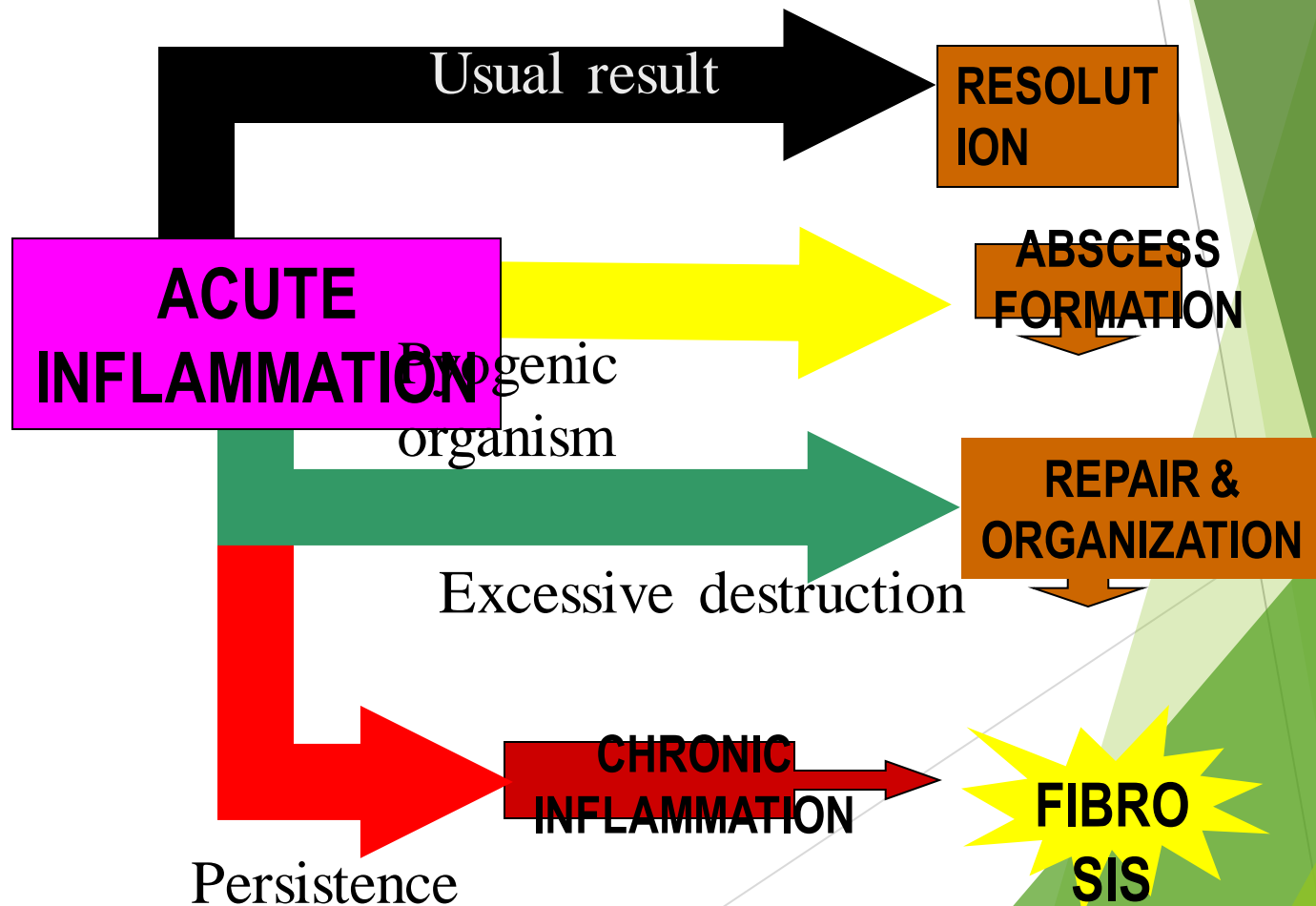
Outcomes of Acute Inflammation

- ▶ **Complete resolution (back to normal)**
 - ▶ Clearance of injurious stimuli
 - ▶ Removal of the exudate, fibrin & debris
 - ▶ Reversal of the changes in the microvasculature
 - ▶ Replacement of lost cells (regeneration)
- ▶ **Healing**
 - ▶ organization by fibrosis through formation of Granulation tissue. Why?
 - ▶ Substantial tissue destruction or
 - ▶ Tissue cannot regenerate or
 - ▶ Extensive fibrinous exudates
- ▶ **Abscess formation**
- ▶ **Progression to chronic inflammation**

Outcomes of Acute Inflammation



Outcomes of Acute Inflammation



Effects of Acute Inflammation

BENEFICIAL:

- ▶ Elimination of injurious stimulus
- ▶ Dilution of toxins
- ▶ Entry of antibodies
- ▶ Drug transport
- ▶ Fibrin formation
- ▶ Delivery of nutrients & oxygen
- ▶ Stimulation of the immune response

HARMFUL:

- ▶ Digestion of normal tissues
- ▶ Swelling
- ▶ Inappropriate inflammatory response

The end

Questions