

وسهلا



أهلا

يُمنع أخذ السلايدات بدون
إذن المحرر واي اجراء
يخالف ذلك يقع تحت طائلة
المسؤولية القانونية
جميع المعلومات للاستخدام
التعليمي فقط

الأستاذ الدكتور يوسف حسين

رئيس قسم التشريح والأنسجة والأجنة

كلية الطب - جامعة مؤتة - الأردن

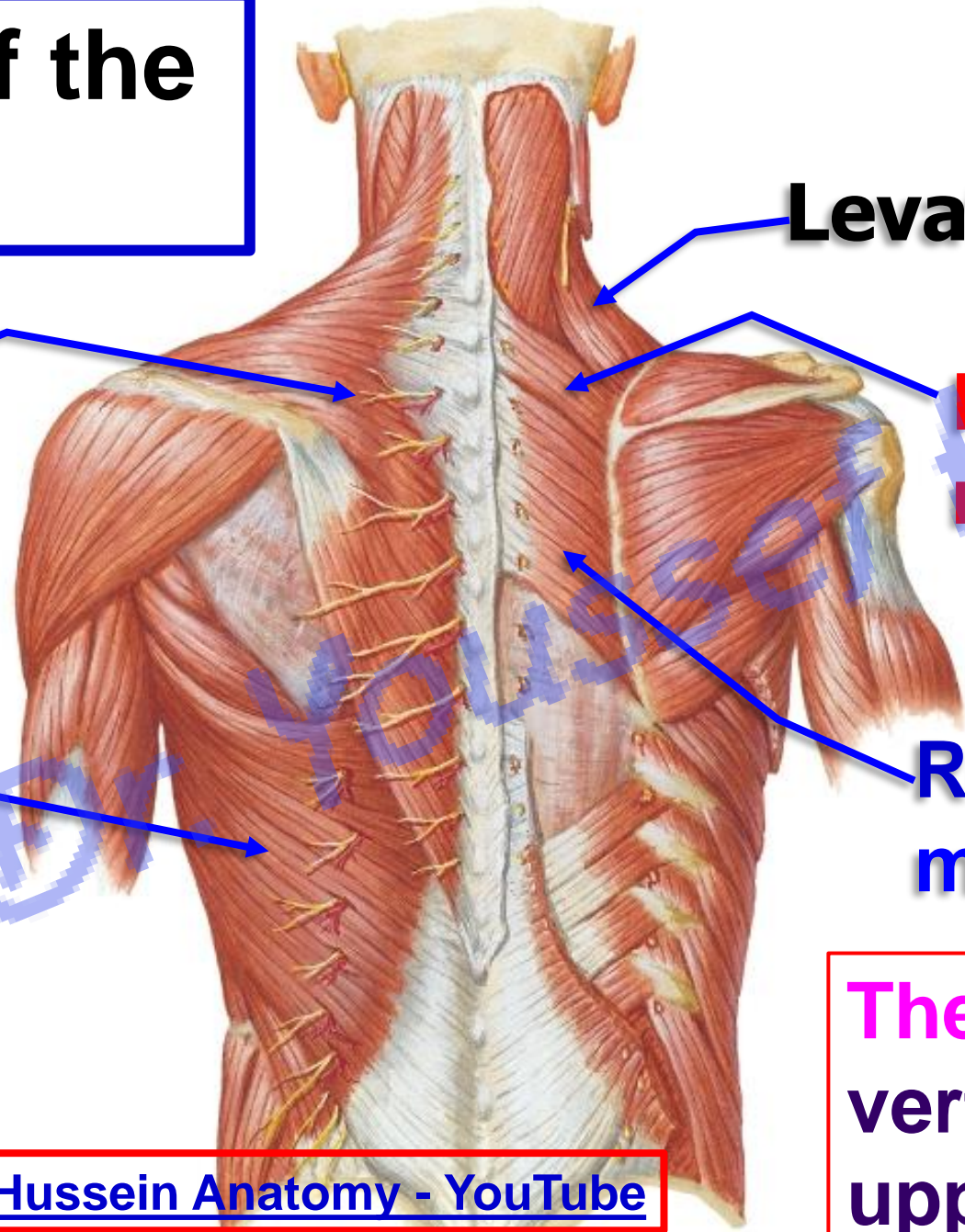
دكتورة من جامعة كولونيا المانيا

Prof. Dr. Youssef Hussein Anatomy - YouTube

الواتس 00201224904207

Muscles of the back

Muscles of the back



Levator scapula

Trapezius

Rhomboideus minor

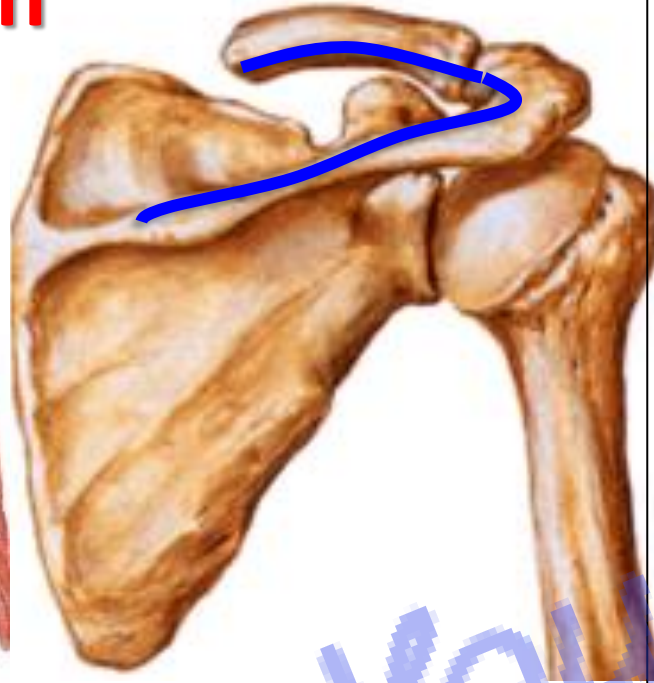
Latissimus dorsi

Rhomboideus major

The muscles connect vertebral column with upper limb

Trapezius

Origin



Insertion

• Trapezius شبه منحرفة

** Origin:

- 1- **Back of the skull**; external occipital protuberance and medial 1/3 of superior nuchal line.
- 2- **Back of the neck**; ligamentum nuchae and spine of the 7th cervical.
- 3- **Back of the thorax**; all thoracic spines.

** Insertion:

- 1- **Upper fibers** into posterior border of the lateral third of the clavicle.
- 2- **Middle fibers** into medial border of the acromion of the scapula.
- 3- **Lower fibers** into upper lip of the spine of the scapula.

**** Nerve supply (double)**

1- Motor; spinal part of accessory nerve.

2- Sensory (Proprioceptive sensation) from the cervical plexus.

**** Actions:**

1. Upper fibers elevate the scapula.

2. Middle fibers retract the scapula.

3. Lower fibers Depress the scapula.

4. Middle and lower fibers Abduction of the arm

more than 90 degree (with lower 5 digitations of the serratus anterior).

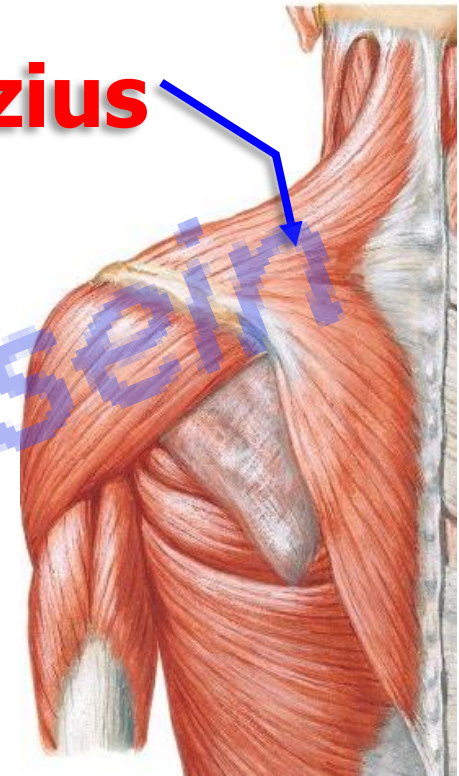
N.B; It is the **only muscle of upper limb**

a- Arises from the skull.

b- Not supplied by the brachial plexus.

- **Wasting of the muscles leading to loss the normal lateral slope of the neck with drop shoulder on affected side**

Trapezius



[Prof. Dr. Youssef Hussein Anatomy - YouTube](#)

Latissimus dorsi

• Latissimus Dorsi

** Origin:

1- From lower 6 thoracic spines under cover of the trapezius.

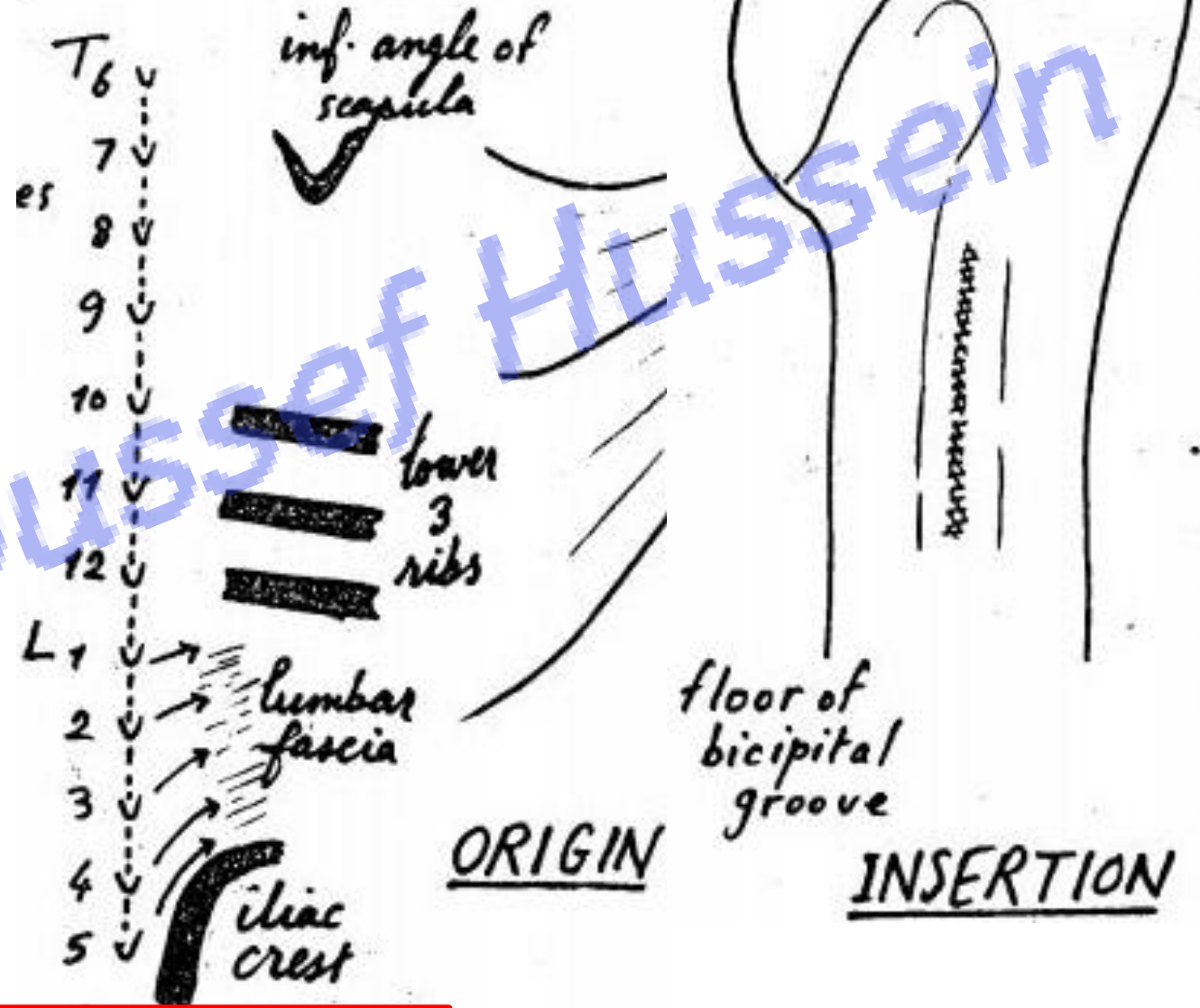
2- Lumbar fascia.

3- Posterior part of the outer lip of the iliac crest.

4- The lower 3 ribs.

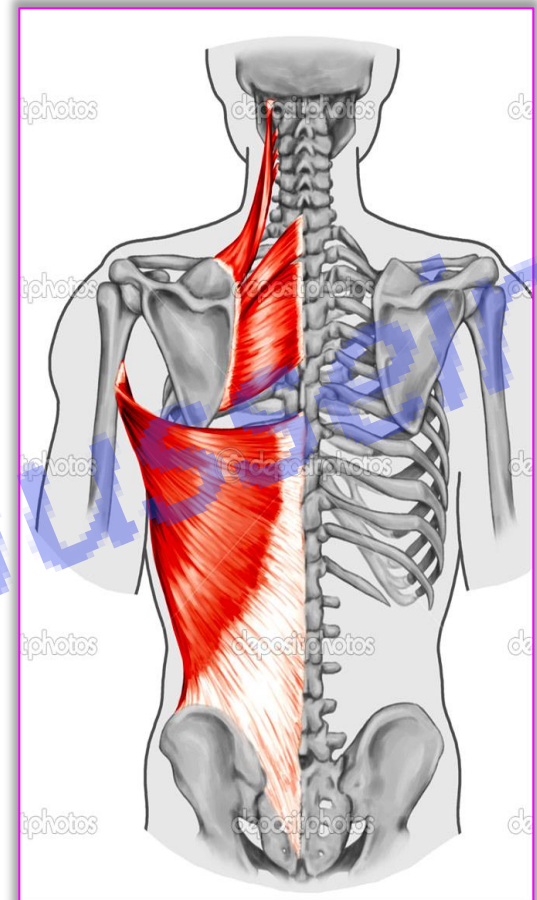
5- The back of the inferior angle of the scapula.

** **Insertion:** into the floor of the bicipital groove of the humerus.



- **Latissimus Dorsi**

- ❖ **Nerve supply:** nerve to latissimus dorsi (thoracodorsal nerve) from posterior cord of brachial plexus.
- ❖ **Actions:**
- ❖ Adduction, extension and medial rotation of the arm (as teres major) **Used in Swimming**
- ❖ It pulls the trunk towards the arm used in **climbing and Gymnastics** with pectoralis major.
- ❖ It assists in deep expiration (**cough**).



- ❖ The only muscles of upper limb has pelvic attachment
- ❖ Accessory muscle of expiration
- ❖ It has triple relations to teres major (it lies behind, below and finally in front)

[Prof. Dr. Youssef Hussein Anatomy - YouTube](#)



Deep muscles of the back

- **Levator Scapulae**

**** Origin:** transverse processes of **C1-C4**

**** Insertion,** dorsal surface of medial border of scapula from superior angle to the root of spine.

**** Nerve supply (double):**

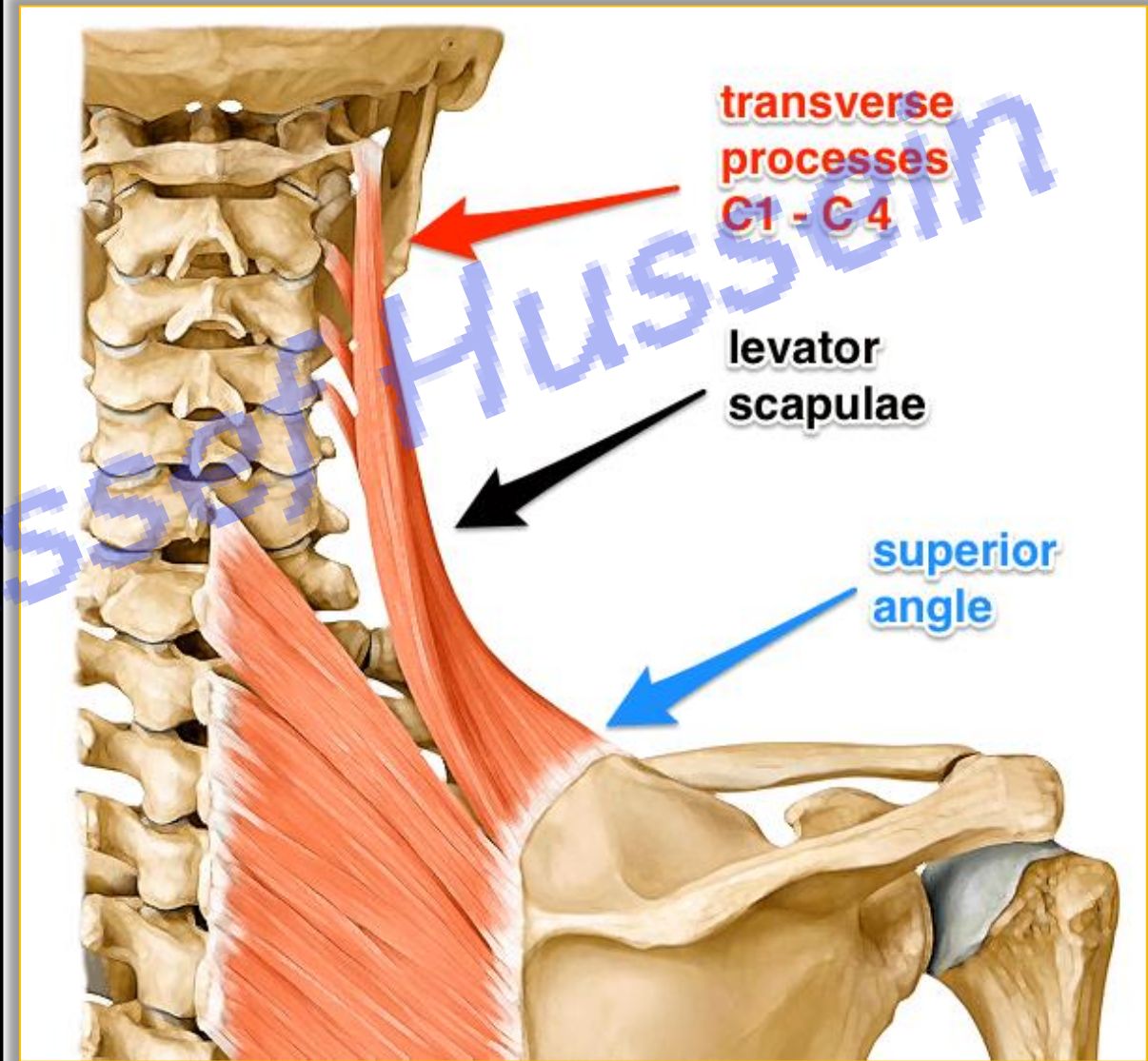
a- Dorsal scapular nerve (nerve to rhomboideus C5).

b- Nerve to levator scapulae from cervical plexus (C3&4)

**** Actions:**

1- Elevates the scapula.

2- Tilts the neck to the same side when shoulder is fixed.



- **Rhomboideus Minor**

** **Origin:** From the lower part of the ligamentum nuchae, spines of **C7 - T1**.

** **Insertion:** dorsal aspect of medial border of scapula opposite root of spine.

- **Rhomboideus Major**

** **Origin:** thoracic spines of **T 2, 3, 4, 5**.

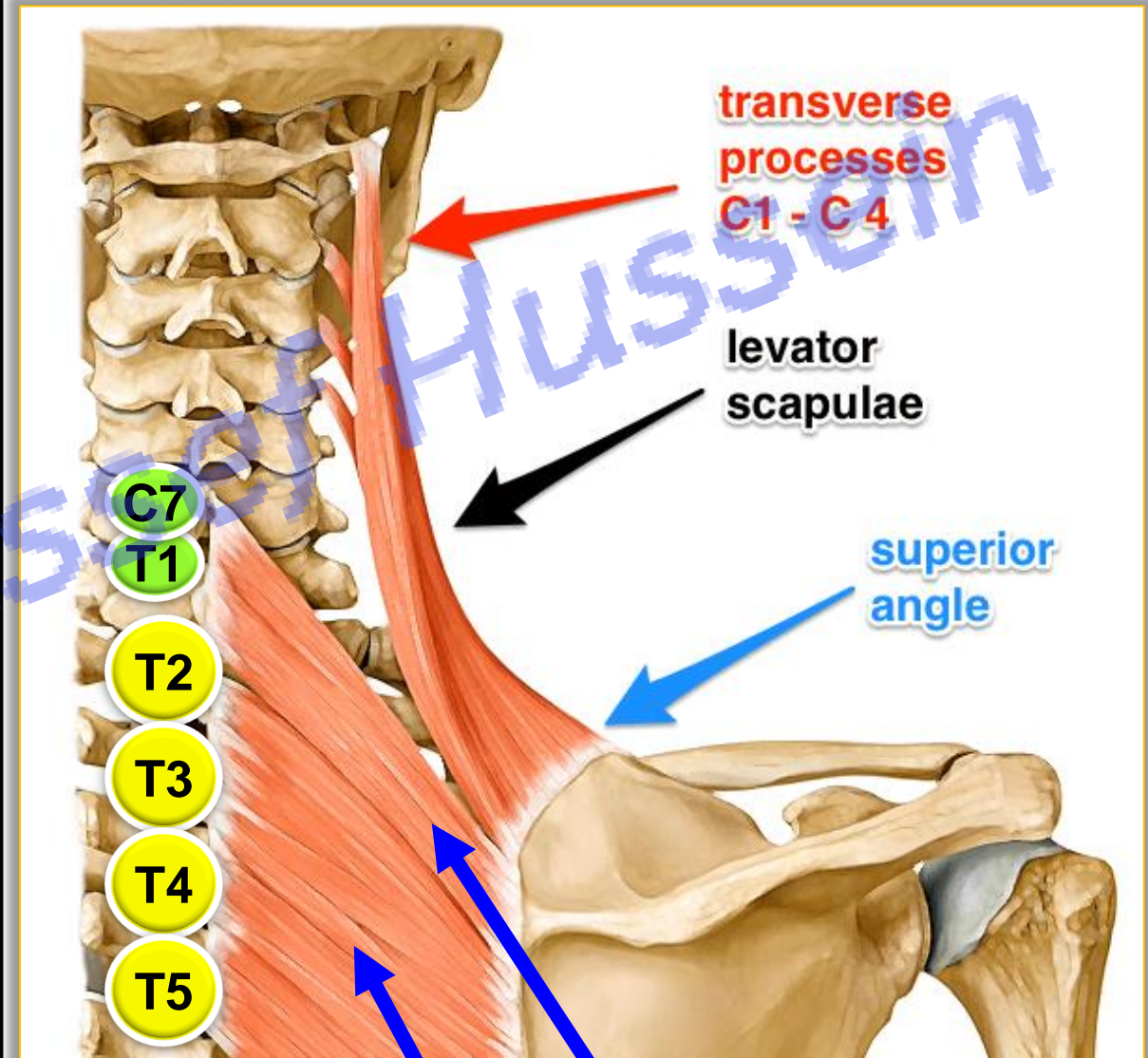
** **Insertion;** dorsal aspect of medial border of scapula from spine to inferior angle.

- **Nerve supply**

- **Dorsal scapular nerve** (nerve to rhomboideus C5).

- **Action of Rhomboideus Minor and major**

- Retraction of the scapula.



Rh. Major

Rh. Minor

- **Movements of the scapula**

- Movements of the clavicle occur at the sternoclavicular and acromioclavicular joints

The scapular movements include:

1- Elevation: by upper fibers of trapezius and levator scapulae.

2- Depression: by lower fibers of trapezius, pectoralis minor, and gravity.

3- Protraction: (forward movement) by pectoralis minor and serratus anterior.

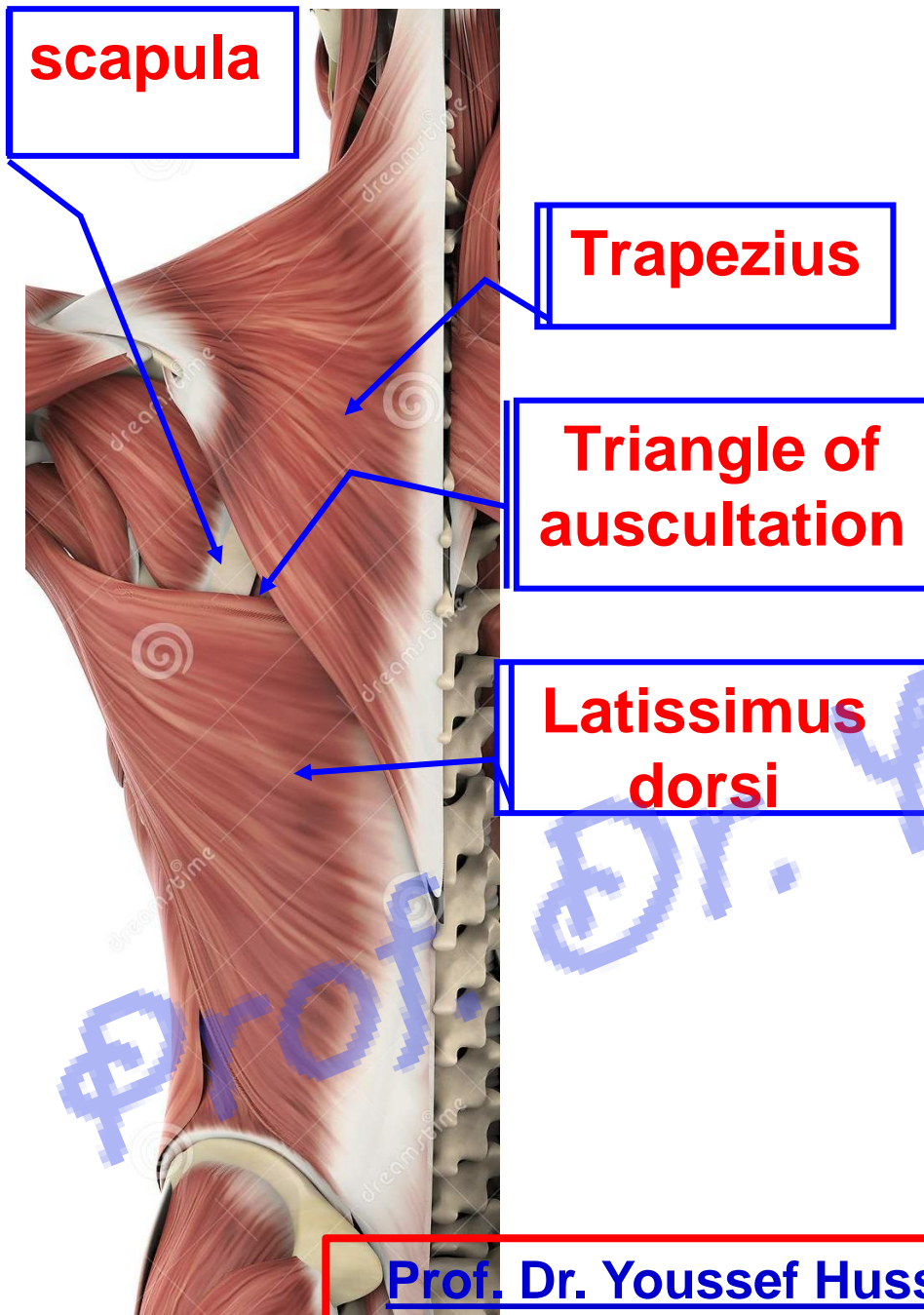
4- Retraction: by middle fibers of trapezius and rhomboideus minor and major muscles.

5- Lateral rotation: The glenoid cavity faces upward and lateral (during **abduction** of the shoulder **more than 90 degree**) by the middle and lower fibers of the trapezius and lower 5 digitations of the serratus anterior.

6- Medial rotation: the scapula **returns** from upward rotation to the rest position, mainly by gravity. If muscle action is needed, this movement is produced by the levator scapula, and rhomboideus muscles.

N.B: subclavius muscle plays an important role in **fixation** of the clavicle during movements of the shoulder girdle.

Intermuscular spaces of back



• Triangle of Auscultation

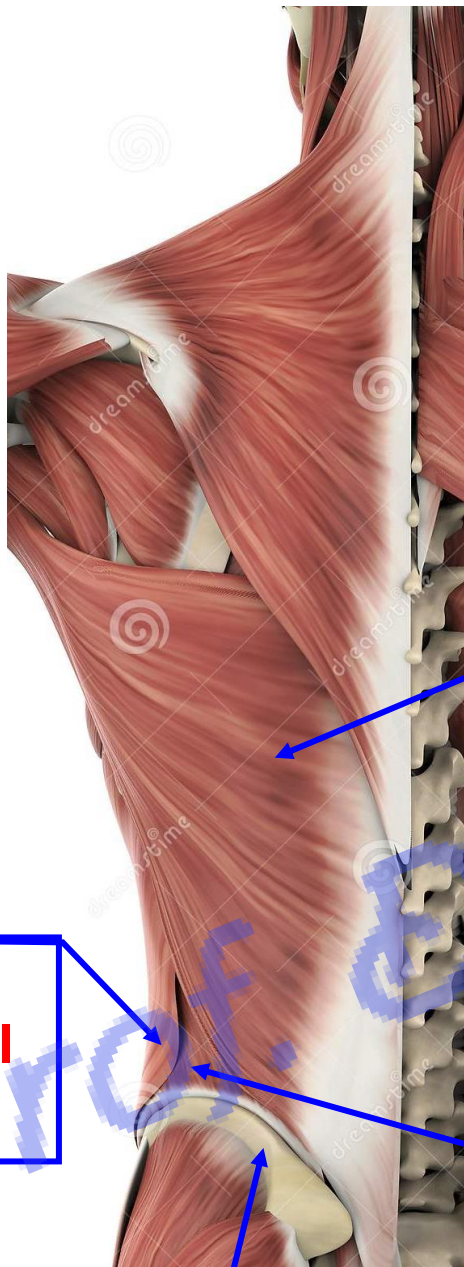
** Borders;

- **Medially**; lateral border of the **trapezius**.
- **Laterally**; Medial border of the **scapula**.
- **Inferiorly**; Upper border of **latissimus dorsi**.

** Its **floor**: rhomboideus major.

** **Clinical importance:**

- It facilitates auscultation of the **breath sound and heart sound**.
- In the left side, it is related to cardiac end of the stomach. **So** in case of **esophageal atresia**, can auscultate splash of fluid.



Latissimus dorsi

External abdominal oblique

Lumbar triangle

Iliac crest

• Lumbar Triangle

**** Borders:**

- **Medial**; latissimus dorsi.
- **Lateral**; external abdominal oblique muscle.
- **Base**, iliac crest.

**** The floor**, internal abdominal oblique muscle.

**** Clinical importance**; A lumbar hernia (**Pettit's hernia**)

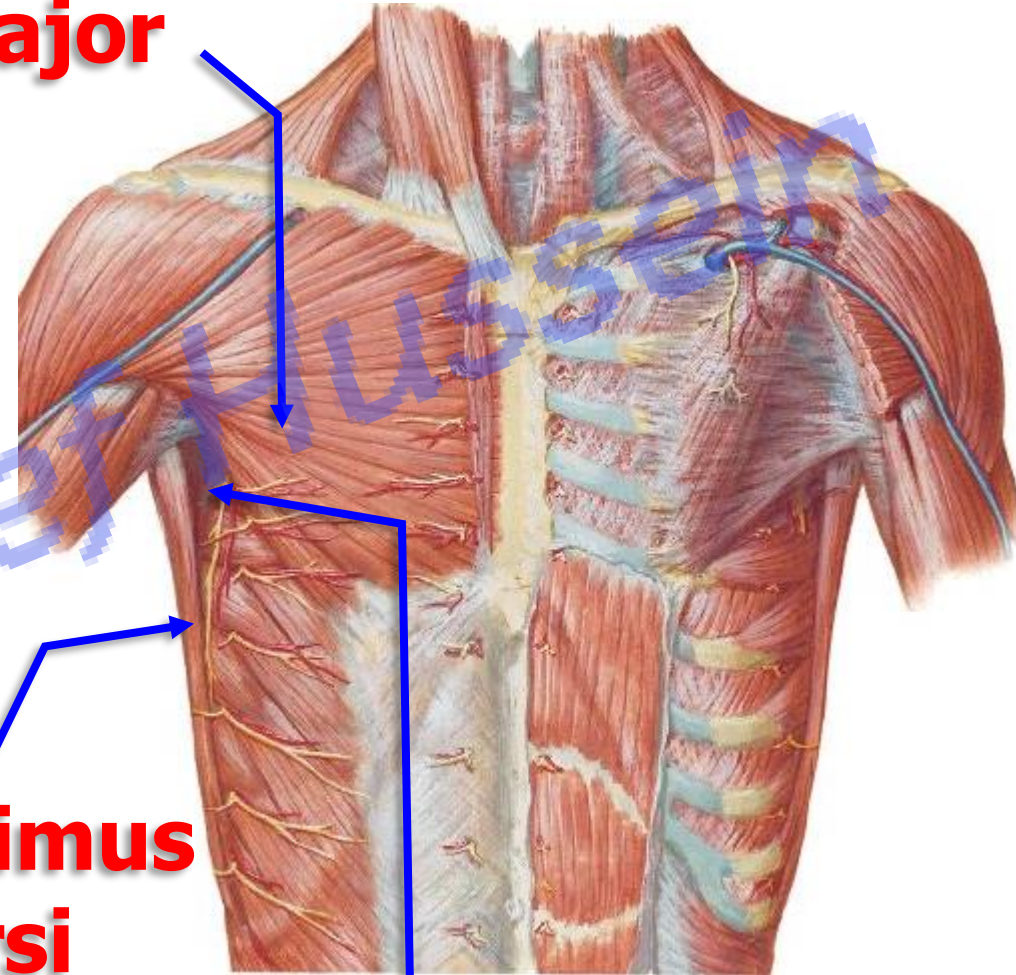
❖ Triangle of safety

- **Boundaries**
 - **Medially:** lateral border of Pectoralis major
 - **Laterally:** Anterior border of latissimus dorsi
 - **Base:** horizontal line passes through 5th intercostal space (nipple in the 4th intercostal space)
 - **Apex:** below axilla
- **Importance:** site of chest tube to the pleural cavity (thoracostomy) in the 4th, or 5th intercostal space anterior to the midaxillary line just above the rib

Pectoralis major

Latissimus dorsi


Triangle of safety



https://www.youtube.com/channel/UCVSNqbibj9UWYaJdd_cn0PQ

يُمنع أخذ السلايدات بدون
إذن المحرر و اي اجراء
يخالف ذلك يقع تحت طائلة
المسؤولية القانونية
جميع المعلومات للاستخدام
التعليمي فقط

اليوتيوب د. يوسف حسين



Thank You
Questions

<https://www.youtube.com/@ProfDrYoussefHusseinAnatomy/playlists>