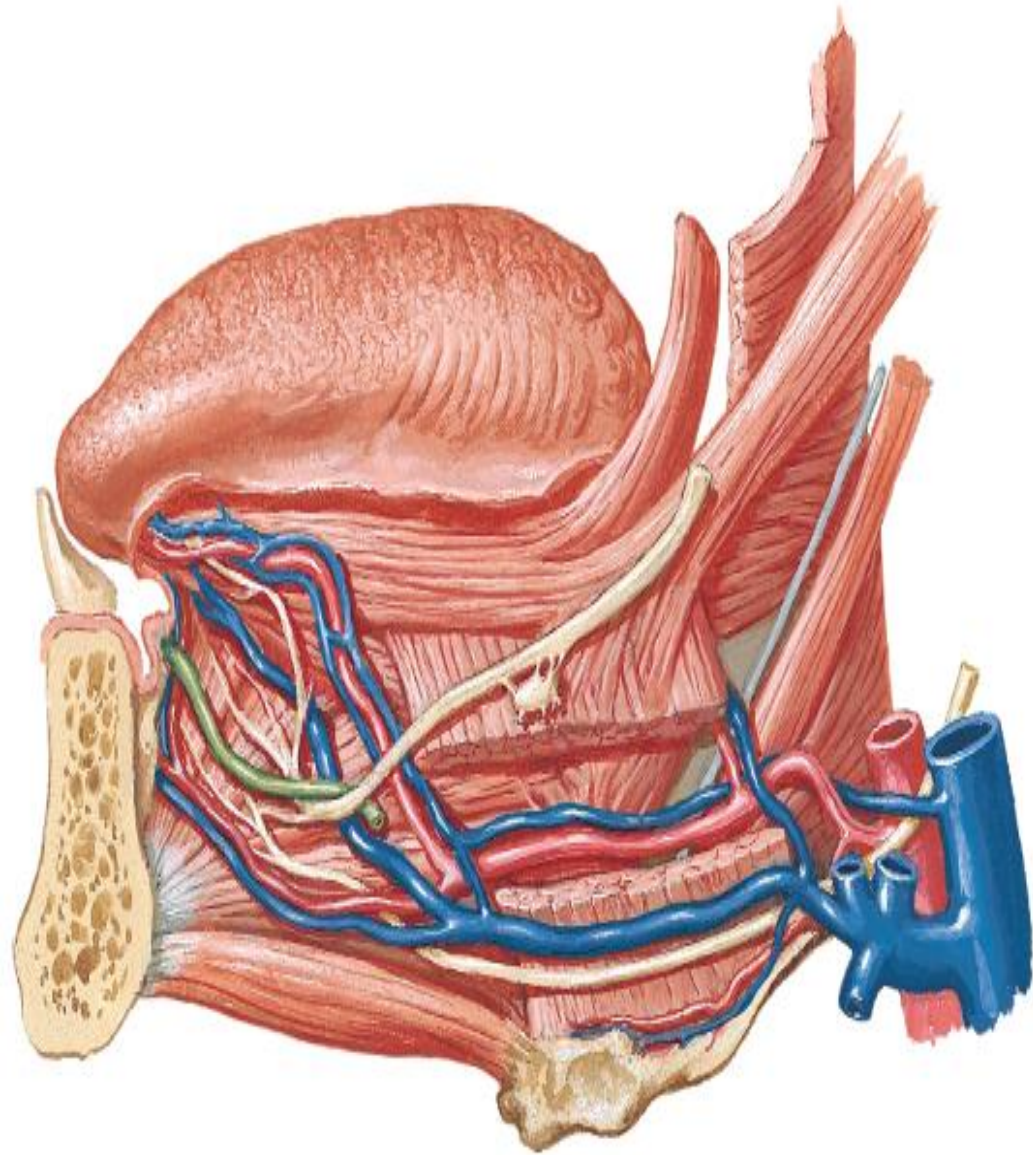


TONGUE



BY
DR ABULMAATY MOHAMED
ASSISTANT PROFESSOR
ANATOMY & EMBRYOLOGY
MUTAH UNIVERSITY

TONGUE

Definition:

a mass of skeletal muscles covered by mucous membrane.

Parts: -

Oral part: ant. 2/3 lies in the floor of oral cavity

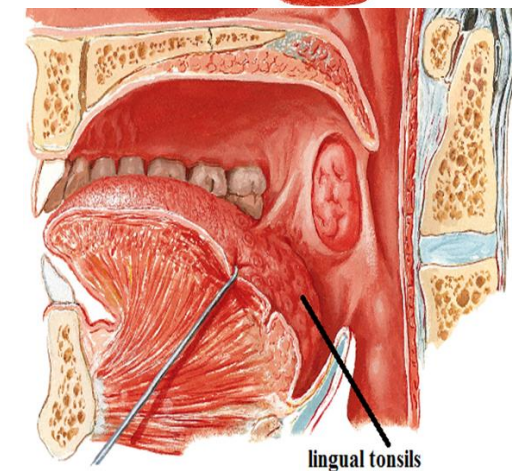
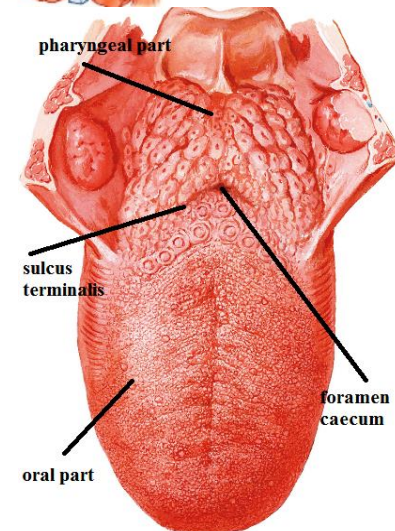
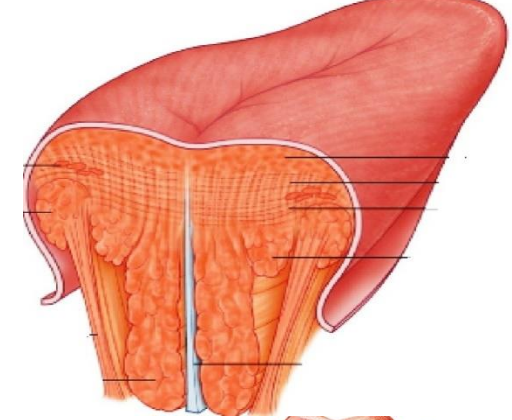
Pharyngeal part: post. 1/3 lies in ant. wall of oropharynx.

Sulcus terminalis :

-It is v- shaped sulcus that marks the junction between the oral part and pharyngeal part of tongue.

-lies on sup. Surface

-its apex directed backwards showing a depression called Foramen caecum



TONGUE

Parts

Oral part of tongue

Shape:-triangular in shape with apex (tip of tongue):- lies just behind the incisors.

2 margins:- lie opposite the teeth

2 surfaces:- superior & inferior

Features of the Sup. Surface:

shows 3 types of papillae:

1-Vallate papillae:

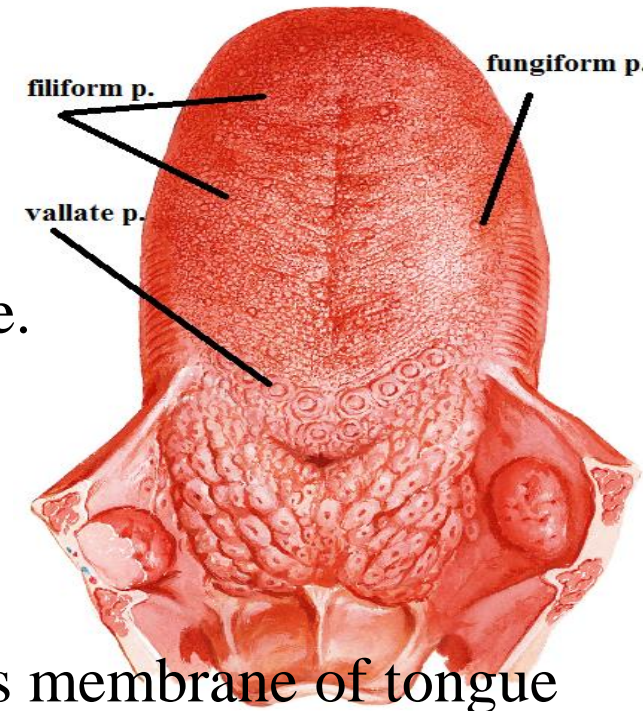
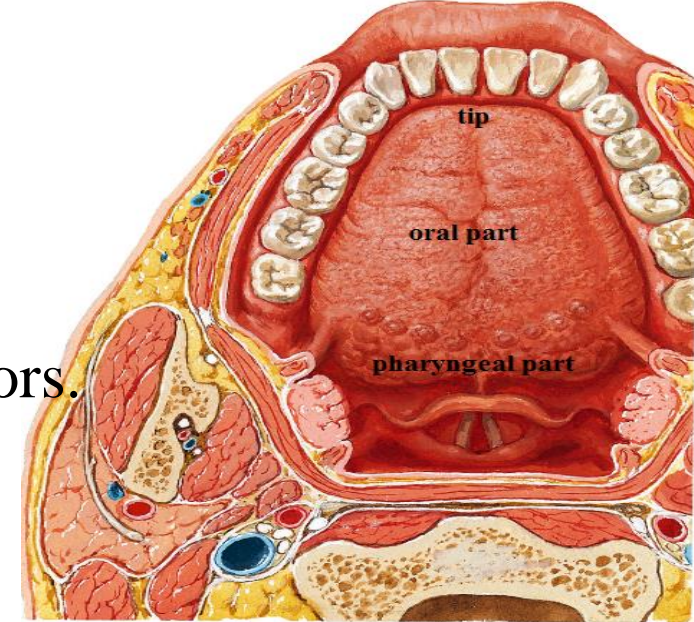
- row of papilla in front of sulcus terminalis
- it is large enough to be easily seen by naked eye.

2-Fungiform papillae:- on tips and sides

3-Filiform papillae. small

arranged into rows parallel to vallate papillae

-The papillae increase the surface area of mucous membrane of tongue and contains taste buds .



TONGUE

Parts

Oral part of tongue

Features of the inferior surface

-Has no papilla, but it shows 3 features.

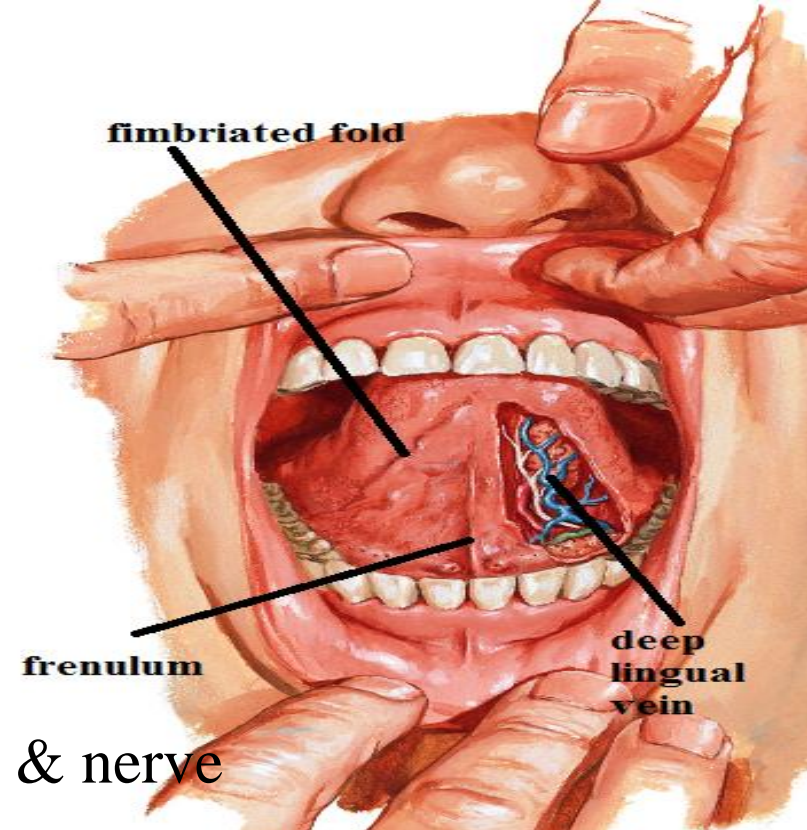
-Lingual frenulum:

-Deep lingual vein:

appears as a dark line lateral to frenulum.

this vein is accompanied by lingual artery & nerve

-Fimbriated fold: lateral to the vein.

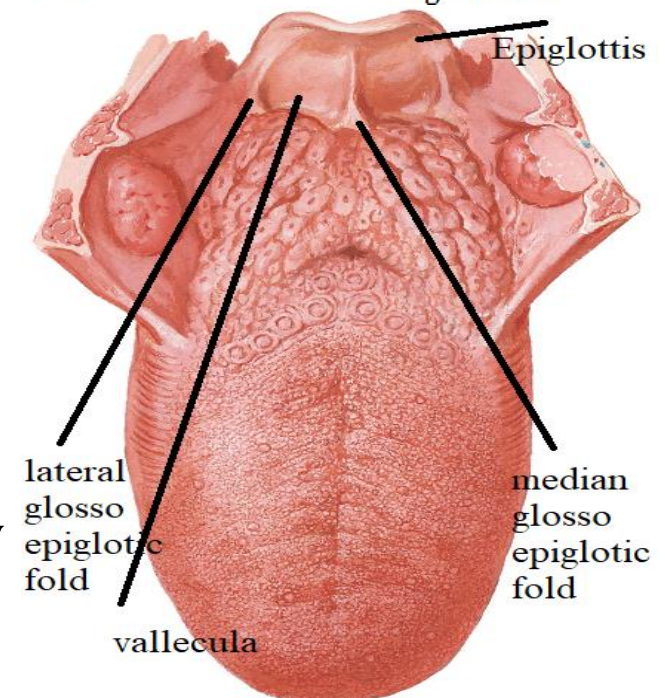
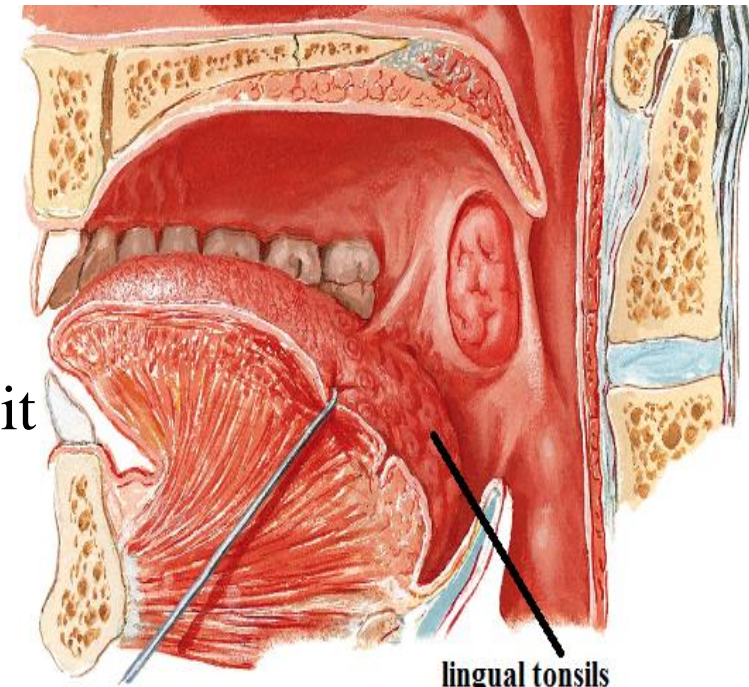


TONGUE

Parts

Pharyngeal part of the tongue-

- It has only a pharyngeal surface which is continuous with sup. surface of oral part but it is nearly vertical
- Has no papilla .
- It is irregular due to presence of nodules of lymphoid tissue in the submucosa (lingual tonsils).
- its pharyngeal surface is connected with the epiglottis by one median & two lateral glossoepiglottic folds
- vallecula :- depressions on both sides of the median glossoepiglottic folds bounded laterally by lateral glossoepiglottic folds



TONGUE

Muscles : intrinsic and extrinsic

Intrinsic muscles:-

- arise and end within the substance of tongue with no bony attachments outside the tongue

- These are 4 groups :

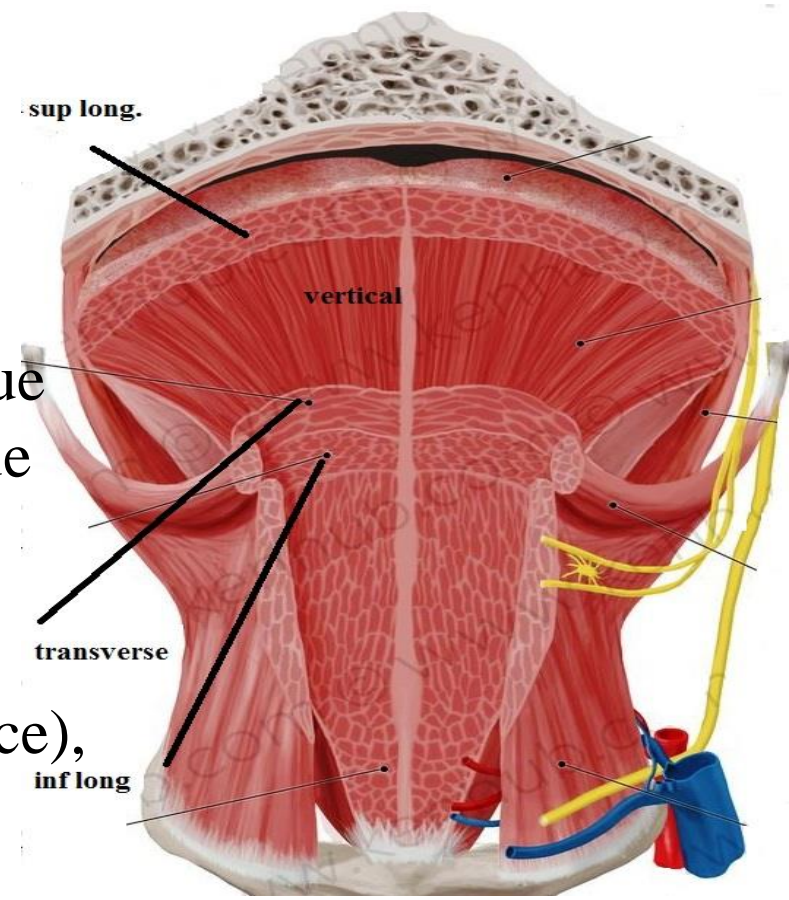
- 1-Superior longitudinal m. (on the dorsum)

- 2-inferior longitudinal m. (on inferior surface),

- 3-vertical m. () 1 & 2

- 4-transverse m.

- They change the shape of tongue in chewing, speech.



TONGUE

Muscles :

Extrinsic muscles:

arise outside the tongue and inserted into the tongue, these are

Genioglossus

O. :- Superior genial tubercle

I. :- whole length of lower surface of tongue -reach hyoid bone

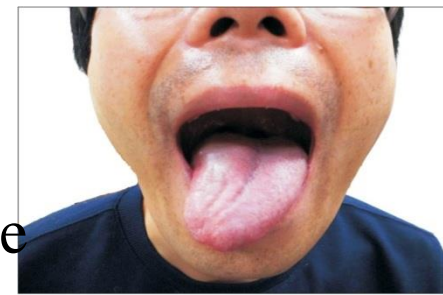
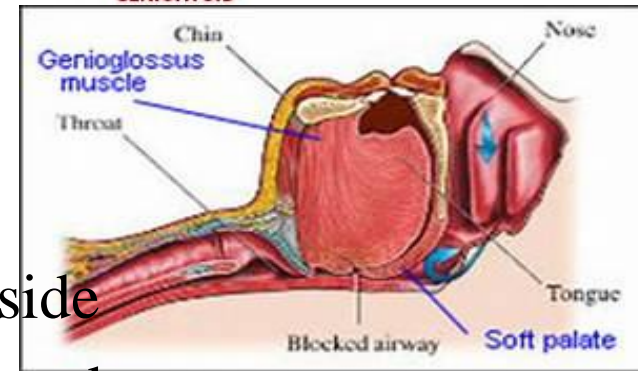
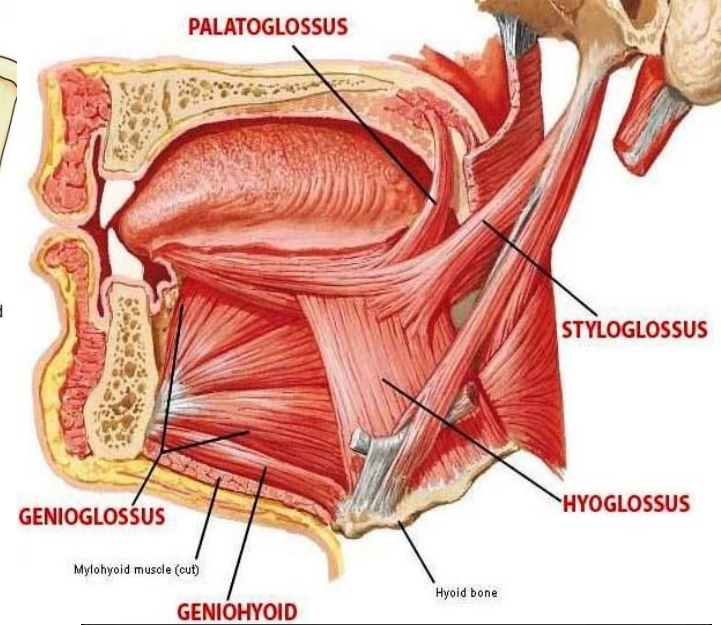
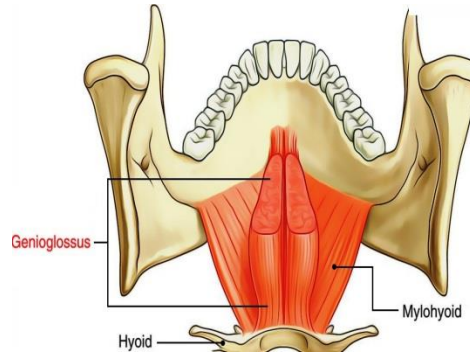
A. :- **one muscle** Protrudes tongue to opposite side
two muscle Protrudes tongue directly forward

by its tone prevent backward displacement of tongue during sleep

Styloglossus

O. :- - Styloid process

I. :- Side of tongue **A.** :- Retracts and elevates tongue



TONGUE

Muscles :

Extrinsic muscles:

Hyoglossus

O. :- body & greater horn of hyoid bone

I. :- Post. 1/2 of side of tongue

A. :- Depresses tongue
during speech , chewing , singing

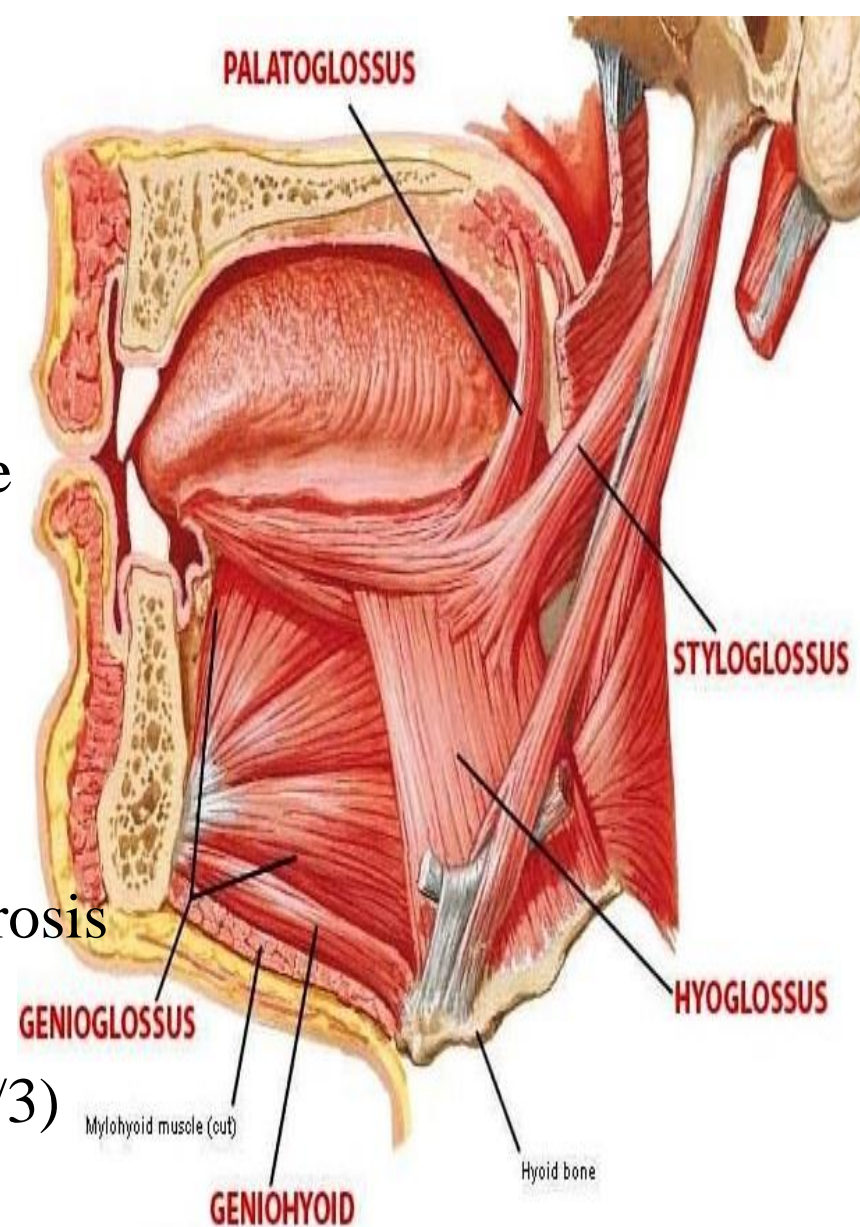
Palatoglossus

O. :- inferior surface of palatine aponeurosis

I. :- side of tongue

(at junction between ant 2/3 and post. 1/3)

A. :- Elevates tongue
depresses palate



TONGUE

Blood supply :

Arterial supply:- Mainly by lingual artery

Venous drainage: it is drained by 2 veins.

1 -Deep lingual vein:

2-Dorsal lingual vein:

Both veins end in IJV

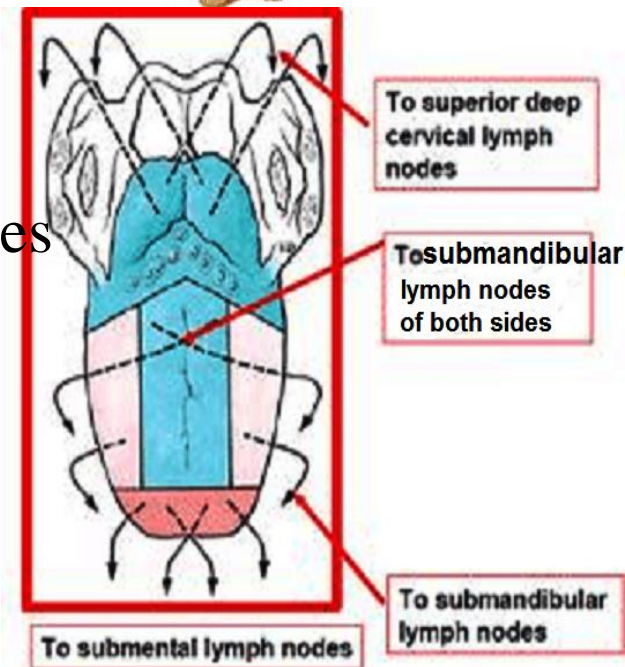
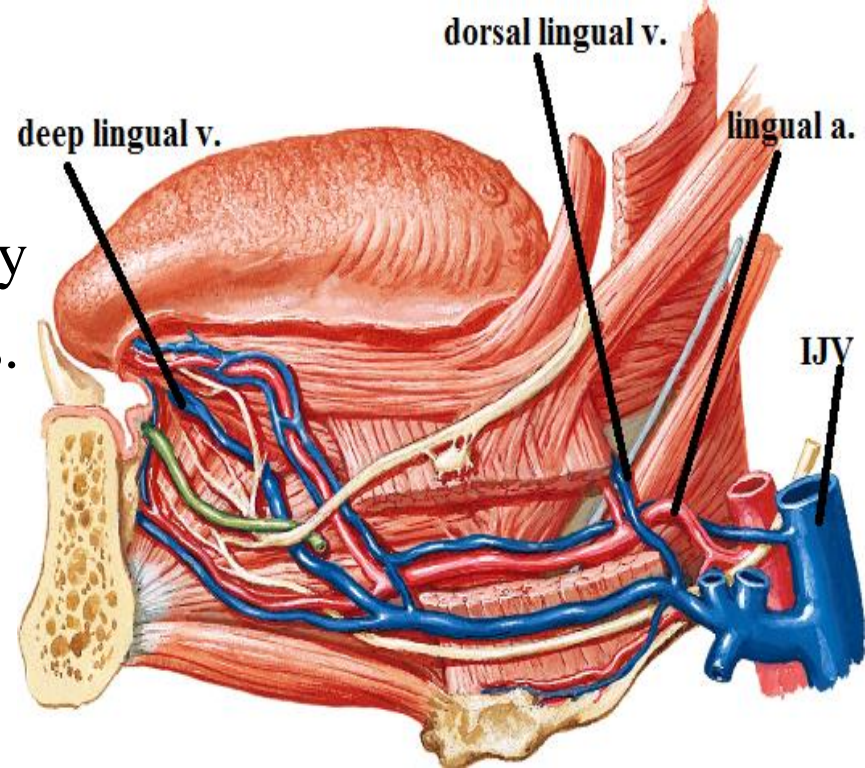
Lymphatics: it drains to

-**Tip:-** to Submental lymph nodes.

-**Sides :-** to Submandibular L.N. of the same side

-**Central part :-** to Submandibular L.N. of both sides

Posterior part:- to Deep cervical L.N.



TONGUE

Nerve supply :

Motor: all muscles (extrinsic and intrinsic) are supplied by hypoglossal nerve except palatoglossus which is supplied by cranial part of accessory n through vagus.

Sensory:

-Ant. 2/3:

General sensation:- lingual nerve

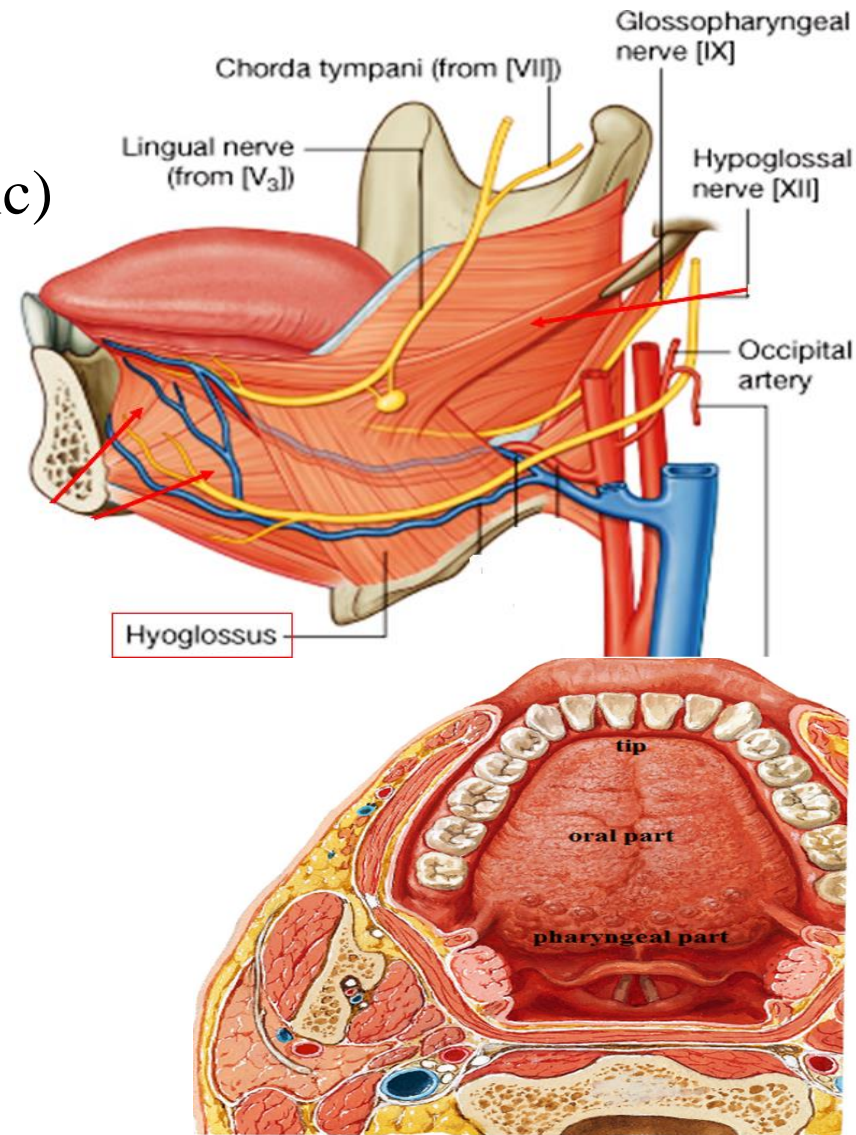
taste sensation:- chorda tympani n.

Post. 1/3: general & taste sensation

by glossopharyngeal nerve

-Most lower part of pharyngeal part: by vagus n

N.B.:- vallate papilla are supplied by glossopharyngeal nerve



THANQ