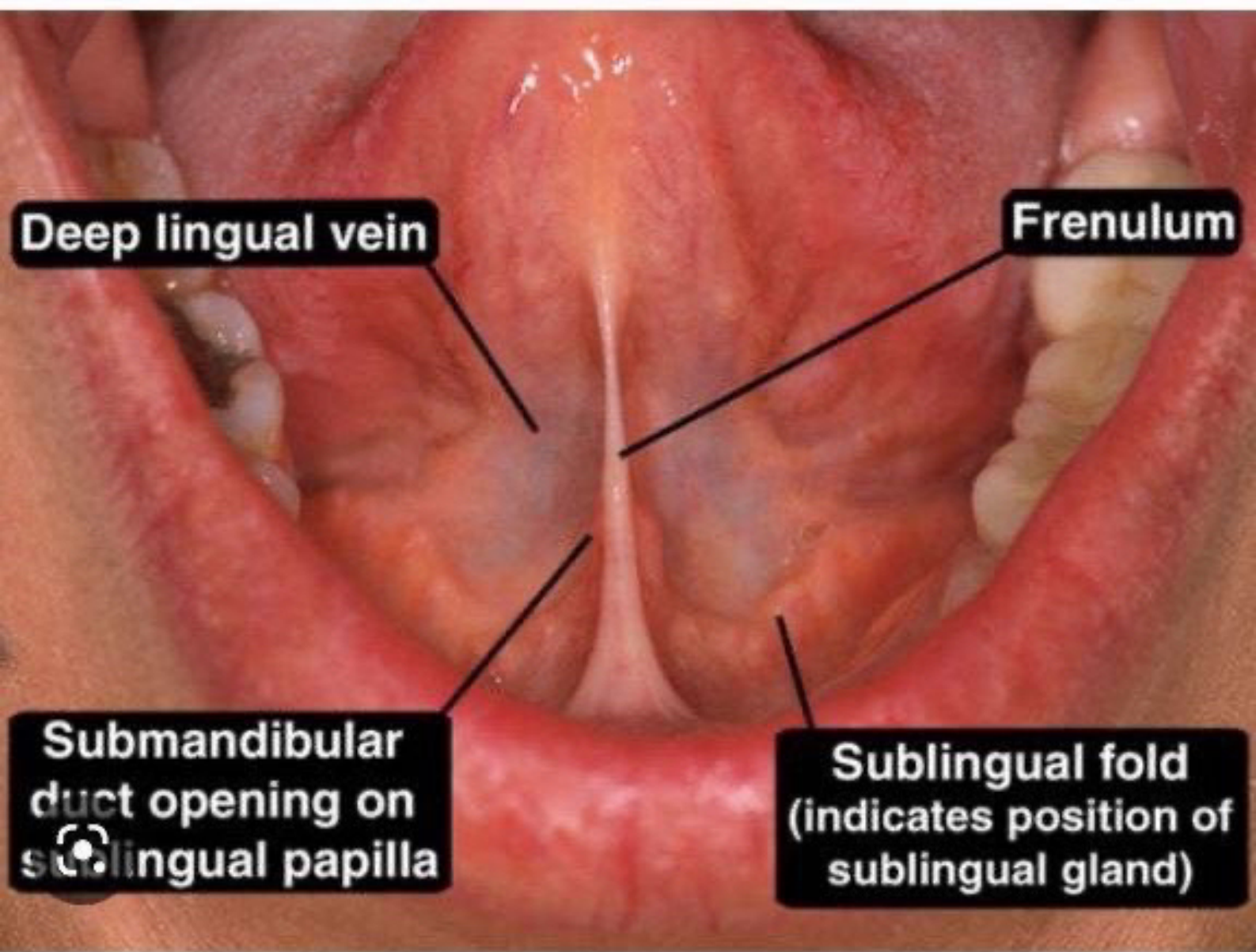

Deep lingual vein

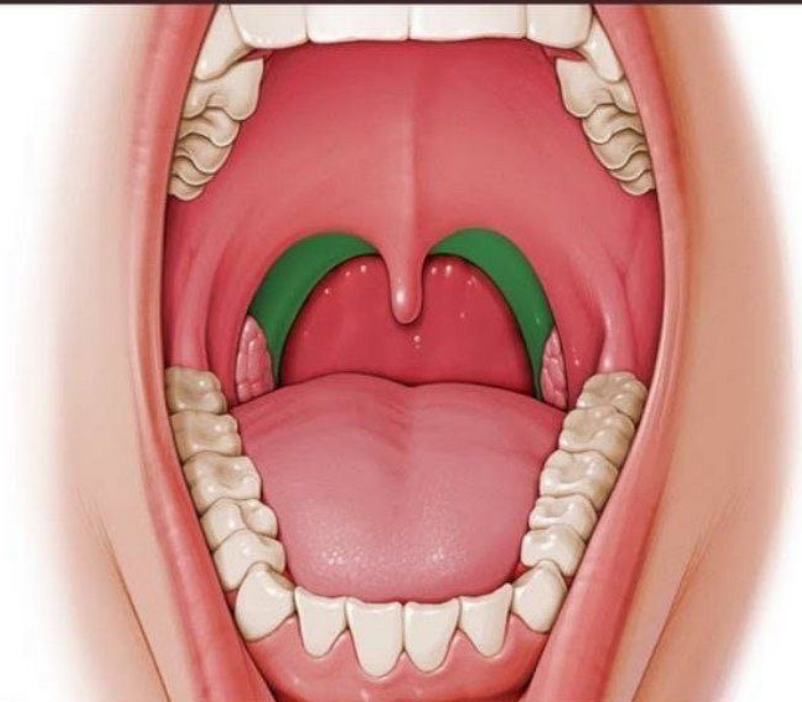
Frenulum

Submandibular duct opening on sublingual papilla

Sublingual fold (indicates position of sublingual gland)



Palatopharyngeal arch



K

inside image

The Tongue

NERVE SUPPLY

MOTOR

Palatoglossus

VAGUS
NERVE
CN 10

**All other
muscles**

HYPOGLOSSAL
NERVE
CN 12

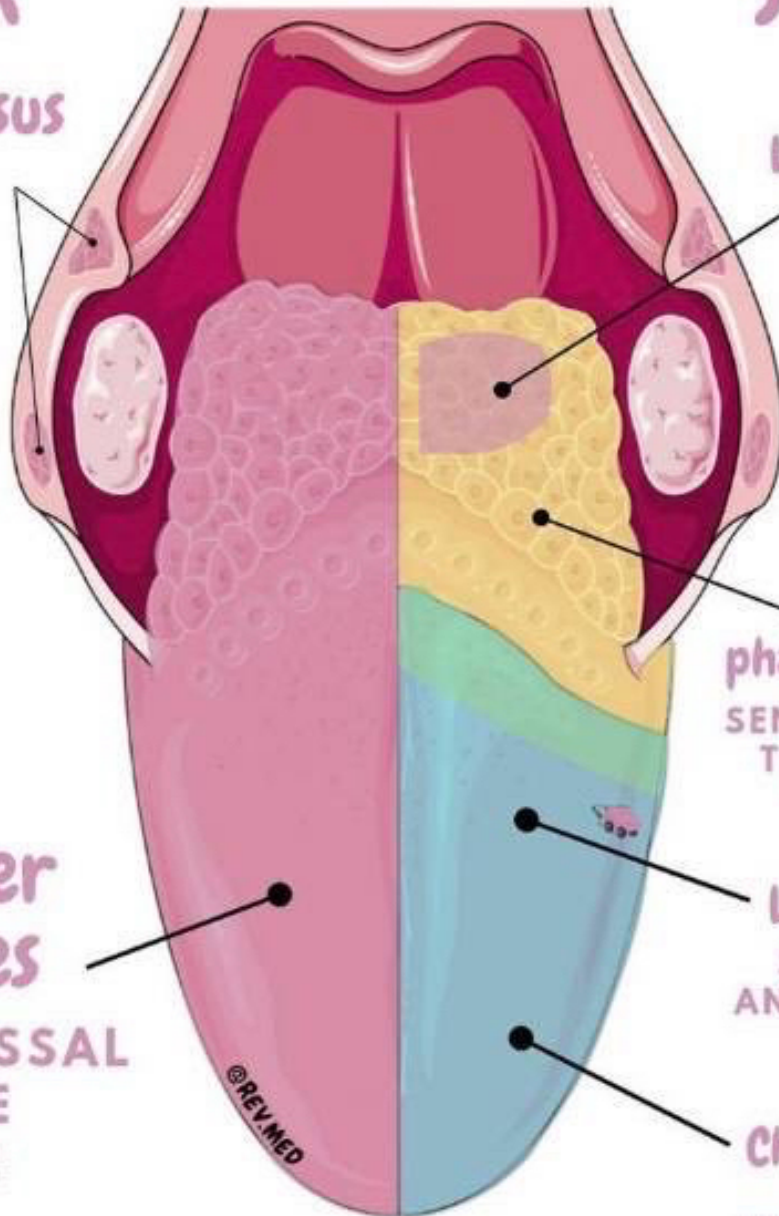
SENSORY

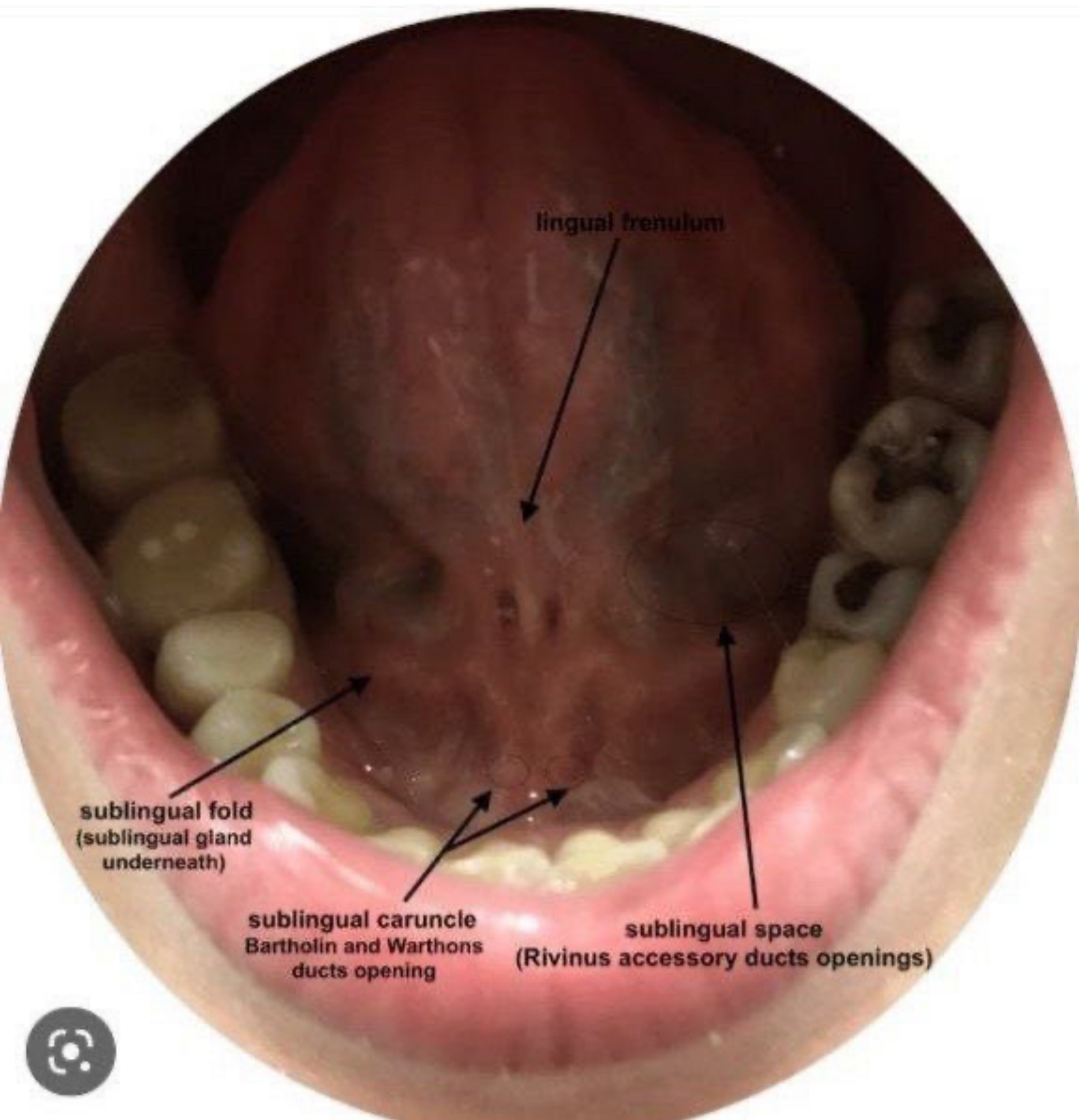
**Internal
Laryngeal nerve**
VAGUS NERVE
CN 10

**Glosso-
pharyngeal nerve**
SENSORY & TASTE
TO POSTERIOR
1/3RD CN 9

Lingual nerve
SENSORY TO
ANTERIOR 2/3RD
CN 5

Chorda Tympani
TASTE TO
ANTERIOR 2/3RD
CN 7





lingual frenulum

sublingual fold
(sublingual gland
underneath)

sublingual caruncle
Bartholin and Warthons
ducts opening

sublingual space
(Rivinus accessory ducts openings)



Oral vestibule

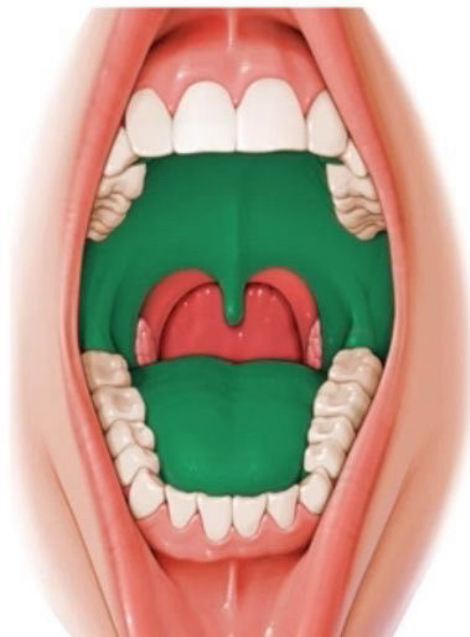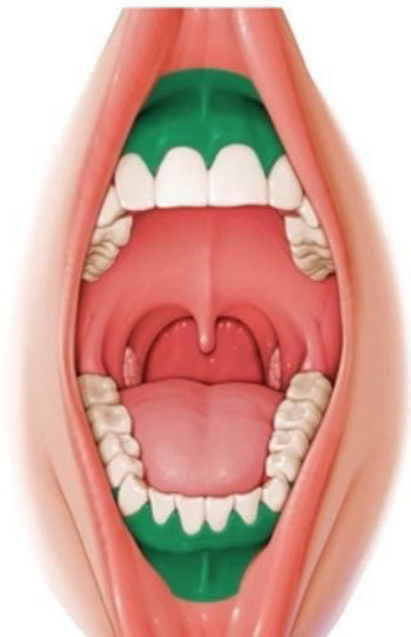
LATIN

Vestibulum oris

Oral cavity proper

LATIN

Cavitas oris propria



Division marked by
the gums and teeth