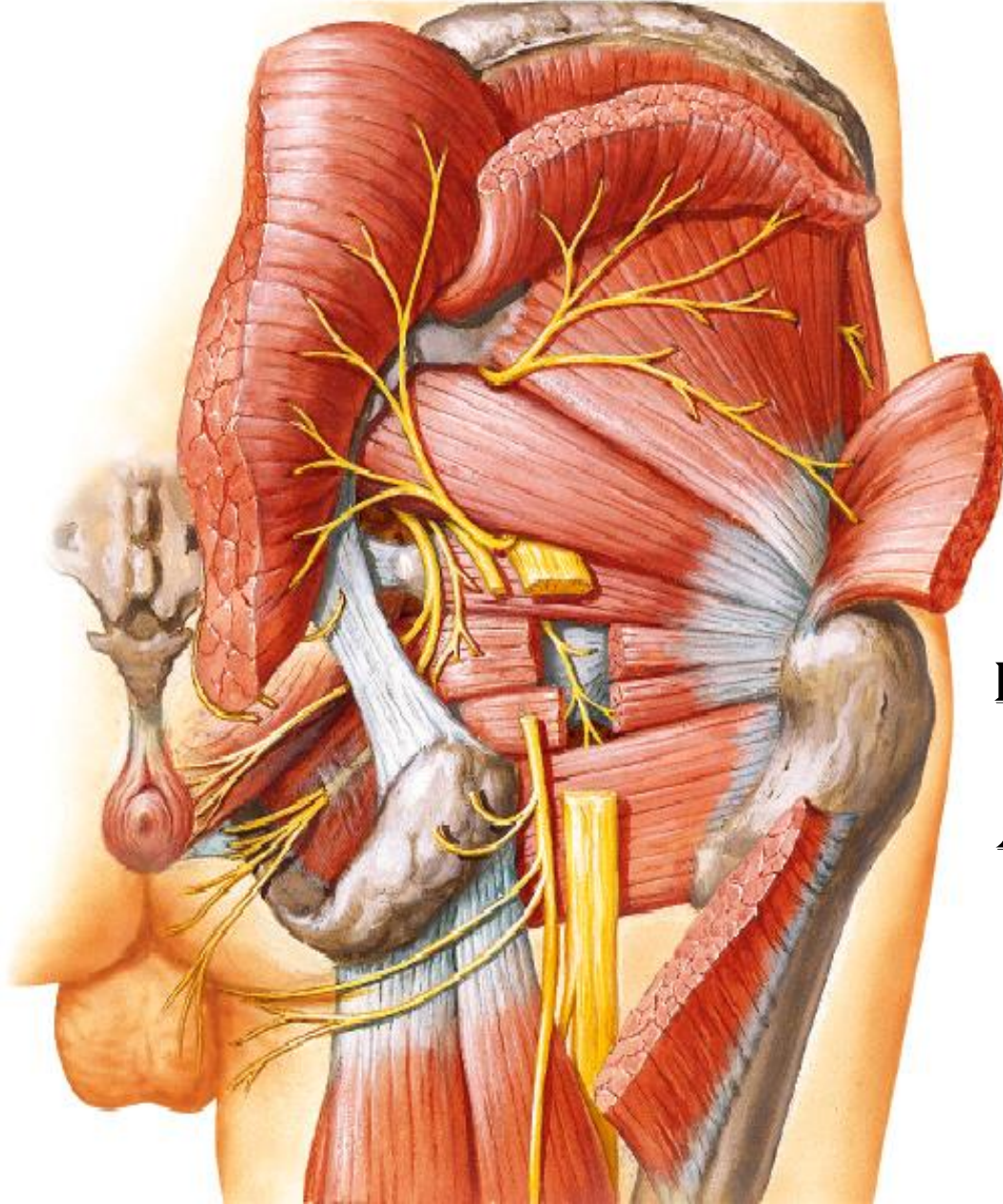


# GLUTEAL REGION



BY  
DR ABULMAATY MOHAMED  
ASSISTANT PROFESSOR  
ANATOMY & EMBRYOLOGY  
MUTAH UNIVERSITY

# LIGAMENTS

## **sacrospinous lig. :**

**From** tip of ischial spine.

**To** margin of last sacral &  
1st coccygeal vertebrae

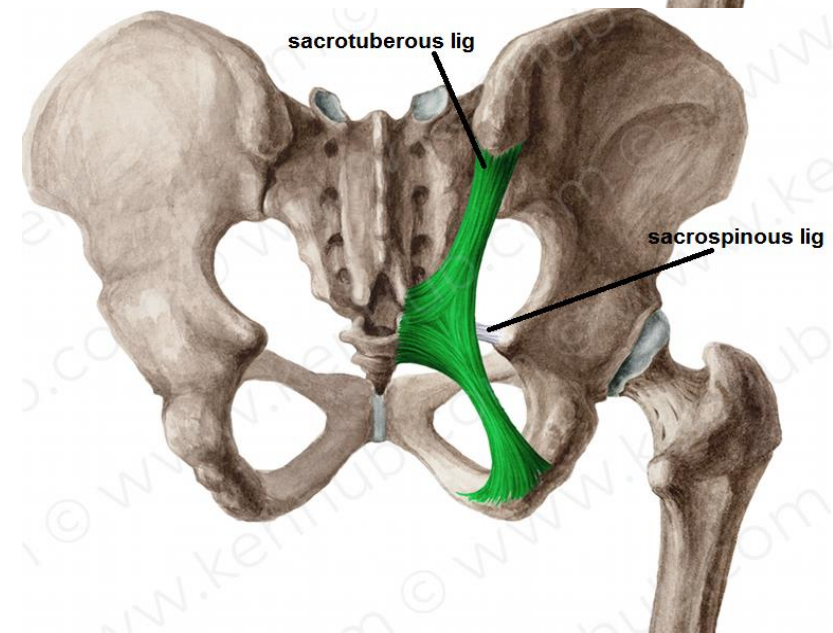
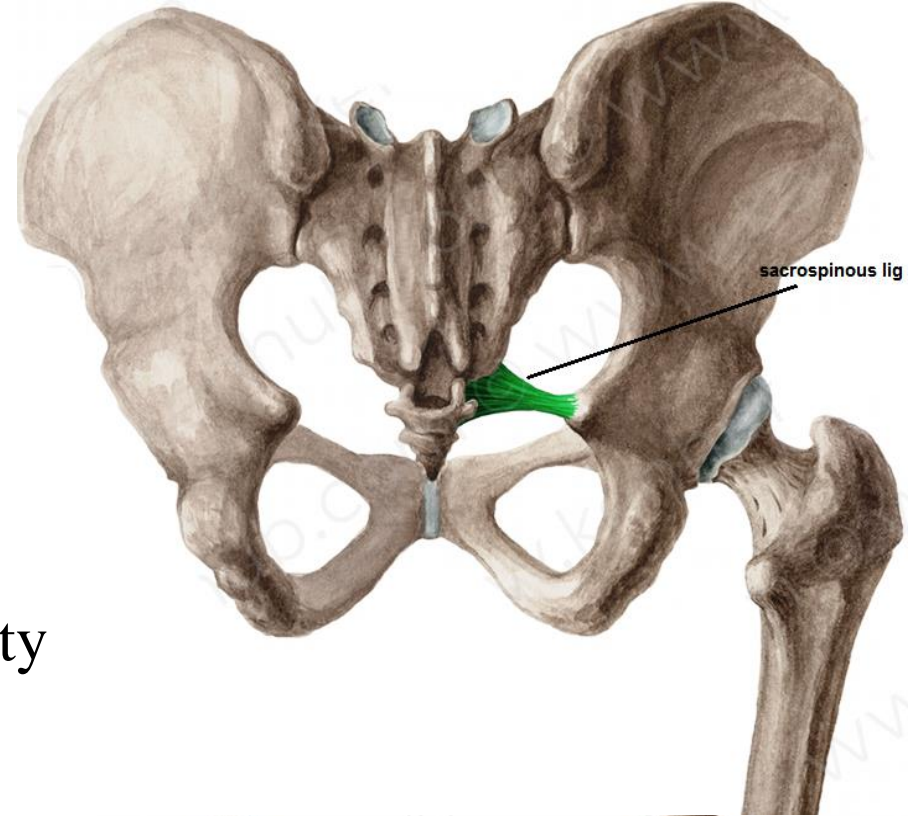
## **sacrospinous lig. :**

**From** medial border of ischial tuberosity

**To** back of sacrum & coccyx

## **Functions**

-transform sciatic notches into foramina





# MUSCLES

## DEEP MUSCLES

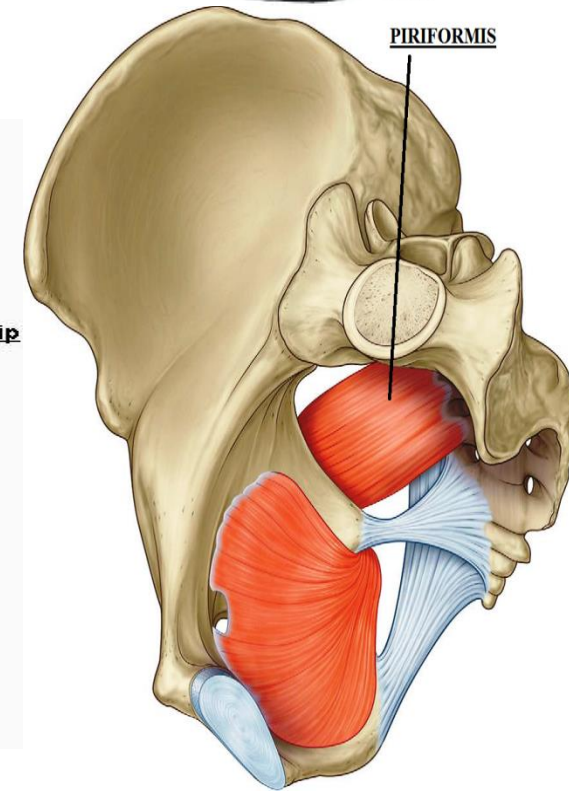
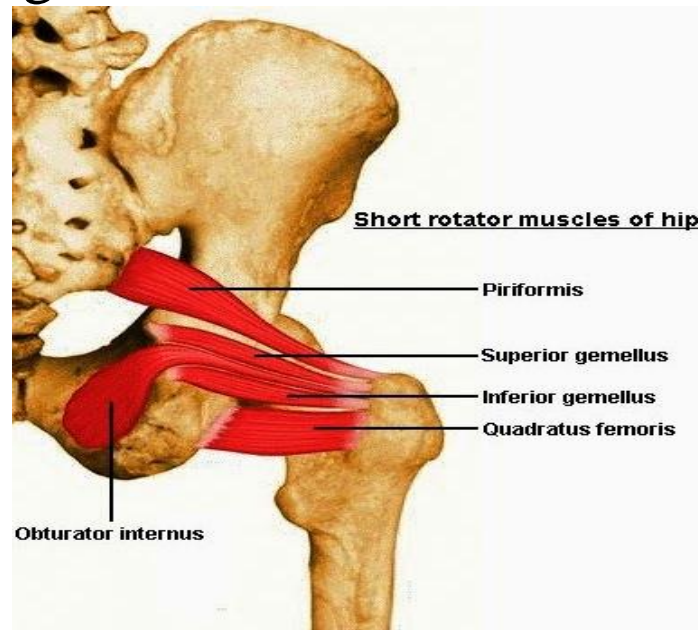
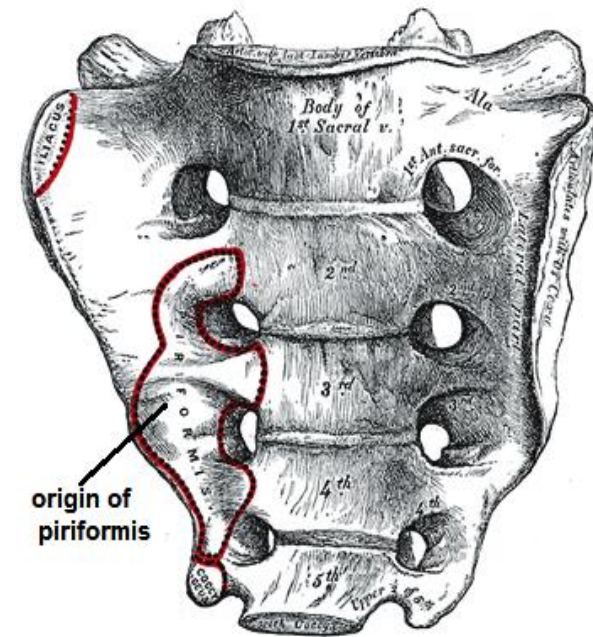
### piriformis

**O.:-** anterior surface of middle 3 sacral vertebrae

**I.:-** pass through greater sciatic foramen  
to upper border of greater trochanter

**N.S.:-** sacral plexus (S1, 2 nerves)

**A.:-** lateral rotation of thigh



# MUSCLES

## DEEP MUSCLES

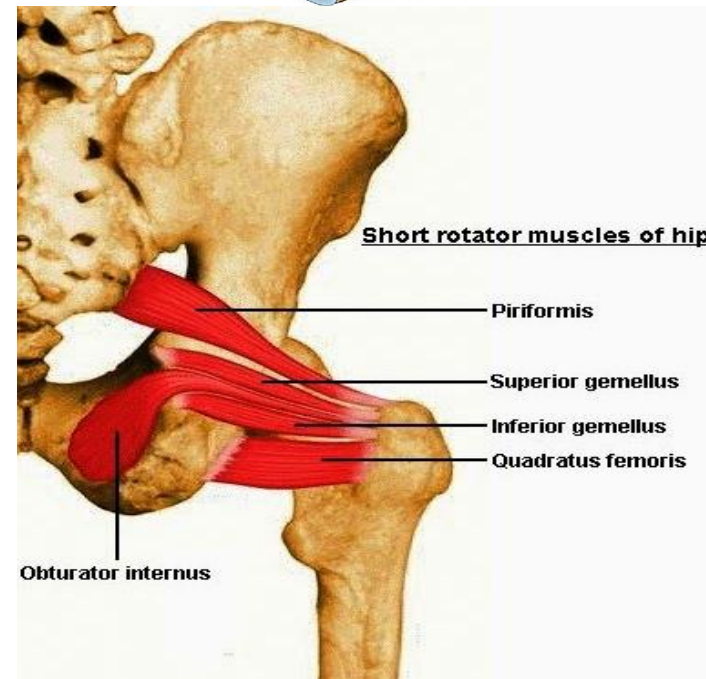
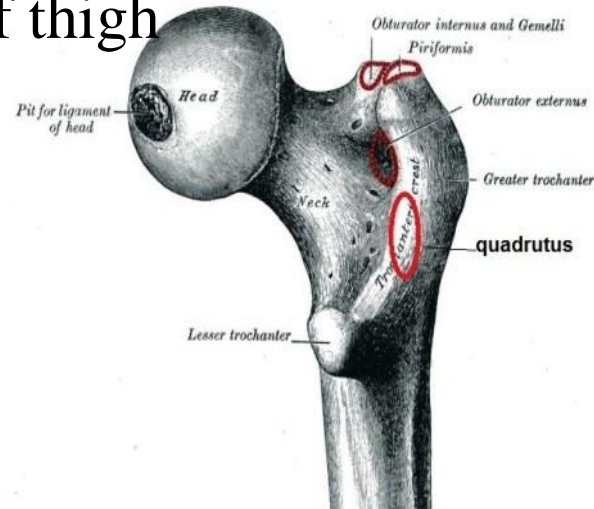
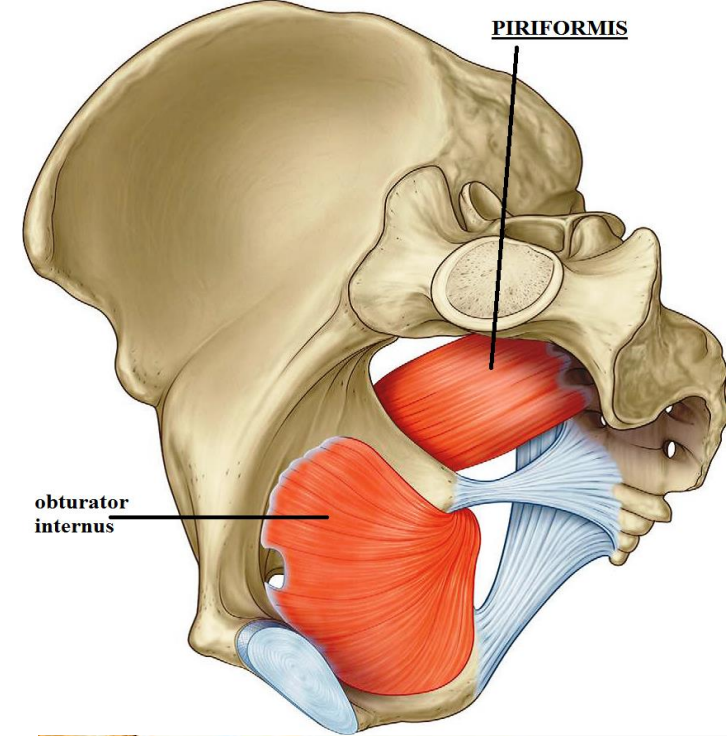
### obturator internus

**O.:-** inner surface of obturator membrane & the surrounding bone

**I.:-** pass through lesser sciatic foramen to insert in greater trochanter above trochanteric fossa

**N.S.:-** sacral plexus, n. to obturator internus

**A.:-** lateral rotation of thigh



# MUSCLES

## DEEP MUSCLES

### superior gemellus

**O.:-** upper border of lesser sciatic notch

**I.:-** upper border of tendon of obturator internus  
then to medial surface of greater trochanter

**N.S.:-**n. to obturator internus

**A.:-** lateral rotation of thigh

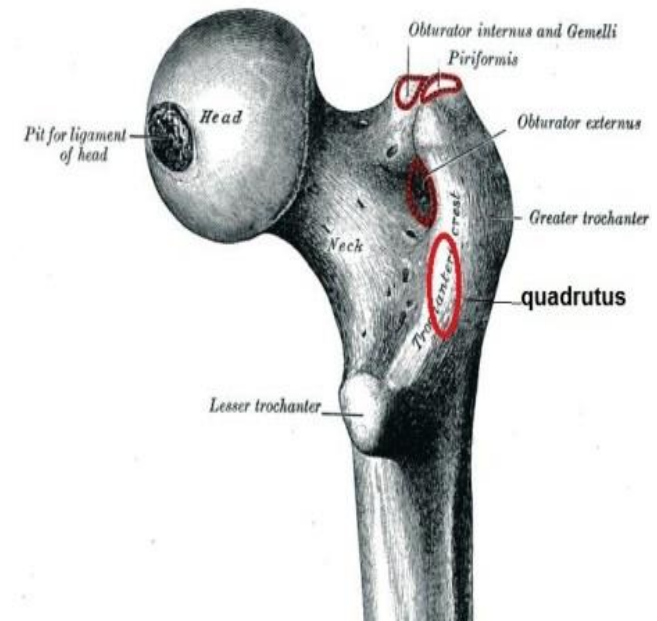
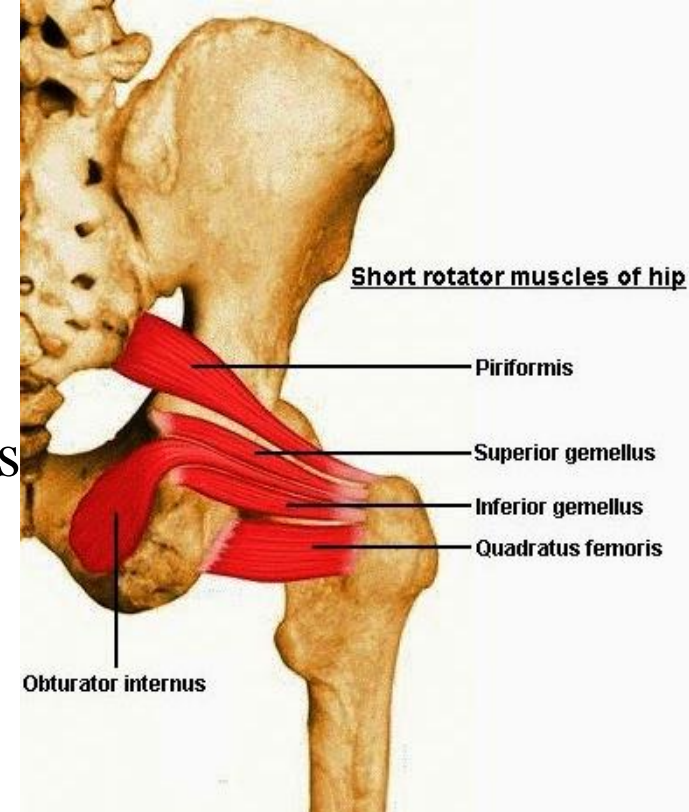
### inferior gemellus

**O.:-** lower border of lesser sciatic notch

**I.:-** lower border of tendon of obturator internus  
then to medial surface of greater trochanter

**N.S.:-**n. to quadratus femoris

**A.:-** lateral rotation of thigh





# MUSCLES

## DEEP MUSCLES

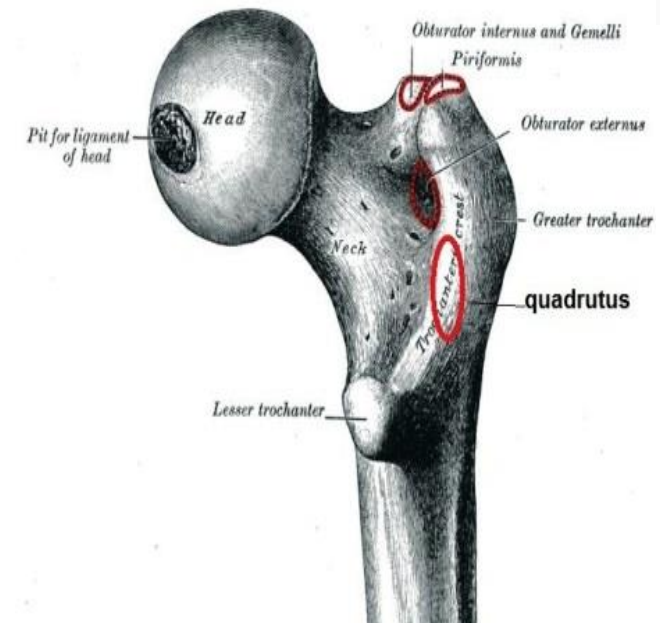
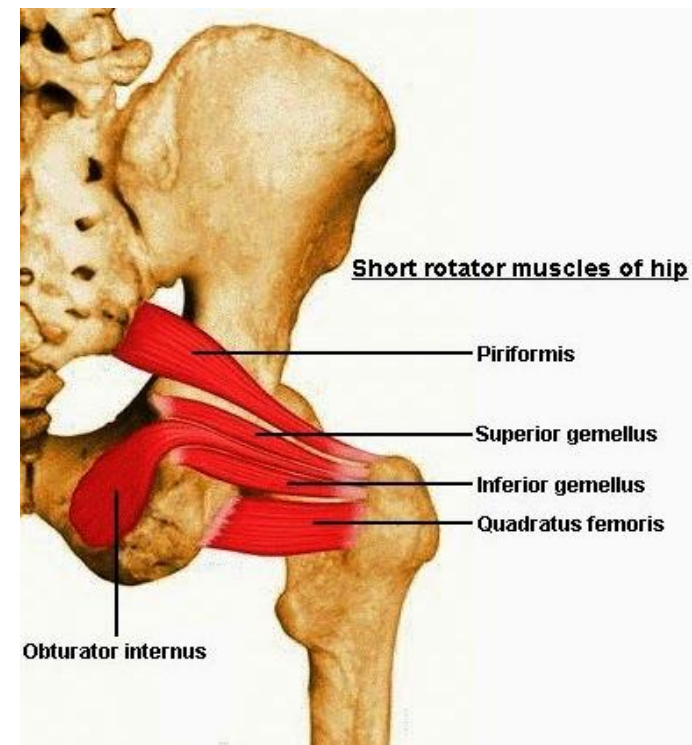
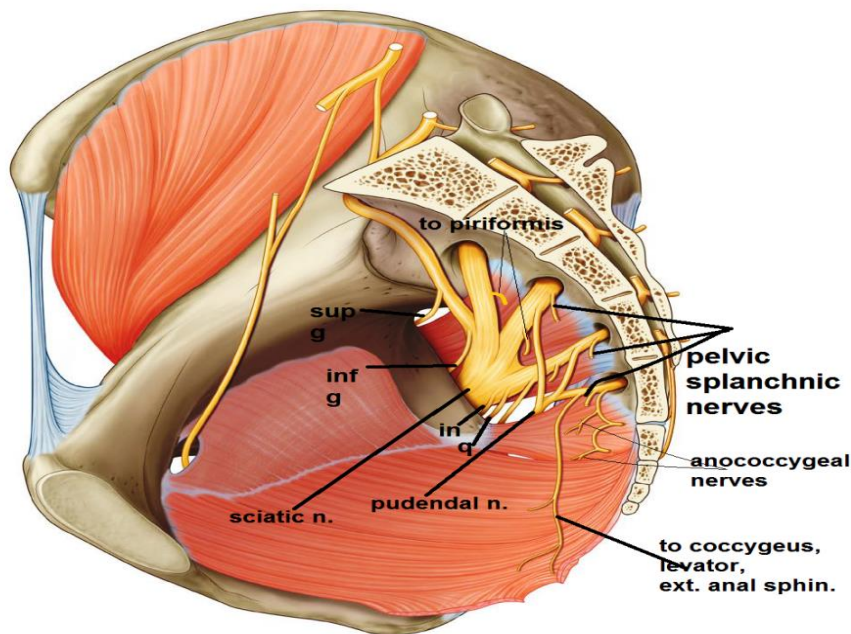
### quadratus femoris

**O.:-** Lateral border of ischial tuberosity

**I.:-** quadrate tubercle

**N.S.:-** sacral plexus, n. to quadratus femoris

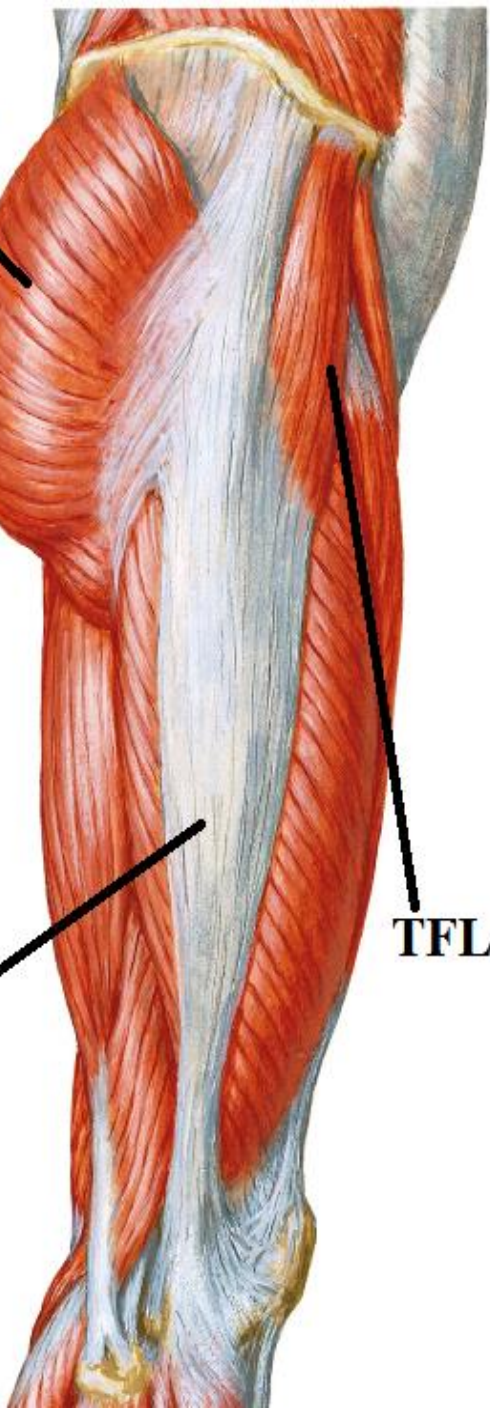
**A.:-** lateral rotation of thigh



**G Mx**

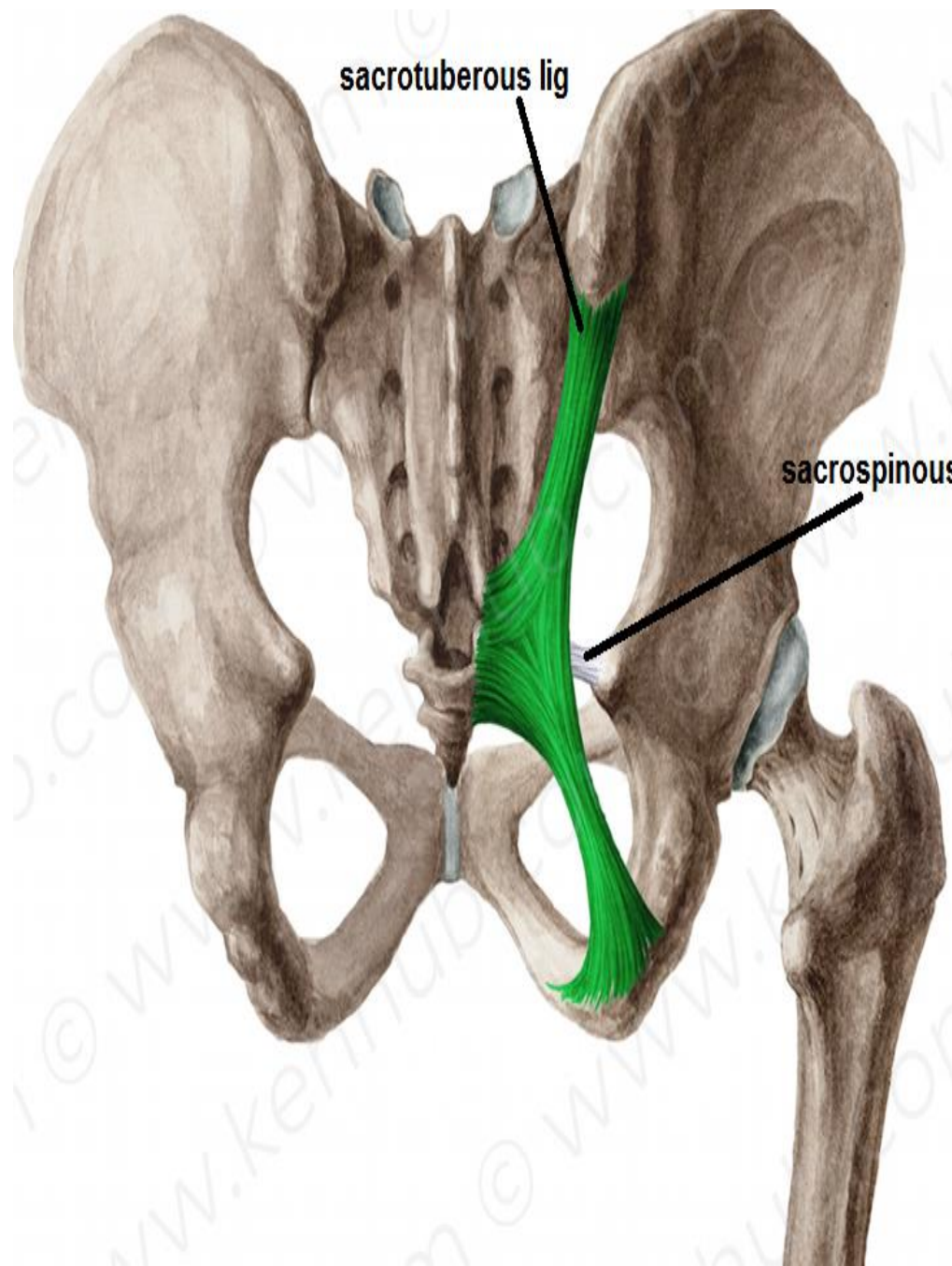
**ITT**

**TFL**



sacrospinous lig

sacrospinous lig





# MUSCLES

## SUPERFICIAL MUSCLES

### **Gluteus minimus:**

**O.:** outer surface of ilium( )ant.& inferior gluteal lines

**I. :** front of greater trochanter.

### **gluteus medius :**

**O. :** outer surface of ilium ( ). post. & ant. gluteal lines

**I. :**lateral aspect of greater trochanter.

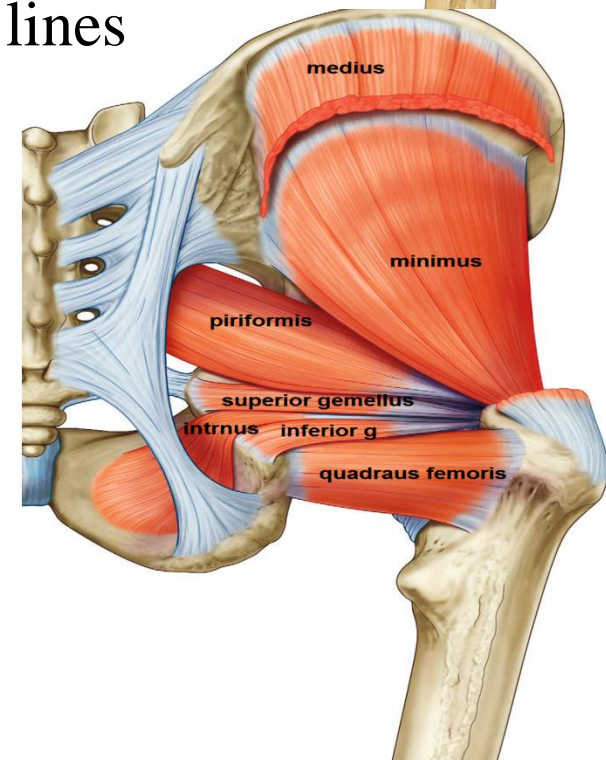
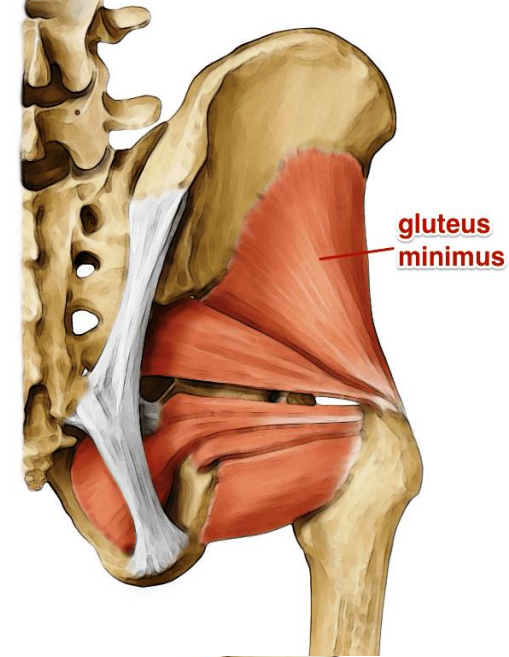
**N.S :** both supplied by superior gluteal n.

### **ACTION :**

1- abduction of thigh

2- Medial rotation of thigh by the ant. fibers

3-prevent tilting of pelvis towards unsupported side on standing on one limb so paralysis of these muscles on both sides causes waddling gait





# MUSCLES

## SUPERFICIAL MUSCLES

### gluteus maximus:

**O.** : outer surface of ilium behind post. gluteal line

Back of sacrum & coccyx &  
sacrospinous lig.

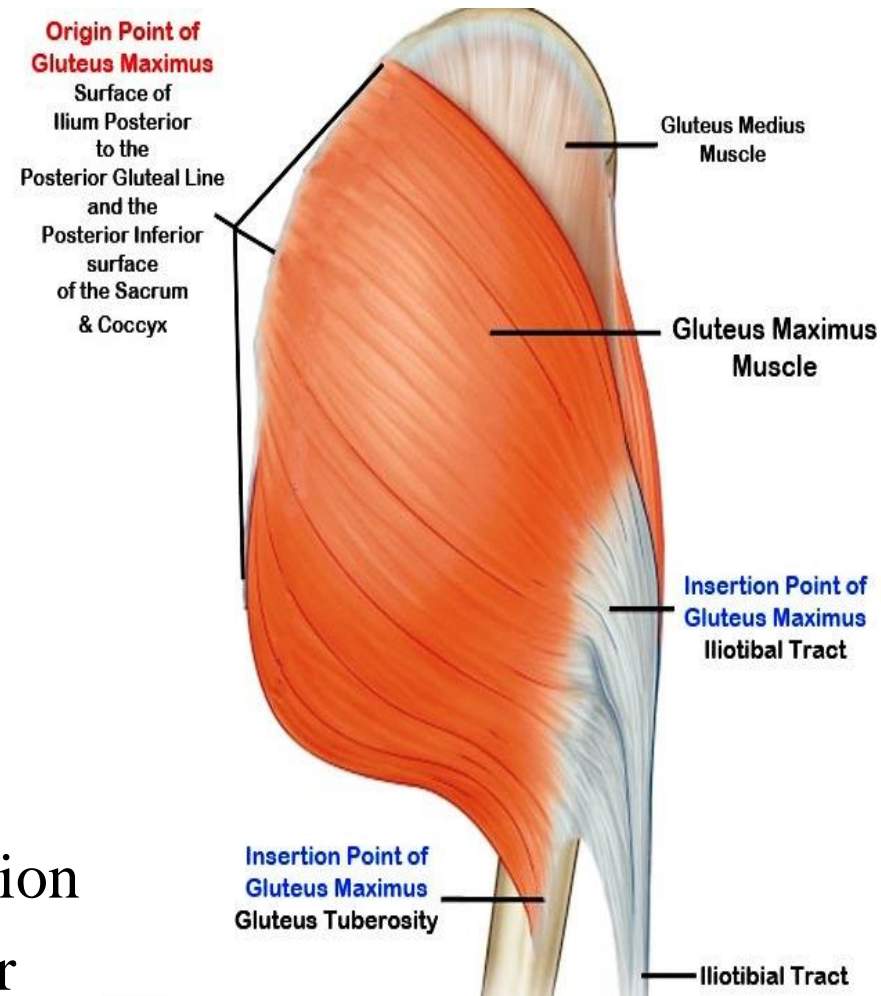
**I.** : superficial 3 / 4 insert in  
post. border of iliotibial tract  
deep 1 / 4 insert in  
gluteal tuberosity

**N.S.** : inferior gluteal n.

**A.** :

1-main extensor of hip joint

2- tense iliotibial tract in standing position  
to keep bone of L.L above each other



# MUSCLES

## SUPERFICIAL MUSCLES

### tensor fascia lata :

**O.:** ant. 5cm of outer lip of iliac crest

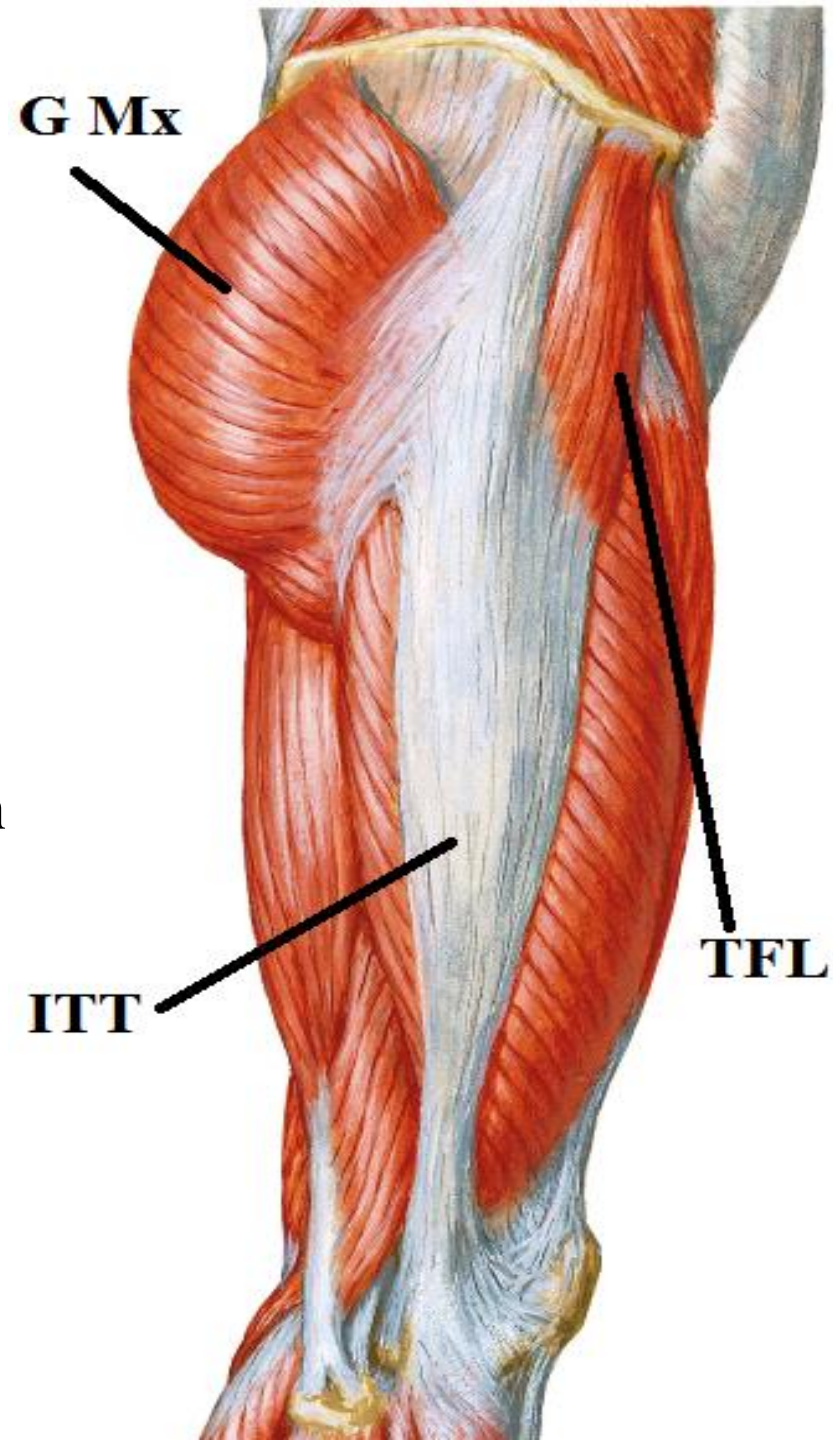
**I.:** ant. border of iliotibial tract

**N.S.:** superior gluteal n.

**A.:**

1-abduction of thigh

2-tense iliotibial tract in standing position  
to keep bone of L.L above each other





# FORAMINA

**greater sciatic foramen :**

piriformis

structures above piriformis

superior gluteal n &

superior gluteal vessels

structures below piriformis

inferior gluteal n.&

inferior gluteal vessels

sciatic n.

post. cut. n. of thigh.

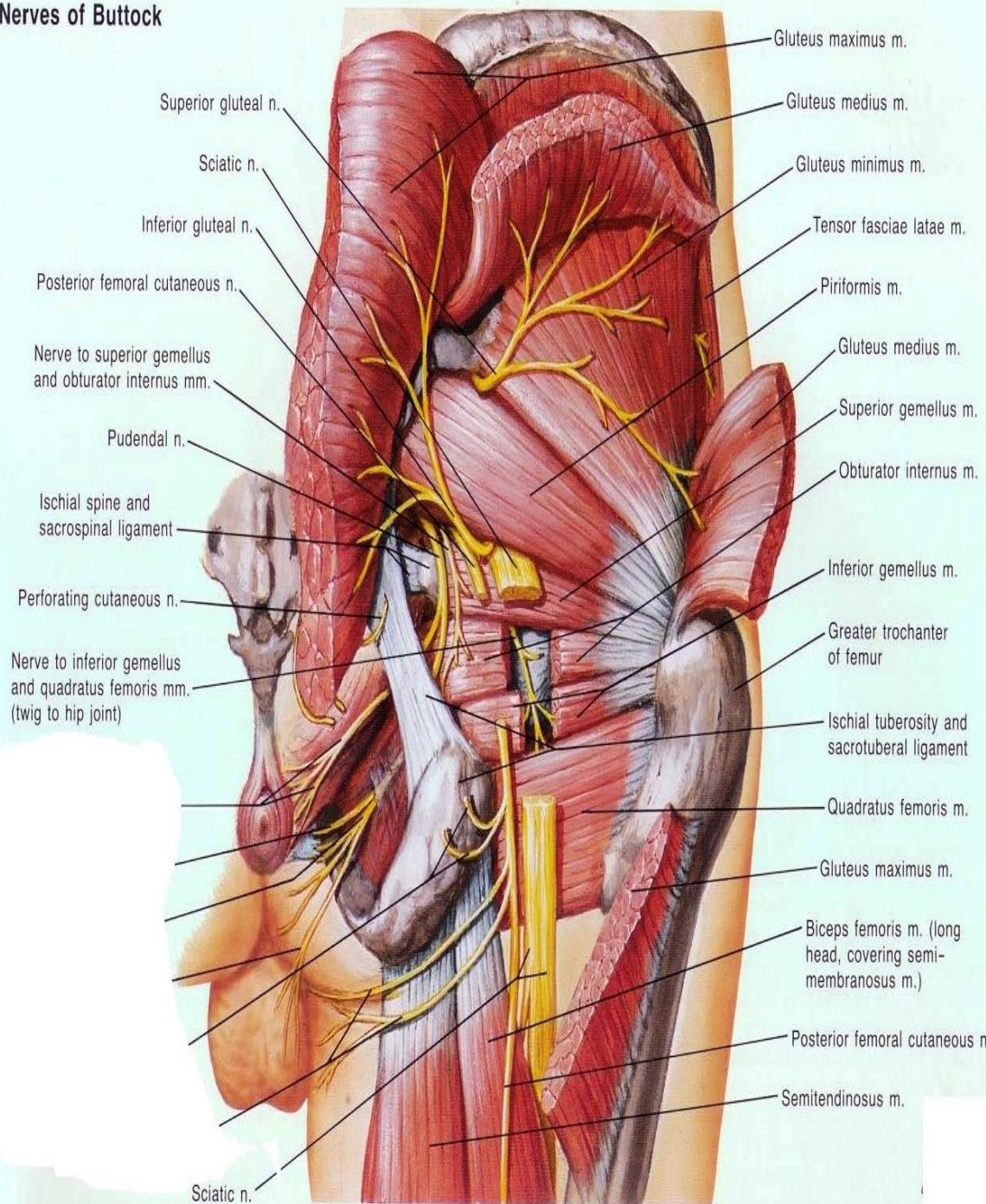
n. to quadratus femoris

n. to obturator internus

int. pudendal vessels

Pudendal n.

Nerves of Buttock



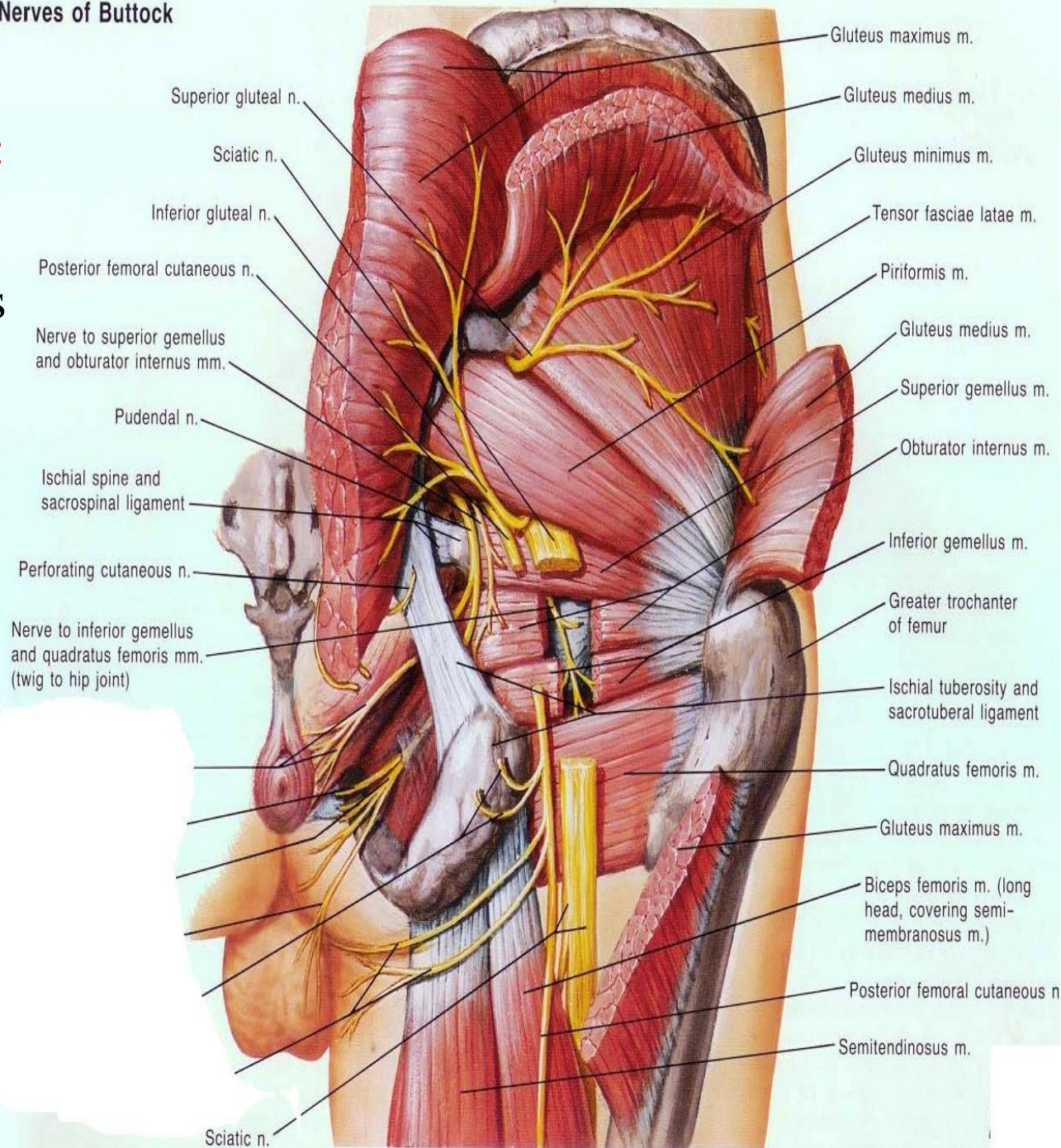


# FORAMINA

## lesser sciatic foramen :

- obturator internus
- n. to obturator internus
- int. pudendal vessels
- pudendal n.

### Nerves of Buttock





# NERVES OF GLUTEAL REGION :

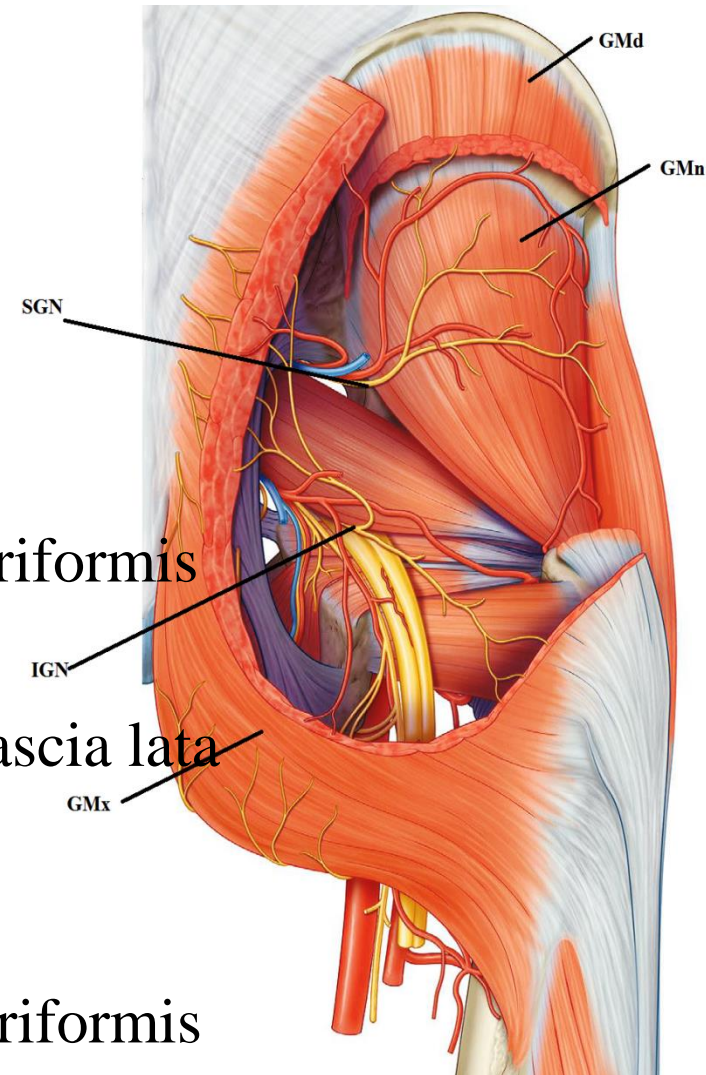
- superior gluteal n. -inferior gluteal n.
- sciatic n -post. cut. n. of thigh
- to Quadratus femoris -n. to obturator internus
- pudendal n.

## superior gluteal n.

- arise inside pelvis from sacral plexus
- pass through greater sciatic foramen above piriformis
- pass ( ) gluteus medius & minimus
- supply gluteus medius& minimus & tensor fascia lata

## inferior gluteal n. :

- arise inside pelvis from sacral plexus
- pass through greater sciatic foramen below piriformis
- supply gluteus maximus



THANQ