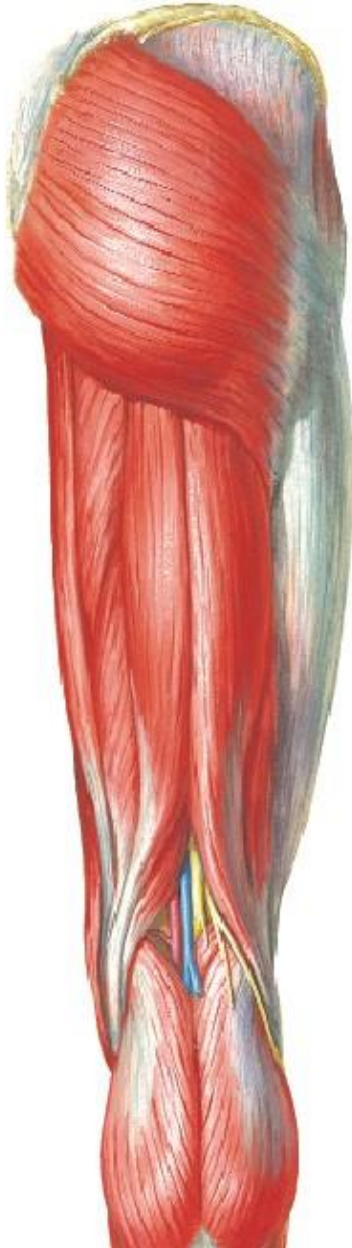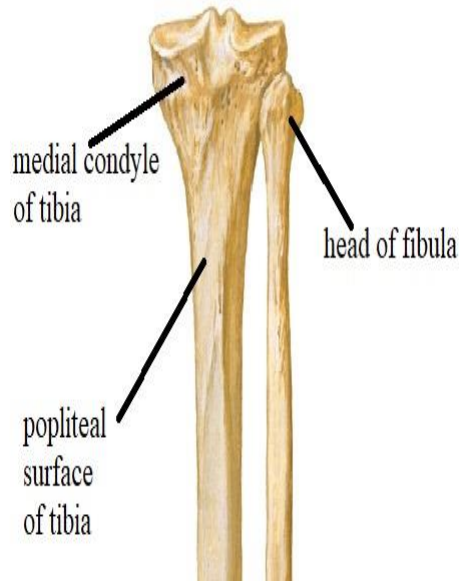
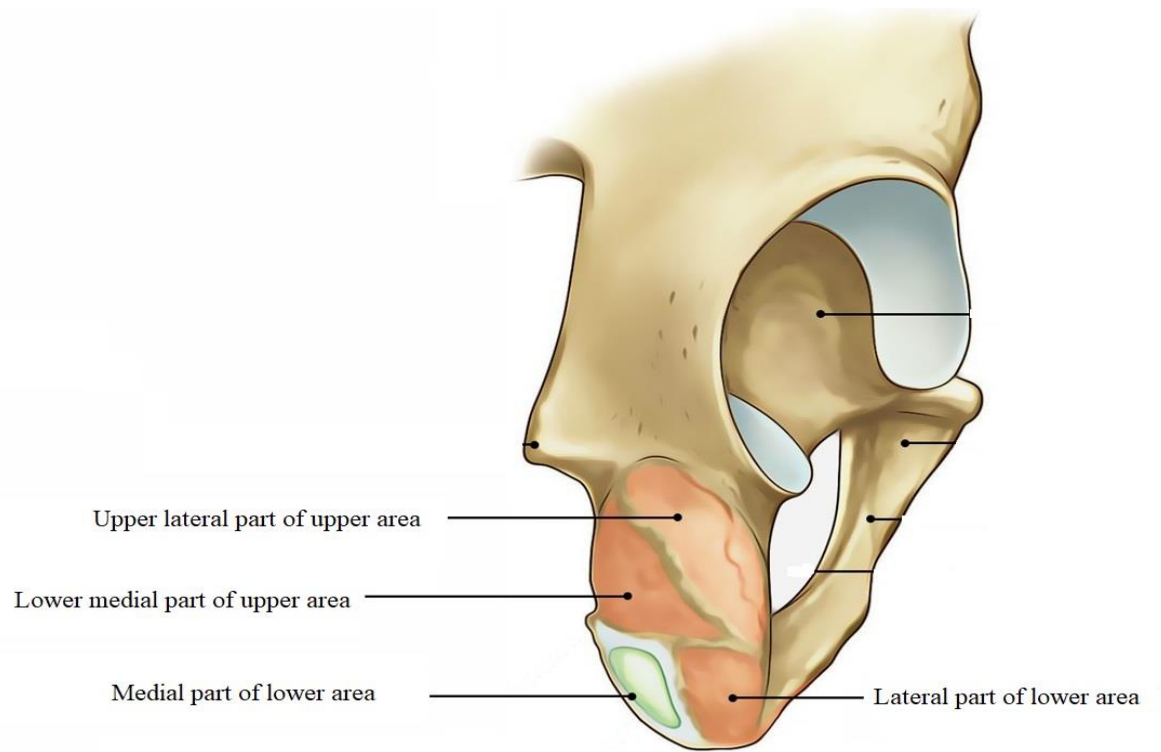
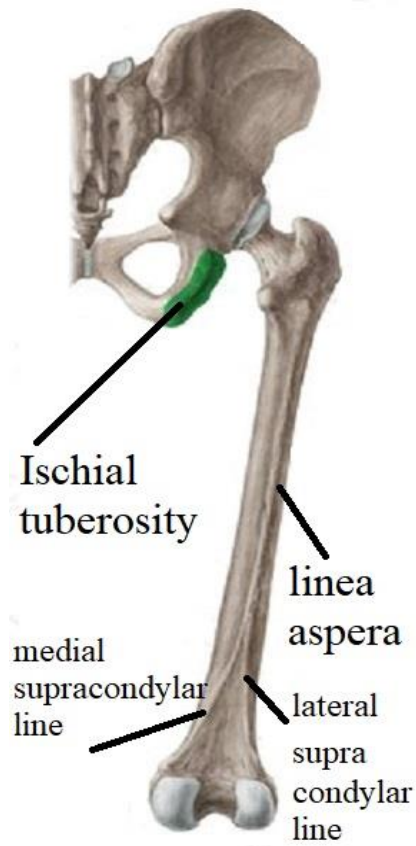


HAMSTRING MUSCLES & POPLITEAL FOSSA



BY

DR ABULMAATY MOHAMED
ASSISTANT PROFESSOR
ANATOMY & EMBRYOLOGY
MUTAH UNIVERSITY

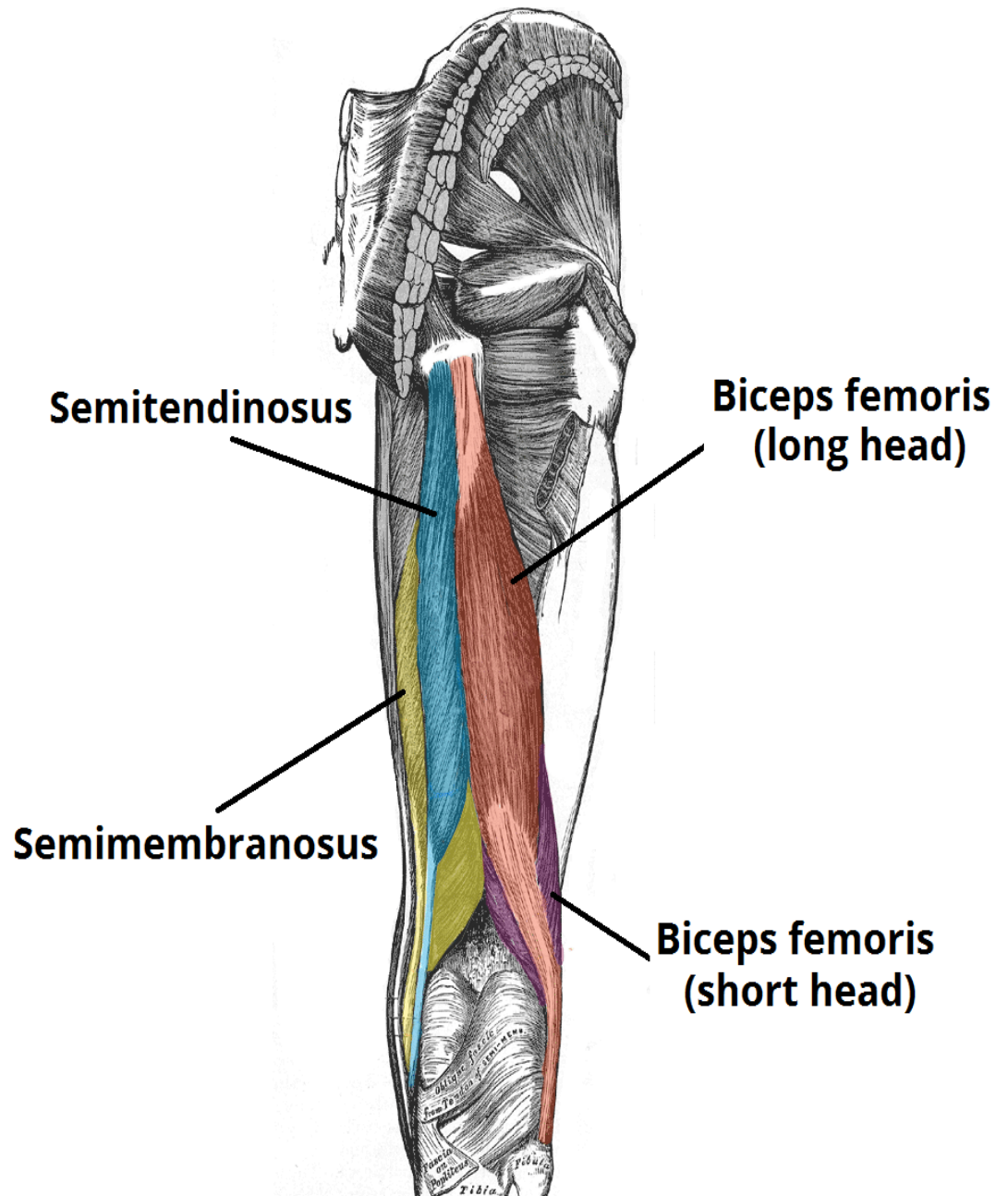


HAMSTRING MUSCLES

Semimembranosus

Semitendinosus

Biceps femoris



HAMSTRING MUSCLES

SEMIMEMBRANOSUS

upper half is thin like a membrane

O.: upper lateral part of upper area of ischial tuberosity

I.: back of medial condyle of tibia & this insertion extends as :

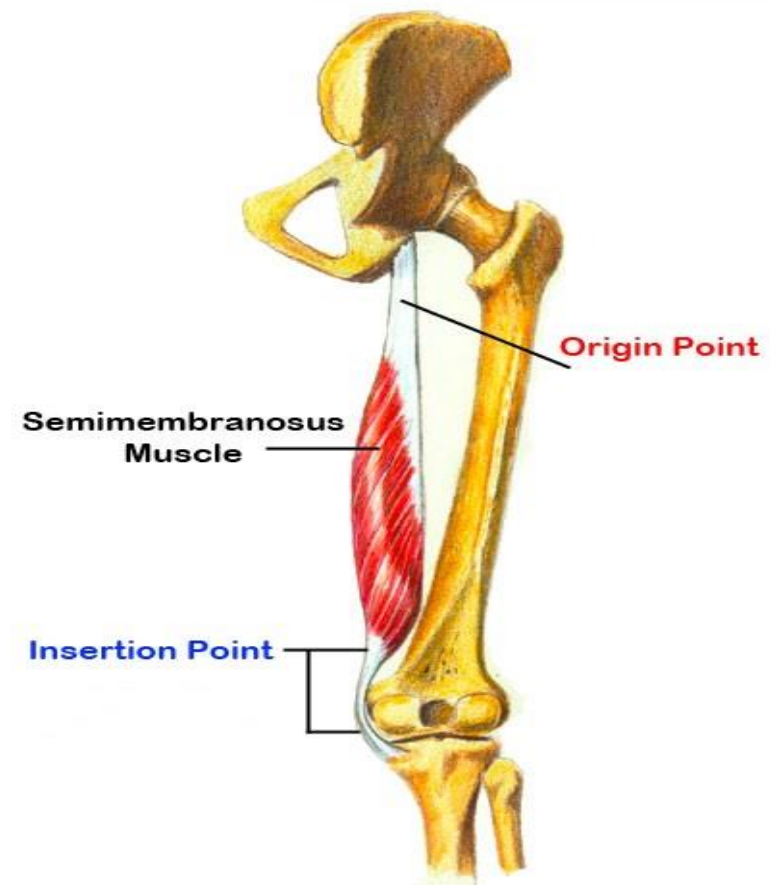
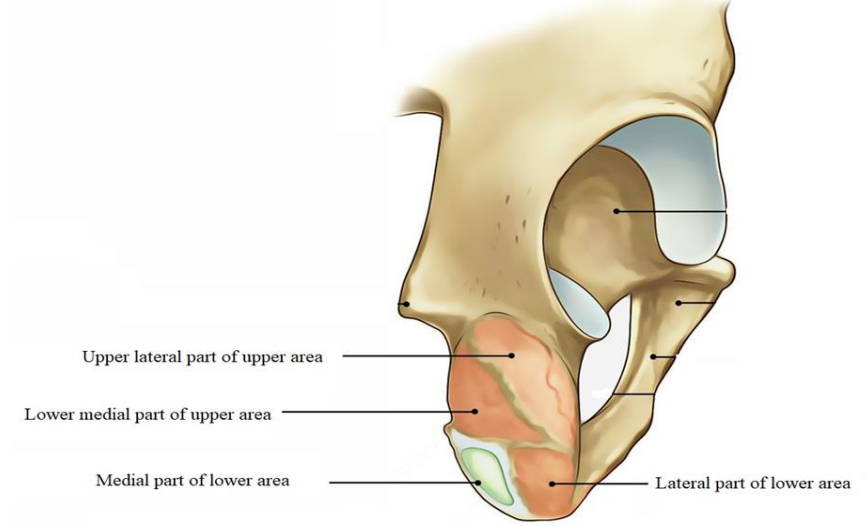
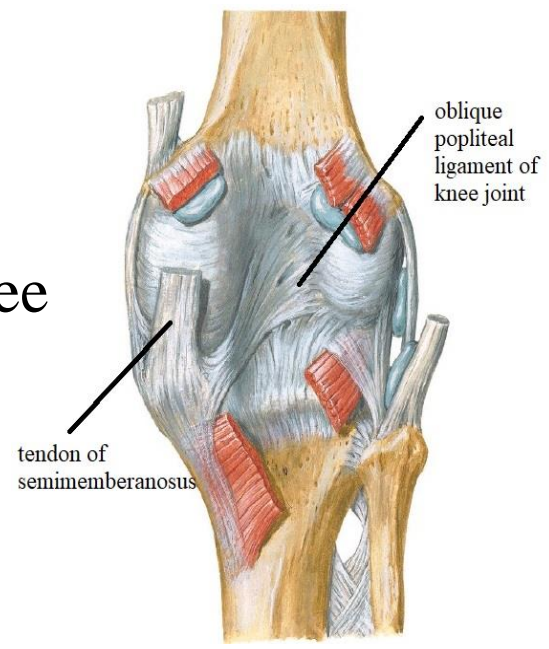
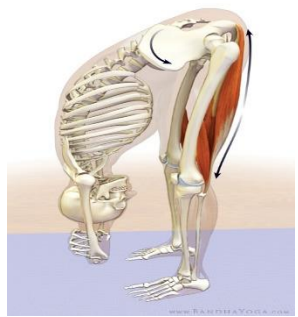oblique popliteal ligament of knee joint

Action:

extension of hip

flexion of knee

medial rotation of knee



HAMSTRING MUSCLES

SEMIMETENDINOSUS

lower half is a cord like tendon

O.: with long head of biceps
from lower medial part of upper area
of ischial tuberosity

I.: upper part of medial surface of tibia

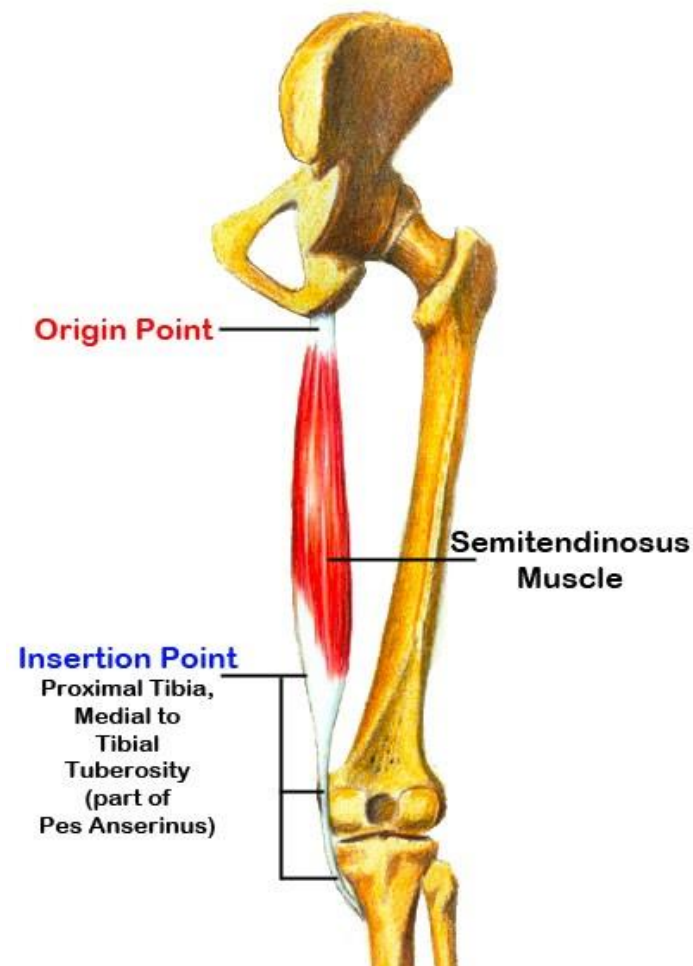
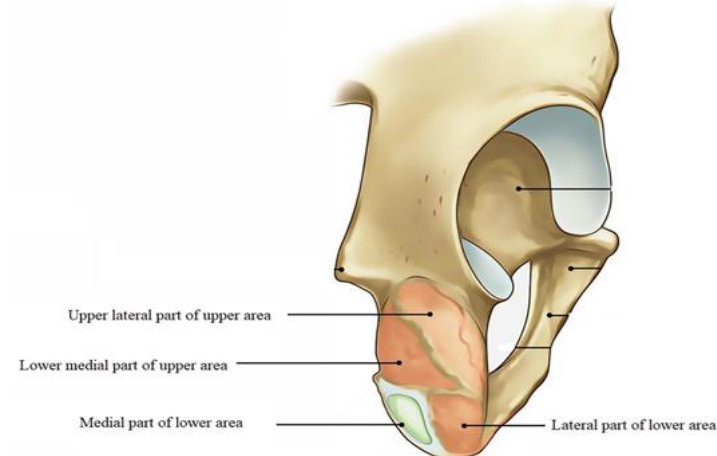
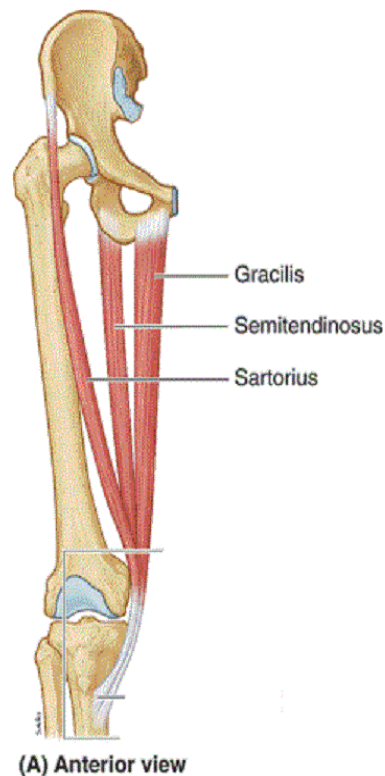
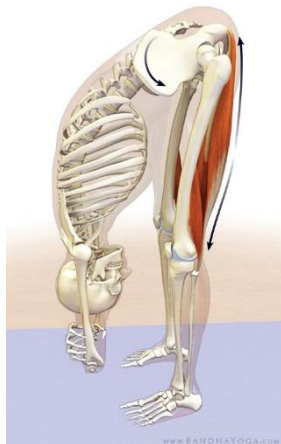Action:

extension of hip

flexion of knee

medial rotation of knee

guy rope ??



HAMSTRING MUSCLES

BICEPS FEMORIS

O.:

long head:

with semitendinosus
from lower medial part of upper area
of ischial tuberosity

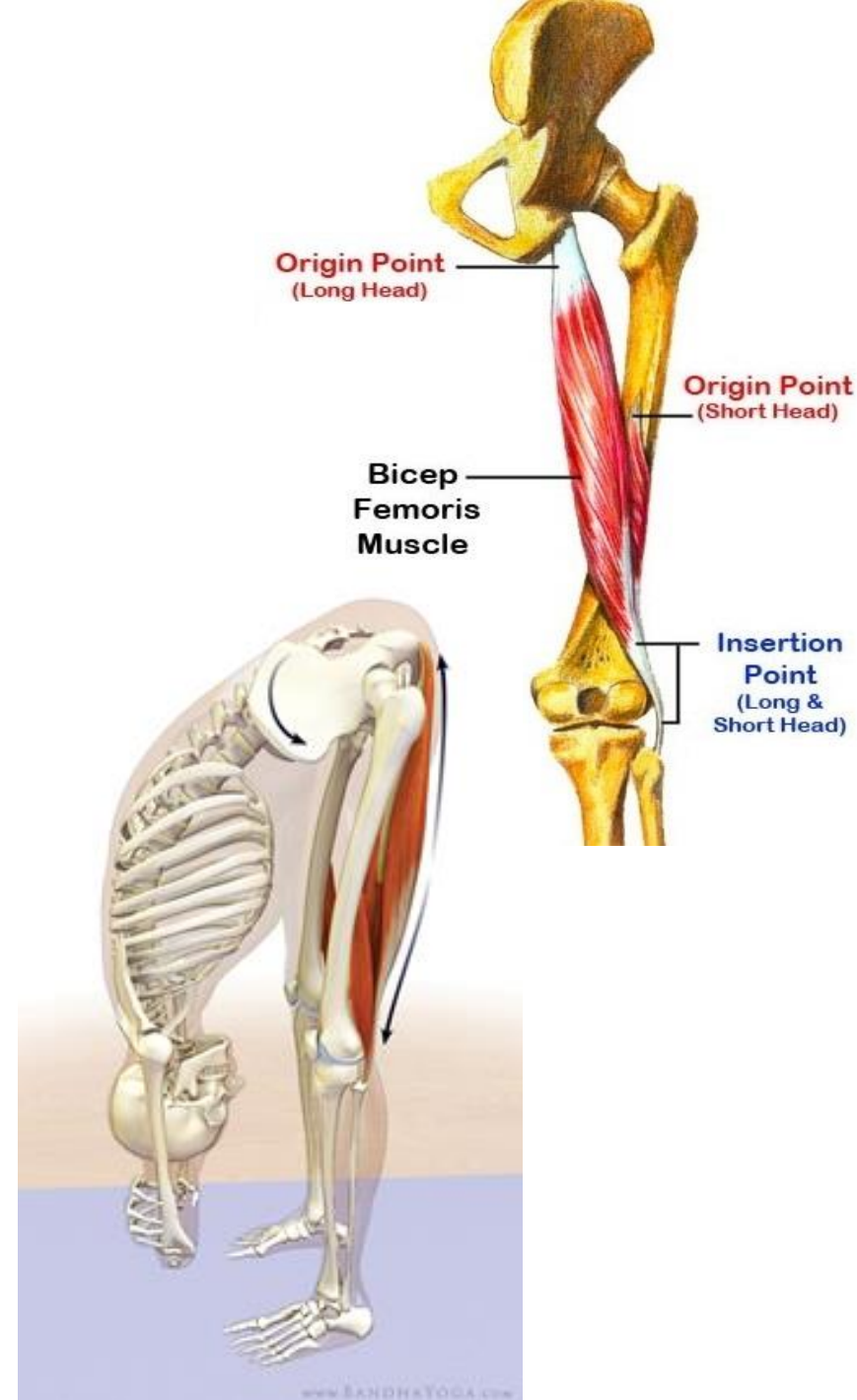
short head:

linea aspera &
upper part of lateral supracondylar line

I.: apex of head of fibula

Action :

extension of hip
flexion of knee
lateral rotation of knee



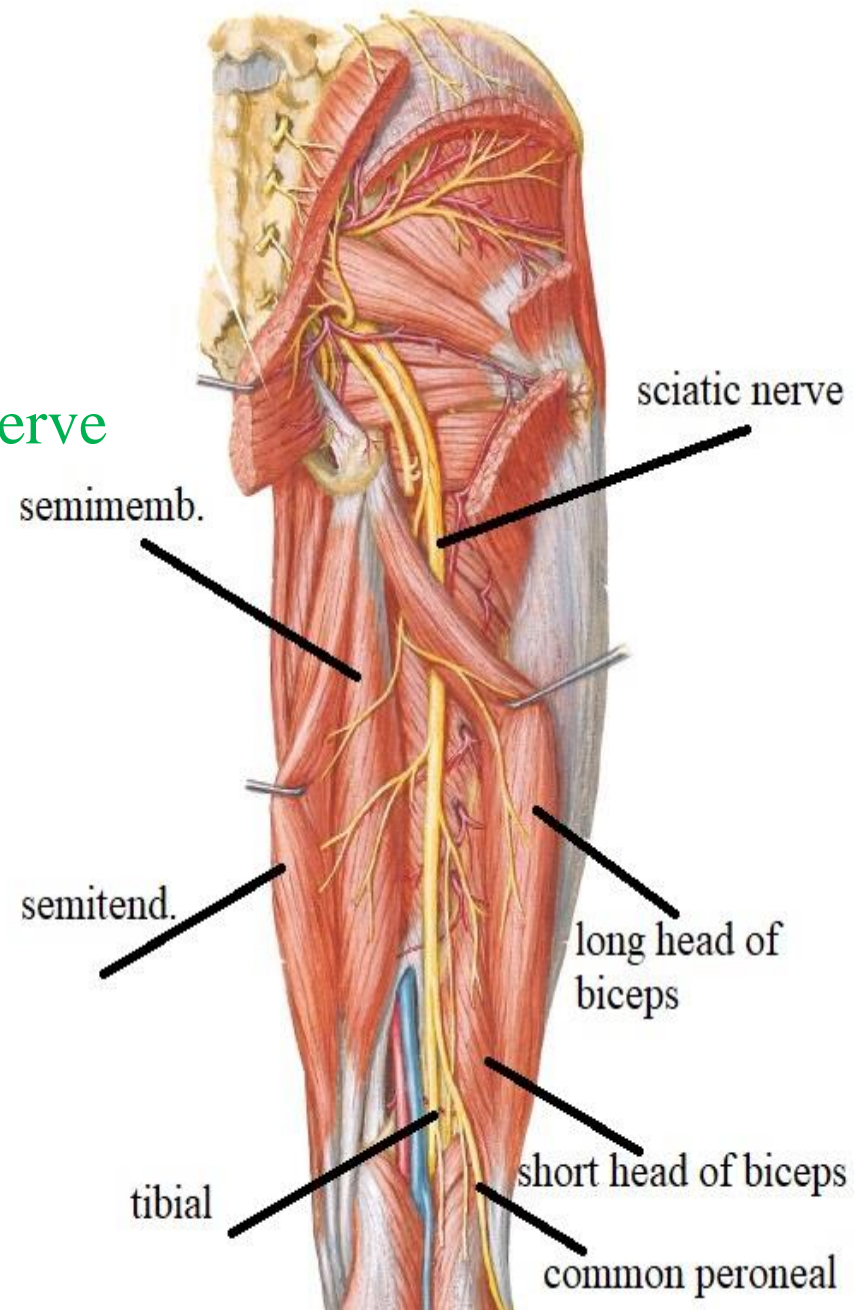
HAMSTRING MUSCLES

NERVE SUPPLY OF HAMSTRING MUSCLES

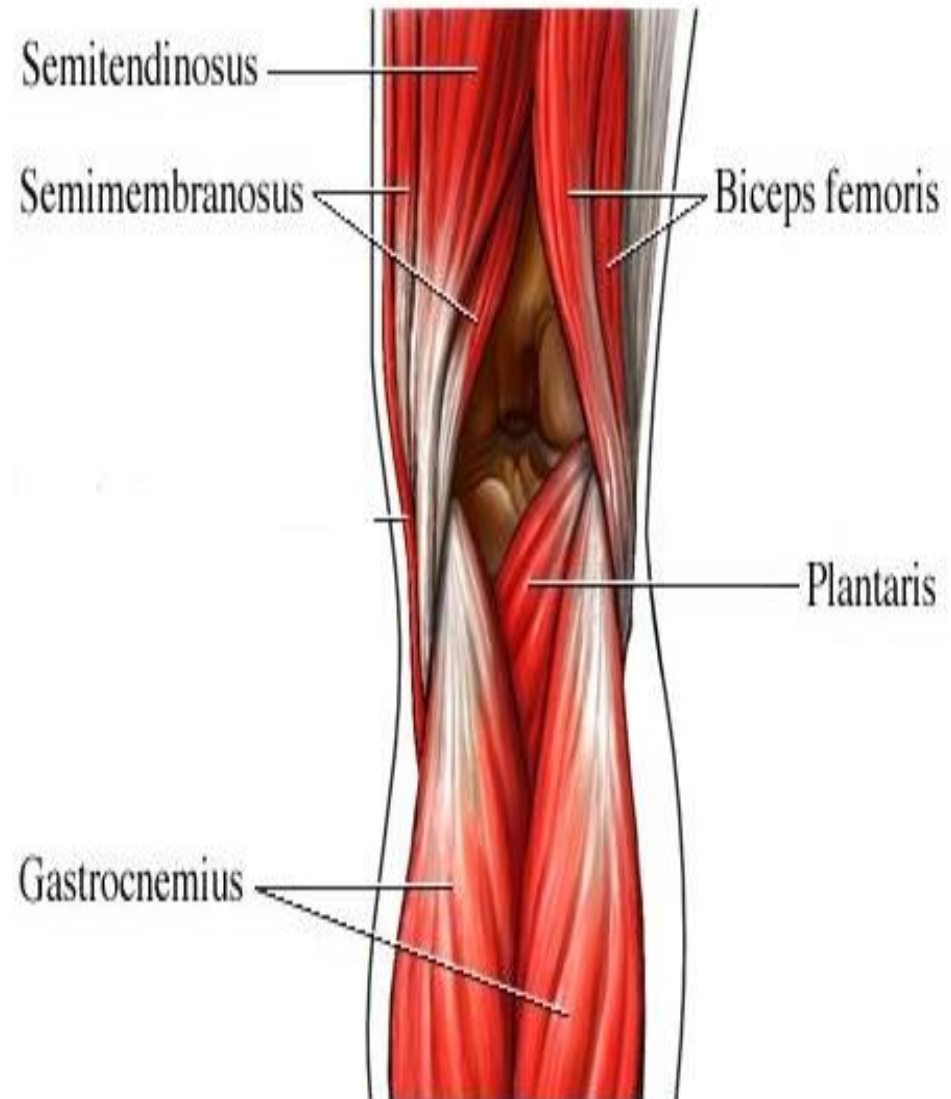
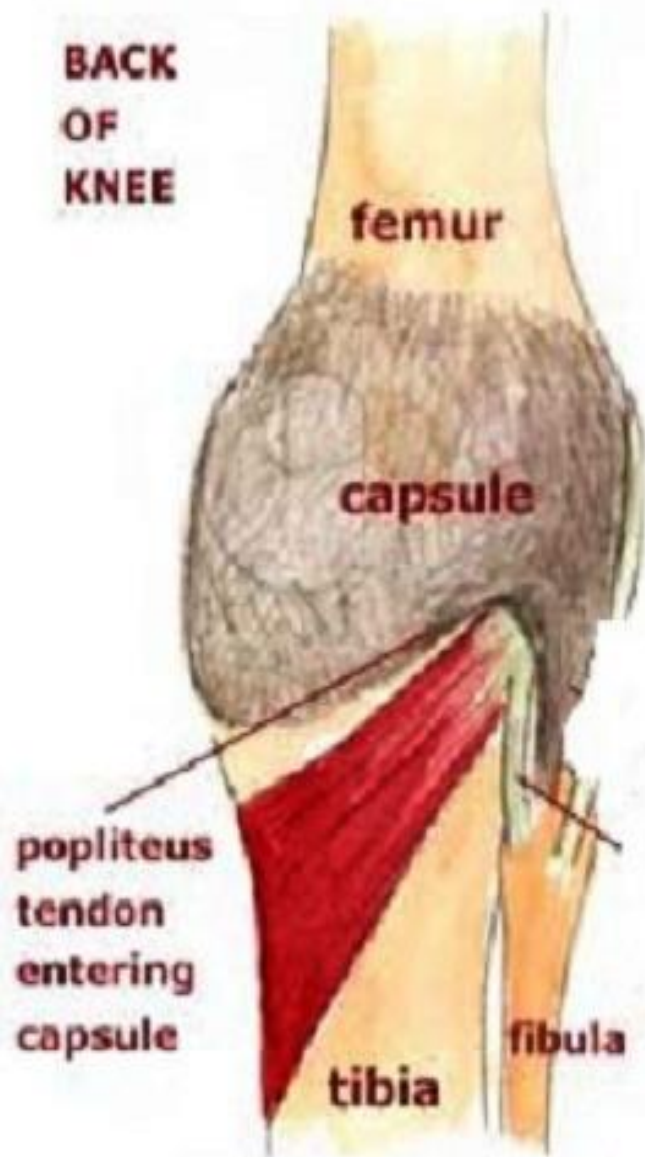
From tibial part of sciatic nerve except

short head of biceps

from common peroneal part of sciatic nerve



POPLITEAL FOSSA



POPLITEAL FOSSA

DEF. & SITE:

tissue space behind lower part of thigh, knee & upper part of leg

BOUNDRIES :

diamond shaped with 4 borders

UPPER&MEDIAL

semimembranosus & semitendinosus

UPPER&LATERAL

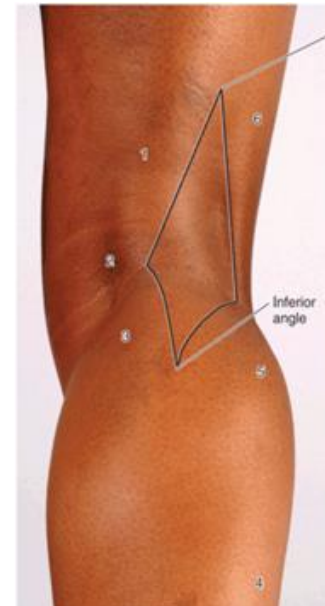
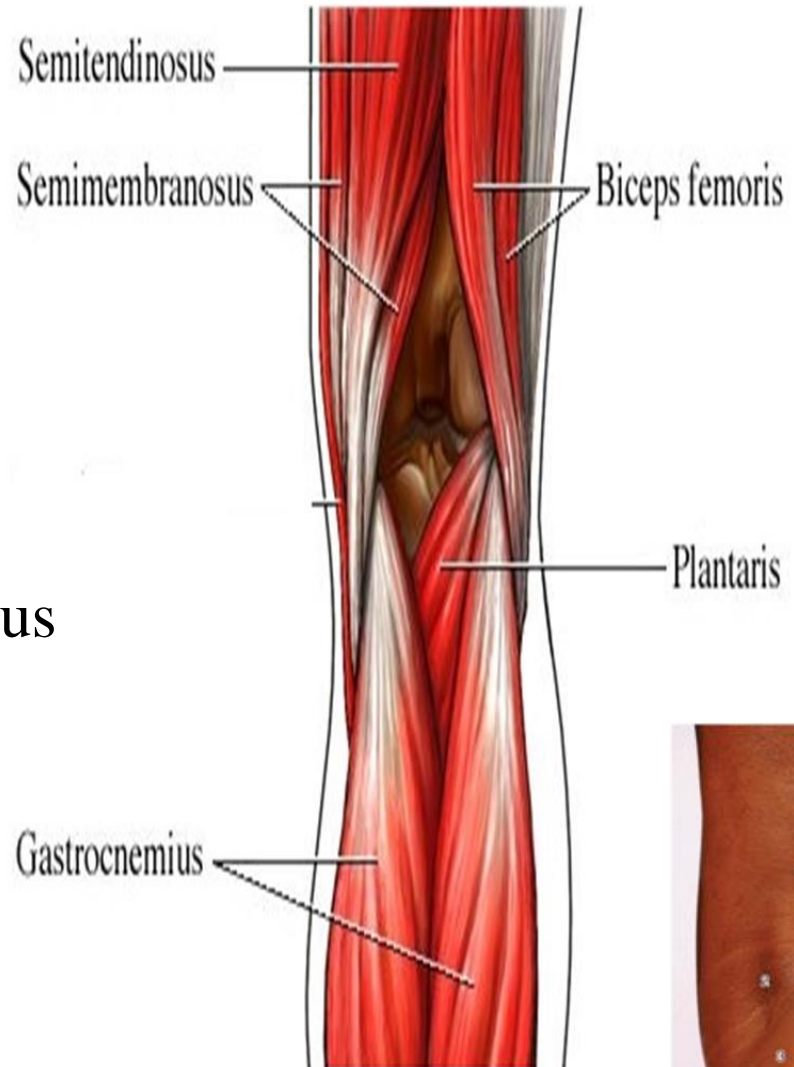biceps femoris

LOWER& MEDIAL

medial head of gastrocnemius

LOWER&LATERAL

lateral head of gastrocnemius & plantaris



POPLITEAL FOSSA

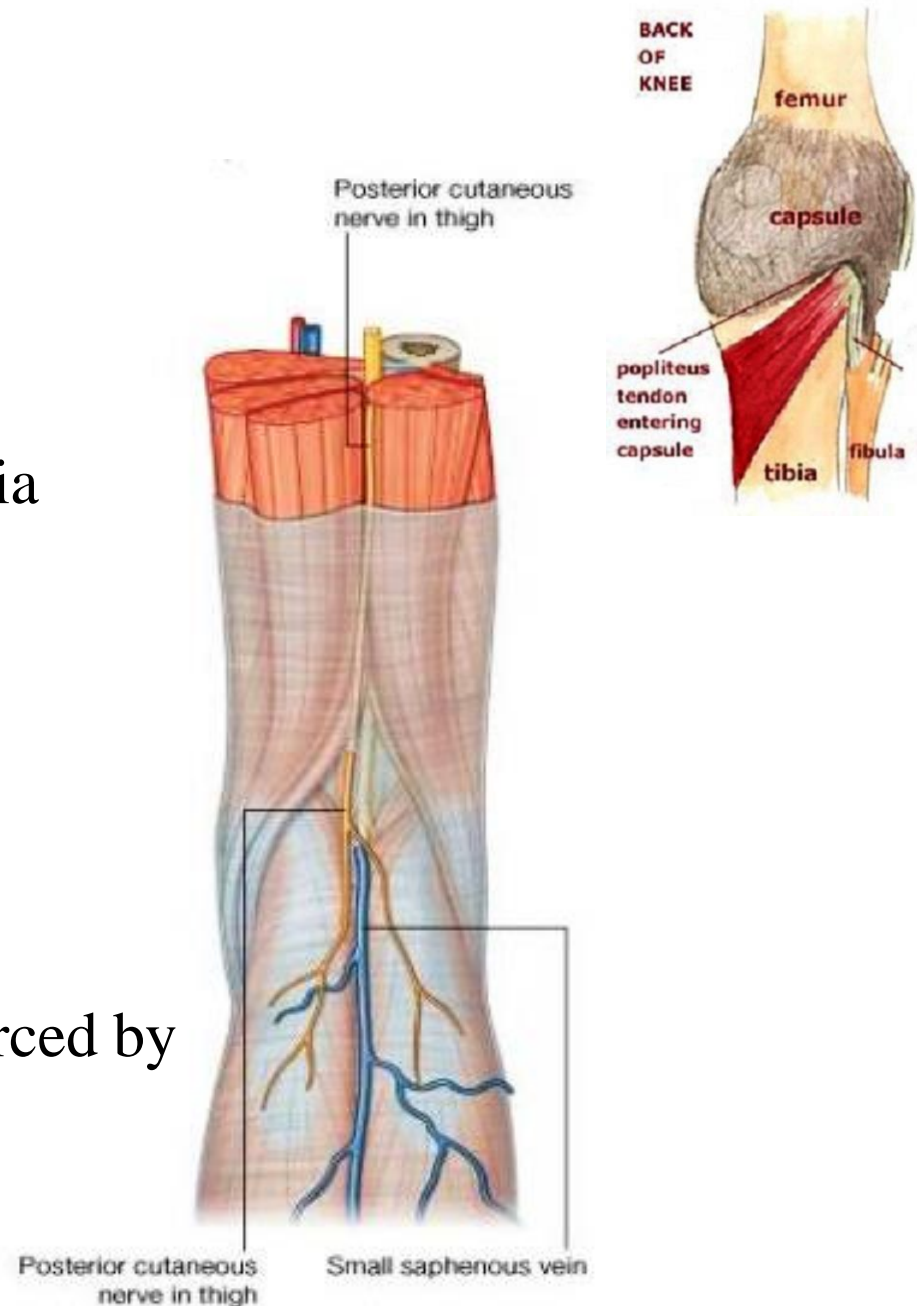
BOUNDRIES :

FLOOR

- popliteal surface of femur
- capsule of knee joint
- popliteus muscle & covering fascia

ROOF

- skin
- superficial fascia: contain
 - short saphenous v.
 - post. cut. n. of thigh
- deep fascia (popliteal fascia): pierced by
 - short saphenous v.
 - lymphatics to popliteal LNs



POPLITEAL FOSSA

CONTENTS

1-popliteal art. & its branches :
deepest structure

2-popliteal V. & its tributaries:
superficial to the artery

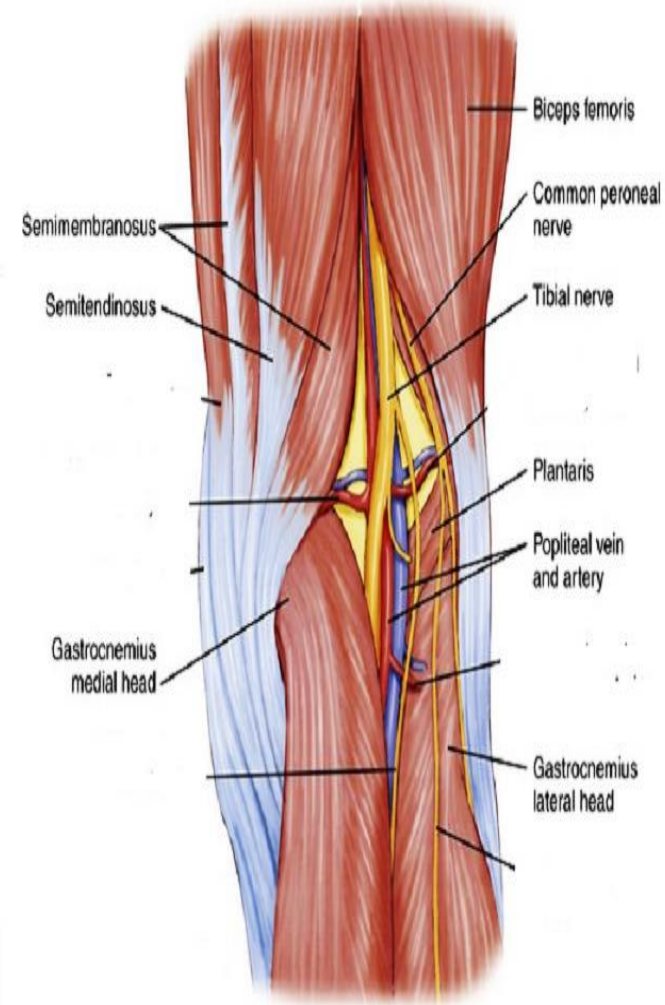
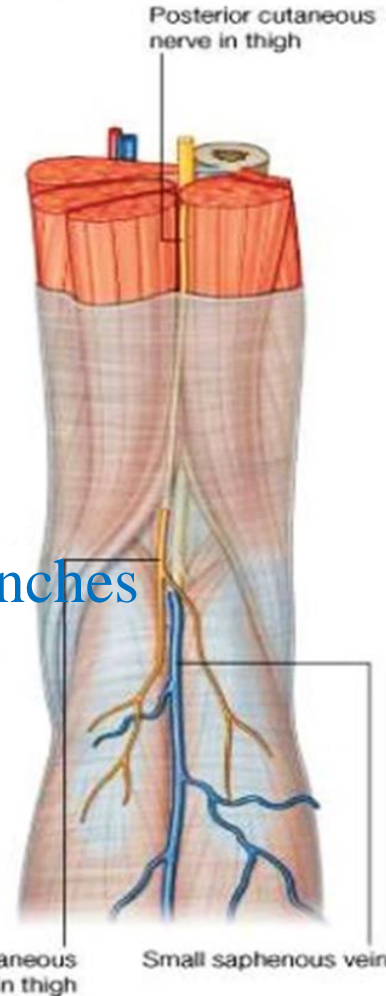
3- popliteal L.Ns

4- popliteal fat

5-tibial n. & its branches:
superficial to the vein

6-Common peroneal n. & its branches

7- post. cut. n. of thigh



THANQ