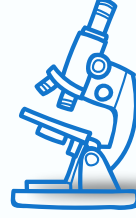

# GASTROINTESTINAL

LAB



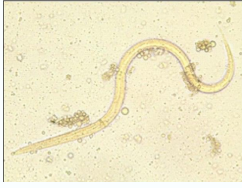مخبر

Done by:

Bayan Mahmoud

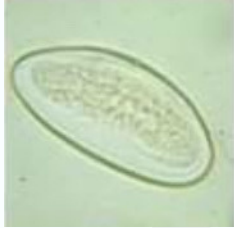

1. What is the following structure?



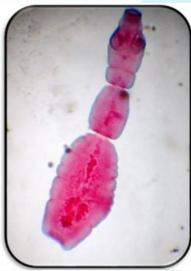
**Strongyloides stercoralis larvae**

2. What is the following structure?



**Enterobius vermicularis eggs D-shape**

3. What is the following structure?



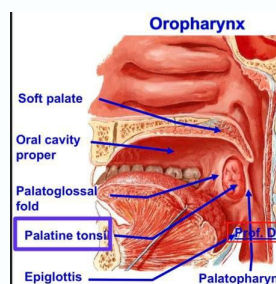
**Echinococcus granulosus adult**

4. What is the following structure?



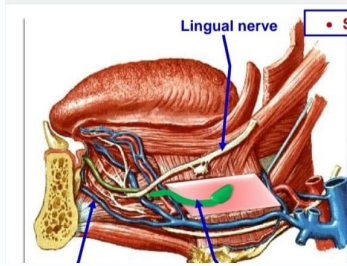
**Trichuris trichiura adult male**

5. What is the following structure?



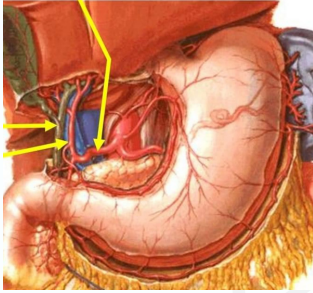
وَإِنْ تَهتَّ فَتَذَكَّرْ : "فَأِنَّكَ بِأَعْيُنِنَا"

6. What is the following structure?

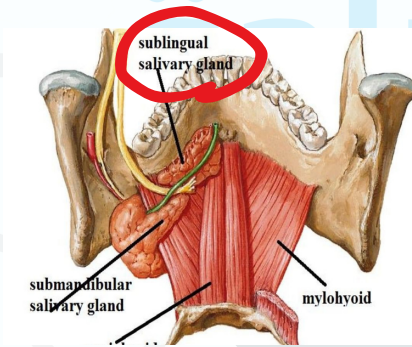


7. What is the following structure?

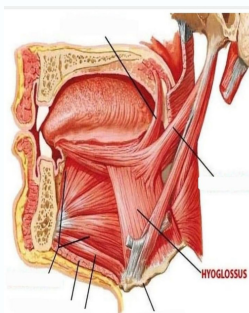
Hepatic artery



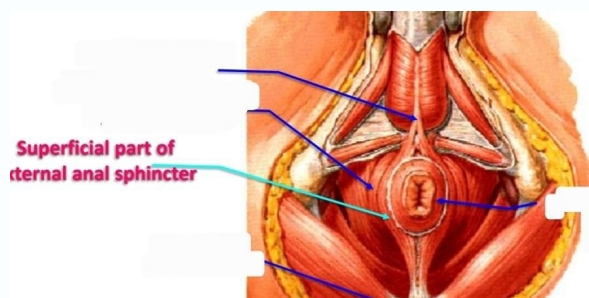
8. What is the following structure?



9. What is the following structure?

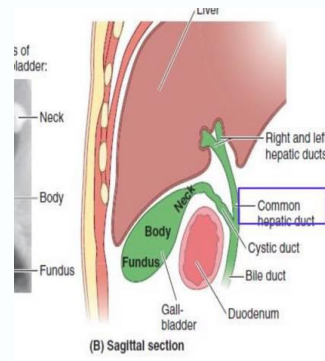


10. What is the following structure?

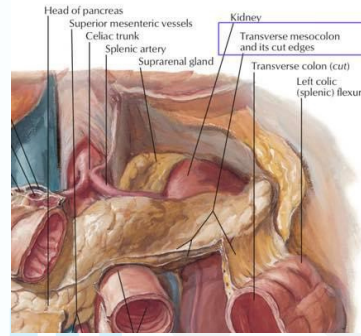


وَإِنْ تَهتَفْتَدَكَّرْ : "فَأَنْكَ بِأَعْيُنِنَا"

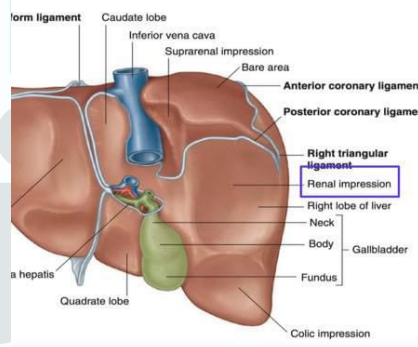
11. What is the following structure?



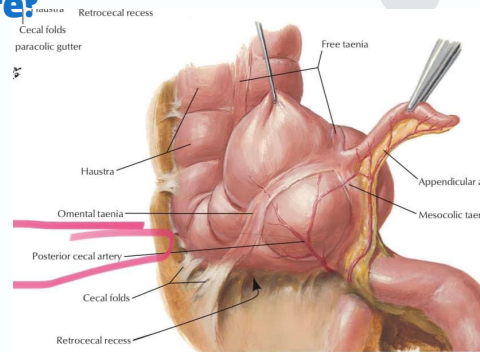
12. What is the following structure?



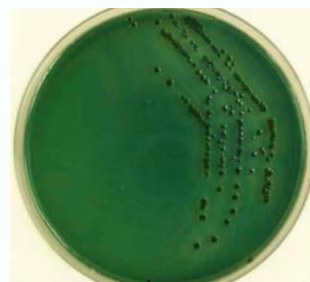
13. What is the following structure?



14. What is the following structure?



15. What is the following structure?

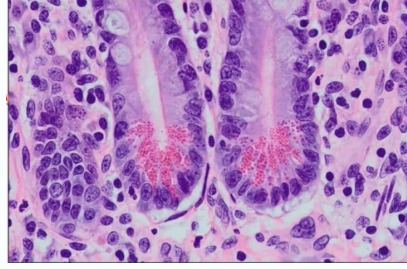


**V. parahemolyticus**

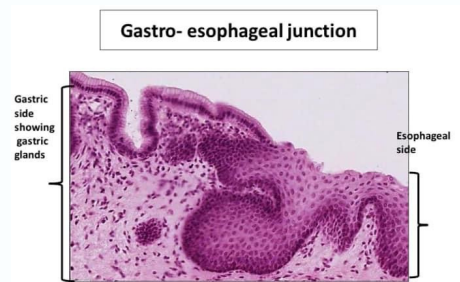وَأِنْ تَهتَفْتَدُكُرْ : "فَأَنْكَ بِأَعْيُنِنَا"

16. What is the type of these cell?

**Paneth cells**

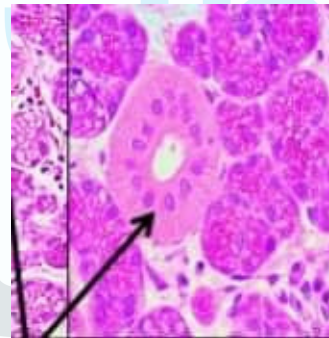


17. What is the following structure?



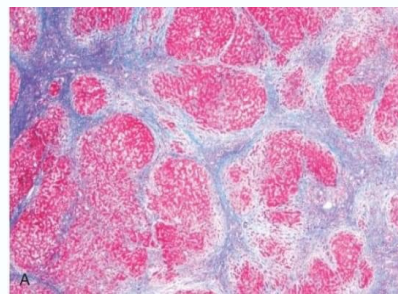
18. What is the type of these gland?

**Parotid salivary gland**



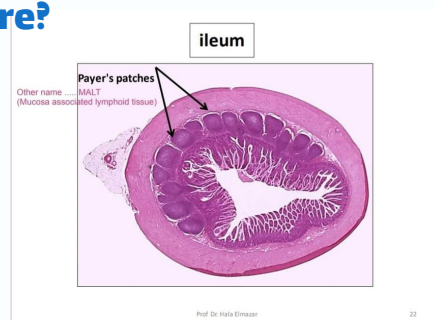
19. The stain is?

**Masson trichrome stain**



20. What is the following structure?

- A. chief cell
- B. kupffer cell
- C. microfold
- D. parietal cell

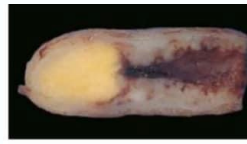

**Answer : c**

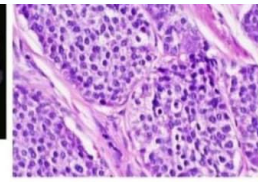
وَإِنْ تَهتَّ فَتَذَكَّرْ : "فَأِنَّكَ بِأَعْيُنِنَا"

21. What is the following cancer?

**Carcinoid tumor**



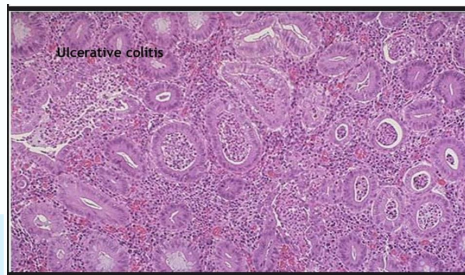
Gross



Microscopic

22. What is the following disease?

**Ulcerative colitis**



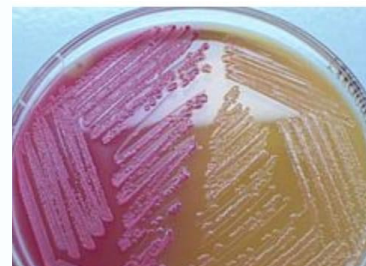23. What is the following mutation?

**SAMAD2**

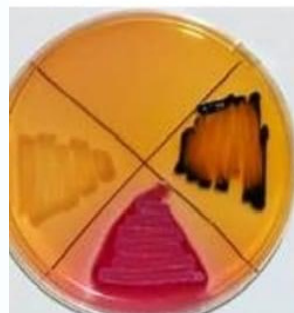


24. What is the following structure?

**MacConkey agar**



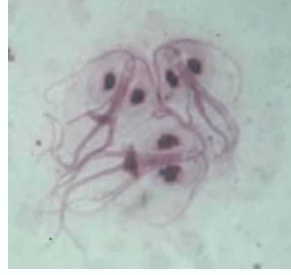25. What is the following structure?



**Salmonella**  
colorless colonies  
with black center

26. What is the following structure?

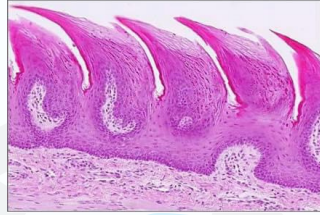
**Giardia lamblia Trophozoite**



27. What is the following structure?

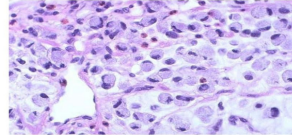
Filiform papillae

thelium : keratinized stratified squamous epithelium, No taste



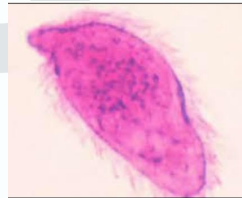
28. What is the following structure?

Diffuse type, signet ring cells



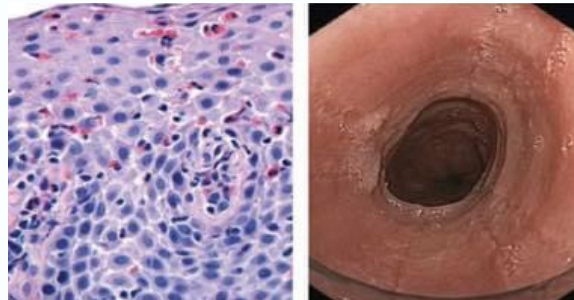
29. What is the following structure?

**Miracidium**



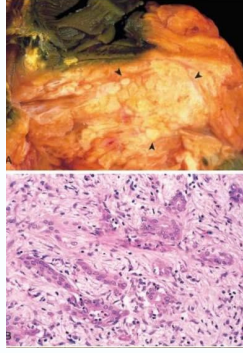
30. What is the following structure?

**Eosinophilic esophagitis**



31. The name of mutation is:

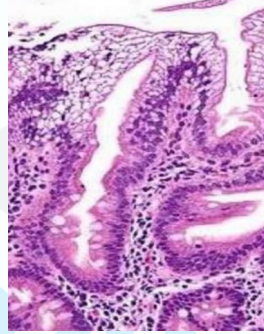
- A. NRAS
- B. KRAS



Answer: b

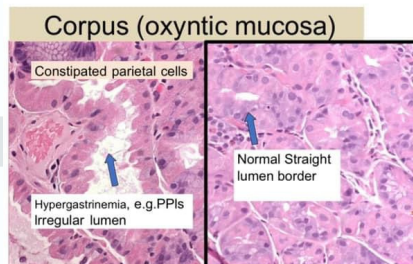
32. The name of disease is:

abetalipoproteinemia.



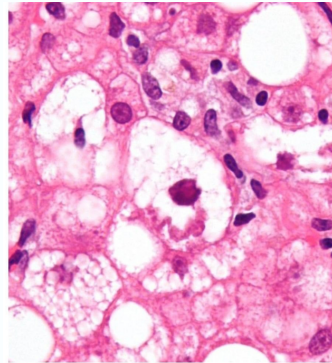
33. What is the cause ?

ppi



34. One of the following is true

ballooning hepatocyte

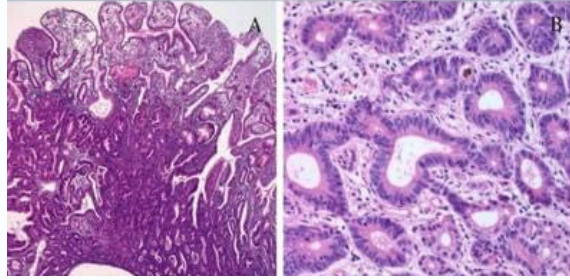


Micrograph showing a Mallory body with the characteristic twisted-rope appearance (centre of image - within a ballooning hepatocyte). H&E stain.



35. One of the following is correct:

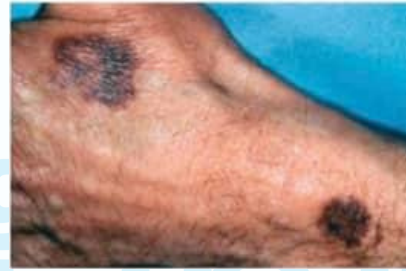- A. Risk of adenocarcinoma related to the size (greatest if > 2cm)-
- B. F:M=3:1



Answer: a

36. One of the following will be increased:

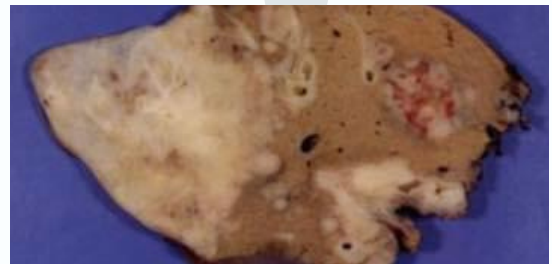- A. IDH
- B. ALT
- C. AST
- D. PT



Answer: d  
not sure

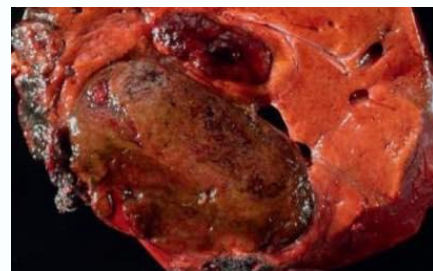37. One of the following is wrong :

- A. infestation by liver flukes
- B. chronic inflammatory disease of the large bile ducts (such as primary sclerosing cholangitis), hepatolithiasis.
- C. fibropolycystic liver disease.
- d. chronic hepatitis



Answer: d

38. What is the following structure?



Hepatocellular adenomass

إذا دخل اليقين قلبَ العبد،  
وتضرَّع إلى الله بالدعوة  
الصادقة؛ عزَّ على الله أن  
يتركه في كُربةٍ آلمته، أو  
حاجةٍ ضايقته!

- الشنقيطي.

