

QUIZ TIME

ARCHIVE

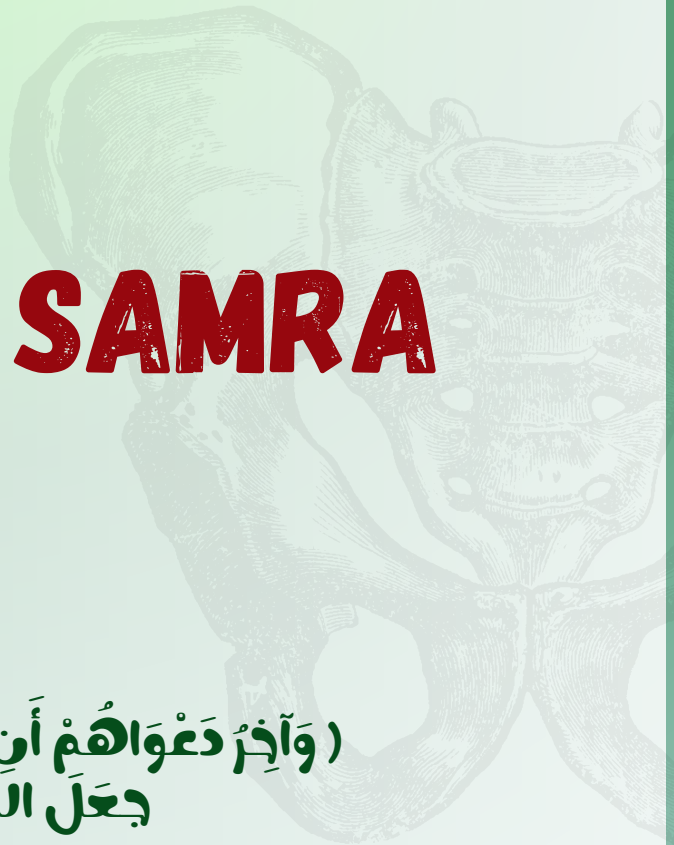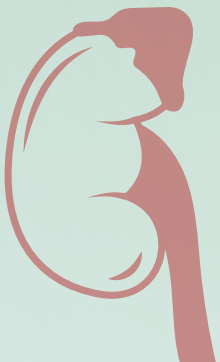Subject:

Anatomy

Done by

AYA ABU SAMRA

♥ (وَآخِرُ دَعْوَاهُمْ أَنِ الْحَمْدُ لِلَّهِ رَبِّ الْعَالَمِينَ)
♥ جَعَلَ اللَّهُ الْخِتَامَ مِسْكَ



Lec 1

1) All the following statements are true EXCEPT : Select one:

- a . The false pelvis forms part of the abdominal cavity
- b . The pelvic outlet is diamond shaped
- c . The bony pelvis is composed by the two hip bones and the sacrum only
- d . The pelvic cavity lies between the inlet and the outlet
- e . The pelvic inlet synonym the pelvic brim

ans: c

2)The pelvic walls . Which is wrong :

- a . The piriformis muscles..... Posterior wall
- b . The obturator membrane Posterior wall .
- c . Levatores ani muscles inferior wall
- d . The pubic rami Anterior wall
- e . The sacrotuberous and sacrospinous ligaments ... Lateral wall

ans: b

Lec 2

1)All the following are posterior relation to the right kidney Except:

- a.The diaphragm
- b.The 11th rib
- c.12th rib
- d.The costodiaphragmatic recess of the pleura
- e. Quadratus lumborum

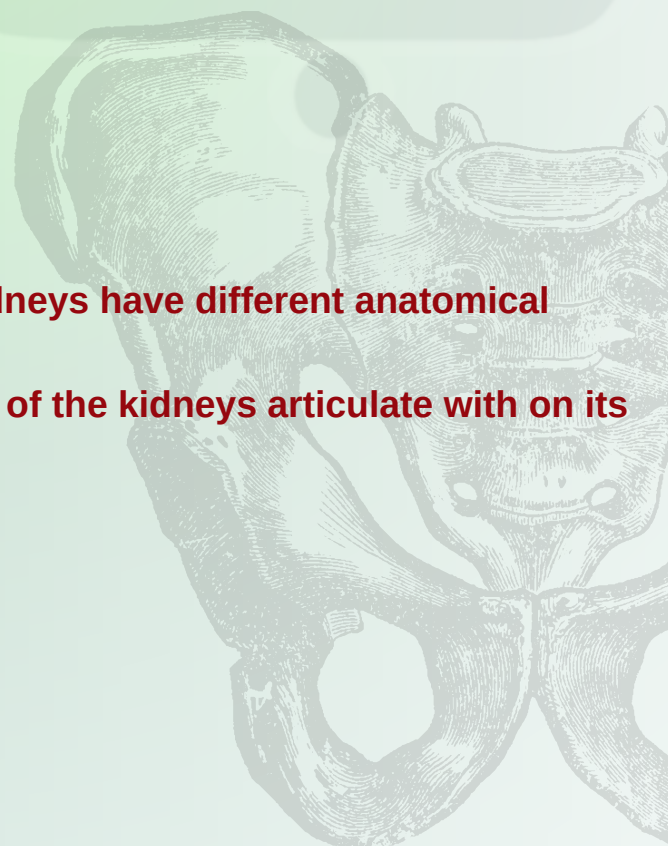

ans:b

2) Due to the asymmetry of the body, the two kidneys have different anatomical relations

Which of the following structures does only one of the kidneys articulate with on its respective : side ? Select one

- a . Diaphragm
- b. Rib 11
- c. Psoas major
- d . Quadratus lumborum
- e . Transversus abdominis

Ans:b



3) One of the following is not true regarding the relations to anterior wall of the left kidney :

- A- coils of small intestine related to lower medial part
- B- body of pancreas to middle part
- C- descending colon to lower medial part
- D- stomach between left suprarenal gland and spleen
- E- spleen related to upper lateral part

Ans : c



Lec 3

1) Regarding the Ureter, one of the following statements is incorrect : Select one :

- a. ureter lies posterior to parietal peritoneum
- b. Crosses bifurcation of aortic artery
- c. lies anterior to sacro -iliac joint.
- d. lies on Lateral wall of pelvis towards ischial spine.
- E. Enter inferior surface of bladder at trigone

Ans : b

2) The muscle of the bladder wall is called :

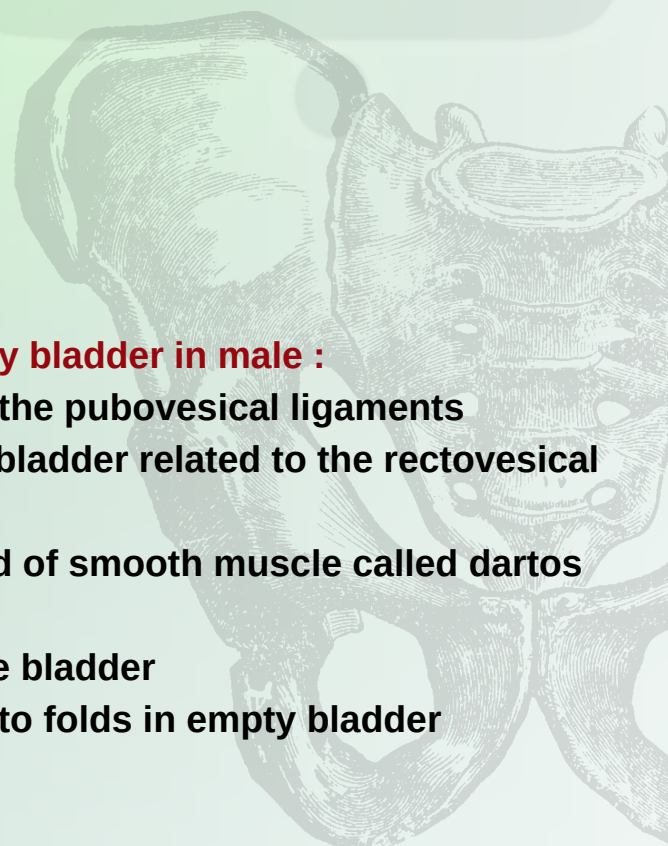
- .a. Detrusor muscle
- b. Dartos
- c. Trigon muscle
- d. Rugae
- e. sphincter muscle

Ans : a

3) Select the true statement regarding the urinary bladder in male :

- a. The neck of the bladder is held in position by the pubovesical ligaments
- b. The lower part of the posterior surface of the bladder related to the rectovesical pouch
- c. The muscular coat of the bladder is composed of smooth muscle called dartos muscle
- d. The sphincter vesicae found in the neck of the bladder
- e . The mucous membrane of trigon is thrown into folds in empty bladder

Ans: d



Lec 4

1) All of the followings are branches of internal pudendal artery except :

- A- Perineal artery
- B- Inferior rectal artery
- C- Middle rectal
- D- Artery of the bulb
- E- Deep artery of the clitoris.

Ans: c

2) All of the following statements are True related to the urethra of a male except : Select one :

- a . The prostatic urethra It is about 1.25 inches long .
- b. The membranous urethra is about 1.25 cm long.
- c . . The external meatus is the widest part of the entire urethra .
- d. The part of the urethra that lies within the glans penis is dilated to form the fossa terminalis.
- e. It is approximately 20 cm long in an adult .

Ans : c

2) Regarding the female urethra, the following statements are INCORRECT, EXCEPT :

- a. Is about 1.5 cm long
- .b. It extends from the neck of the bladder to the external meatus
- .c. It opens into the vestibule about 1cm below the clitoris
- .d. It lies immediately dorsal to the vagina
- .e. The ducts of the paraurethral glands at the sides of the neck of bladder

Ans: b

Lec 5

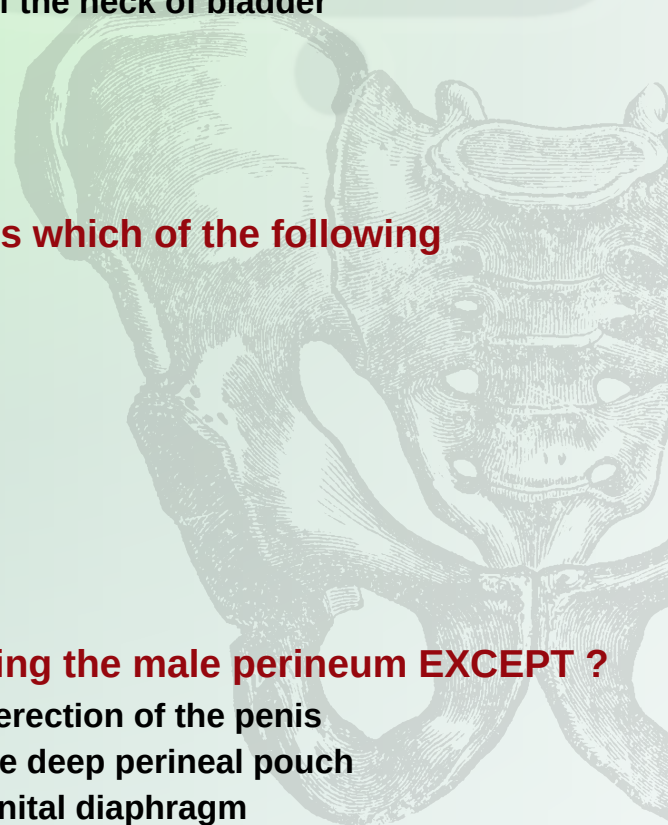
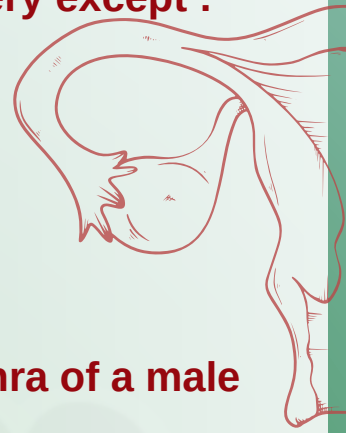1) The Male superficial perineal pouch contains which of the following structures ?

- a . Prostate
- b . Bulbourethral glands
- c . Membranous urethra
- d . Ischiocavernosus muscle
- e . Deep transverse perineal muscles

ans: d

2) All the following statements are true regarding the male perineum EXCEPT ?

- a . Ischiocavernosus muscle assist in the process of erection of the penis
- b . Sphincter urethrae muscle surrounds urethra in the deep perineal pouch
- c . The bulb of penis situated in the midline the urogenital diaphragm




- d. The corpora cavernosa are supplied by the dorsal artery of the penis
- e. The skin of the penis is drained into the superficial inguinal

ans: d

The Deep Perineal pouch in the Male Contain the following Except :

- a . Muscle by which micturition involuntarily stopped
- b . Bulbourethral Glands
- c- Deep Transverse Perineal Muscles
- d . Intemai Pudendal Artery
- e . Dorsal Nerve of the Penis

Ans : a



Lec 6

1) Select the false statement regarding the Vulva :

- a . Drained to Medial group of superficial inguinal nodes
- b . Mons Pubis hair - bearing elevation of skin found anterior to the pubis
- c . Labia Minora hair - bearing folds of soft skin
- d . Vestibule bounded laterally by the labia minora with the clitoris at its apex
- e. The glans of the clitoris is partly hidden by the prepuce

ans: c

2) Which one is true regarding the Vulva ? Select one

- a . The anterior ends of labia minora form the clitoris
- b . Orifices of the greater vestibular glands opens on each sides of urethra
- c . The vestibule is bounded laterally by the labia majora
- d . The clitoris is an erectile tissue of bulbus spongiosus
- e . The labia majora is covered by skin

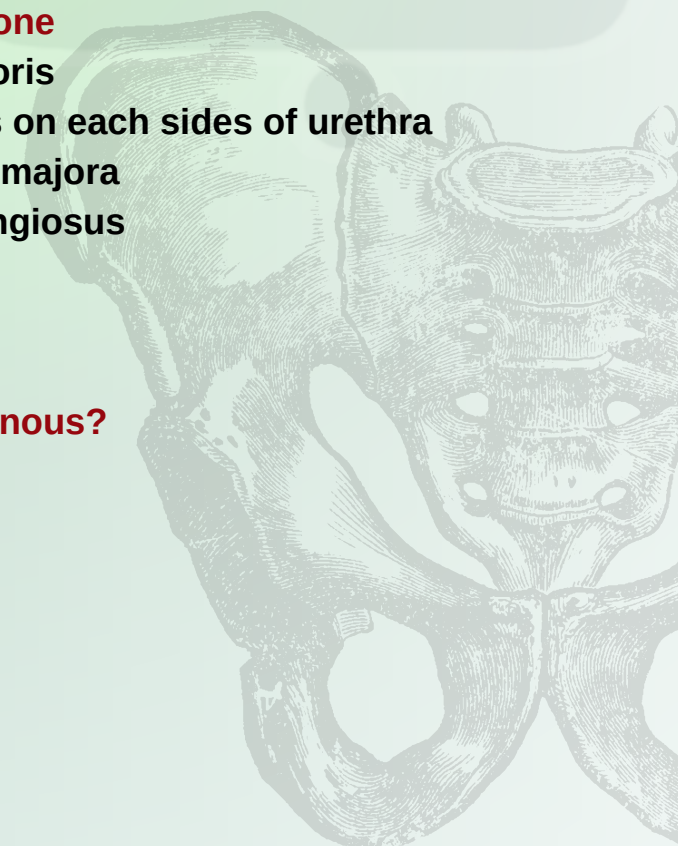
ans: e

5- Which is the artery that supplies corpora cavernous?

Select one:

- A- Dorsal artery of the penis
- B- Radial artery
- C- Vaginal artery
- D- Deep artery of the penis
- E- Basilar artery

Ans:d



Lec 7

1) What is the posterior relation for the prostate? Select one:

- A. Fascia of Denonvi
- B- Kidney
- C- Urinary bladder
- D- Aorta
- E- Uterus

Ans:a

2) Which part of male reproductive system secretes most of seminal fluid? Select one:

- A. Prostate
- B- Penis
- C- Seminal vesicle
- D- Epididymis
- E- Paraididymis

Ans:c

3) Which of the following the palpated part of prostate during rectal examination? Select one:

- A- Membranous urethra
- B- Lateral lobe
- C- Inferior lobe
- D- Anterior lobe
- E- Posterior lobe

Ans:e

4) Which of the followings are incorrect regarding layers of the scrotum ? Select one

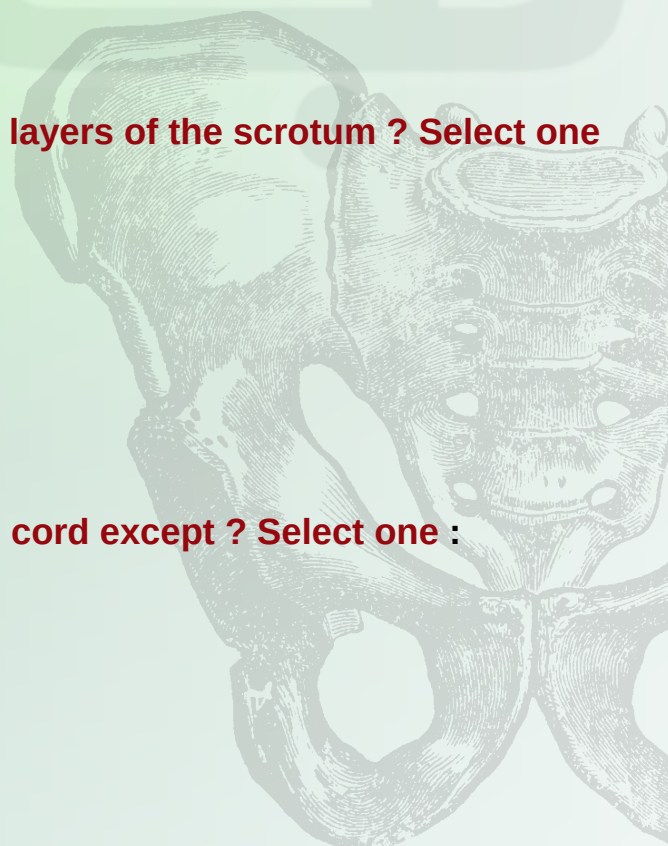
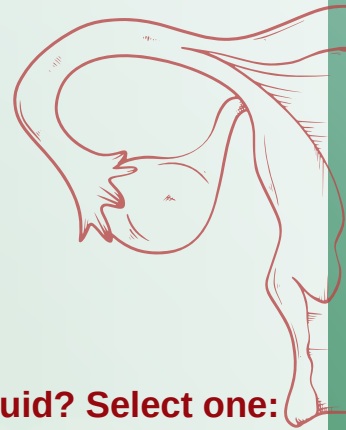
- a . External spermatic fascia
- b . Cremasteric muscle .
- C. Superficial fatty layer
- d. Internal spermatic fascia
- e. Involuntary dartos muscle

ans: c

5) All of the followings are covering the spermatic cord except ? Select one :

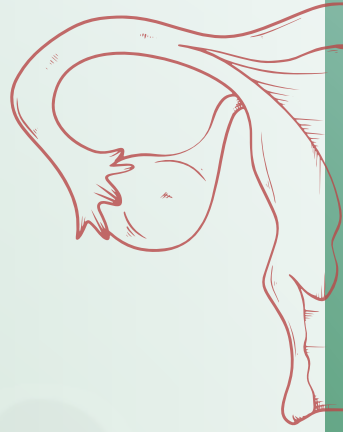
- a . Cremasteric muscle
- b . Internal spermatic fascia
- c . External spermatic fascia
- d . Dartos muscle
- e . Cremasteric fascia

ans ; d



Lec 7

اسئلة من مصادر خارجية



1)The ejaculatory duct formed by union of vas deferens and which of the following?

- A.Vasa efferentia
- B.Duct of seminal vesicle
- C.Prostatic glands
- D.Prostatic urethra

Ans :b

2)Which of the following is not a component of the spermatic cord?

- A.Pampiniform plexus
- B.Vas deferens
- C.Testicular artery
- D.Ilioinguinal nerve

Ans: d

3)Concerning the vas deferens, all are true EXCEPT:

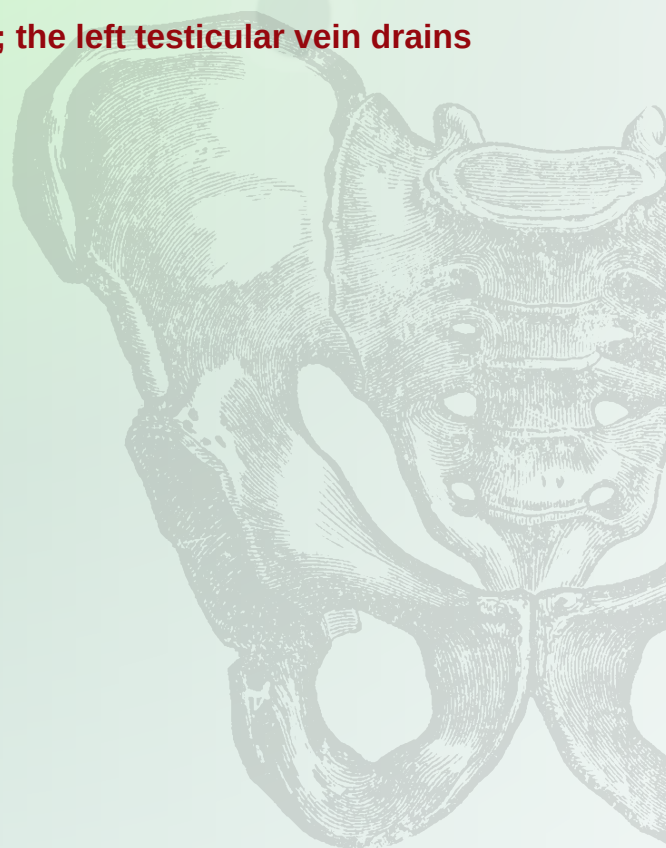- A.It lies medial to the epididymis.
- B.It lies lateral to the seminal vesicle.
- C.It is about 45 cm long.
- D.It has a retroperitoneal course.

Ans: b


4)A patient was examined with a left-sided varicocele; the left testicular vein drains into which of the following?

- a. Left renal vein
- B.Left internal iliac vein
- C.Left external iliac vein
- D.Inferior v ena cava

Ans: a



Lec 8



1) The normal anatomical position of the uterus?

- a . Anteverted anteflexed
- b . Anteverted
- c . Retroverted retroflexed
- d . Anteverted anteflexed
- e . Anteverted

ans: d

2) All of the following are contents of the broad ligament of the uterus except ?

- a . Fallopian tube
- b . Paroophoron
- c . Ligament of the ovary
- d . Uterine vessels
- e . Rectovaginal fold

ans : e

Lec 9

1) Gartner's cyst in vaginal wall is developed from?

- a. Cranial part of the uterovaginal canal
- b. Metanephric duct
- c. Definitive urogenital sinus
- d. Mesonephric duct
- e. Caudal part of the uterovaginal canal

ans: d

2) An the following statements are true regarding the ovary EXCEPT ? Select one :

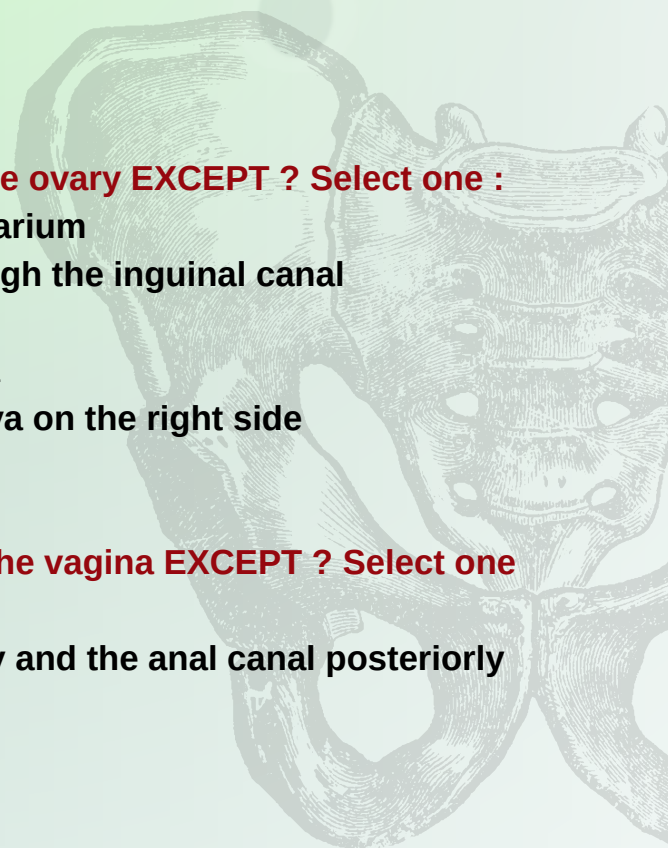
- a. It is attached to the broad ligament by the mesovarium
- b. The suspensory ligament of the ovary pass through the inguinal canal
- c . It is primary female genital organs
- d . Its blood supply arises from the abdominal aorta
- e . The ovarian vein drains into the inferior vena cava on the right side

ans: b

3) All the following statements are true concerning the vagina EXCEPT ? Select one

- a. The cervix of the uterus pierces its posterior wall
- b . The lower half lies between the urethra anteriorly and the anal canal posteriorly
- c . It is directed upward and backward
- d . Its upper part is related to ureter
- e . Its posterior wall is longer than anterior wall

ans: a



Lec 10

1) All of the followings are branches of internal pudendal artery except? (ارثيف)

Select one:

- A- Perineal artery
- B- Inferior rectal artery
- C- Middle rectal
- D- Artery of the bulb
- E- Deep artery of the clitoris.

Ans: c

(اسئلة من مصادر خارجية)

2) Which of the following arteries do not enter the lesser pelvis ?

- A- ovarian arteries
- B- median sacral arteries
- C- testicular arteries
- D- superior rectal arteries
- E- internal iliac

Ans: c

C

3) Internal iliac arteries begin at the level of the IV disc:

- A- L2-L3
- B- L 4
- C- S1-S2
- D- L5-S1
- E- L5-S3

Ans: D

4) Select the WRONG regarding INTERNAL ILIAC ARTERY branches:

- A- superior gluteal artery from posterior dev
- B- the iliolumbar artery from posterior division
- C - inferior gluteal artery from posterior division
- D- middle rectal artery from anterior division
- E- Obturator artery from anterior division

Ans: c

فِي الْقَلْبِ شَعَثٌ، لَا يَلْمُهُ إِلَّا الْإِمْبَالُ عَلَى اللَّهِ.

وَفِيهِ وَخْشَةٌ، لَا يُزِيلُهَا إِلَّا الْأَنْسُ بِهِ فِي خَلْوَتِهِ.

وَفِيهِ حَزْنٌ لَا يُذْهِبُهُ إِلَّا الشَّرُّورُ بِمَعْرِفَتِهِ وَصِدْقِ مُعَامَلَتِهِ.

وَفِيهِ قَلْقٌ لَا يُسْكِنُهُ إِلَّا الْاجْتِمَاعُ عَلَيْهِ، وَالْفِرَارُ مِنْهُ إِلَيْهِ.

وَفِيهِ نِيرَانٌ حَسْرَاتٍ: لَا يُطْفِئُهَا إِلَّا الرِّضَا بِأَمْرِهِ وَتَنْهِيهِ وَقَضَائِهِ، وَمُعَانَقَةُ الصَّبْرِ عَلَى ذَلِكَ إِلَى وَصْفِ لِقَائِهِ.

وَفِيهِ طَلَبٌ شَدِيدٌ: لَا يَقِفُ دُونَ أَنْ يَكُونَ هُوَ وَخَدَهُ مَطْلُوبَهُ.

وَفِيهِ فِاقَةٌ: لَا يَسُدُّهَا إِلَّا مَحَبَّتُهُ، وَالْإِنَابَةُ إِلَيْهِ، وَدَوَامُ ذِكْرِهِ، وَصِدْقُ الْإِحْلَاصِ لَهُ. وَلَوْ أُعْطِيَ الدُّنْيَا وَمَا فِيهَا لَمْ

تَسُدَّ تِلْكَ الْفِاقَةَ مِنْهُ أَبَدًا

ابن القيم رحمه الله -

