

QUIZ TIME

ARCHIVE

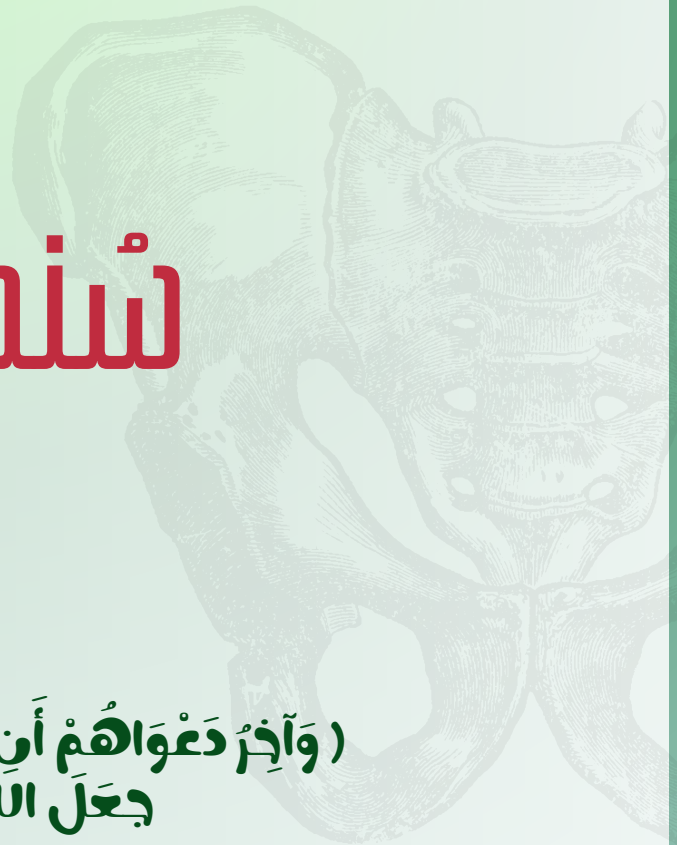
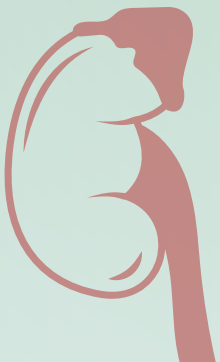Subject:

Biochem

Done by:

سندس ذياب

♥ (وَآخِرُ دَعْوَاهُمْ أَنِ الْحَمْدُ لِلَّهِ رَبِّ الْعَالَمِينَ)
♥ جَعَلَ اللَّهُ الْخِتَامَ مِسْكَ



1. Within 12 hours of an irreversible hypoxic-ischemic insult, this cell body shrinks, the nucleus is pyknotic, the nucleolus disappears, the cytoplasm shows intense eosinophilia and Nissl substance is lost. What is this cell type most likely to be?

- a- Astrocyte
- b- Endothelial cell
- c- Neuron
- d- Microglia
- e- Oligodendroglia

ans: c

2. Activated after injury for scar and repair, this cell undergoes both hypertrophy and hyperplasia, where the nucleus enlarges and the nucleolus becomes prominent. The cytoplasm expands with bright pink hue extending multiple processes. What is this cell type most likely to be?

- a- Astrocyte
- b- Endothelial
- c - Neuron
- d. Microglia
- e- Oligodendroglia

ans: a

3. One of the following diseases is associated with early onset in trisomy 21 individuals)Down syndrome(?

- a- Amyotrophic Lateral Sclerosis
- b- Parkinson Disease
- c- Wernicke encephalopathy
- d- Huntington Disease
- e- Alzheimer Disease

ans: e

4. the Wrong statement about alzheimer's disease :

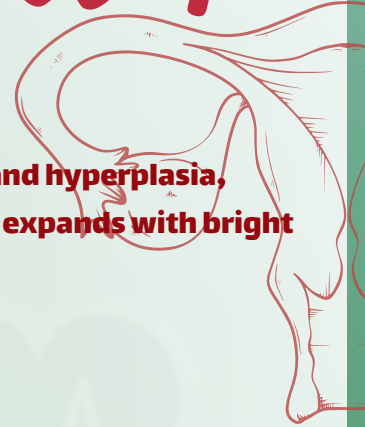- a. death due to infection
- b. altered mood and behavior.
- c. Macro: cortical atrophy
- d. intracellular amyloid and extracellular tau المفروض العكس عشان تكون صح بس مش مفصل بحاضرة الدكتور
- e. in early life associated with Down syndrome

5. A 69 year old female referred to the specialty memory clinic from neurology with a 2-year history memory loss, and executive function loss. Word finding and reading/writing skills were noted to have deteriorated in the preceding 6 months according to her husband. She also stopped driving her car about 6 months. Magnetic resonance imaging scan revealed mild generalized cortical atrophy. Which of the following mechanisms is most likely responsible for her disease:

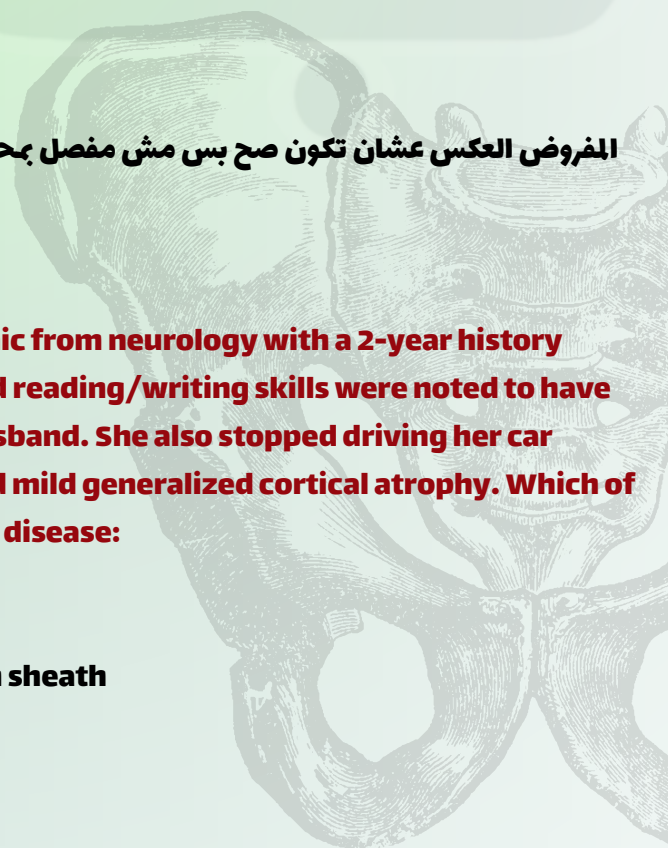
- a- Aggregation of Huntington
- b- Aggregation of Amyloid beta (AB) peptide
- c- Autoimmune response against components of the myelin sheath
- d- Loss of upper motor neurons in the cerebral cortex
- e- Dopaminergic neurons degeneration

ans: b

Lec 1



الطبيب الجراح
الدكتور



1) If a case of emphysema was hospitalized showing drop in blood PH and increase in CO₂. This is a condition of? Select one:

- a) Metabolic alkalosis
- b) Respiratory alkalosis
- c) Metabolic acidosis
- d) Respiratory acidosis
- e) Compensated respiratory alkalosis

ANS: D

If a patient undergoing a prolonged surgery and have repeated blood transfusion during and after surgery, which condition will he have if you know that the transfused blood contain citrate? Select one

- a) Compensated respiratory alkalosis
- b) Metabolic alkalosis
- c) Respiratory alkalosis
- D) Respiratory acidosis
- E) Metabolic acidosis

ANS: B

In sever acidosis, the kidneys? Select one 3

- A) Excrete bicarbonate
- B) Forms ammonia
- C) Prevent excretion of keto-acids
- D) Reabsorb
- E) Inhibits excretion of titratable acids

ANS: B

:Metabolic acidosis is caused by all of the following, Except? Select one :

- A) Breath holding
- B) Diabetic keto-acidosis
- C) Heavy exercise
- D) Cardiac arrest
- E) Renal failure

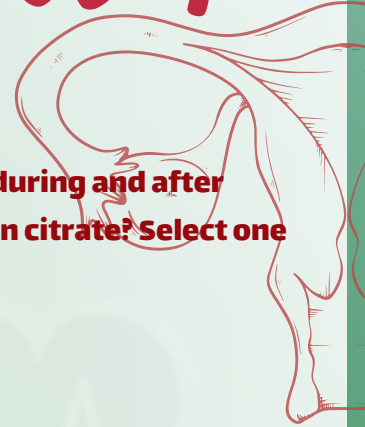
ANS: A

The kidneys keep acid base balance via doing all of the following except? Select one

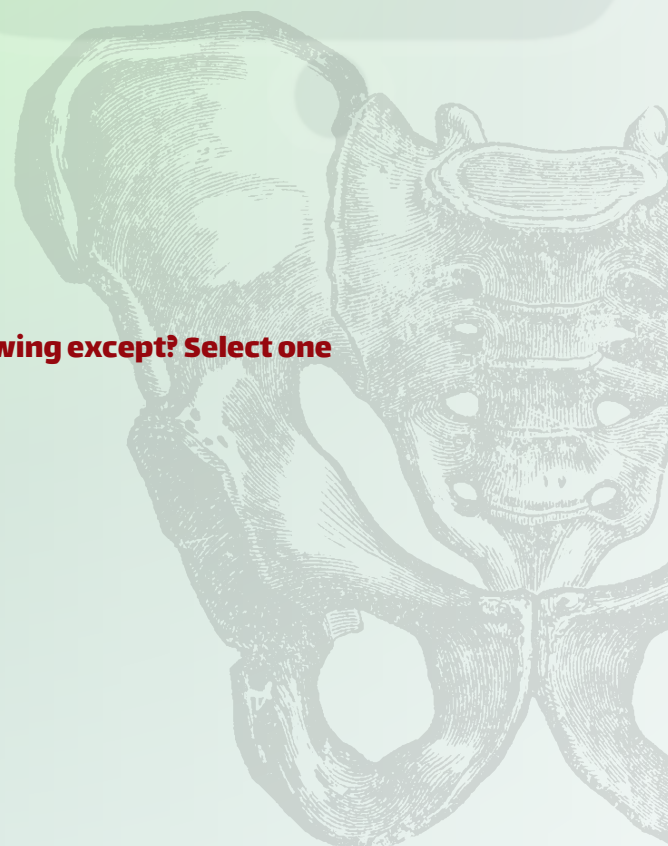- A) Excretion of non-volatile acids
- B) Formation of ammonia
- C) Bicarbonate re-absorption
- D) Release of erythropoietin
- E) Formation of acid phosphate in renal tubules

ANS: D

Lec 1



المطب والجراف
للطب والعلوم



A man came to hospital with releasing his stomach contents with PH= 7.55, PCO₂= 52, HCO₃⁻= 40 what :does he most likely has?Select one

- A)Metabolic alkalosis
- B)Metabolic acidosis
- C)Respiratory alkalosis
- D)Respiratory acidosis
- E)None of the following

Ans: A

:Which of the following crystals found in acidic urine Select on

- A)Calcium phosphate
- B) Amorphous phosphate
- C)Triple phosphate
- D)Calcium oxalate
- E)None of the following

Ans: D

?whatDiabetes mellitus is associated with

:Select one

- A- Decrease urine volume, increase urine specific gravity
- B- Increase urine volume, increase urine specific gravity
- C- Increase urine volume, decrease urine specific gravity
- D- Decrease urine volume, decrease urine specific gravity
- E- Nothing

Ans:B

Which of the following crystals found in acidic urine?

Select one:

- A- Calcium phosphate
- B- Amorphous phosphate
- C- Triple phosphate
- D- Calcium oxalate
- E- None of the following


Ans:D

The atoms of purine ring are derived from different precursors in the pathway of de novo synthesis. Which of the following is not of theses precursors? Select one:

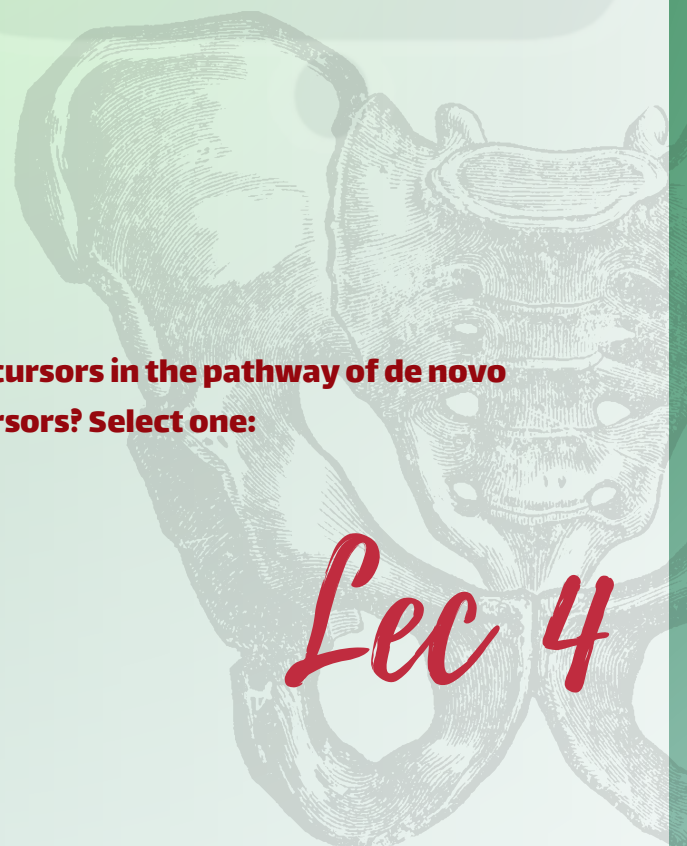
- a. CO₂
- b. Glutamine
- c. Aspartate
- d. Arginine
- e. Glycine

ANS:D

Lec 1



Lec 3



Lec 4