



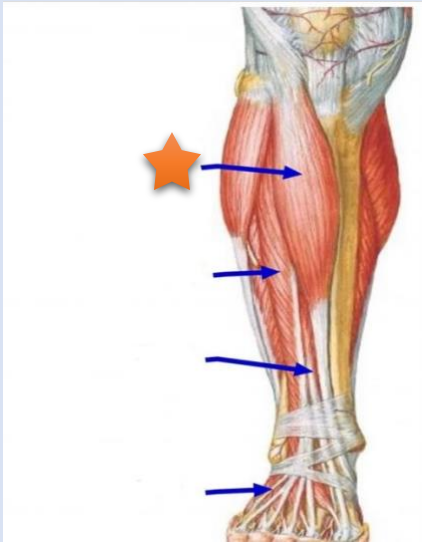
الطب والجراحة لبننة



Anatomy lab – final exam

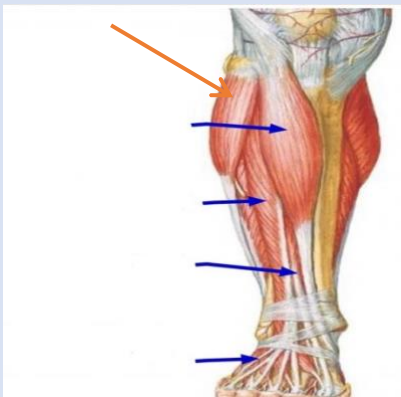
دفعه رَوح 2021

Q1- The structure with star is



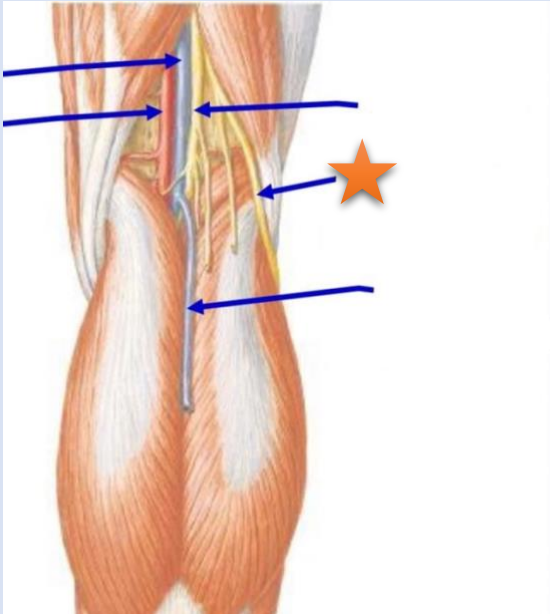
- A- *Tibialis anterior*
- B- *Gastrocnemius muscle*
- C- *Soleus muscle*
- D- *Extensor digitorum longus*
- E- *Extensor hallucis longus*

Q2- What is the labelled structure?



- A- *Tibialis anterior*
- B- *Gastrocnemius*
- C- *Soleus*
- D- *Peroneus longus*
- E- *Extensor hallucis longus*

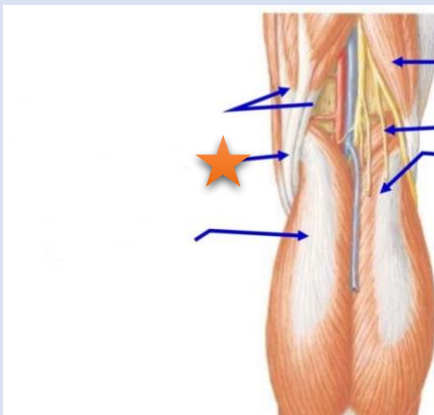Q3- The structure with star is:



A- Common fibular nerve

B- Tibial nerve

Q4- The structure with star is:



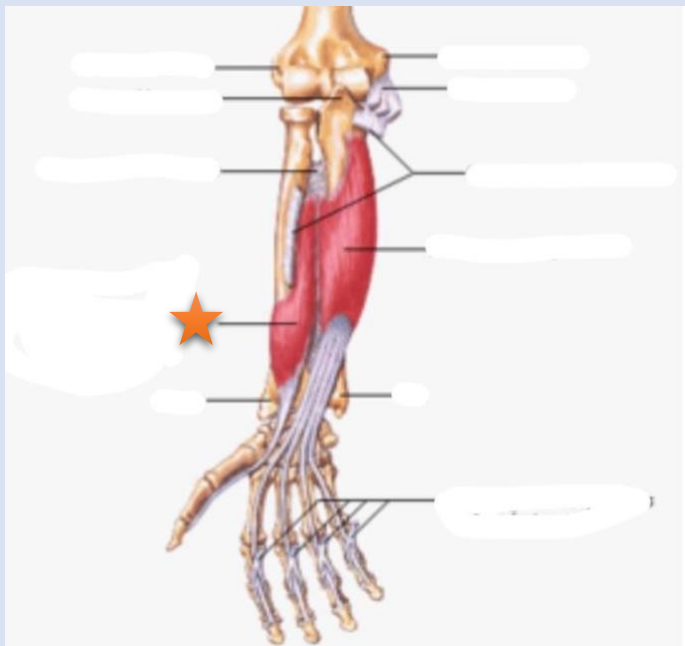
A- Gracilis

B- Sartorius

C- Semitendinosus

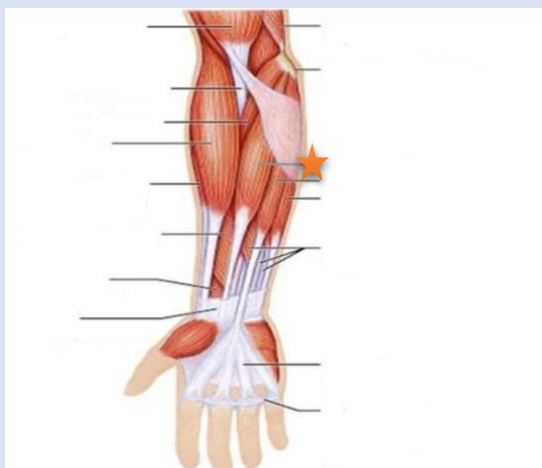
D- Semimembranosus

Q5- The structure with star is:



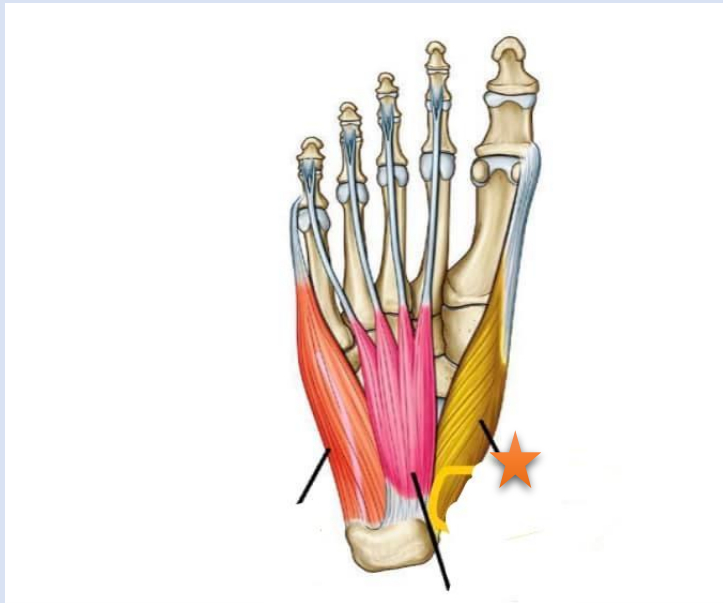
- A- Flexor pollicis longus**
- B- Flexor digitorum profundus**
- C- Flexor digitorum superficialis**

Q6- The structure with star is:



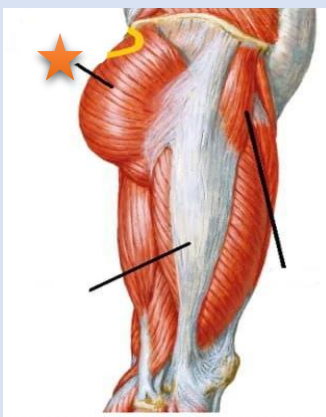
- A- Extensor digiti minimi**
- B- Extensor digitorum**
- C- Anconeus**
- D- Extensor carpi radialis brevis**

Q7- The structure with star is:



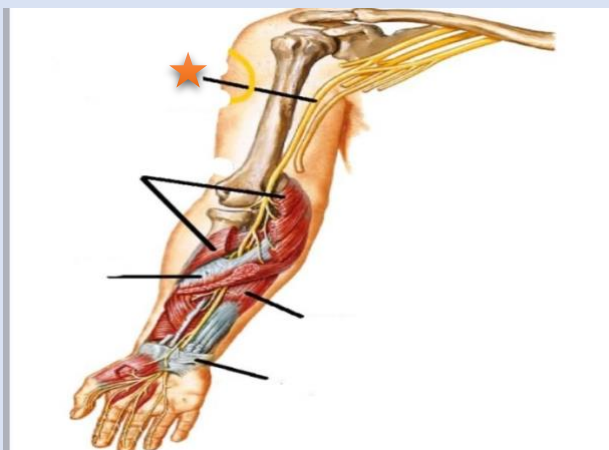
- A- Lumbrical muscle**
- B- Flexor hallucis longus**
- C- Abductor hallucis**
- D- Flexor digitorum brevis**

Q8- The structure with star is:



- A- Gluteus maximus**
- B- Vastus lateralis**
- C- Rectus femoris**
- D- Sartorius**
- E- plantaris**

Q9- The structure with star is:



A- Median nerve

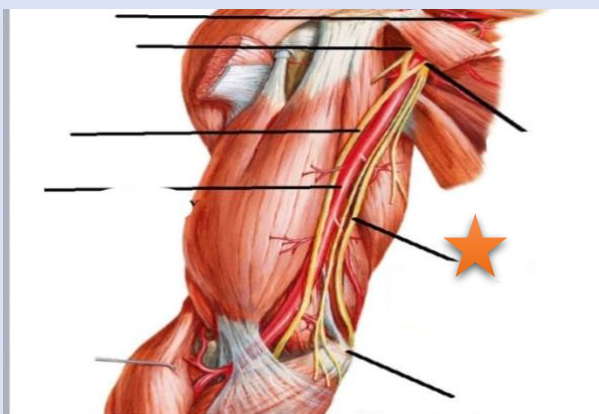
B- Ulnar nerve

C- Medial pectoral nerve

D- Lateral pectoral nerve

E- Radial nerve

Q10- The structure with star is:

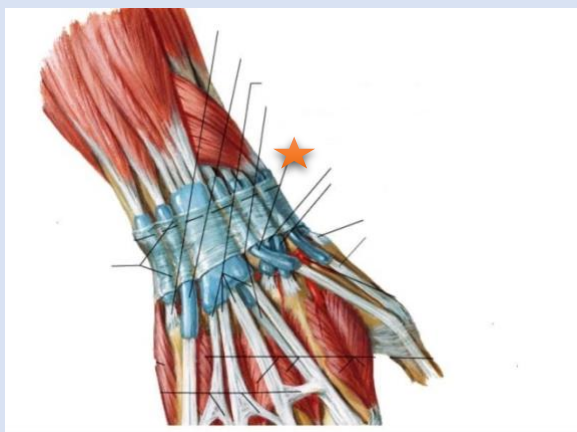


A- Radial nerve

B- Ulnar nerve

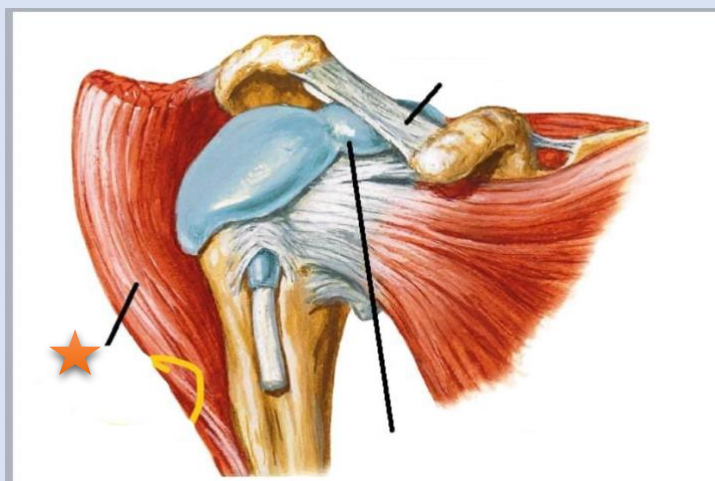
C- Median nerve

Q11- The structure with star is:



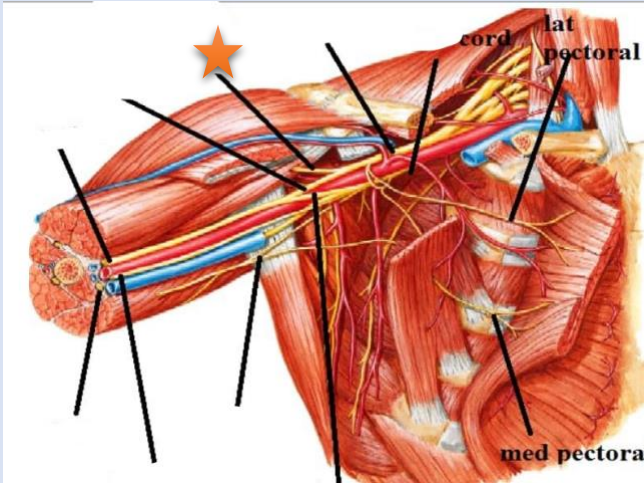
- A- Extensor pollicis longus**
- B- Extensor carpi radialis brevis**
- C- Extensor carpi radialis longus**
- D- Abductor pollicis longus**
- E- Extensor pollicis brevis**

Q12- The structure with star is:



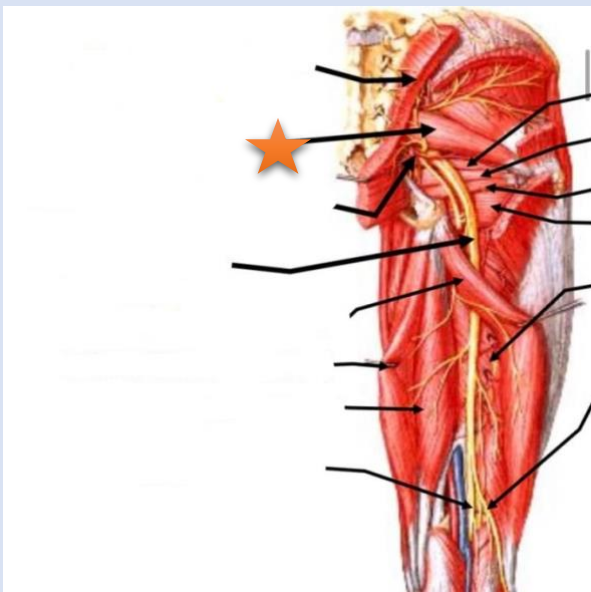
- A- Deltoid muscle**
- B- Supraspinatus**
- C- Subscapularis**
- D- Trapezius**
- E- Teres major**

Q13- The structure with star is:



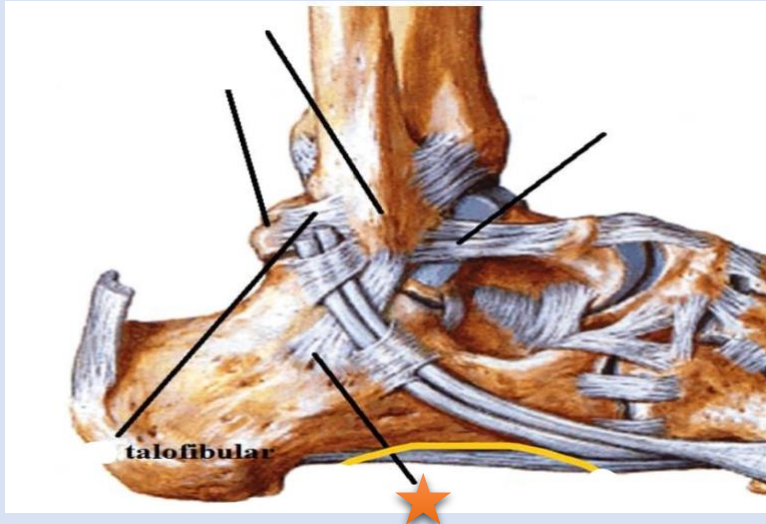
- A- Ulnar nerve**
- B- Median nerve**
- C- Musculocutaneous nerve**
- D- Radial nerve Medial pectoral nerve**

Q14- The structure with star is:



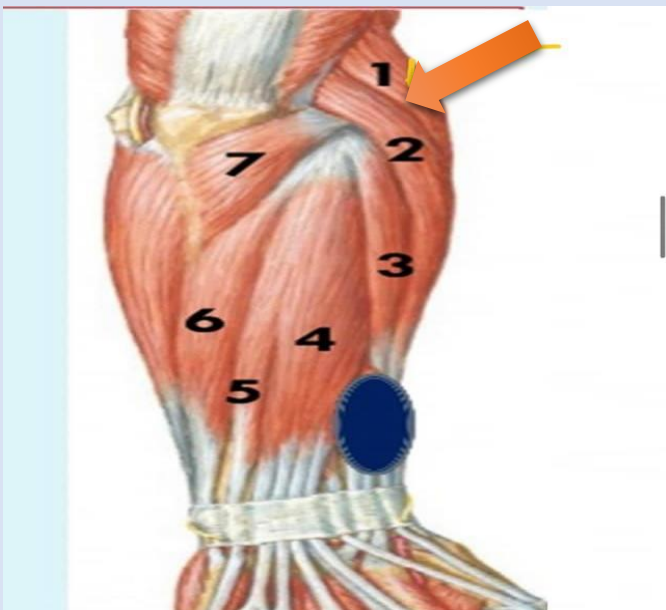
- A- Piriformis**
- B- Gluteus medius muscle**
- C- Inferior gemellus muscle**
- D- Superior gemellus muscle**
- E- Obturator internus**

Q15- The structure with star is:



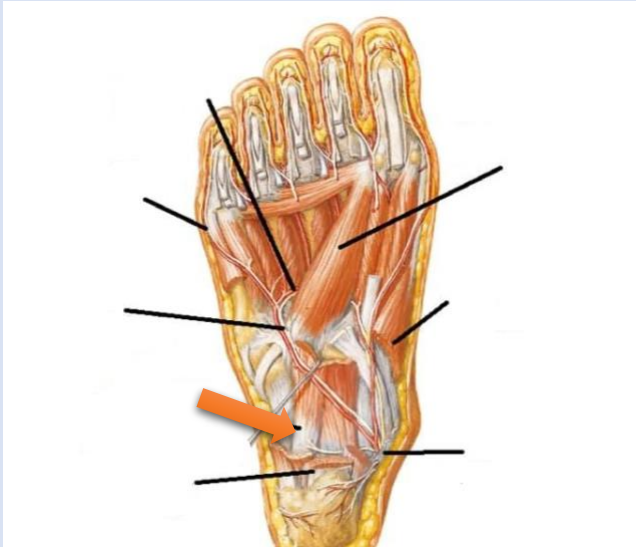
- A- Calcaneofibular ligament**
- B- Anterior talofibular ligament**
- C- Posterior talofibular ligament**
- D- Dorsal calcaneocuboid ligament**
- E- Long plantar ligament**

Q16- What is the labelled structure?



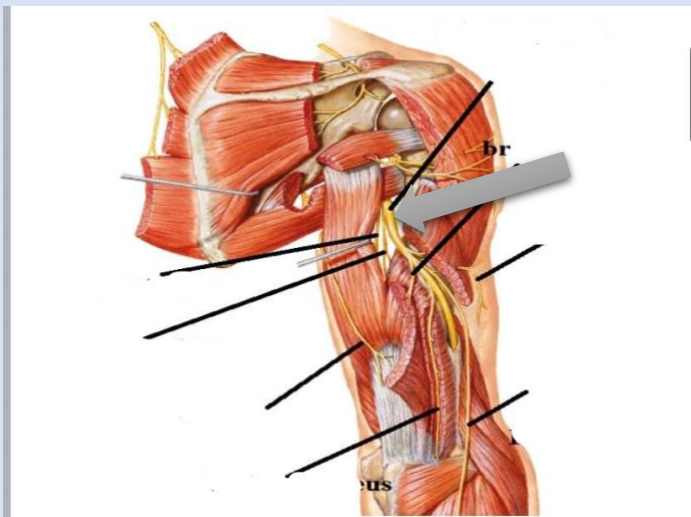
- A- Extensor digitorum muscle**
- B- Extensor digit minimi muscle**
- C- Abductor pollicis longus**
- D- Brachioradialis muscle**
- E- Anconeus**

Q17- What is the labelled structure?



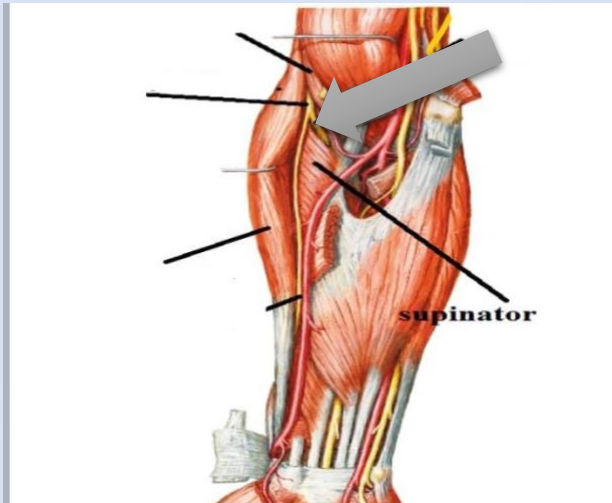
- A- Flexor digitorum accessorius**
- B- Flexor hallucis longus**
- C- Abductor hallucis muscle**
- D- Flexor digitorum brevis muscle**
- E- Flexor digiti minimi brevis muscle**

Q18- What is the labelled structure?



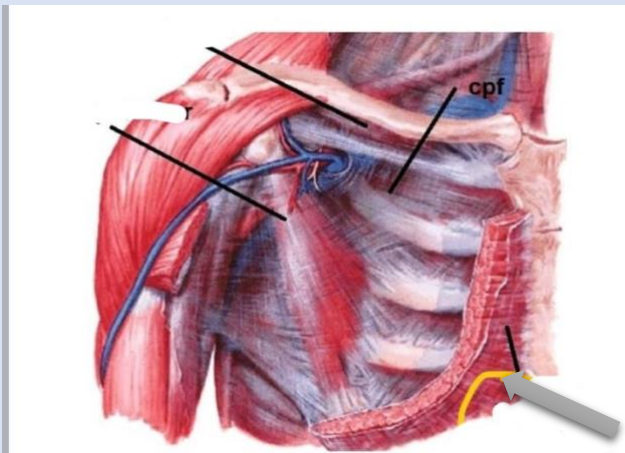
- A- Radial nerve**
- B- Median nerve**
- C- Ulnar nerve**
- D- Musculocutaneous nerve**
- E- Lateral pectoral nerve**

Q19- What is the labelled structure?



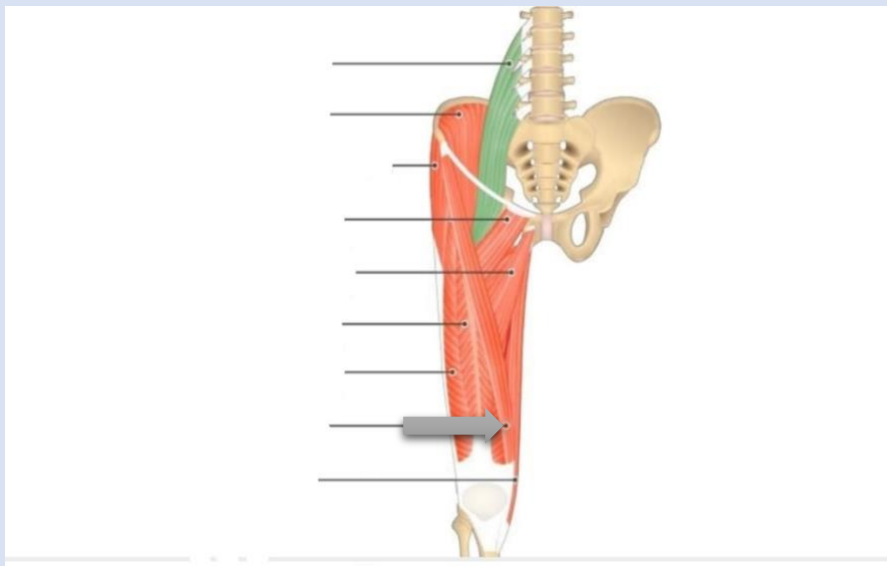
- A- Posterior interosseous nerve**
- B- Median nerve**
- C- Ulnar nerve**

Q20- What is the labelled structure?



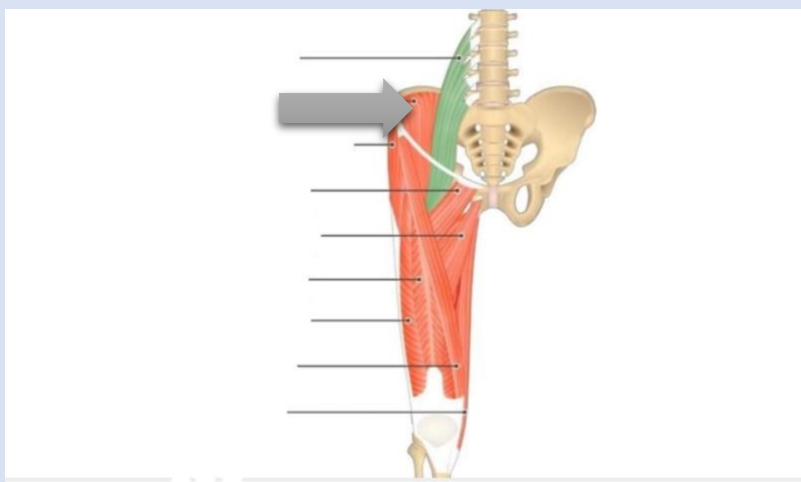
- A- Pectoralis major**
- B- Pectoralis minor**
- C- Serratus anterior**
- D- Latissimus dorsi**
- E- Trapezius muscle**

Q21- What is the labelled structure?



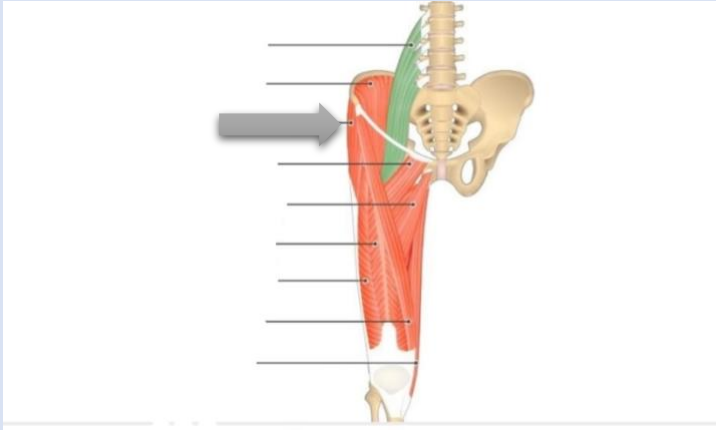
- A- Rectus femoris**
- B- Pectineus muscle**
- C- Psoas major**
- D- Iliacus muscle**
- E- Sartorius**

Q22- What is the labelled structure?



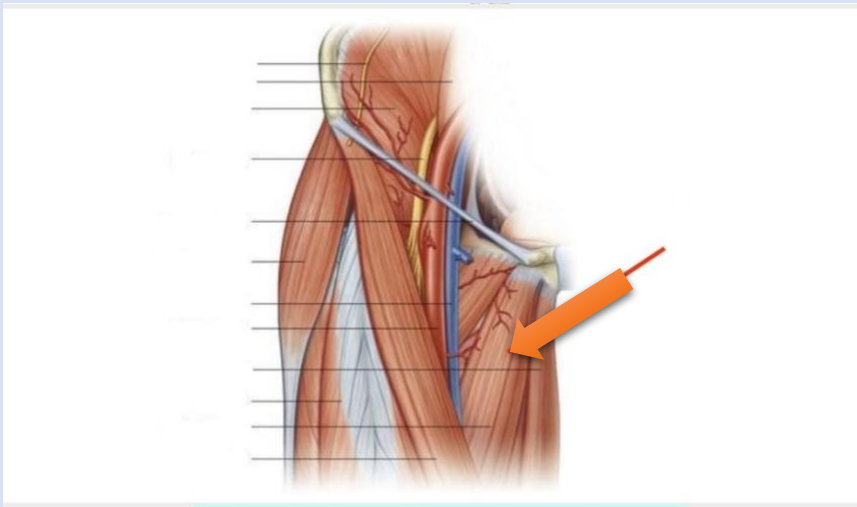
- A- Rectus femoris**
- B- Pectineus muscle**
- C- Psoas major**
- D- Iliacus muscle**
- E- Sartorius**

Q23- What is the labelled structure?



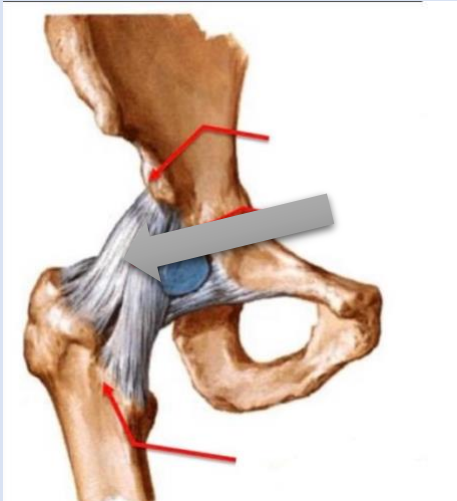
- A- Tensor fascia lata**
- B- Pectineus muscle**
- C- Psoas major**
- D- Iliacus muscle**
- E- Sartorius**

Q24- - What is the labelled structure?



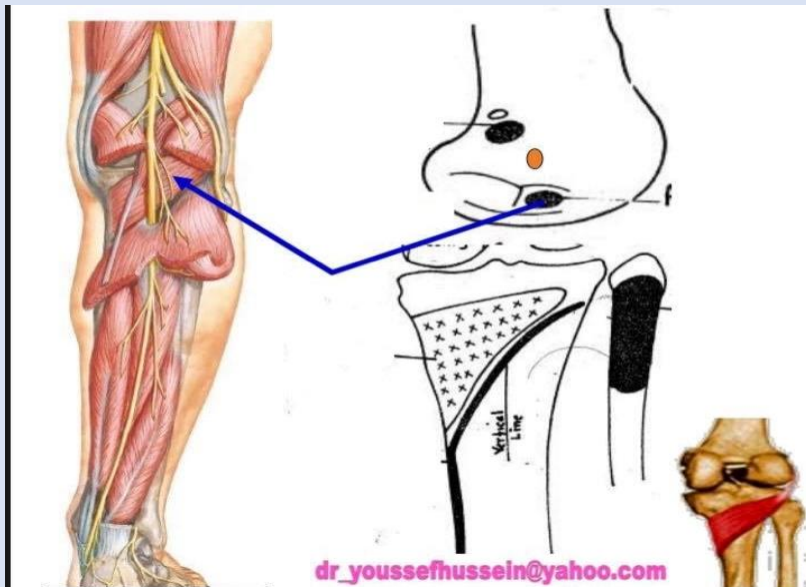
- A- Vastus lateralis**
- B- Vastus medialis**
- C- Pectineus**
- D- Adductor longus**
- E- Sartorius**

Q25 - What is the labelled structure?



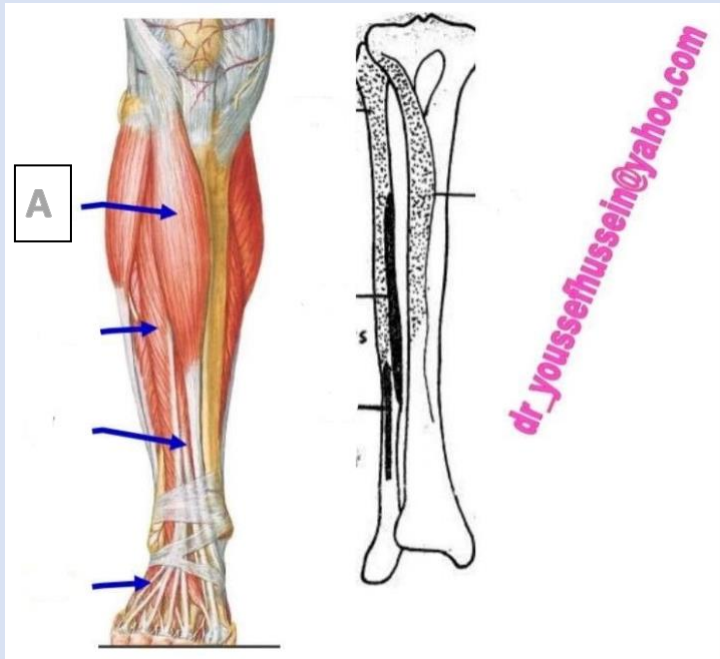
- A- Ischiofemoral ligament**
- B- Iliofermoral ligament**
- C- Transverse ligament**
- D- Iliopectineal ligament**
- E- Ligament of head of femur**

Q26- - What is the labelled structure?



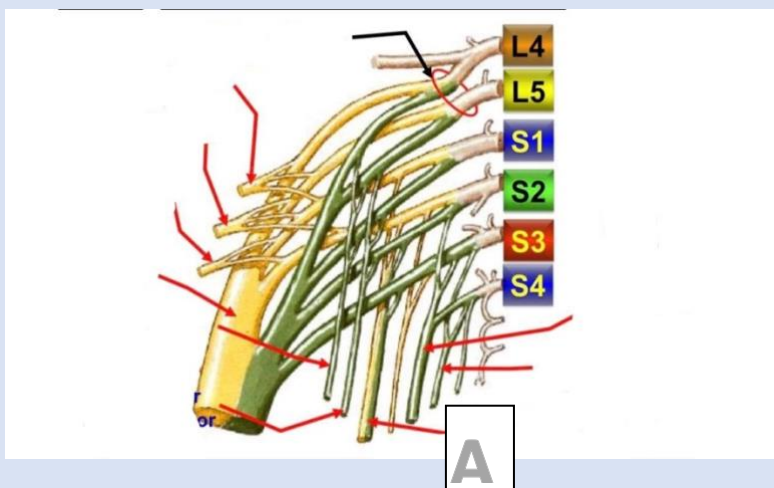
- A- Popliteus**
- B- Gastrocnemius**
- C- Sartorius**
- D- Semitendinosus**
- E- Semimembranosus**

Q27- The structure A is:



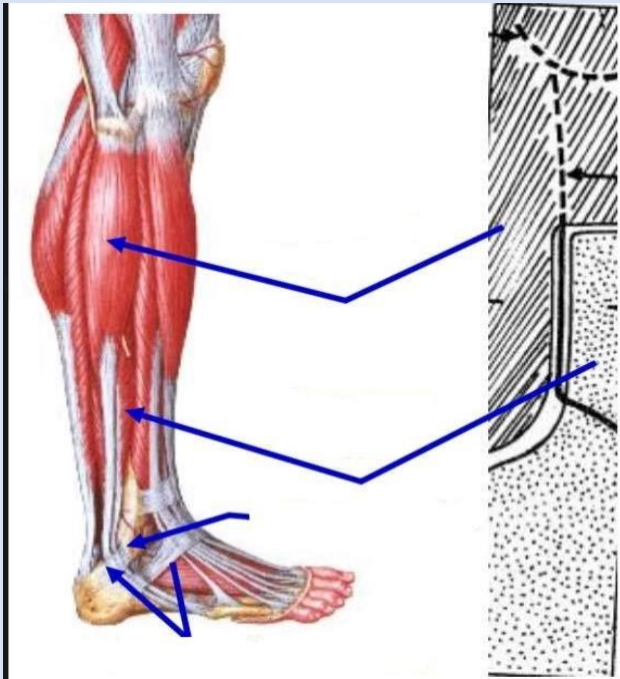
- A- Fibular longus muscle
- B- Tibialis anterior
- C- Gastrocnemius muscle
- D- Soleus muscle
- E- Extensor hallucis longus muscle

Q28- the structure A is:



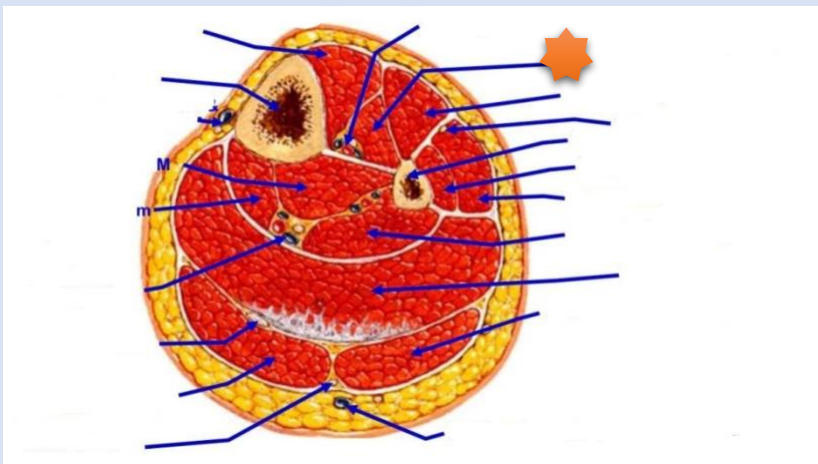
- A- Superior gluteal nerve
- B- Inferior gluteal nerve
- C- Sciatic nerve
- D- Pudendal nerve
- E- Posterior cutaneous nerve

Q29- the structure A is:



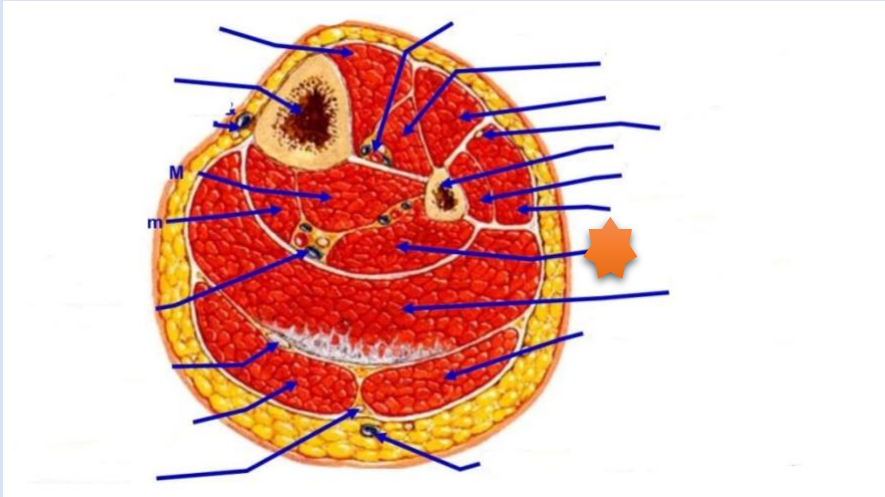
- A- Peroneus longus**
- B- Soleus muscle**
- C- Gastrocnemius muscle**
- D- Peroneus brevis muscle**
- E- Tibialis anterior muscle**

Q30- The structure with star is:



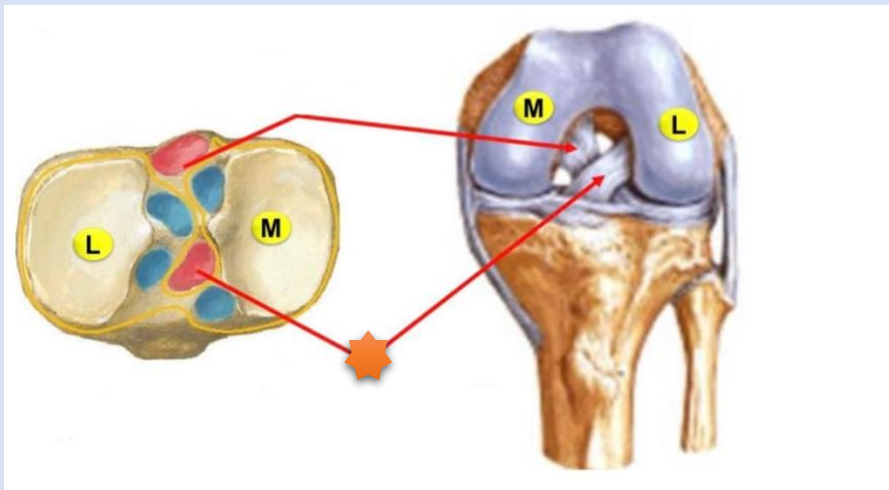
- A- Extensor hallucis longus**
- B- Extensor digitorum longus**
- C- Tibialis anterior**
- D- Soleus muscle**
- E- Gastrocnemius muscle**

Q31- The structure with star is:



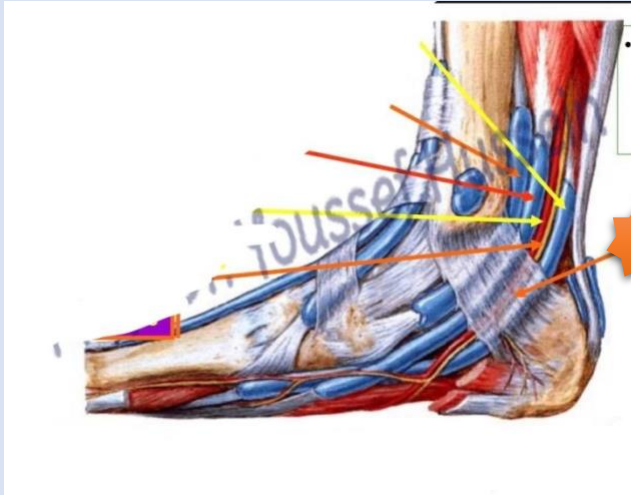
- A- Gastrocnemius muscle**
- B- Soleus muscle**
- C- Flexor digitorum longus**
- D- Tibialis posterior**
- E- Flexor hallucis longus**

Q34- The structure with star is:



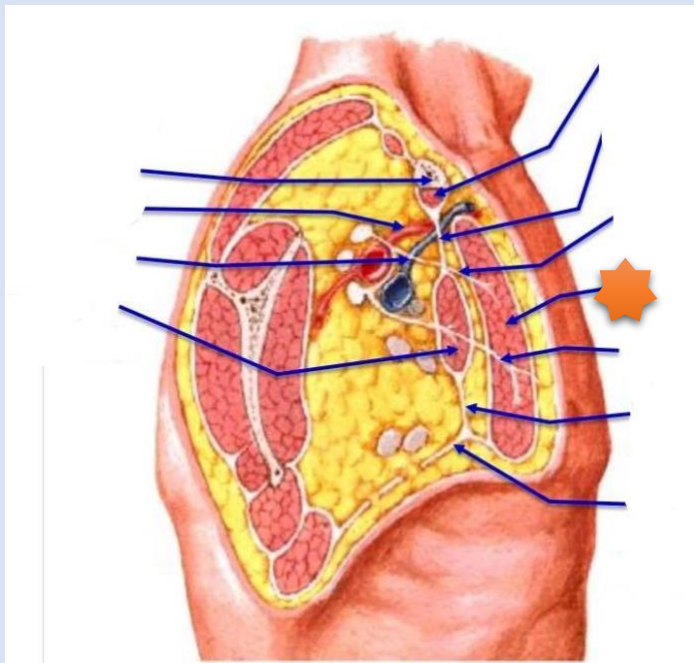
- A- Posterior cruciate ligament**
- B- Anterior cruciate ligament**
- C- Posterior meniscofemoral ligament**

Q35- The structure with star is:



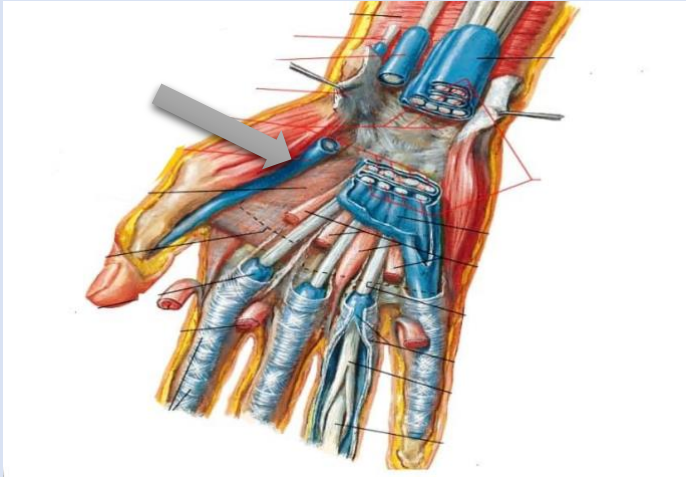
- A- Flexor retinaculum**
- B- Plantar aponeurosis**
- C- Tendinous sheath of flexor hallucis longus**
- D- Tendinous sheath of flexor digitorum longus**
- E- Sheath of tibialis posterior tendon**

Q36- The structure with star is:



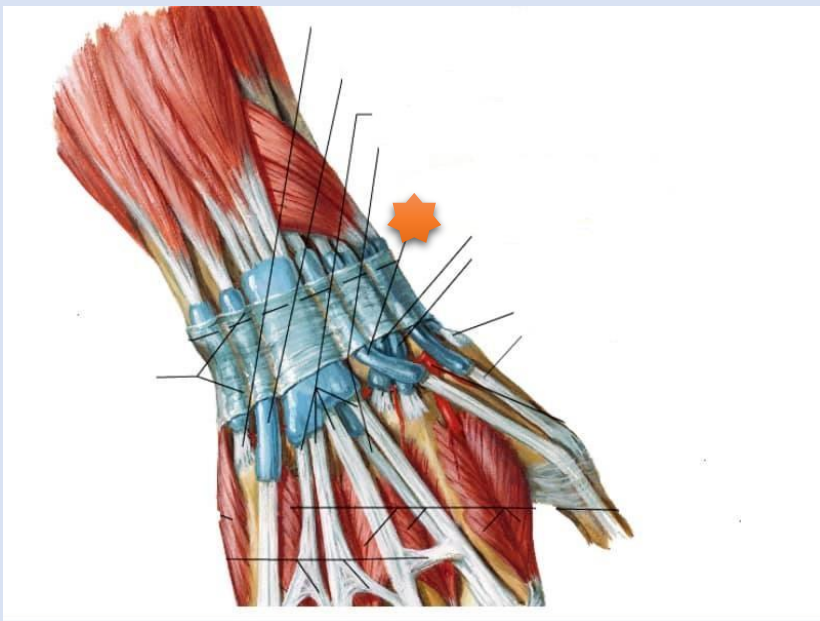
- A- Pectoralis minor**
- B- Pectoralis major**
- C- Subclavius**
- D- Teres major**
- E- Teres minor**

Q37- What is the labelled structure?



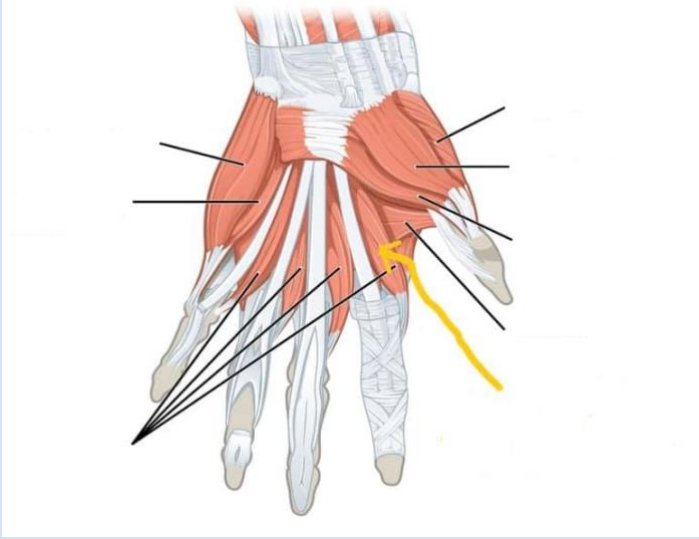
- A- Tendinous sheath of flexor pollicis longus**
- B- Flexor digitorum profundus tendon**
- C- Flexor carpi radialis tendon**

Q38- The structure with star is:



- A- Extensor pollicis longus**
- B- Extensor digiti minimi**
- C- Extensor pollicis brevis**
- D- Abductor pollicis longus**
- E- Extensor retinaculum**

Q39- What is the labelled structure?



- A- *Opponens pollicis***
- B- *Abductor pollicis brevis***
- C- *Flexor pollicis brevis***
- D- *Second lumbrical muscle***
- E- *First lumbrical muscle***

لا تنسونا من صالح دعائكم
بالتوفيق
لجنة الطب والجراحة