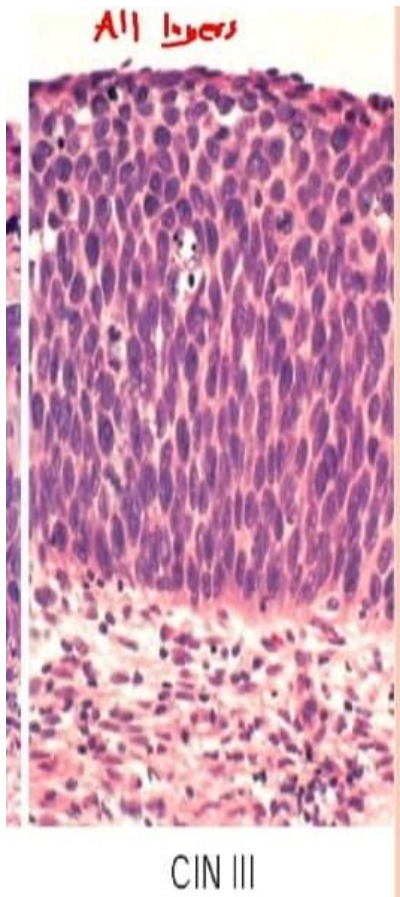

## Dipstick chemical analysis leukocyte esterase tests



**Leukocytes:** Indicates infection or inflammation

**Normal=negative**

- **Pyuria:** Leukocytes in urine
- **Cystitis:** Bladder infection
- **Pyelonephritis:** Kidney infection

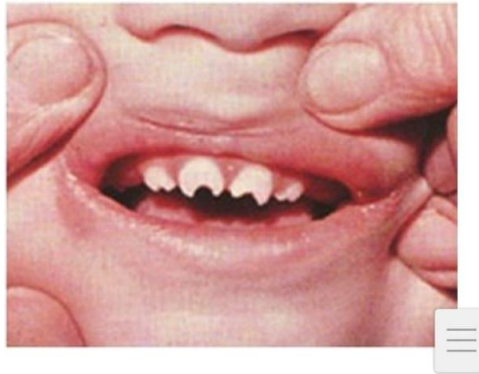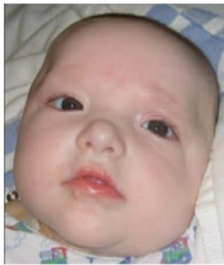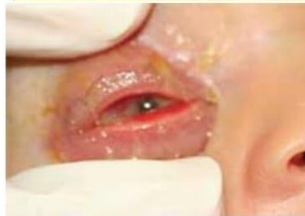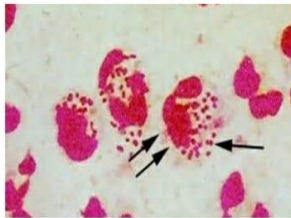
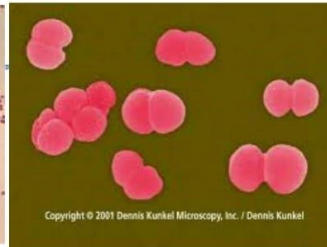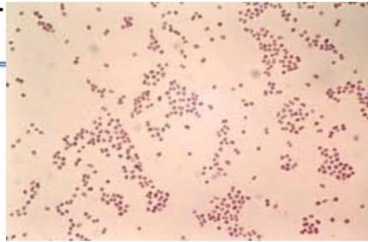
# Gonorrhea

Diagnosis:

1- Staining.

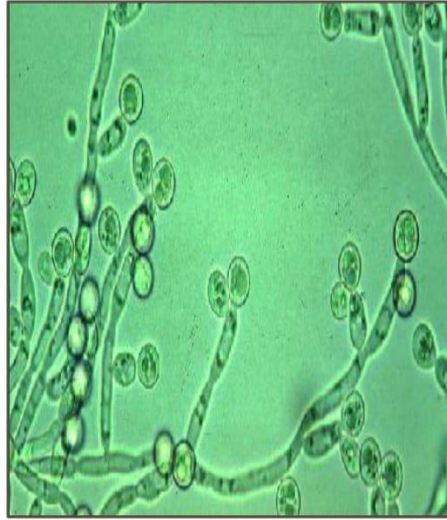
2- Culture.

3- PCR.

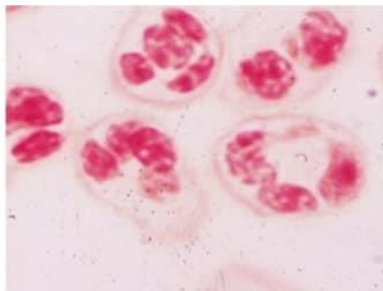


## *Candidia albicans*

- ❖ Oval gram positive.
- ❖ Budding yeast which produce pseudohyphae.
- ❖ It ferments glucose & maltose with acid & gas production.
- ❖ **Germ tube** is formed when cultured colonies is incubated with human serum at 37 C for 30 min.



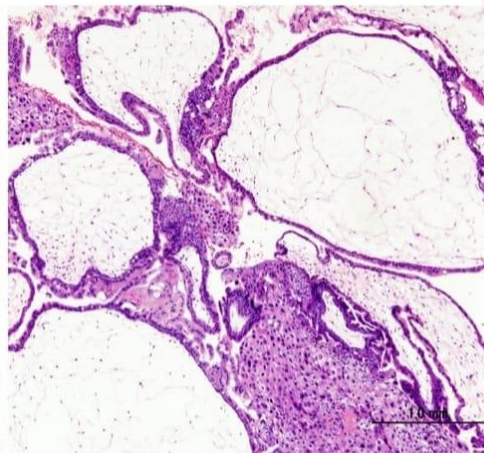

34



**Non-gonococcal  
urethritis**

## HYDATIDIFORM MOLE – MORPHOLOGY

Uterine cavity is expanded by friable mass (Grape-like villi) composed of thin-walled, cystically dilated chorionic villi covered by varying amount of atypical chronic epithelium.



الخدمات الطبية الملكية

مستشفى: \_\_\_\_\_

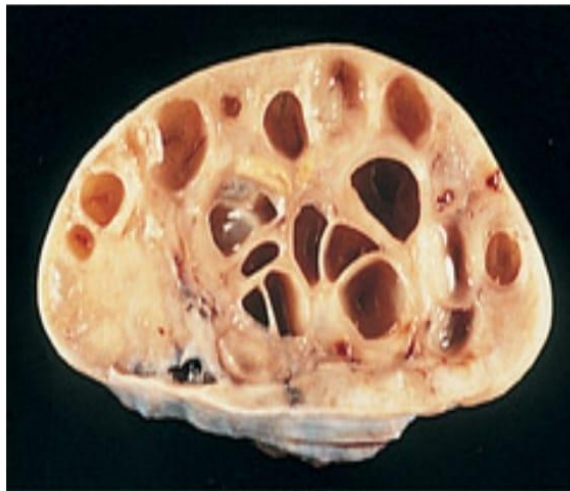فحص البول  
URINALYSIS

اسم المريض الكامل: \_\_\_\_\_  
 الرقم الطبي: \_\_\_\_\_  
 الرقم الوطني: \_\_\_\_\_  
 الرتبة: \_\_\_\_\_  
 العمر: \_\_\_\_\_  
 الجنس:  انثى  ذكر  
 متزوج  أعزب

الطبيب الاعتمادي:	اسم و توقيع الطبيب المشرف:	القسم / العيادة:	تاريخ الطلب:
Diagnosis & Relevant Information :			
Test	Result	Test	Result
Albumin	+ (1)	Microscopic sediment :	
Sugar	++ (2)	R. B. C	8-10
Other Tests :		W. B. C	8-20
		casts	
		Crystals	ca <sup>++</sup> oxalate
		Other Findings	
Comments :			
اسم و توقيع طبيب المختبر:	اسم و توقيع المشرف:	التاريخ:	التسجيل:

## OVARIES- POLYCYSTIC OVARIAN SYNDROME

Stein-Leventhal, young with a/oligomenorrhea, infertility (anovulation), obesity and hirsutism



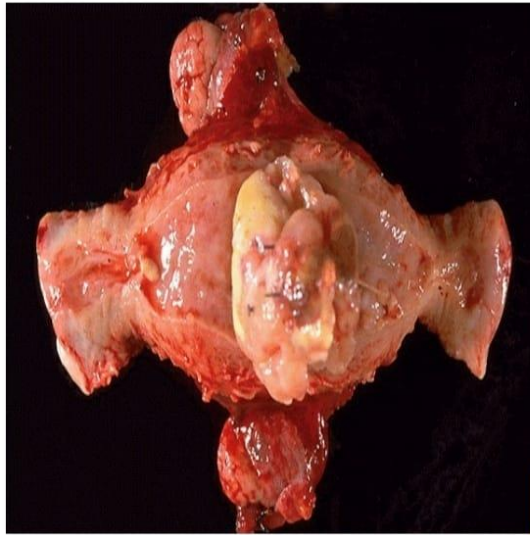
Courtesy of NIH in Medica Inc. an affiliate of Elsevier Inc.



## TUMORS OF MYOMETRIUM – LEIOMYOSARCOMA

**Gross:** soft, hemorrhagic, necrotic masses. Irregular borders.

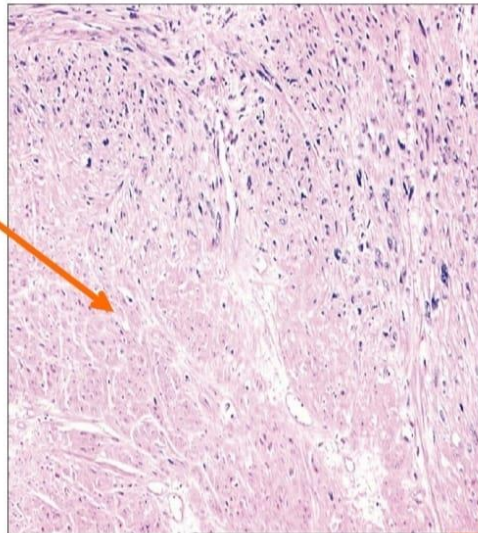
Single mass, atypia, enlarges even with no estrogen (menopause)



35

## TUMORS OF MYOMETRIUM – LEIOMYOSARCOMA

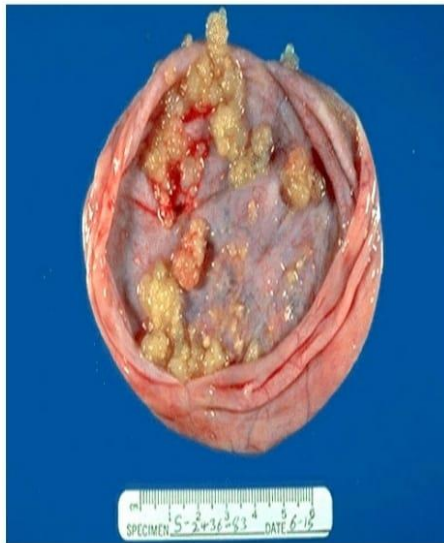
**Microscopic:** Diagnostic features of leiomyosarcoma; (1) tumor necrosis, (2) cytologic atypia, and (3) mitotic activity. Assessment of all three is necessary to make a diagnosis.



36

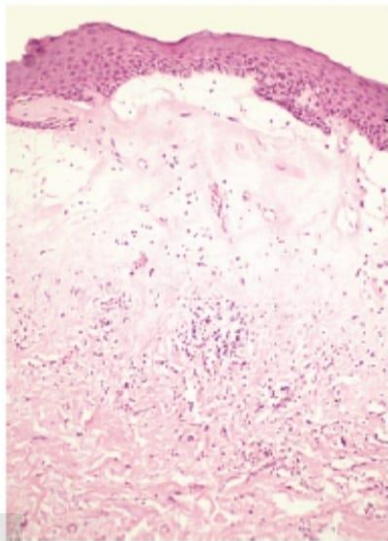
## SEROUS TUMORS - BORDERLINE SEROUS TUMORS

- complex architecture. (Protruding papillary projections)
- might be associated with peritoneal implants.



Lichen sclerosis is characterized by thinning of the epidermis, disappearance of rete pegs, hydropic degeneration of the basal cells, dermal fibrosis, and a scant perivascular mononuclear inflammatory cell infiltrate.

All ages, white patch, more in postmenopausal, can become SCC, Idiopathic, can be with autoimmune



Thinned epidermis

Hydropic degeneration at basal layer

Sclerotic stroma

Dermal inflammation