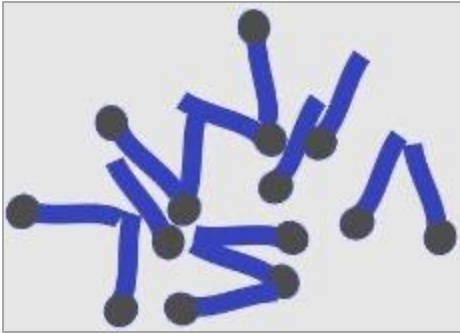

# *Corynebacterium diphtheriae*

**By**

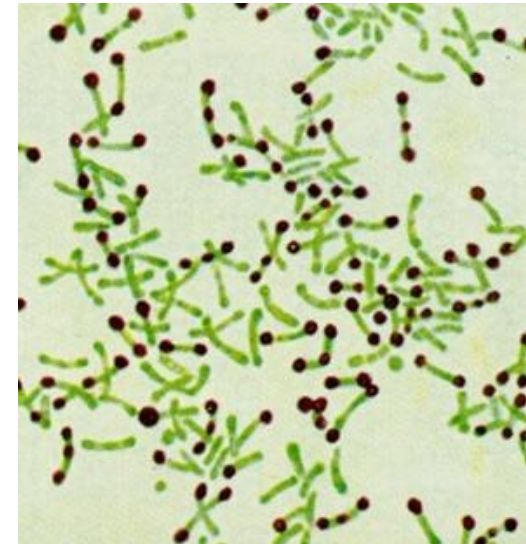
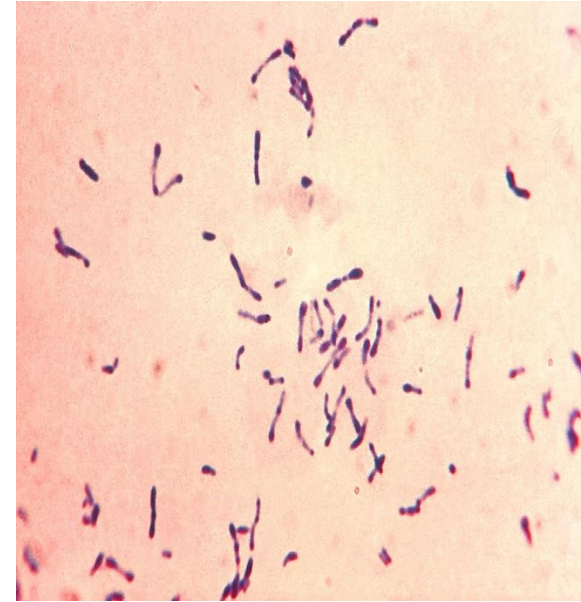**Professor Dina Moustafa Abou Rayia**

**Medical Microbiology and Immunology Department**

**2024-2025**

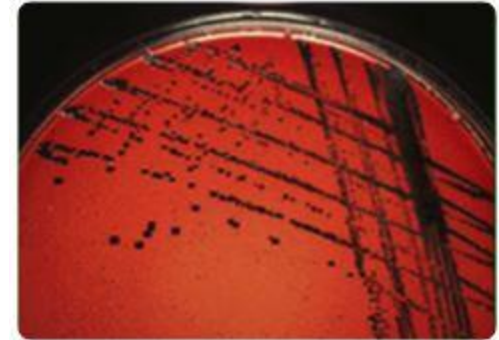
# Morphology

- ❑ They are **gram-positive** pathogenic rods with one end swollen (club-shaped).
- ❑ They lie in small groups at acute angles or parallel to each other (**Chinese-letter in arrangement**).
- ❑ They may have a beaded appearance when stained with methylene blue or Neisser stain due to the presence of metachromatic polyphosphate (volutin) granules.
- ❑ They are non-capsulated, non-motile, and non-spore-forming.



# Culture characters

- ❑ They are aerobic but can grow also under anaerobic conditions (facultative anaerobe) at 37° C.
- ❑ They grow on **Loeffler's serum**, **blood agar** and **blood tellurite medium** (selective differential medium).
- ❑ On blood tellurite medium, the colonies appear grey to black and can be differentiated according to morphology, size, and colour of the colonies into 3 biotypes [mitis (black with gray periphery), **gravis** (large **gray**), and intermedius (small, dull gray to black)].



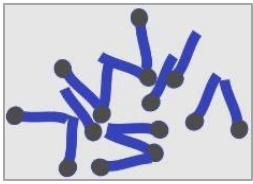
Mitis



Gravis



Intermedius

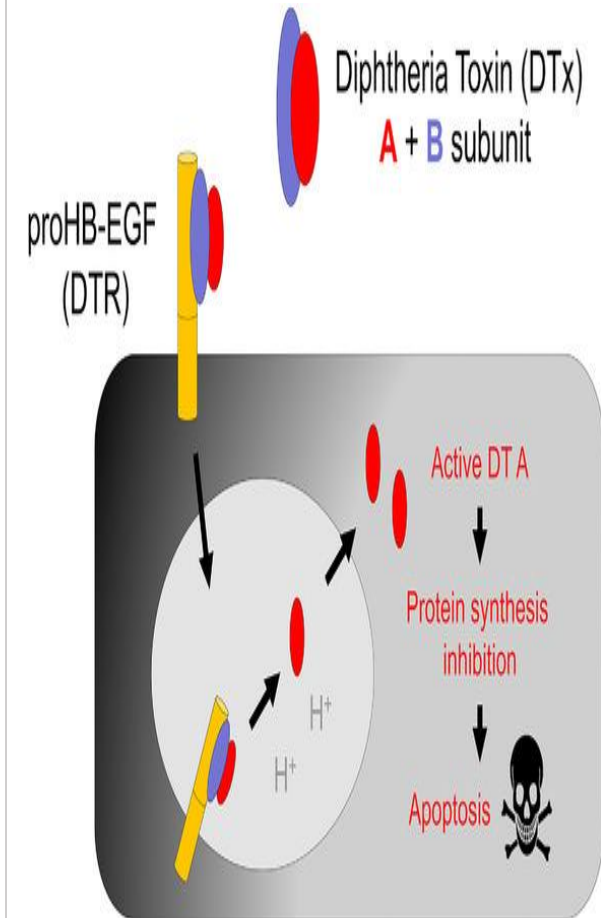


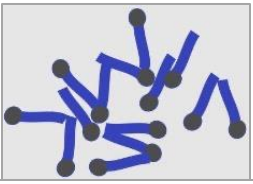
# Virulence factor



## Diphtheria toxin

- ❑ The main virulence factor is the ability of *C. diphtheriae* strains to produce a powerful exotoxin.
- ❑ The toxin is produced only when the bacilli are infected by a temperate phage (**lysogenic strains**).
- ❑ Toxin production requires a critical concentration of iron as in response to iron deprivation, the *C. diphtheriae* can produce exotoxin.
- ❑ The exotoxin is composed of two fragments A and B. Fragment B allows binding with the host cell and Fragment A enters the host cell preventing protein synthesis by inhibiting elongation factor 2 (EF-2) and causing cell death.
- ❑ This toxin is heat labile, highly toxic, highly antigenic, can be transformed into toxoid by formalin, and neutralizable by antitoxin.

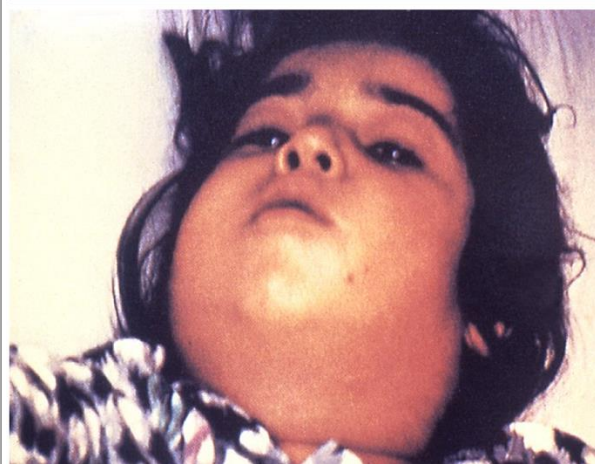
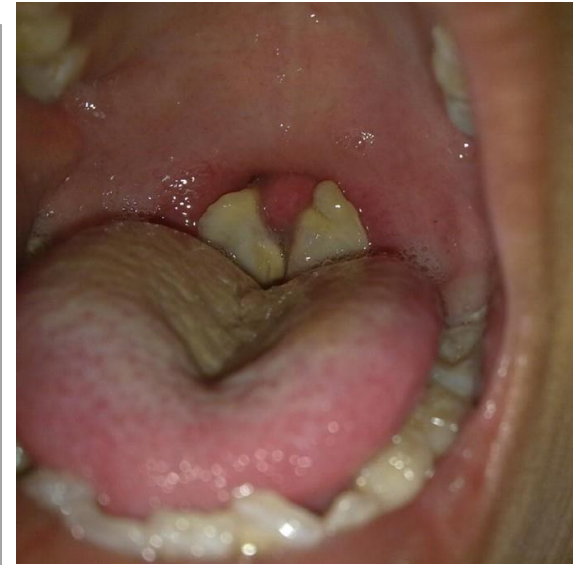
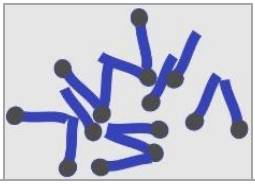


# Diphtheria



- A highly contagious disease caused by *C. diphtheriae*.
- **Transmission:** It can be transmitted by droplet infection or contact with a case or carrier.
- **Pathogenesis and clinical picture:**
  1. Diphtheria toxin is absorbed into the mucus membrane causing epithelium destruction and superficial inflammatory response resulting in the formation of a grayish pseudomembrane on over tonsils, pharynx and larynx. Any attempt to remove this membrane results in bleeding. With enlargement of cervical lymph nodes (bull's neck)





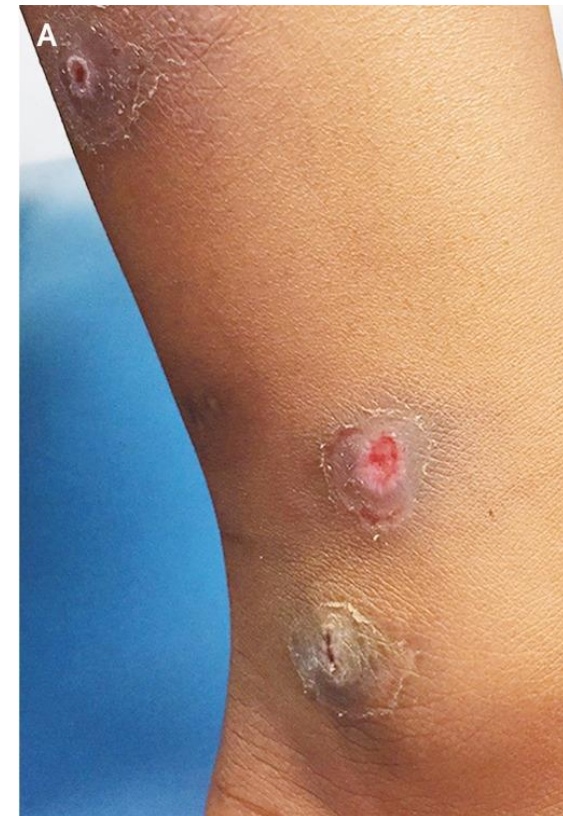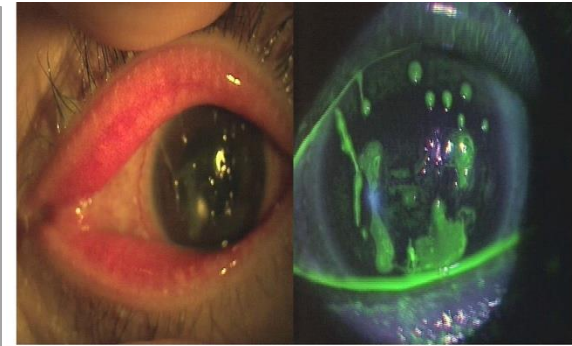
# Diphtheria

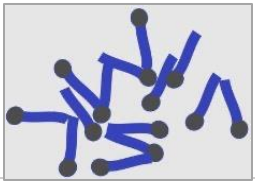


2. The bacilli within the mucus membrane continue to produce toxin which is absorbed in the circulation and affects the following:

- **Heart muscle:** myocarditis
- **Nerves:** nerve damage, that may lead to muscle paralysis causing soft palate paralysis, difficulty in swallowing and speech, respiratory obstruction and suffocation or limb paralysis.
- **Kidney:** Nephritis.

3. May be transmitted by contact affecting the skin or conjunctiva.

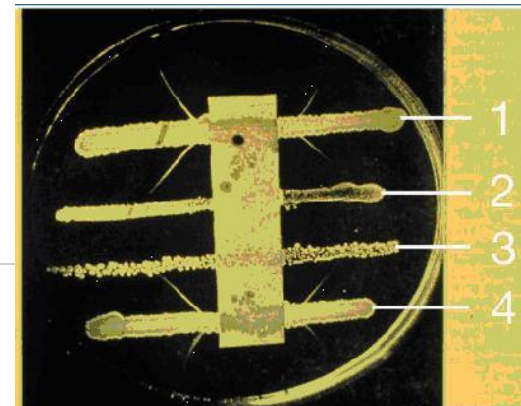
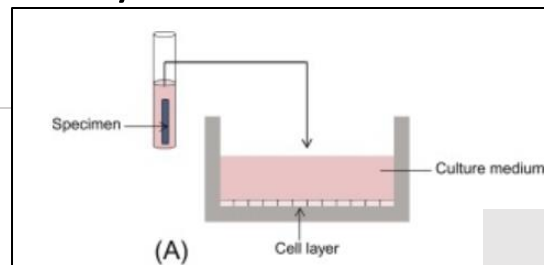
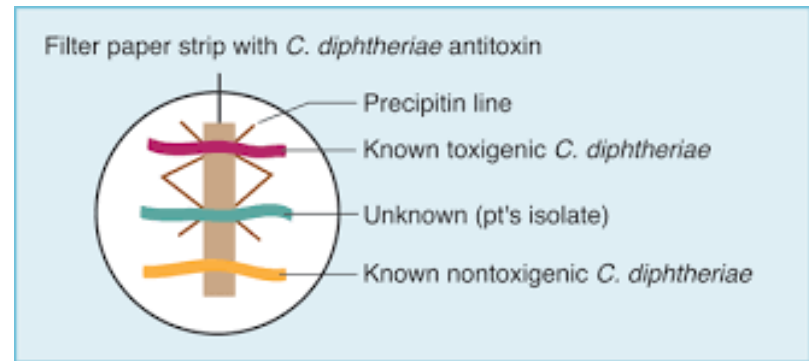


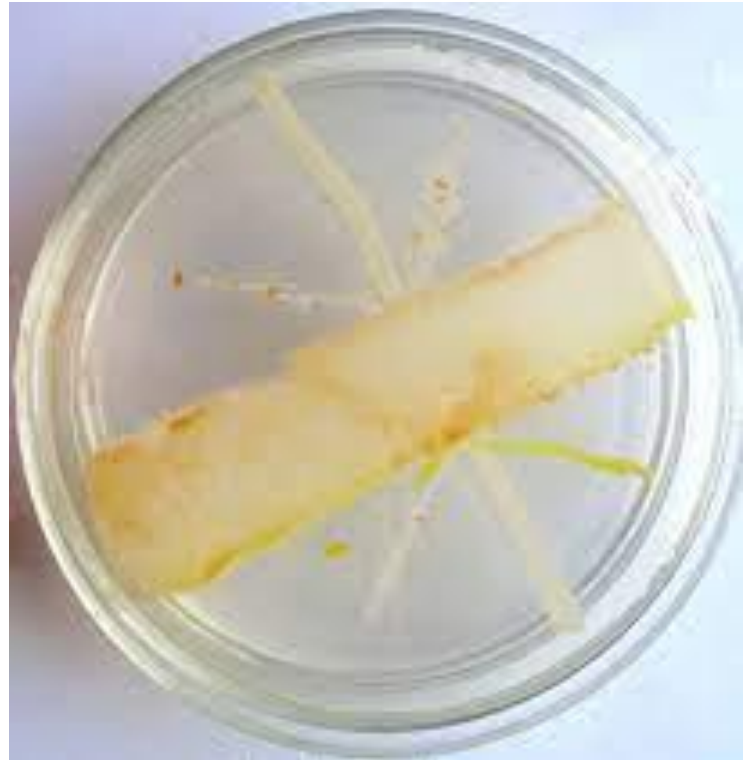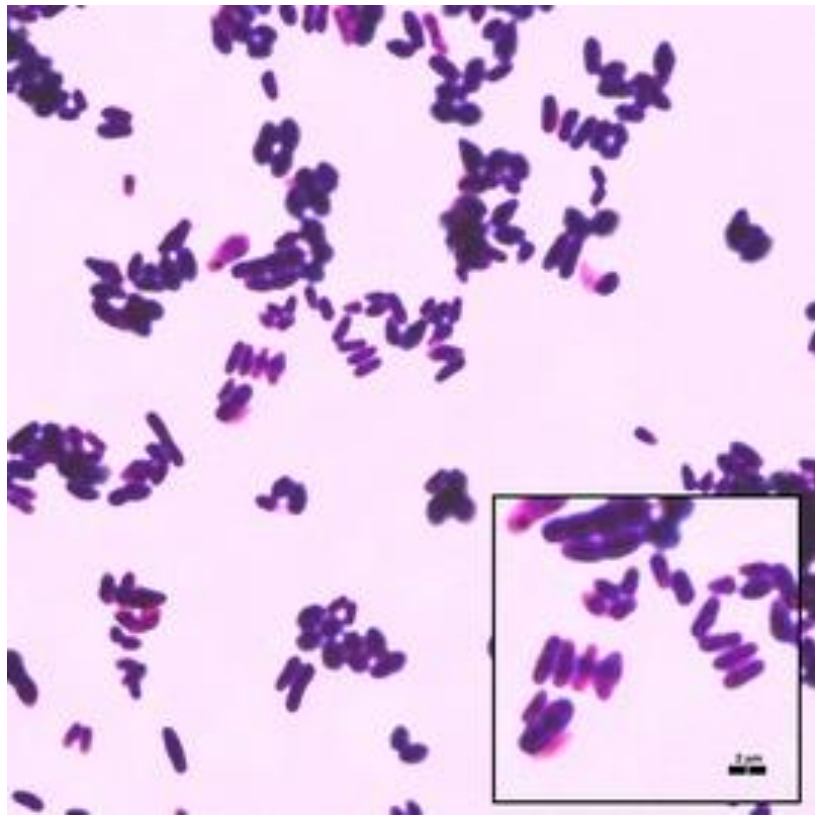


# Laboratory Diagnosis

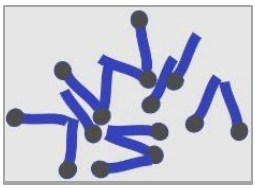


- **Specimen:**- throat swab or swab from any suspected lesions.
- **Smear:** stained with Gram, methylene blue or Neisser stain (Chinese letters)
- **Culture:** on Loffler's serum, blood tellurite agar and blood agar for **D.D hemolytic streptococci**.
- **Toxigenicity testing:**
  - Elek's test on serum agar plate
  - PCR
  - ELISA
  - Rapid immunochromatographic
  - Tissue culture cytotoxicity assay









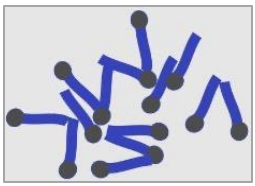
# Treatment

## 1. Diphtheria antitoxic serum

- Should be given without delay if a case is suspected from 20,000 to 100,000 units IM or IV after precautions to avoid hypersensitivity to animal serum.

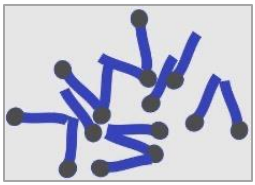
## 2. Antibiotic:

- Penicillin and erythromycin but they are not a substitute to antitoxic serum but inhibit bacterial growth thus decreasing the toxin production and carrier incidence.



## Management Patients in whom diphtheria is suspected

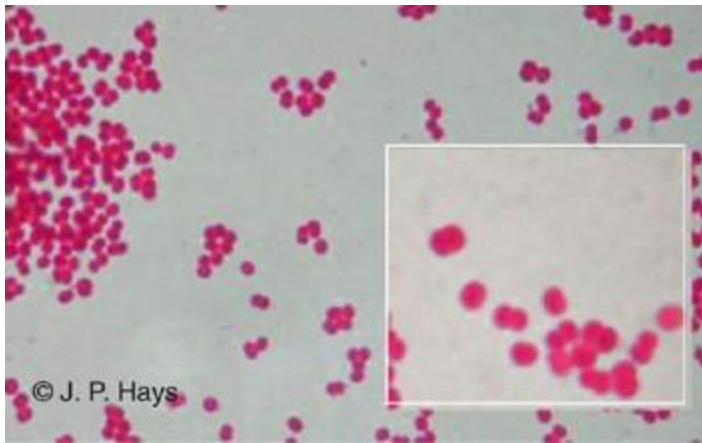
- Should be hospitalized in respiratory isolation rooms, with close monitoring of cardiac and respiratory function.
- A cardiac workup is recommended to assess the possibility of myocarditis.
- In patients with extensive pseudomembranes, possibility a tracheostomy or intubation will be required.
- In some settings, pseudomembranes can be removed surgically.



# Prophylaxis

## Types of vaccine:

1. **Single vaccine:** Diphtheria toxoid
2. **Combined vaccine:** various vaccine available are
  - DPT:** Contains DT (diphtheria toxoid), P (pertussis whole cell killed vaccine), and TT (tetanus toxoid). It is the vaccine of choice for infants. **(why). Given at 2,4,6 and 18 months. Booster at school age.**
  - Pertussis in this vaccine which is used as a whole cell acts as an adjuvant which increases the immunogenicity of DT and TT.
  - TD:** Booster every 10 years in adults. **Why TD only ??**



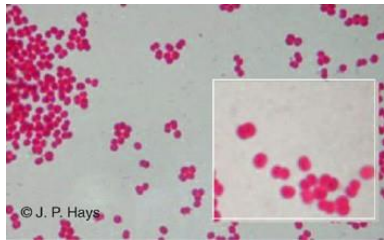
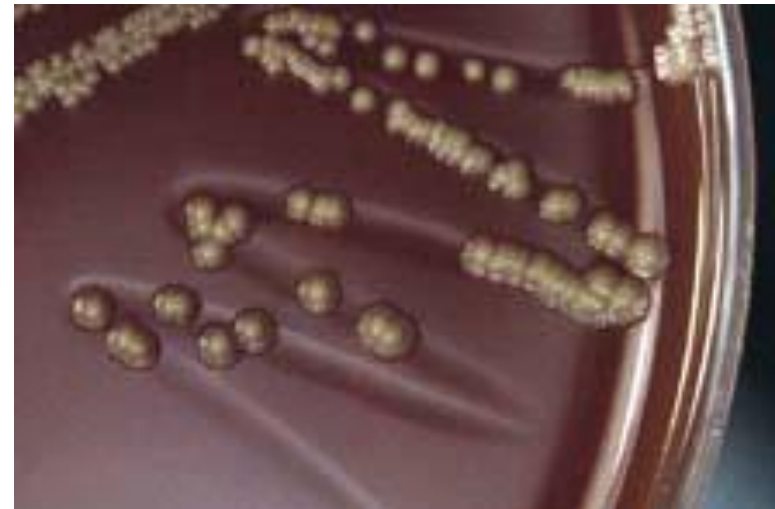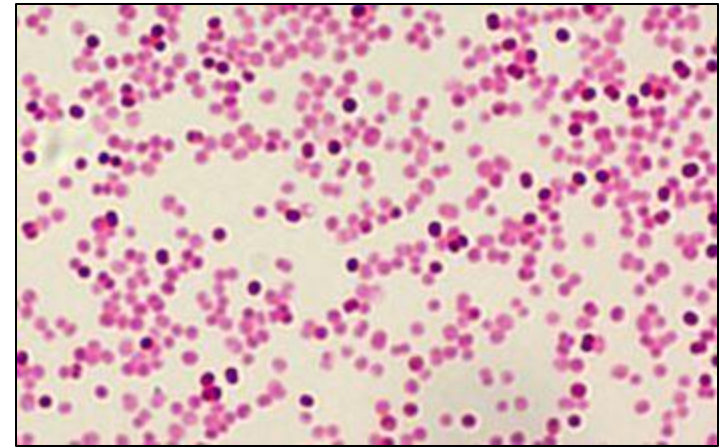
# **M***oraxella catarrhalis*

# *Moraxella catarrhalis*



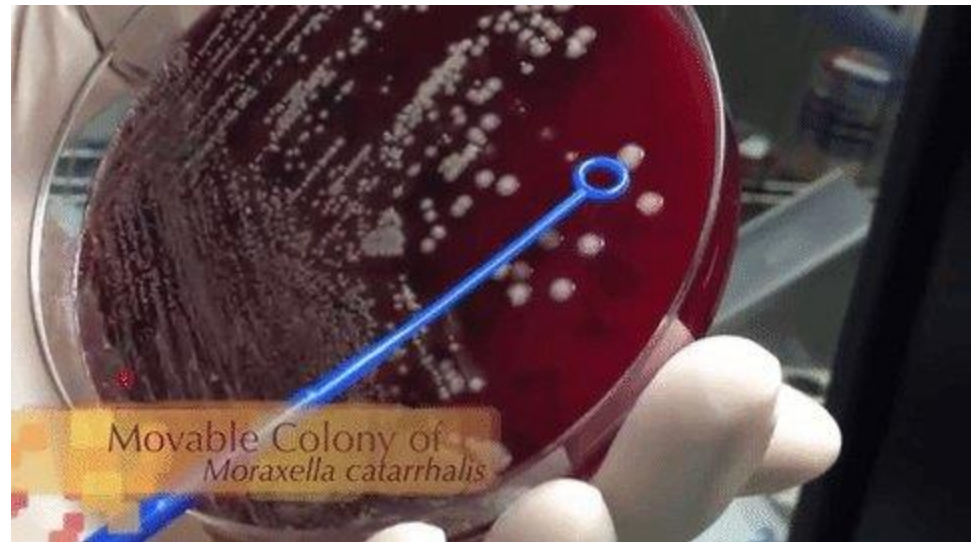## Morphology and culture characters

- Gram-negative cocci or diplococci
- Non motile
- Aerobic \*\*\*
- Grayish-white colonies which scoot across the agar without disruption when pushed by loop (**Hockey puck sign**)

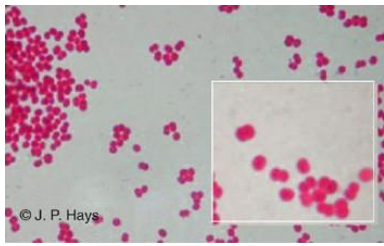




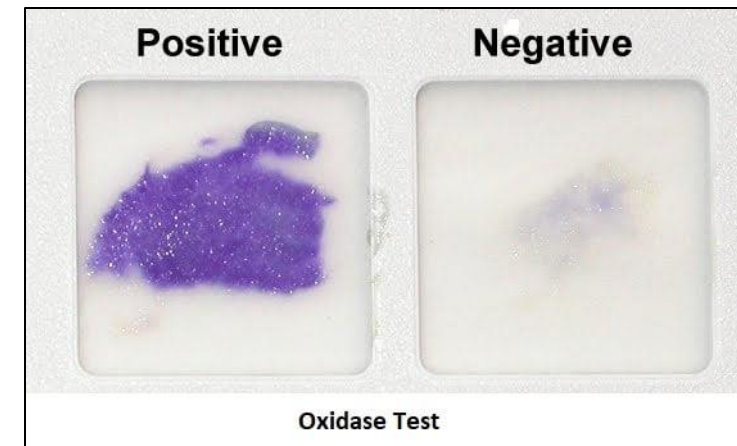

(Hockey puck sign)



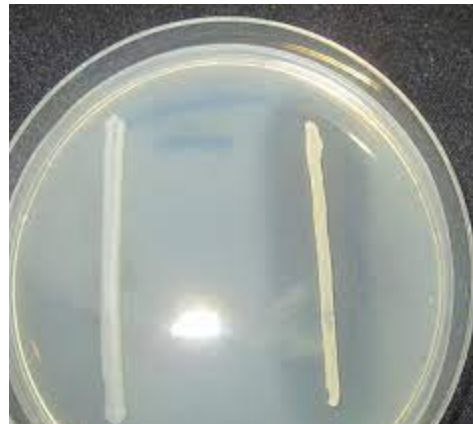# *Moraxella catarrhalis*

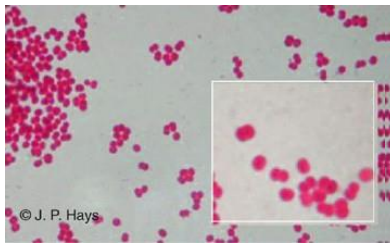


- **Biochemical reaction**
- Oxidase positive
- Catalase positive
- Non sugar fermenter
- Produce beta- lactamase
- DNase positive



DNase test





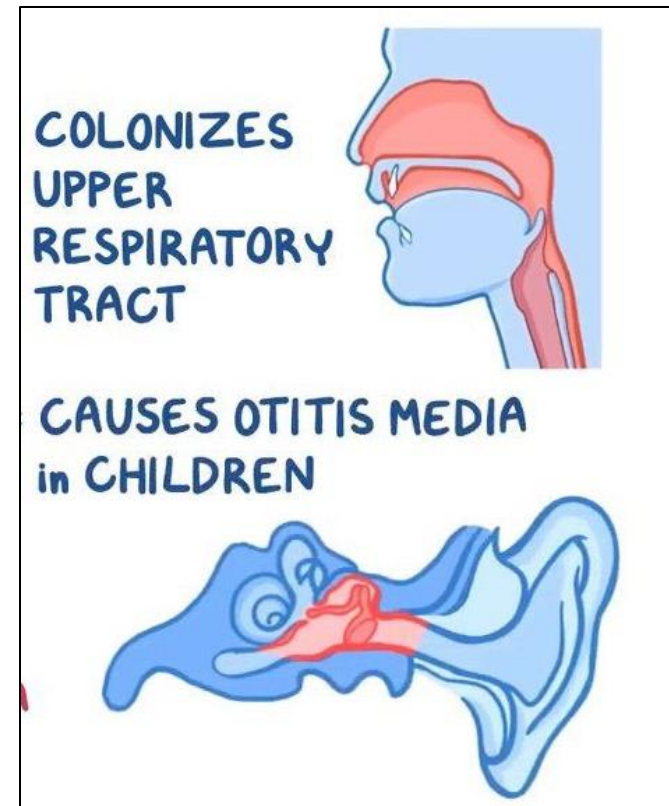
# *Moraxella catarrhalis*

## • Clinical infections

- Pneumonia
- Sinusitis
- Otitis media (3<sup>rd</sup> most common cause)
- Eye, CNS, Joints infection

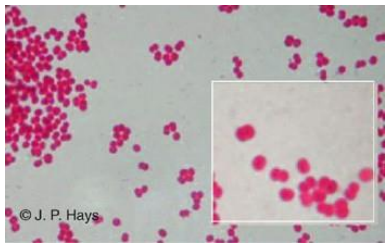
## • Predisposing factors

- Advanced age
- Immunodeficiency
- Neutropenia
- Other debilitating diseases



Normal commensal of the respiratory tract (humans only)  
Has become an important opportunistic pathogen



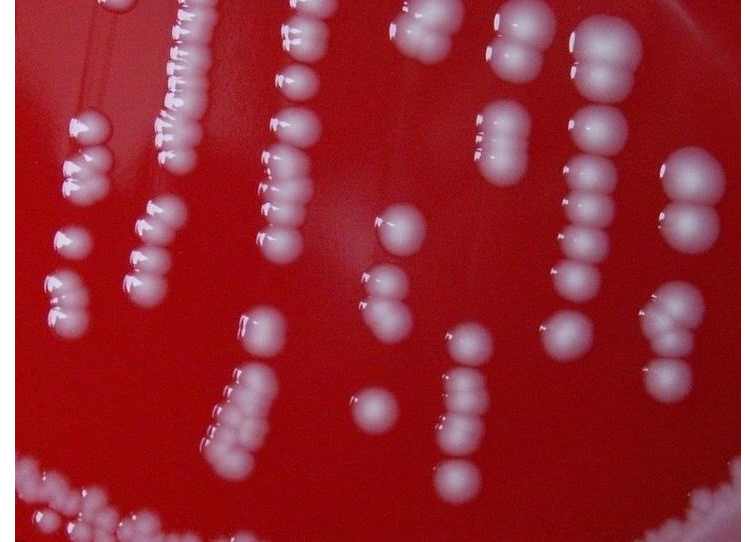

# *Moraxella catarrhalis*



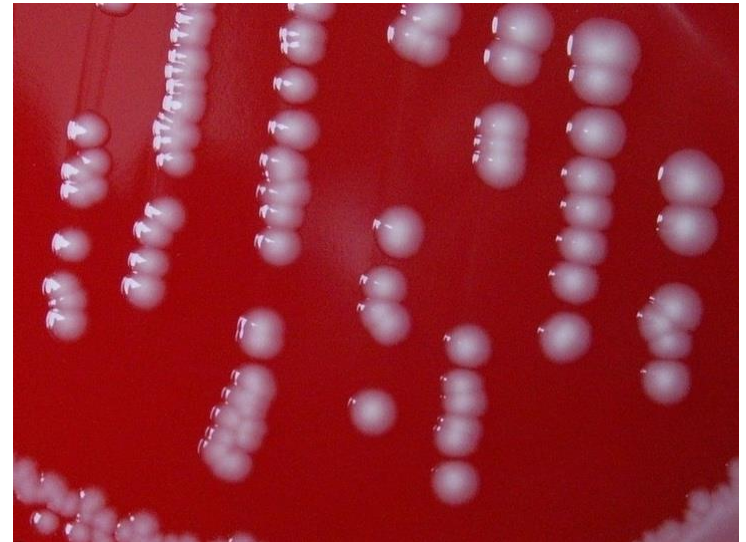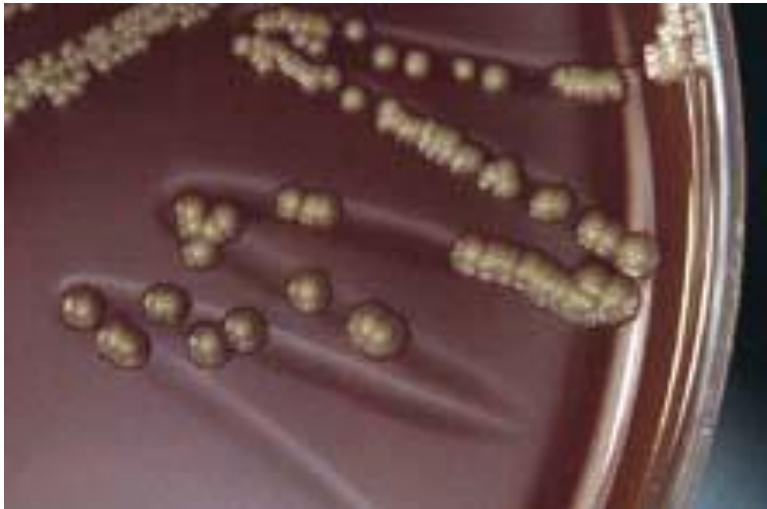## Laboratory diagnosis;

- **Sample:** pus, sputum, CSF
- **Smear:** Gram negative diplococci
- **Culture:** Smooth grayish-white colour
- **Biochemical reaction:**
  - Oxidase positive
  - Catalase positive
  - Non sugar fermenter
  - Produce beta- lactamase
  - DNase positive



# *Moraxella catarrhalis*

- **Treatment:** fluoroquinolones, most second and third generation cephalosporins, erythromycin, and amoxicillin-clavulanate





## Case study

- A 2 year old child experienced an upper respiratory infection.
- He had anorexia and fatigue.
- The patient was seen in the emergency room. He had a fever of 39.9°C.
- Physical examination revealed a clear chest, exudative pharyngitis, and bilaterally enlarged cervical lymph nodes.
- A throat culture was taken and the child given a course of penicillin.

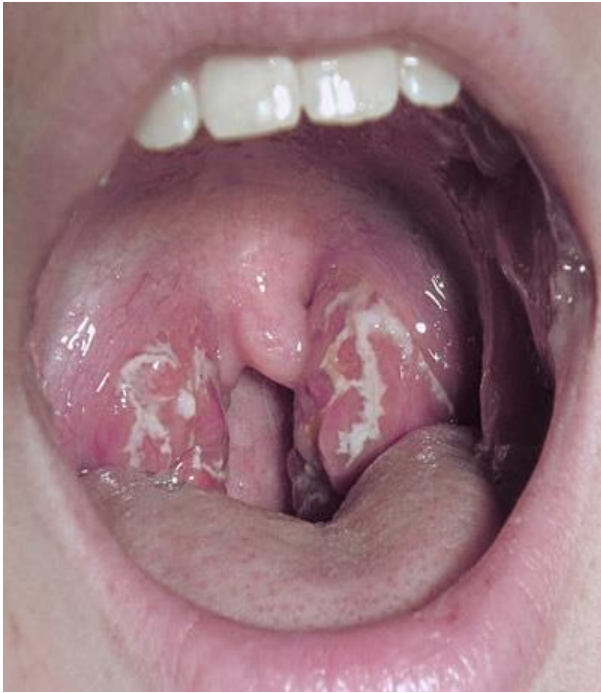
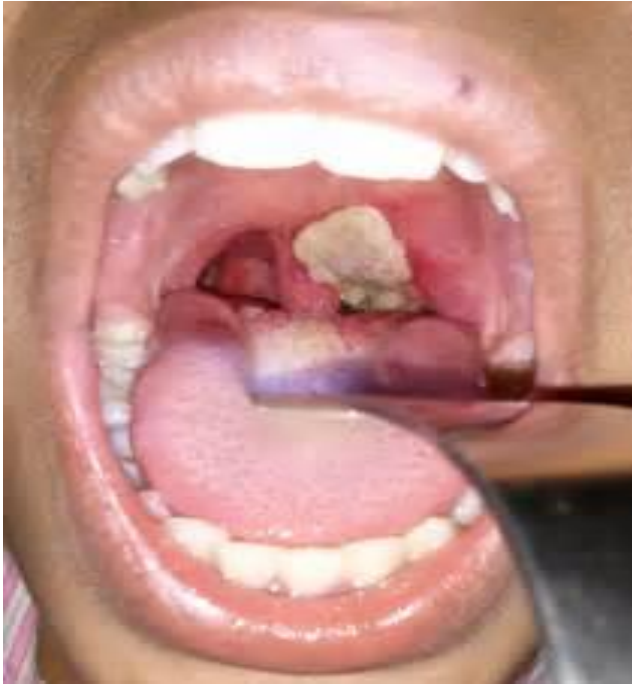
It was noted that the throat culture had not grown any group A streptococci



- On day 10 of the infection, the child's condition worsened. He became increasingly lethargic; developed respiratory distress on the day of admission. On examination, 38.9°C, had an exudate in the posterior pharynx that was described as yellowish, and thick membrane which bled when scraped and removed. The patient's medical history revealed that he had received no immunizations.

# The Diphtheritic vs. Streptococcal Pharyngitis



Thank  
You

