حجرات القلب

atrium

Right

① Tricusped opening

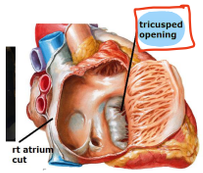

- lower of anterior wall
- guarded tricusped valve
- 3 finger

② Anterior wall [Rough]

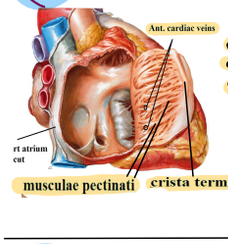

- anterior cardic vain
- cresta terminales → virtical musul (IVC, SVC)
- musculai pectinat → externaly: sulcus terminales
  - transvers musul
  - cresta terminales → anterior wall
- separat → posterior / aterior wall

③ posterior [smothe]

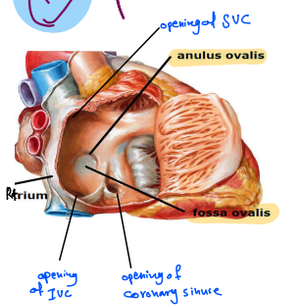

- fossa ovali → In interatrial septum / above SVC
- Anulus ovali
- opening → IVC 6.c.c / SVC 3.c.c / coronary sinus: → valve of IVC, → tricusped opening
- venus cordai minime

*SVC :- No valve
*IVC :- non function valve

left

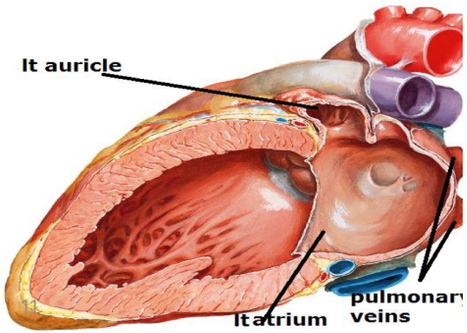

- Mitral opening: guarded mitral valve, 2 fingers
- anterior wall: rough, have auricle, have musculai pectinat only
- posterior wall: smoth, 4 pulmonary vain opening (in uper part), No valve
- venus cordai minime

raghf serves
coagulation ؟ عكن يسوي تكتل للدم
لا ليش لانه مبطن بـ endothelium
ناعم

ventricle

right

* Semilunar
* $\frac{1}{3}$ of thikness of left

- opening of 2 → tricuspe, → pulmonary
- Rough wall [in flow]
  - 1-Trabeculae carneae: • muscular Ridg • freelly interciross • spongy meshwork
  - 2-papillary muscles: 3 → anterior, posterior, septum
    - shape: conical
    - base → ventricular wall
    - Apex → cordae tendani to margin; ventrical surfes of cusps of tricuspes valve
  - function: prevent the value regurge
  - 3-moderator band = septumarginal tubercil
    - tubercl from sptum to anterior papilary musole
    - function: • transmition right Bundle branch. • prevent the over stroching.
- smoth wall [out flow.] = infundebulum

out flow wall | in flow wall

(separat) supraventricular crest

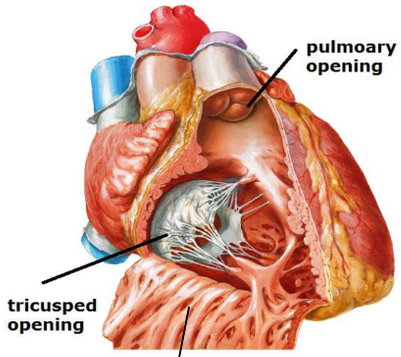

1-Trabeculae carneae:

left

* circular
* 3 thiker than Right
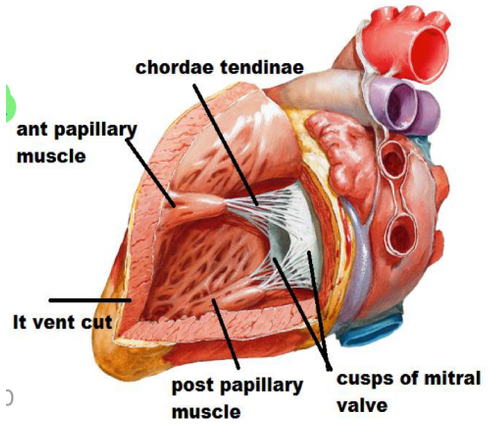
- opening 2 → mitral, → Aorta
- Rough wall [in flow]
  - 1-Trabeculae carneae: → thiner, → multepil more than right
  - 2-papillary muscles: 2 → anterior, posterior
    - shape:- larger than that of rt vent., chordae tendinae are thicker & fewer, attach to margins & ventricular surface of both cusps of the mitral valve
    - contraction
  - 3- has no moderator band
    - ماض داخي اد بر بالي ما ال strech
    - لان الدم الي دخل اقلة كنت مزيطيته من ال Right
- smoth wall [out flow.] = Aortic vestebule