

# ENT December archive

Batool frehat

1) Mass extend to one vocal cord ??

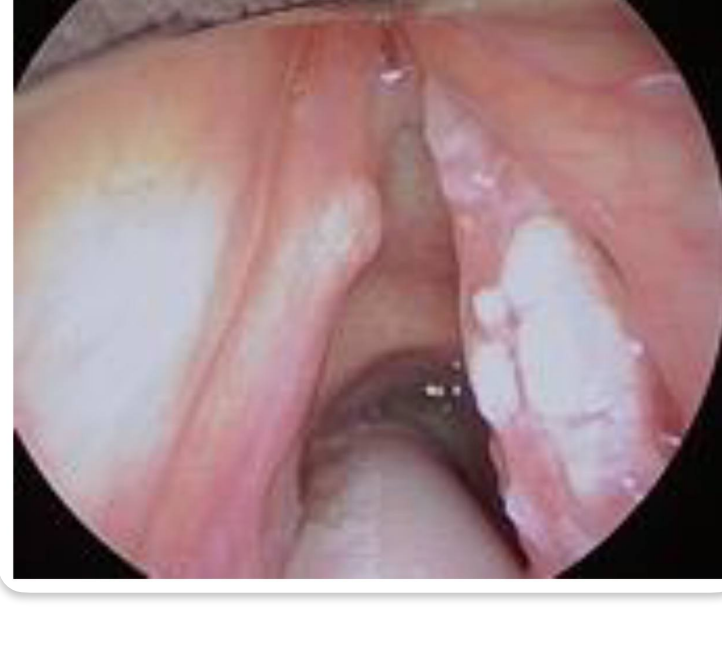Stage T1a

2) All are used for treatment for it except??

Total laryngectomy

3) In this case, Patient complain from ear pain which nerve is affected??

Vagus nerve



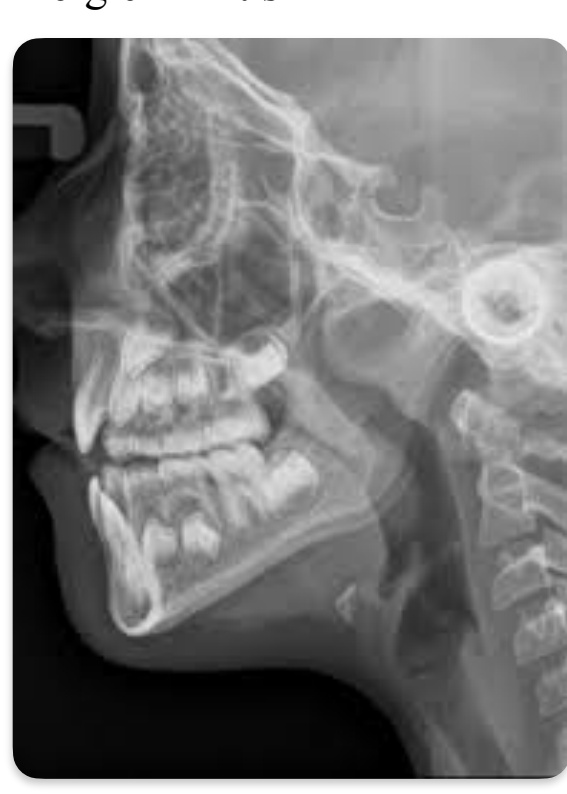صورة Adenoid

4) Diagnosis??

Adenoid hypertrophy

5) Indication for surgery except??

Allergic rhinitis



6) Nasal packing anterior and posterior صورة

Except??

All of the following are true regarding this pic except?

Ant nasal packing in the pic

Shown posterior and anterior nasal packing

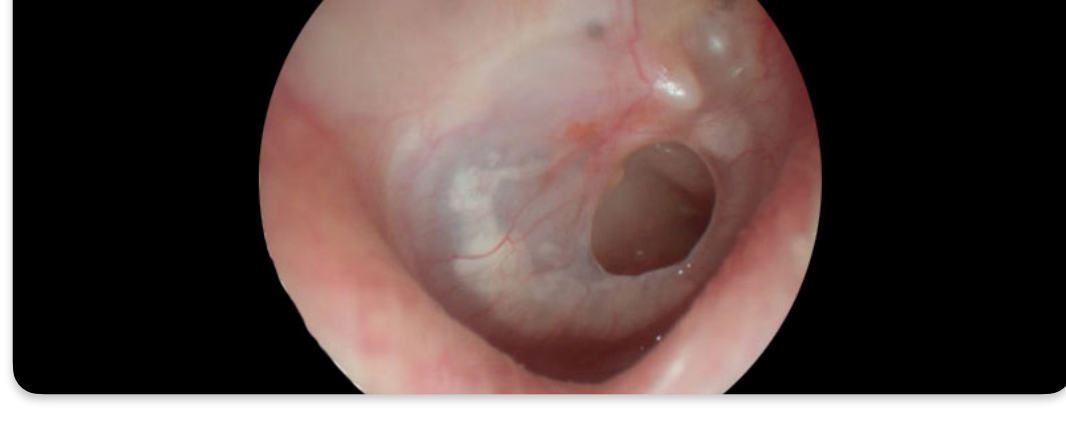
Post nasal packing

This procedure done at out pt clinic ✓

The site of bleeding for this pic is most likely from wd

7) Complication except,??

Rhinitis medicamentosa



صورة TM perforation one is true (8?)

Right rein negative left rein positive Weber lateralise to right

9) Type of tympano???

Type B and high ear Canal volume

10) Pure tone audio gram ??

Air conduction abnormal and Bone normal with a gap more than 10

11) Vertigo more than 20 minutes and headache no hearing loss one is true??

Head test —no nystagmus

12) Diagnosis??

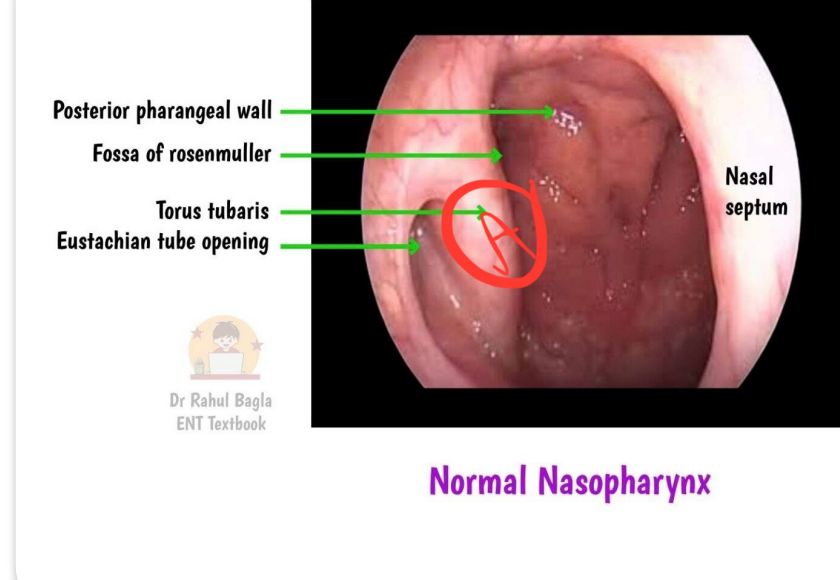
Vestibular migraine

13) Neck mass and recurrent nasal obstruction , next step???

Fibre optic nasopharyngeal endoscope

14) If the mass in A ,, and have a right ear issue , what is the state of tympanic membrane???

Retracted TM



15) FB , one is false,??

Ear sponge — need ear syringing

Best way for insect extraction is forceps

16) Compare per cutaneous and surgical tracheostomy except???

LA — GA

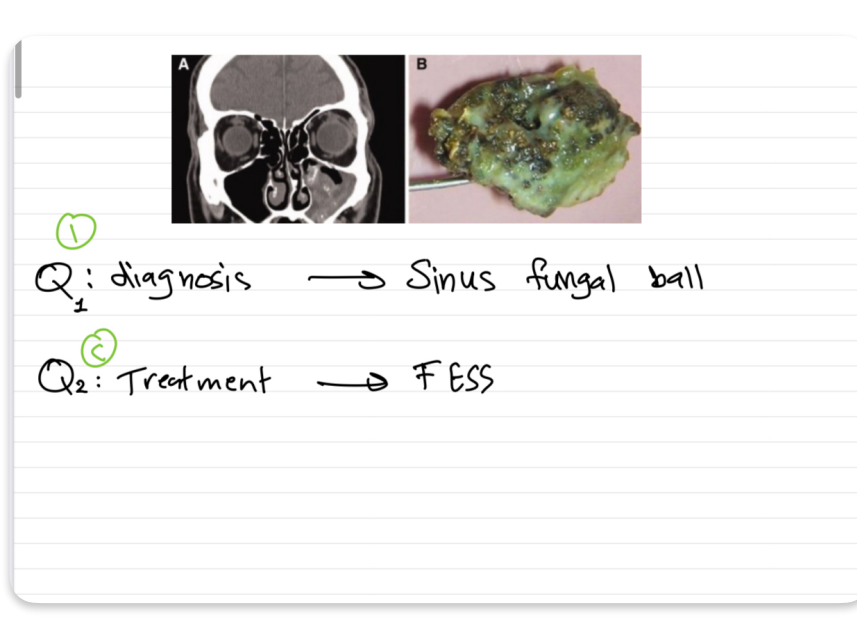
Bedside \_\_\_ ICU

Same site of incision

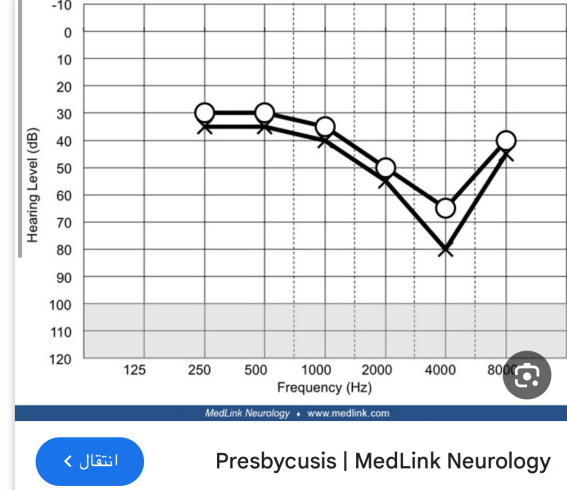
Both need isthmus and thyriod traction

17) +18)

With systemic antifungal!!!



19)



Perspycusis — hearing aid

bilateral SNHL ما كان في جواب ثاني أصح لانها

noise induced المفروض تكون

20) vocal cord polyp. Next step??

Excisionl biopsy