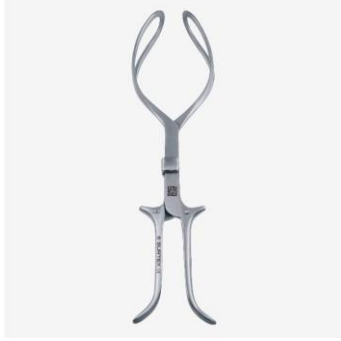
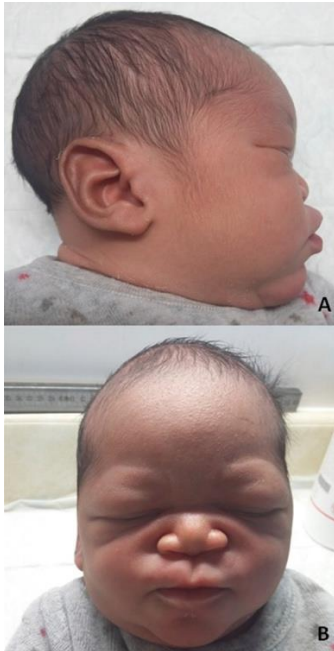


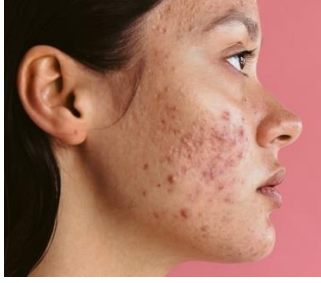- Name of the forceps
- A,B,C each part what is it called
- One indication for this forceps
- Presquities for using a forceps in general (5)
- Mention other kinds of forceps
- Complications (مش متاكدة)



Mother with a prosthetic metallic valve

- What medication is she using
- 4 or 5 other signs will be seen in her neonate
- Write her a management plan and treatment
- في كمان كثير من الأسئلة بس ناسية - preconception advice idk..



A whole station on PCOS (case history)

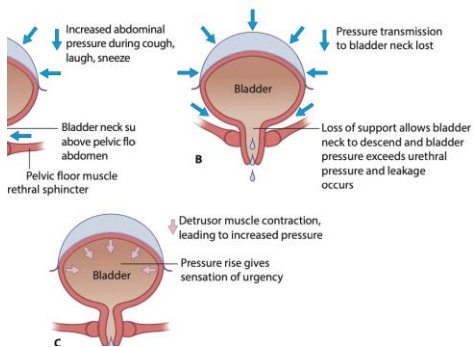
-diagnosis

-One major sign seen in those patients

-management

-متabolic syndrome سؤال عن ال ...

Etc..



-What is Graph A , Graph B

-pathophysiology of graph A

-Other symptoms of graph ... other than mentioned in the case

- medical treatment for graph A

-medical treatments for graph b and one common side effect between the drugs

-surgical treatments of this case (smth like that)

(Q) A pregnant woman with pruritis (a case of cholestasis w/ questions)

الطفل ctg اخر فرعين عن it was late decelerations and what is your next step

(Q) A station of Cervical intraepithelial neoplasia

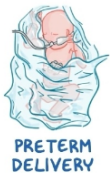Notes

Date 5 / July /2024

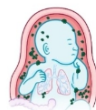Pregnant woman came to your clinic for antenatal visit
Complain of generalized itching

- Most likely diagnosis ;
Intrahepatic cholestasis of pregnancy
- Other lab test that you will order
- Possible complications on the fetus

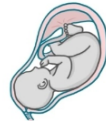INTRAHEPATIC CHOLESTASIS of PREGNANCY (ICP) RELATIVELY UNCOMMON DISEASE ASSOCIATED with POOR FETAL OUTCOMES



PRETERM
DELIVERY



MECONIUM-STAINED
AMNIOTIC FLUID



STILLBIRTH

Lab results ← كان ضايف

ALT ~ 102
AST ~

باضي لزوجهم
Normal

Management:

Antepartum

- Medical management
 - Ursodeoxycholic acid
 - +/- Antihistamines for intense pruritus
 - Corticosteroids for fetal lung maturity if delivery prior to 37 weeks
- Increased antepartum fetal surveillance
- Delivery timing
 - Total bile acids 10-99: Deliver 36 0 / 7 - 39 0 / 7 weeks
 - Total bile acids ≥ 100 : Deliver at 36 0 / 7 weeks

Intrapartum

- Continuous intrapartum fetal heart rate monitoring

- What test would you order for definitive diagnosis?
- What features would help you differentiate it from other differentials?

- Picture of a CTG
- She asked about the type of deceleration:

Late deceleration

- Management :

