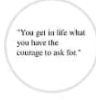

You're in Data Mode ?

Go to Free

← أرشيف هستو ميد

RECENT ACTIVITY



Malak Mht ▶ أرشيف هستو ميد



14 Mar 2018 at 18:53 •

In blood smear .what is the cell with metachromasia property?
Basophilic only

Rania Abdallah Sbieh



Like



Comment



Mohamed Salih Al-Qawaqzeh ▶ أرشيف هستو ميد



14 Mar 2018 at 18:14 •

ادرس تبيض .. لا ترد ع الدكتوره ما تدرس تبيض . ادرس تبيض ..
تبيض ثم سلايد ..

Rania Abdallah Sbieh and 1 other



Like



Comment



Mahmoud Otoom ▶ أرشيف هستو ميد



14 Mar 2018 at 17:22 •

اذا قالت د. فردوس لا تدرسوا التبييض ...
ادرسوه و اتكلوا ع الله لان رح بييجي اسئله منه
و ادرسوا اسئلة المواقع لان بييجي منها
لقد فقعنا في... See more

Yousef E. Al Hijazeen and 1 other

1 Comment



Like



Comment



Thara Hamideh ▶ أرشيف هستو ميد



14 Mar 2018 at 17:00 •

سؤال شو الغلط عن ال cardiac fibers ?

Triad

You're in Data Mode ?

Go to Free

← ارشيف هستو ميد



Mahmoud Otoom ▶ ارشيف هستو ميد



14 Mar 2018 at 17:22 •

اذا قالت د. فردوس لا تدرسوا التبييض ...
ادرسوه و اتكلوا ع الله لان رح بييجي اسئله منه
و ادرسوا اسئلة المواقع لان بييجي منها
لقد فقعننا في الوح
وركزوا على الانزيم ل د. سمير

Yousef E. Al Hijazeen and 1 other

1 Comment



Like



Comment



Thara Hamideh ▶ ارشيف هستو ميد



14 Mar 2018 at 17:00 •

سؤال شو الغلط عن ال cardiac fibers ?

Triad

Rania Abdallah Sbieh



Like



Comment



Thara Hamideh ▶ ارشيف هستو ميد



14 Mar 2018 at 16:41 •

1- شو يلي بتحتوي على large blue granules

basophils

2- من خصائص ال fibrocyte

has oval dark nucleous

3- من خصائص ال smooth muscle

don't have T tubule

4- شو ال wrong match ... See more

Yousef E. Al Hijazeen and Rania Abdallah Sbieh

6 comments



Like



Comment



Mahmoud Otoom ▶ ارشيف هستو ميد



You're in Data Mode ?

Go to Free

← ارشيف هستو ميد



Like



Comment



Thara Hamideh ▶ ارشيف هستو ميد



14 Mar 2018 at 16:41 •

1- شو يلي بتحتوي على large blue granules

👍 basophils

2- من خصائص ال fibrocyte

👍 has oval dark nucleous

3- من خصائص ال smooth muscle

👍 don't have T tubule

4- شو ال wrong match

👍 white muscle – more mitochondria

5- شو يلي يبطن ال goblet gland

👍 simple columnner

6- most numerous in plasma cell

👍 Golgi

7- what's correct about plasma cell

👍 formed from activated B lymphocyte



Yousef E. Al Hijazeen and Rania Abdallah Sbieh

6 comments



Like



Comment



Mahmoud Otoom ▶ ارشيف هستو ميد



14 Mar 2018 at 16:39 •

Correct about smooth muscledont have t tubule



Like



Comment



Mahmoud Otoom ▶ ارشيف هستو ميد



14 Mar 2018 at 16:39 •

سؤال عن مكونات الـ لاكتين

7 comments



Like



Comment

You're in Data Mode ?

Go to Free

← ارشيف هستو ميد



Like



Comment

**Mahmoud Otoom** ▶ ارشيف هستو ميد

14 Mar 2018 at 16:38 •

Compression between red and white muscle....
Red muscles have more mitochondria



Like



Comment

**Mahmoud Otoom** ▶ ارشيف هستو ميد

14 Mar 2018 at 16:37 •

جذب سؤال عن خصائص chondro ..plast and cyte
ركزوا عليها



Like



Comment

**Mahmoud Otoom** ▶ ارشيف هستو ميد

14 Mar 2018 at 16:35 •

كان في سؤال عن ossification ناسيه

6 comments



Like



Comment

**Mahmoud Otoom** ▶ ارشيف هستو ميد

14 Mar 2018 at 16:34 •

Plasma cell....differentiated b cell



1

2 comments



Like



Comment

You're in Data Mode ?

Go to Free

← ارشيف هستو ميد



Mahmoud Otoom ▶ ارشيف هستو ميد



14 Mar 2018 at 16:34 •

Plasma cell....differentiated b cell



1

2 comments



Like



Comment



Mahmoud Otoom ▶ ارشيف هستو ميد



14 Mar 2018 at 16:32 •

Multilobulated cell....neutrophil



Like



Comment



Sukaina Walid Madadha ▶ ارشيف هستو ميد



14 Mar 2018 at 16:32 •

اجا انو شو الفرق بين ال periosteum and endo ??



1

5 comments



Like



Comment



Mahmoud Otoom ▶ ارشيف هستو ميد



14 Mar 2018 at 16:31 •

Contains hydrolytic enzymes....lambda granules



Mohammad Talafha and 1 other



Like



Comment



Mahmoud Otoom ▶ ارشيف هستو ميد



14 Mar 2018 at 16:31 •

You're in Data Mode ?

Go to Free

← ارشيف هستو ميد

اجا انوشو الفرق بين ال periosteum and endo ??



1

5 comments



Like



Comment

**Mahmoud Otoom** ▶ ارشيف هستو ميد

14 Mar 2018 at 16:31 •

Contains hydrolytic enzymes....lambda granules



Mohammad Talafha and 1 other



Like



Comment

**Mahmoud Otoom** ▶ ارشيف هستو ميد

14 Mar 2018 at 16:31 •

Platelets are circumstantial ,discoid,because of.....microtubules



1



Like



Comment

**Mahmoud Otoom** ▶ ارشيف هستو ميد

14 Mar 2018 at 16:29 •

Platelets arefragments of megakaryocyte



Like



Comment

**Mahmoud Otoom** ▶ ارشيف هستو ميد

14 Mar 2018 at 16:29 •

What is the reticulocytes ..

3 comments

You're in Data Mode ?

Go to Free

← ارشيف هستو ميد

**Mahmoud Otoom** ▶ ارشيف هستو ميد

14 Mar 2018 at 16:31 •

Platelets are circumstantial ,discoid,because of.....microtubules



1



Like



Comment

**Mahmoud Otoom** ▶ ارشيف هستو ميد

14 Mar 2018 at 16:29 •

Platelets arefragments of megakaryocyte



Like



Comment

**Mahmoud Otoom** ▶ ارشيف هستو ميد

14 Mar 2018 at 16:29 •

What is the reticulocytes ..

3 comments



Like



Comment

**Mahmoud Otoom** ▶ ارشيف هستو ميد

14 Mar 2018 at 16:28 •

Make slow movement of blood and varicose veinsrouleax formation of blood



Rania Abdallah Sbieh



Like



Comment

**Mahmoud Otoom** ▶ ارشيف هستو ميد

You're in Data Mode ?

Go to Free

← ارشيف هستو ميد

3 comments



Like



Comment

**Mahmoud Otoom** ▶ ارشيف هستو ميد

14 Mar 2018 at 16:28 •

Make slow movement of blood and varicose veinsrouleax formation of blood

Rania Abdallah Sbieh



Like



Comment

**Mahmoud Otoom** ▶ ارشيف هستو ميد

14 Mar 2018 at 16:27 •

Fixed cell...mast cell

2 comments



Like



Comment

**Noor Mahmoud** ▶ ارشيف هستو ميد

14 Mar 2018 at 16:21 •

What is the most abundant organelle in plasma cell :

شو الجواب



Salman Shattara

10 comments



Like



Comment

**Mahmoud Otoom** ▶ ارشيف هستو ميد

14 Mar 2018 at 16:07 •

ركزوا على الانزايم

You're in Data Mode ?

Go to Free

← ارشيف هستو ميد

what is the most abundant organelle in plasma cell .

شو الجواب

😓 Salman Shattara

10 comments



Like



Comment

**Mahmoud Otoom** ▶ ارشيف هستو ميد

14 Mar 2018 at 16:07 • 👤

ركزوا على الانزائم

😓 Salman Shattara



Like



Comment

**Mahmoud Otoom** ▶ ارشيف هستو ميد

14 Mar 2018 at 16:06 • 👤

اجا من الريكورد اسمعوا ريكورد

😓 Salman Shattara



Like



Comment

**Mahmoud Otoom** ▶ ارشيف هستو ميد

14 Mar 2018 at 16:06 • 👤

ما اجا ولا stain

😓 Salman Shattara



Like



Comment

**Mahmoud Otoom** ▶ ارشيف هستو ميد

14 Mar 2018 at 16:05 • 👤

Brown adipose tissue features except...

You're in Data Mode ?

Go to Free

← ارشيف هستو ميد



Like



Comment

**Mahmoud Otoom** ▶ ارشيف هستو ميد

14 Mar 2018 at 16:06 •

ما اجا ولا stain



Salman Shattara



Like



Comment

**Mahmoud Otoom** ▶ ارشيف هستو ميد

14 Mar 2018 at 16:05 •

Brown adipose tissue features except...



Salman Shattara and 1 other



Like



Comment

**Mahmoud Otoom** ▶ ارشيف هستو ميد

14 Mar 2018 at 16:04 •

Fibers present but not apparent in mucoidcollagen 2



Rania Abdallah Sbieh and 2 others



Like



Comment

**Mahmoud Otoom** ▶ ارشيف هستو ميد

14 Mar 2018 at 16:03 •

Highly vascular....loose c.t



Salman Shattara and Mohammad Talafha



Like



Comment

You're in Data Mode ?

Go to Free

← ارشيف هستو ميد



Like



Comment

**Mahmoud Otoom** ▶ ارشيف هستو ميد

14 Mar 2018 at 16:02 •

Reticular cartilage.....collagen 3

Salman Shattara

7 comments



Like



Comment

**Mahmoud Otoom** ▶ ارشيف هستو ميد

14 Mar 2018 at 16:00 •

Flasked shaped for secretionalveolar

Rania Abdallah Sbieh and Salman Shattara



Like



Comment

**Mahmoud Otoom** ▶ ارشيف هستو ميد

14 Mar 2018 at 15:59 •

Goblet cell associated with.....simple columnar epithelium

Rania Abdallah Sbieh and 4 others

2 comments



Like



Comment

**Mahmoud Otoom** ▶ ارشيف هستو ميد

14 Mar 2018 at 15:59 •

One of tissues is not connective.....transitional

Salman Shattara and 2 others



Like



Comment

You're in Data Mode ?

Go to Free

← ارشيف هستو ميد



Like



Comment

**Mahmoud Otoom** ▶ ارشيف هستو ميد

14 Mar 2018 at 15:59 •

One of tissues is not connective.....transitional



Salman Shattara and 2 others



Like



Comment

**Mahmoud Otoom** ▶ ارشيف هستو ميد

14 Mar 2018 at 15:57 •

Epithelium of blood vesselsendothilum



Rania Abdallah Sbieh and 4 others



Like



Comment

**Shahed Maher Kawaleet** ▶ ارشيف هستو ميد

14 Mar 2018 at 15:57 •

اجى عن basophils انه nucleus is covered by granules هيڪ اشي يعنى..

Mucoid doesn't have apparent fibers..

Fibroblasts are not free cells..

Goblet cells are pseudo stratified..

wrong statement— smooth muscles contain t-tubules..

the cartilage that doesn't calcify—in external ear..

osteoblasts secrets acid phosphatase—wrong ... [See more](#)

Salman Shattara and Omar Abdalqader Alrashdan

7 comments



Like



Comment

**Mahmoud Otoom** ▶ ارشيف هستو ميد



14 Mar 2018 at 15:56 •

You're in Data Mode ?

Go to Free

← ارشيف هستو ميد

Goblet cells are pseudo stratified..
 wrong statement— smooth muscles contain t-tubules..
 the cartilage that doesn't calcify—in external ear..
 osteoblasts secrets acid phosphatase—wrong ... See more

  Salman Shattara and Omar Abdalqader Alrashdan

7 comments

 Like

 Comment



Mahmoud Otoom ▶ ارشيف هستو ميد

...

14 Mar 2018 at 15:56 • 

Cover stomach intestine.....simple columnar epithelium

   Salman Shattara and 2 others

 Like

 Comment



Mahmoud Otoom ▶ ارشيف هستو ميد

...

14 Mar 2018 at 15:55 • 

Not calcsify.....elastic fibers in external ear

   Salman Shattara and 3 others

 Like

 Comment



Noor Al-Huda Esam Al-karaki ▶ ارشيف هستو ميد

...

14 Mar 2018 at 15:37 • 

HELLO 🙋

**type of the collagen in reticular ? Type three

**goblet cell? Respiratory + GIT tract

**flask shape ? Simple Alveolar

**in blood smear metacromasia? Basophils

Note# blood smear or blood film they are same

**modified of microtubules? Cilia ... See more

   Salman Shattara and 7 others

You're in Data Mode ?

Go to Free

← أرشيف هستو ميد



Like



Comment



Noor Al-Huda Esam Al-karaki ▶ أرشيف هستو ميد



14 Mar 2018 at 15:37 •

HELLO 🙋

**type of the collagen in reticular ? Type three

**goblet cell? Respiratory + GIT tract

**flask shape ? Simple Aloveolar

**in blood smear metacromasia? Basophils

Note# blood smear or blood film they are same

**modified of microtubules? Cilia

يا رب يكون صح 😊

**discoid shape ? Microtubules in haylomere

بمعنى انه مين يحافظ على الشكل .

**Type of sequamus epithelium in blood.v ? Endotheluum

**In abdominal wall ? Mesothelium

بغض النظر عن السبيلنق 😊

**correct ?

Immature____primary .

**the wrong ?

White fiber____many mitochondria .

**سؤال عن ال goblet cell بأي نوع من جماعة اليبغيليم ، طبعاً شنتنه 😊 بس انه

ملاحظة اجا هيك سؤال

و اجا ترتيب lamina densa and lamina leucina

And reticular

و هالسوالف 😊

خليها ببالكم و هكذا 🙋

**بكررا عذرا على الاخطاء الاملائية ، اعذرونا 😊

Byee 🙋🙋🙋🙋🙋🙋



Salman Shattara and 7 others



Like



Comment



Sukaina Walid Madadha ▶ أرشيف هستو ميد



14 Mar 2018 at 15:19 •

😊 يخوان ادرسو ريكورد مهما تبدلت الآراء



Rania Abdallah Sbieh and 7 others

1 Comment

You're in Data Mode ?

Go to Free

← أرشيف هستو ميد

**the wrong ?

White fiber___many mitochondria .

**سؤال عن ال goblet cell بأي نوع من جماعة اليبثيليم ،طبعا شنصته 😊 بس انه

ملاحظة اجا هيك سؤال

و اجا ترتيب lamina densa and lamina leucina

And reticular

و هالسوالف 😊

خليها ببالكم و هكذا 🙌

**بكررا عذرا على الاخطاء الاملائية ،اعذرونا 😊

Byee 🙌🙌🙌🙌🙌🙌

👍❤️😞 Salman Shattara and 7 others



Like



Comment



Sukaina Walid Madadha ▶ أرشيف هستو ميد



14 Mar 2018 at 15:19 • 👤

😊 يخوان ادرسو ريكورد مهما تبدلت الآراء

😂😞 Rania Abdallah Sbieh and 7 others

1 Comment



Like



Comment