

Data Mode ?

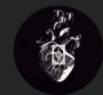Go to Text Only

← ارشيف ميد هستو

Mar 12, 2020 · 🌐

incorrect match?

\*white fiber.....for sustained production of force

 3 Like Comment

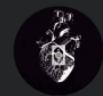ارشيف ميد هستو ▶ عدن محمد

...

Mar 12, 2020 · 🌐

granule in Eosinophils in E. M?

\*granule with crystalloid dense shape

 3 Like Comment

ارشيف ميد هستو ▶ عدن محمد

...

Mar 12, 2020 · 🌐

junction prevent lateral movement of materials  
in adjacent cells?

\*\*zonula occluding

 Respond ▼

...



Data Mode ?

Go to Text Only

← ارشيف ميد هستو



ارشيف ميد هستو ▶ عدن محمد



Mar 12, 2020 · 🌐

C. T in ligament is?  
\*dense regular C. T  
type of C. T that is resisted for tension?  
\*dense regular C. T

Raneem Manasrah and 2 others



Like



Comment



ارشيف ميد هستو ▶ عدن محمد



Mar 12, 2020 · 🌐

which is correct about junctions in cardiac muscle?

\* macula adherents prevent the cell from pulling apart

2



Like



Comment

Respond ▾



Data Mode ?

Go to Text Only

← ارشيف ميد هستو



ارشيف ميد هستو ▶ عدن محمد



Mar 12, 2020 · 🌐

incorrect about smooth muscle?

\*no Z line and actin

فيها أكتين بس ما فيها z line  
لهيك تعتبر غلط

Renad Mawajdeh and 5 others



Like



Comment



ارشيف ميد هستو ▶ عدن محمد



Mar 12, 2020 · 🌐

in correct match?

\*pancreas. is mixed gland

الصح البنكرياس يعتبر mixocrin



Raneem Manasrah and 2 others

2 comments




Like




Comment

Respond ▾




Data Mode [Go to Text Only](#) ارشيف ميد هستو Like Comment

ارشيف ميد هستو ▶ عدن محمد


Mar 12, 2020 · 

which of the following is right about  
Granulomere in platelet??

\*contain ribosomes


 Renad Mawajdeh Like Comment

ارشيف ميد هستو ▶ عدن محمد

Mar 12, 2020 · 

granule secrets hydronic enzyme?!

\* lambda granule in the platelet

 Raneem Manasrah and 5 others Like Comment Respond ▼

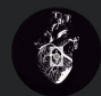Data Mode ?

Go to Text Only

← ارشيف ميد هستو

Like

Comment



ارشيف ميد هستو ▶ عدن محمد



Mar 12, 2020 · 🌐

where u can find a(actin. spectrin. ankyrin)?

الجواب مش حرفي هيك

\*in RBCs for flexibility

Renad Mawajdeh and 2 others

3 comments

Like

Comment



Raghad Amr ▶ ارشيف ميد هستو



Mar 12, 2020 · 🌐

Connective tissue covering a muscle fascicle?

Perimysium

عدن محمد and 3 others

Like

Comment



ارشيف ميد هستو ▶ عدن محمد



Respond ▼



Data Mode ?

Go to Text Only

← ارشيف ميد هستو



ارشيف ميد هستو ▶ عدن محمد



Mar 12, 2020 · 🌐

what is a Echinocytes?!  
crenated RBCs

👍 Renad Mawajdeh and 3 others



Like



Comment



ارشيف ميد هستو ▶ عدن محمد



Mar 12, 2020 · 🌐

immature RBCs?

\*Rectulocytes

👍 Renad Mawajdeh and 4 others



Like



Comment



Hazem Tarawneh ▶ ارشيف ميد هستو



👤 Respond ▼



Data Mode ?

Go to Text Only

← ارشيف ميد هستو



هستو

Mar 12, 2020 · 🌐

1)What is the echinocytes?

مش متأكد من صيغه السؤال  
الجواب crenation

1)what is the reticulocyte?

الصيغه مش متأكد كمان 😂  
الجواب immature RBCs

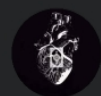بس ركزو كويس 🤔🤔🤔🤔

👀👍❤️ 4

3 comments

👍 Like

💬 Comment



ارشيف ميد هستو ▶ عدن محمد

Mar 12, 2020 · 🌐

Not found in costal cartilage?

- 1 water
- 2 chondriotun sulfate
- 3 keratan sulfate
- 4\* troponin
- 5 hyaluronic acid

👤 Respond ▾

⋮

Data Mode ?

Go to Text Only


← ارشيف ميد هستو

 Like Comment

Hazem Tarawneh ▶ ارشيف ميد




هستو

Mar 12, 2020 · 



Asthmatic reaction determines increase in Eosinophils

 2 Like Comment

Raghad Amr ▶ ارشيف ميد هستو

Mar 12, 2020 · 

Which of these are considered multilobulated?  
Neutrophils and eosinophils

  عدن محمد and 5 others Like Comment

ارشيف ميد هستو ▶ عدن محمد

 Respond ▼



Data Mode ?

Go to Text Only

← ارشيف ميد هستو

 Like Comment


ارشيف ميد هستو ▶ عدن محمد



Mar 12, 2020 · 🌐

which type of these found in blood (normally)  
in big amount? مش حرفي هيك

\*Neutrophils

 Raneem Manasrah and 1 other Like Comment

ارشيف ميد هستو ▶ عدن محمد





Mar 12, 2020 · 🌐

not true cell?!

\*platelet



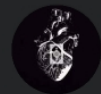 Raneem Manasrah and 5 others Like Comment Respond ▼

Data Mode [Go to Text Only](#) ارشيف ميد هستو Like Comment


Hazem Tarawneh ▶ ارشيف ميد هستو

Mar 12, 2020 · 

One of these is correct for both skeletal muscles and cardiac muscles  
Cardiac muscle has sarcothubules


  Raneem Manasrah and 5 others Like Comment

عدن محمد ▶ ارشيف ميد هستو

Mar 12, 2020 · 

what is differential account?


\*for different type of white cells

 Raneem Manasrah and 1 other Like Comment[Respond](#) 

Data Mode ?

Go to Text Only

← ارشيف ميد هستو



Hazem Tarawneh ▶ ارشيف ميد



هستو

Mar 12, 2020 · 🌐

Barr body is found in  
Neutrophils



1


3 comments



Like



Comment



Hazem Tarawneh ▶ ارشيف ميد



هستو

Mar 12, 2020 · 🌐

What determines the sex  
Barr body in the chromatin of microphage



Anan Mazen Malahmeh and 2 others



Like



Comment



Hazem Tarawneh ▶ ارشيف ميد



Respond ▼




Data Mode ?

Go to Text Only

← ارشيف ميد هستو

Like

Comment



Hazem Tarawneh ▶ ارشيف ميد



هستو

Mar 12, 2020 · 🌐

Goblet cells


pseudostratified epithelium

Raneem Manasrah and 2 others

4 comments

Like

Comment



Hazem Tarawneh ▶ ارشيف ميد



هستو

Mar 12, 2020 · 🌐

ركزو على الدم كثير يعني الاسماء كل خليه بكون الها اسم  
ثاني زي هيك انتو حرين ولا اعلمكو انسو لا تقرو

1 comment

Like

Comment

Respond ▾



Data Mode ?

Go to Text Only

← ارشيف ميد هستو

Like

Comment



ارشيف ميد هستو ▶ عدن محمد



Mar 12, 2020 · 🌐

incorrct is :  
H band lie inside i band

3

Like

Comment



Shukri AlOmari ▶ ارشيف ميد هستو



Mar 12, 2020 · 🌐

Which of the following are multilobular?  
-T-cells, B-cells, and neutrophils  
-Eosinophils and neutrophils  
السؤال حيرني كونه ال Eosinophils هم dilobular  
فحطيت الاولى

Raneem Manasrah and 1 other

13 comments

Like


Comment

Respond ▾




Data Mode [Go to Text Only](#) ارشيف ميد هستو Like Comment

Rand Al-Smadi ▶ ارشيف ميد هستو

Mar 12, 2020 · 

All of the following are present in rib cartilage except?

Troponin 

Hyaluronic acid

Chondroitin aulfate


Keratan sulfate



Raneem Manasrah and 9 others

 Like Comment

Rand Al-Smadi ▶ ارشيف ميد هستو

Mar 12, 2020 · 

Acts like a mast cell in blood circulation?

Basophils 

Raneem Manasrah and 5 others

[Respond](#) 

Data Mode ?

Go to Text Only

← ارشيف ميد هستو



Like



Comment



Rand Al-Smadi ▶ ارشيف ميد هستو



Mar 12, 2020 · 🌐

حدا عنده asthma شو بكون زايد عنده؟  
Eisonophils ✓



Roa'a Ayed Al-zawahreh and 3 others



Like



Comment



Rand Al-Smadi ▶ ارشيف ميد هستو



Mar 12, 2020 · 🌐

Not a true cell?  
Platelets



Joud Zeitoun and 4 others

3 comments



Like



Comment



Dashed Amr ▶ ارشيف ميد هستو



Respond ▾



Data Mode ?

Go to Text Only

← ارشيف ميد هستو



Raghad Amr ▶ ارشيف ميد هستو



Mar 12, 2020 · 🌐

What is (normally) most found in blood films?  
Neutrophils

ما كان في خيار RBC صح؟؟ عشان نسيت الخيارات



Raneem Manasrah and 6 others

1 comment



Like



Comment



Rand Al-Smadi ▶ ارشيف ميد هستو



Mar 12, 2020 · 🌐

Origin of all blood cells?  
Bone marrow



Bara'ah Saleh Alqudah and 7 others



Like



Comment



Raghad Amr ▶ ارشيف ميد هستو



Respond ▾





Data Mode ?

Go to Text Only

← ارشيف ميد هستو



Like



Comment



Raghad Amr ▶ ارشيف ميد هستو



Mar 12, 2020 · 🌐

Where are lysosomal hydrolytic enzymes found in the platelets?

Lambda granules



Raneem Manasrah and 7 others



Like



Comment



ارشيف ميد هستو ▶ يزيد جابر الحمایده



Mar 12, 2020 · 🌐

اقرو كل قواميس اللغة الإنجليزیه عشان تحللو السؤال



Joud Zeitoun and 1 other

5 comments



Like



Comment



Raghad Amr ▶ ارشيف ميد هستو



Respond ▼



Data Mode ?

Go to Text Only

← ارشيف ميد هستو

Like

Comment



Raghad Amr ▶ ارشيف ميد هستو



Mar 12, 2020 · 🌐

Which of the following is true about the granulomere of platelets?

Has ribosomes

👍❤️ محمد عدن and 4 others

Like

Comment



Raghad Amr ▶ ارشيف ميد هستو



Mar 12, 2020 · 🌐

Immature RBCs with a basophilic cytoplasm are called?

Reticulocytes ✓

Reticular cells

👍❤️ Raneem Manasrah and 5 others

Like

Comment

Respond ▾



Data Mode ?

Go to Text Only

← ارشيف ميد هستو

Like

Comment



Raghad Amr ▶ ارشيف ميد هستو



Mar 12, 2020 · 🌐

Echinocytes are also known as?

مش متأكدة من صيغة السؤال

Crenated RBCs

👍❤️ Roa'a Ayed Al-zawahreh and 4 others

Like

Comment



Mohammed Eyad ▶ ارشيف ميد هستو



هستو

Mar 12, 2020 · 🌐

كان في سؤال عن multilobulated بس مش متذكر

الصيغه شو كان الجواب ؟

5 comments

Like

Comment

Respond ▾




Data Mode 

Go to Text Only

 ارشيف ميد هستو Like Comment


Raghad Amr ▶ ارشيف ميد هستو

Mar 12, 2020 · 

Actin, spectrin and ankyrin are?  
Subplasmalemmal cytoskeleton

  Joud Zeitoun and 7 others Like Comment

Raghad Amr ▶ ارشيف ميد هستو

Mar 12, 2020 · 

Differential count is used for?  
Different types of white blood cells

  Joud Zeitoun and 8 others Like Comment

Sara Almasri ▶ ارشيف ميد هستو

 Respond ▾

Data Mode ?

Go to Text Only

← ارشيف ميد هستو



Mar 12, 2020 · 🌐

1) the most common type of luekucyte ?

- Neutrophile ✓

بتحس السؤال هدية 😂

2) one of the following is correct for both skeletal and cardiac muscles ?

- the level of Z line

- skeletal is diad

- cardiac is triad

- cardiac has sarcotubules ✓

الخيارات مش حرفيا هيك بس حطيت معناهم

👍 Joud Zeitoon and 2 others

8 comments



Like



Comment



Rand Al-Smadi ▶ ارشيف ميد هستو ...

Mar 12, 2020 · 🌐

كان في سؤال من نوعية

which of the following correct

المهم جوابه كان

Myosin has a head and a tail



5

Respond ▾



Data Mode ?

Go to Text Only

← ارشيف ميد هستو



Raghad Amr ▶ ارشيف ميد هستو



Mar 12, 2020 · 🌐

Which of these tissue can withstand tensile stress?

Dense regular

Adipose

Reticular

Elastic

مش متأكدة من الجواب بس انا اخترت اول خيار



Bara'ah Saleh Alqudah and 3 others 4 comments

👍 Like

💬 Comment



Rand Al-Smadi ▶ ارشيف ميد هستو



Mar 12, 2020 · 🌐

Incorrect about smooth muscles?

No actin and no z-line ✓

لانه عندهم اكتين



Joud Zeitoun and 3 others

2 comments

👤 Respond ▾



Data Mode ?

Go to Text Only

← ارشيف ميد هستو

Like

Comment



Raghad Amr ▶ ارشيف ميد هستو



Mar 12, 2020 · 🌐

Ligaments are made of?  
Dense regular connective tissue

👍❤️ Joud Zeitoun and 6 others

Like

Comment



Raghad Amr ▶ ارشيف ميد هستو



Mar 12, 2020 · 🌐

Which of these forms antibodies?  
B lymphocytes

لو كان في خيار plasma cells بكون هو الاصح

+كان في سؤال انه من وين بتيجي ال plasma cells ولا  
بتهيالي؟

👍❤️ Bara'ah Saleh Alqudah and 5 others 4 comments

Respond ▾



Data Mode ?

Go to Text Only

← ارشيف ميد هستو



Rand Al-Smadi ▶ ارشيف ميد هستو



Mar 12, 2020 · 🌐

بشكل عام ما اجا اسئله على الارقام يعني لا تركزوا عليهم  
كثير  
اعرفوا مين اكثر ومين اقل بس لا تحفظوا كل الارقام  
عالفاضي 😂



Raneem Manasrah and 2 others

1 comment



Like



Comment



Rand Al-Smadi ▶ ارشيف ميد هستو



Mar 12, 2020 · 🌐

What bests describe appositional growth of  
cartilage?

Fibroblasts change to chondroblast ✓

Chondrocyte form extra matrix

Chondoblast form extra matrix



2

2 comments

Respond ▾






Data Mode ?

Go to Text Only

← ارشيف ميد هستو

 Like Comment

Raghad Amr ▶ ارشيف ميد هستو

Mar 12, 2020 · 


Macrophage found in tissue is called  
Histiocytes

 5

3 comments

 Like Comment


Raghad Amr ▶ ارشيف ميد هستو

Mar 12, 2020 · 

Sudan stain is used for?  
Fat

 4 Like Comment

Raghad Amr ▶ ارشيف ميد هستو

Mar 12, 2020 ·  Respond ▼

Data Mode ?

Go to Text Only

← ارشيف ميد هستو



Raghad Amr ▶ ارشيف ميد هستو



Mar 12, 2020 · 🌐

Most common cell in connective tissue?  
Fibroblasts


👍❤️ Bara'ah Saleh Alqudah and 6 others



Like



Comment



Rand Al-Smadi ▶ ارشيف ميد هستو



Mar 12, 2020 · 🌐

What feature of epithelium is protective?

Stratification ✓

Brush border

Microvilli

👍 Raneem Manasrah and 3 others

7 comments



Like



Comment



Rand Al-Smadi ▶ ارشيف ميد هستو



Respond ▾



Data Mode ?

Go to Text Only

← ارشيف ميد هستو

Mar 12, 2020 · 🌐

Which of the following WBCs has specific granules that have low affinity to dyes and can kill bacteria?

Neutrophils ✓

Basophils

Eisonophils

Platelets

Lymphocyte

👍 Raneem Manasrah

7 comments

👍 Like

💬 Comment



Raghad Amr ▶ ارشيف ميد هستو

⋮

Mar 12, 2020 · 🌐

What is the first step following secretion from cells in Collagen synthesis?

Removal of non helical chains

هاد الموضوع الدكتور ما دقت عليه بالمحاضرة، فادرسوا الصورة اللي موجودة بالاسلايد كثير منيح

👍 Respond ▼

⋮



Data Mode ?

Go to Text Only

← ارشيف ميد هستو



Raghad Amr ▶ ارشيف ميد هستو



Mar 12, 2020 · 🌐

Which of the following is not found in the ground substance?

Collagen bundles ✓

Fibronectin

GAGs

Hyaluronic acid

Proteoglycans



Bara'ah Saleh Alqudah and 7 others



Like



Comment



Raghad Amr ▶ ارشيف ميد هستو



Mar 12, 2020 · 🌐

What prevents the passage of molecules to the underlying tissues between adjacent epithelial cells?

(ناسية صيغة السؤال بس المهم الفكرة)

Zonula occludens



Bara'ah Saleh Alqudah and 3 others

Respond ▾



Data Mode ?

Go to Text Only

← ارشيف ميد هستو

 Like Comment



Raghad Amr ▶ ارشيف ميد هستو



Mar 12, 2020 · 🌐

Which of the following is a function of the basement membrane?

Molecular filtration

  Bara'ah Saleh Alqudah and 7 others Like Comment

Raghad Amr ▶ ارشيف ميد هستو



Mar 12, 2020 · 🌐

The taste buds of the tongue are?

Neuro-epithelium

  Renad Mawajdeh and 8 others

2 comments

 Like Comment Respond ▼

Data Mode ?

Go to Text Only

← ارشيف ميد هستو

Like

Comment



Raghad Amr ▶ ارشيف ميد هستو



Mar 12, 2020 · 🌐

What type of epithelium is found in body openings and has a protective function?  
Stratified epithelium



Renad Mawajdeh and 6 others

2 comments

Like

Comment



Rahaf Ababneh ▶ ارشيف ميد هستو



Mar 12, 2020 · 🌐

\_في سؤال عن Eosinophils  
\_جوابو كان rER  
\_تقريباً قريب من هاي الصيغه

Which of these cells is the most in white blood cells?  
Neutrophils الجواب هو

3

Like


Comment

Respond ▾





Data Mode [Go to Text Only](#) ارشيف ميد هستو


Raghad Amr ▶ ارشيف ميد هستو

Mar 12, 2020 · 



Transitional epithelium is?  
A special type of stratified epithelium

  Naba Jehad and 4 others Like Comment

Raghad Amr ▶ ارشيف ميد هستو

Mar 12, 2020 · 

Simple squamous epithelial line all of the following except?  
Bowman's capsule  
Lung alveoli  
Kidney tubules ✓  
Blood vessels  
Lymph vessels

  Renad Mawajdeh and 7 others Like Comment[Respond](#) 

Data Mode ?

Go to Text Only

← ارشيف ميد هستو

Like

Comment



Raghad Amr ▶ ارشيف ميد هستو



Mar 12, 2020 · 🌐

Goblet cells are usually associated with?  
Pseudostratified epithelial ✓  
Stratified columnar  
Simple squamous  
Simple cuboidal

❤️😭 Bara'ah Saleh Alqudah and 4 others 2 comments

Like

Comment



Raghad Amr ▶ ارشيف ميد هستو



Mar 12, 2020 · 🌐

Which of the following is used to classify  
epithelial tissue?  
Number of layers

👍❤️😭 Renad Mawajdeh and 8 others

Like

Comment

Respond ▾





Data Mode ?

Go to Text Only

← ارشيف ميد هستو

Like

Comment



Raghad Amr ▶ ارشيف ميد هستو



Mar 12, 2020 · 🌐

Which of the following is true about epithelial tissue?

Can regenerate



Bara'ah Saleh Alqudah and 10 others

1 comment

Like

Comment



Rahaf Ababneh ▶ ارشيف ميد هستو



Mar 12, 2020 · 🌐

فردوس = تبيض

ايمن = ارشيف وحرقي من لسلايد



Rand Al-Smadi and Omyma Anwar

13 comments

Like

Comment



Raghad Amr ▶ ارشيف ميد هستو



Respond ▾



Data Mode ?

Go to Text Only

← ارشيف ميد هستو



Raghad Amr ▶ ارشيف ميد هستو



Mar 12, 2020 · 🌐

An asthmatic patient would have an increased number of what type of cells when examining the blood film?

Eosinophil



Renad Mawajdeh and 5 others

4 comments



Like



Comment



Raghad Amr ▶ ارشيف ميد هستو



Mar 12, 2020 · 🌐

A clinical implication of MHC is?

Tissue transplantation



Renad Mawajdeh and 6 others

15 comments



Like



Comment



ارشيف ميد هستو ▶ احمد الكعبي



Respond ▾




Data Mode 

Go to Text Only

 ارشيف ميد هستو

ارشيف ميد هستو ▶ احمد الكعبي

Mar 12, 2020 · 

Which of these is stained by metachromasia and contains granules ?

Mast cells



Renad Mawajdeh and 3 others

2 comments




Like



Comment



Raghad Amr ▶ ارشيف ميد هستو

Mar 12, 2020 · 

Sex can be determined by examining a blood film from?

Barr body near the nucleus of microphage ✓

(microphage is another name for neutrophils)



Roa'a Ayed Al-zawahreh and 7 others

4 comments



Like



Comment

 Respond ▾

Data Mode ?

Go to Text Only

← ارشيف ميد هستو



Raghad Amr ▶ ارشيف ميد هستو



Mar 12, 2020 · 🌐

Which of these is not a cell polarity adaptation?

Glycocalyx ✓

Microvilli

Cilia



Renad Mawajdeh and 7 others

4 comments



Like



Comment



Abdalfatah Mohammad ▶ ارشيف



ميد هستو

Mar 12, 2020 · 🌐

كان سؤال عن ال asthma patient

جوابه. eosinophils cell



Roa'a Ayed Al-zawahreh and 4 others

1 comment



Like



Comment

Respond ▾



Data Mode ?

Go to Text Only

← ارشيف ميد هستو



Like



Comment



Raghad Amr ▶ ارشيف ميد هستو



Mar 12, 2020 · 🌐

What happens in apocrine secretion? (مش  
حرفي)

The apex of the cells is lost with the secretion



Renad Mawajdeh and 9 others



Like



Comment



Raghad Amr ▶ ارشيف ميد هستو



Mar 12, 2020 · 🌐

What is the adaptation of the Epididymis?  
Stereocillia



Joud Zeitoun and 12 others



Like



Comment



Sara Ibrahim Al Sarairah ▶ ارشيف



Respond ▾



Data Mode ?

Go to Text Only

← ارشيف ميد هستو



Like



Comment



Sara Ibrahim Al Sarairah ▶ ارشيف



ميد هستو

Mar 12, 2020 · 🌐

ابصموا ارشيف ورید ❤️👩



Renad Mawajdeh and 2 others


5 comments



Like



Comment



Hazem Tarawneh ▶ ارشيف ميد



هستو

Mar 12, 2020 · 🌐

نص الاسئله من الريكورد ومن غرب القريه ديرو بالكو  
يعني لا تخلو زاويه ولا قرنه الا لما تقروها



1



Like



Comment


Respond ▾



Data Mode ?

Go to Text Only

← ارشيف ميد هستو



Diana F. Abushehab ▶ ارشيف ميد ...

هستو

Mar 12, 2020 · 🌐

كيف دكتور ايمن مع a????? 🤔💔

4 comments



Like



Comment



Sara Almasri ▶ ارشيف ميد هستو ...

Mar 12, 2020 · 🌐

- 1) the correct answer about microvillai ?
  - make a wide area for absorption
- 2) the incorrect matched :
  - elastin cartilage - ossifi with age
- 3) the mast cell of the blood is :
  - basophile



Naba Jihad and 6 others

2 comments



Like




Comment

Respond ▾




Data Mode 


Go to Text Only

 ارشيف ميد هستو Like Comment

Sara Almasri ▶ ارشيف ميد هستو

Mar 12, 2020 · 

Myoepithelial has all of the following except :  
- has many rER


 Renad Mawajdeh and 5 others



2 comments

 Like Comment

Sara Almasri ▶ ارشيف ميد هستو

Mar 12, 2020 · 

The type of gland due to prsesnce of ducts :  
- endocrine , exocrine , mixed  
- unicellular , multicellular  
- tubular , alveolar , tubulualveolar  
- no answer is correct 

  Naba Jehad and 4 others

22 comments

 Like Comment Respond ▼