

QUIZ TIME

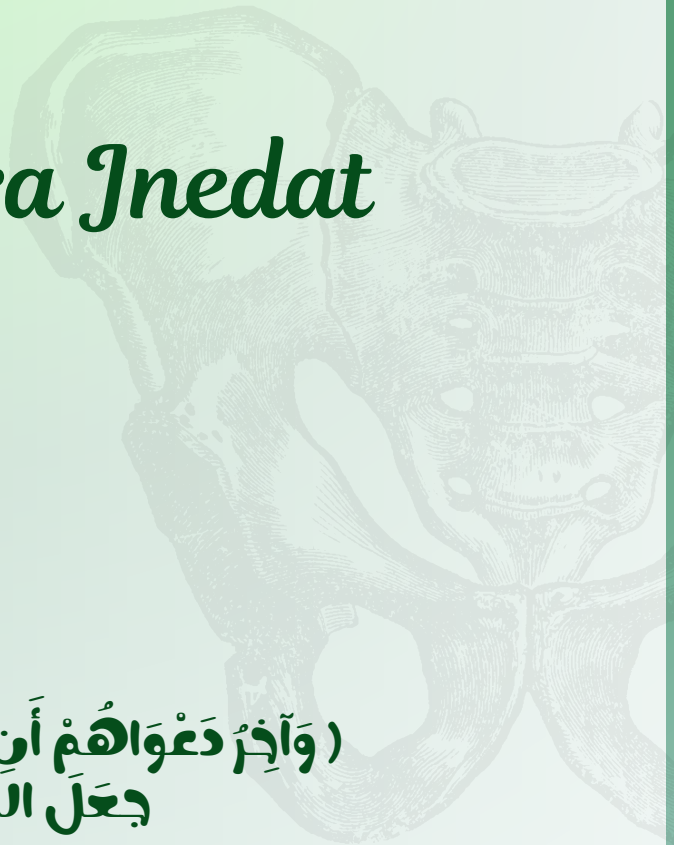
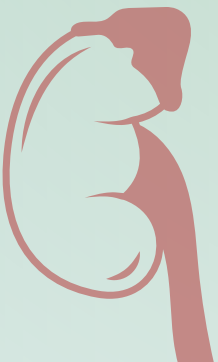
ARCHIVE

Subject:

Embryo

Done by : Yara Inedat

♥ (وَآخِرُ دَعْوَاهُمْ أَنِ الْحَمْدُ لِلَّهِ رَبِّ الْعَالَمِينَ)
♥ جَعَلَ اللَّهُ الْخِتَامَ مِسْكَ .



Trigone of urinary bladder is developed from? a. Mesonephric duct (1

- b. Cloaca
- c. Pronephric duct
- d. Urachus
- e. Metanephric duct

ans: a

?All of the followings are types of hypospadias except (2

- a. Glandular hypospadias
- b. Hypospadias with ectopia vesica
- c. Scrotal hypospadias
- d. Penile hypospadias
- e. Complete hypospadias

ans: b

?The pronephric kidney is developed from

- a. Cranial part of intermediate mesoderm
- b. Caudal part middle mesoderm
- c. Middle part intermediate mesoderm
- d. Cranial part of middle mesoderm
- e. Caudal part of intermediate mesoderm

ans: a

?Failure of obliteration of the urachus leading to (4

- a. Urachal cyst
- b. Urachal diverticulum
- c. Urachal fistula
- d. Median umbilical ligament
- e. Urachal sinus

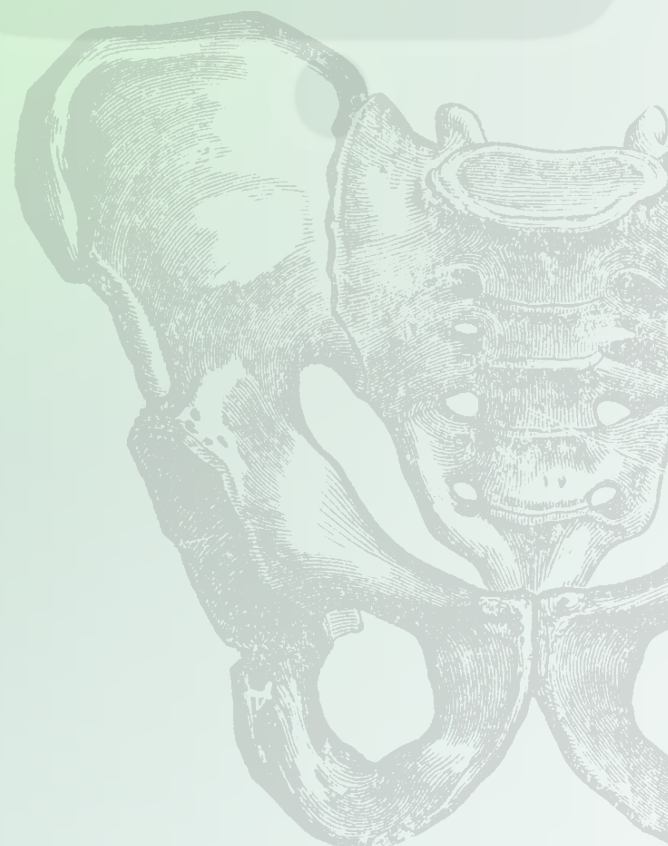
ans: c

?What are the main cause of the epispadias (5

- a. Failure in fusion of the genital groove
- b. Genital tubercle is caudal to the urogenital membrane
- c. Failure of the formation of the genital tubercle
- d. Failure in fusion of the urethral groove
- e. Genital tubercle is cranial to the urogenital membrane

ans: d

Lec 1&2



6)) **Rosette Shaped Kidney is formed due to?**

- a- Fusion of the upper poles of both kidneys
- b. Fusion of the hilum of both kidneys
- c. Fusion of the lower poles of both kidneys
- d. Failure of ascending by inferior mesenteric artery
- e. Fusion of the lower and upper poles of both kidneys

ans: e

?The proximal pans of the allantois gives (7

- a. Tngone of the urinary bladder
- b. Apex of the urinary bladder
- c. Membranous urethra
- d. Most of the urinary bladder
- e. Penile urethra

ans: b

?The mesonephric duct gives all of the followings in male except 😎

- a. Epididymis
- b. Seminal vesicle
- c. Paradidymis
- d. Ejaculatory duct
- e. Vas deferens

ans: c

?Failure of urorectal septum in the male leading to (9

- a. Urachal fistula
- b. Vesicovaginal fistula
- c. Anal fistula
- d. Rectovesical fistula
- e. Vaginal fistula

ans: d

Lec 1&2



المطب والجراحة
للحديقة



Which of the following congenital -
?anomalies for hymen diagnosed lately

:Select one

- A- Semilunar
- B- Cribriform
- C- Imperforate
- D- Annular
- E- Septate

ans:C

?Uterus with 2 bodies, 2 cervices, and double vagina-

- A- Uterus didelphys
- B- Uterus bicornis bicolis

ans:A

?All of the followings are male genital system except (

- a. Epididymis
- b. Vas deference
- c. Vasa efferentia
- d. Rete testis
- e. Paroophoron

ans:E

Lec 4



ولا تكلني إلى نفسي طرفه عينٍ؛ فلولا معيتك لضاع عني الطريق ،
ولولا توفيقك ما وجدت الرفيق ، ولولا رضاك عني لما خطوت خطوةً
واحدةً !

ياربُّ،

هيء لي من أمري رَشْدًا ، ولا تُرهقني من أمري عُسرًا ،

و أصلح لي شأني كلّه ، و أغفر لي ذنبي دقّه و جلّه ،

و أدخلني برحمتك في عبادك الصّالحين ♥ ..

• سمر إسماعيل.