



**Osteoporosis:** A BMD greater than 2.5 standard deviations from the normal (T score less than or equal to -2.5) defines osteoporosis.

1 comment



Like



Comment



محمود برکات

31 May 2022 ·



all the following are bone scan indications except:

Fractures

Paget's disease

Malignancies

Infection

Prolapsed disc



1



Like



Comment



محمود برکات

31 May 2022 ·



all the following are contraindications for thyroid scan except

-Patient on thyroxine 50mg

-Patient taking amiodarone


-Pregnant women

-Breastfeeding women

-Acute thyroiditis attack



1



Like



Comment



محمود برکات



Respond





محمود بركات

31 May 2022 · 📷



Which of the following is the most common cause of bone sclerotic metastasis

Breast

Prostate ←

Lung

Kidney

Lymphoma



1



Like



Comment



محمود بركات

31 May 2022 · 📷



سؤال على هذا

## Findings

- **Normal:** A bone BMD is considered normal if the T-score is within 1 standard deviation of the normal young adult value. Thus a T-score  $> -1$  is considered a normal result.
- **Osteopenia (Low bone mass):** A BMD defines osteopenia as a T-score between  $-1$  and  $-2.5$ . This signifies an increased fracture risk but does not meet the criteria for osteoporosis.
- **Osteoporosis:** A BMD greater than 2.5 standard deviations from the normal (T score less than or equal to  $-2.5$ ) defines osteoporosis.

1 comment



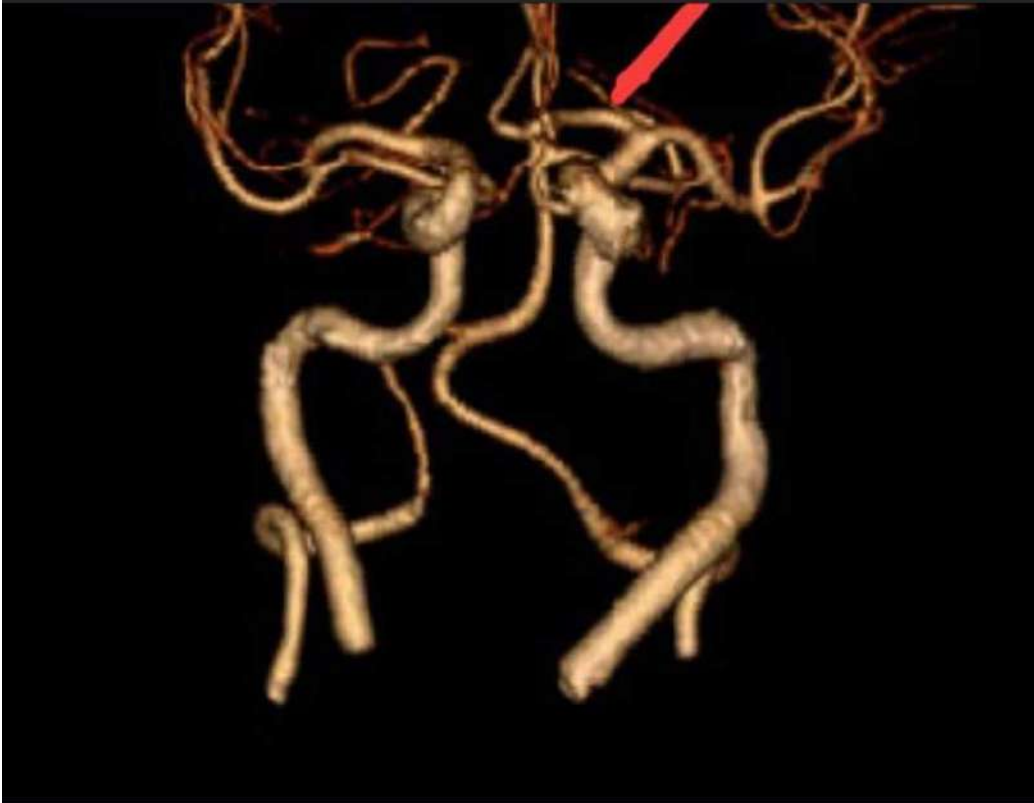Like



Comment

Respond ▼





2

3 comments



Like



Comment



محمود برکات

31 May 2022 ·



All of the following are correct about isotopes except:

- the same chemical properties
- the same atomic number
- different number of neutrons
- different mass numbers
- They have no clinical use

1



Like



Comment

Respond





7 COMMENTS



Like



Comment

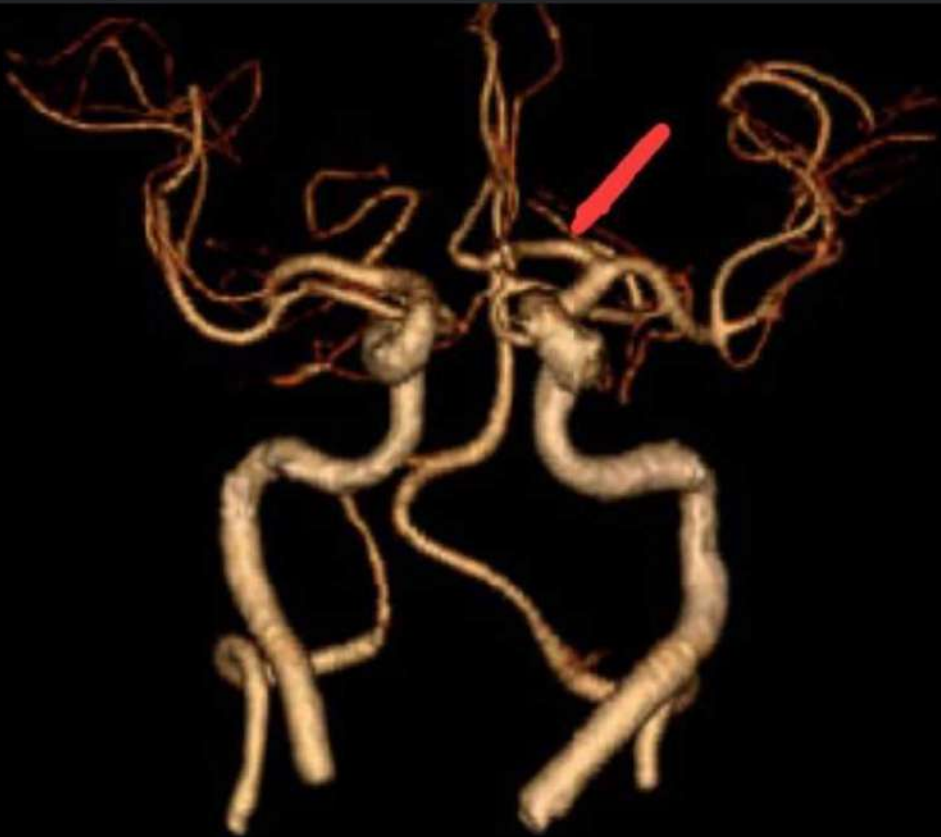


فاطمة هشام



31 May 2022 · 🌐

جابت صورة CTA reconstruction وحاطة عدة أسهم وبدها الخطأ  
أحد الأسهم لونه رمادي كان محل اللي بالصورة وعنده Left MCA  
على ما أعتقد



2

3 comments



Like



Comment



محمد بكات



Respond ▼





Like

Comment



فاطمة هشام

31 May 2022 ·



Female patient with acute central abdominal pain and repeated vomiting. All should be done except:  
Chest X-ray with supine position?

حدا متذكر خيارات السؤال شو كانت؟

4 comments

Like

Comment

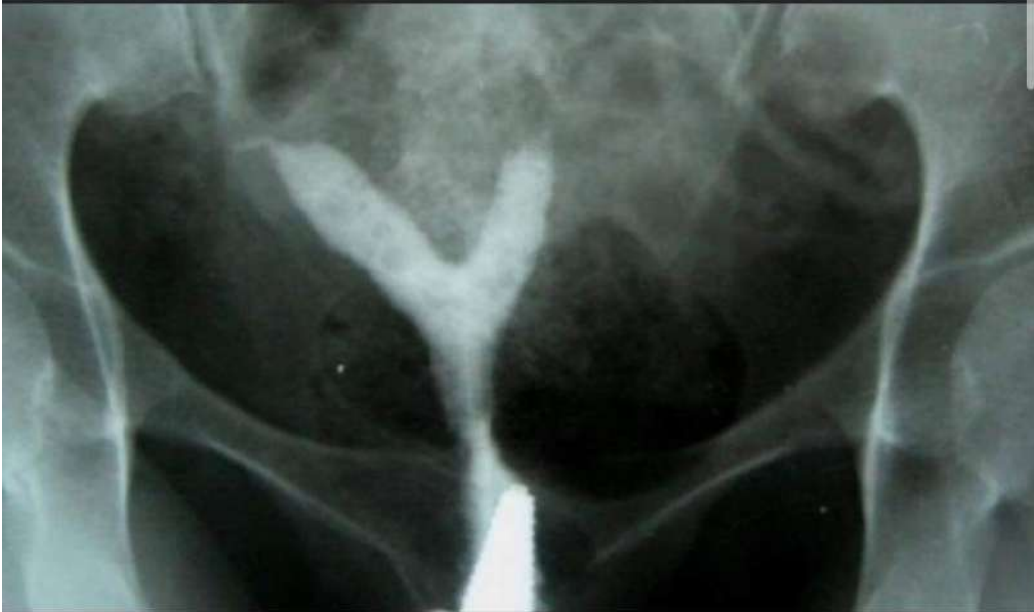

فاطمة هشام

31 May 2022 ·



Bicornuate uterus



7 comments

Like

Comment

Respond ▼





Like



Comment



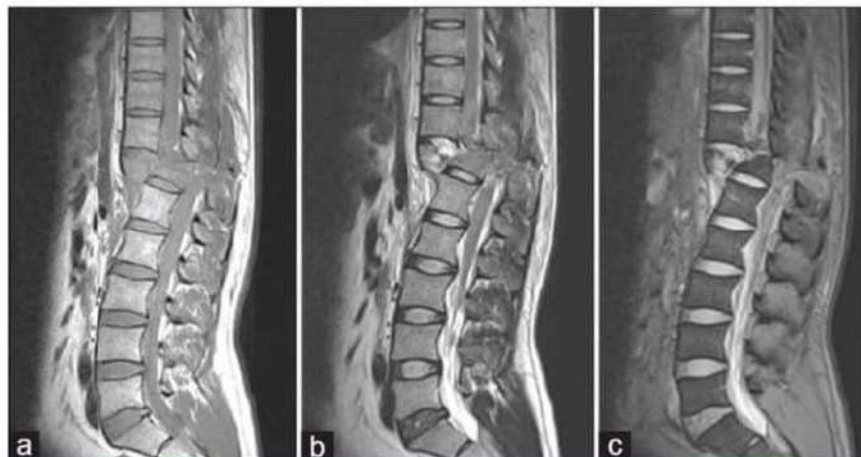Laith F Najada

31 May 2022 · 🌐



- The largest tarsal bone : calcaneus
- Ultrasound of renal cell carcinoma
- CT scan of kidney stone
- MRI of spine زي اللي بالصورة :  
الغلط كان انه الكسر عند L2/L3
- No needed for bone scan: prolapse of disk

Figure 1: Sagittal T1-weighted (a), T2-weighted (b), and gradient echo (c) images showing comminuted fracture of D12 vertebral body with posterior translation. There is complete transection of distal thoracic cord at this level with blooming on gradient echo sequence, representing cord hemorrhage



4 comments



Like



Comment



فاطمة هشام

31 May 2022 · 🌐



Respond ▼



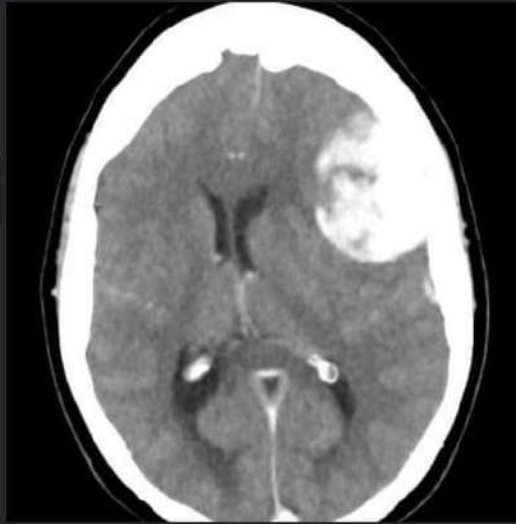

Laith F Najada

31 May 2022 · 📷



Brain tissue



Like



Comment



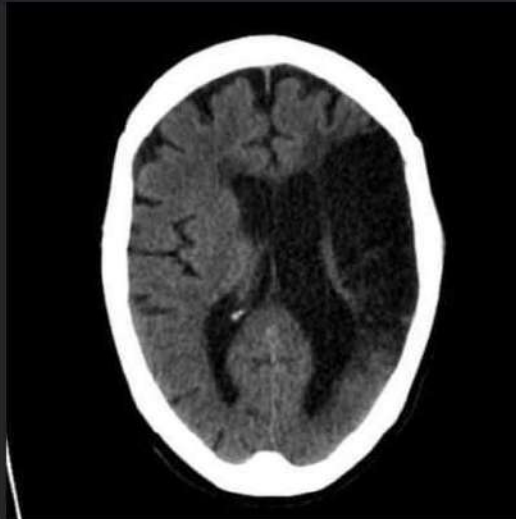
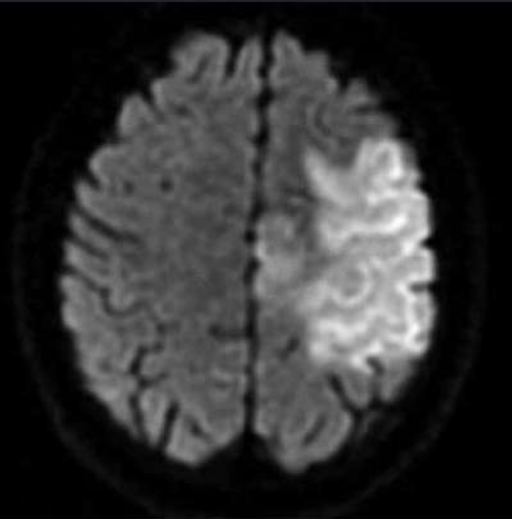
Laith F Najada

31 May 2022 · 📷



Left parietal lobe infarction

مش نفس الصور بس تشبهها



1

Respond





Like

Comment

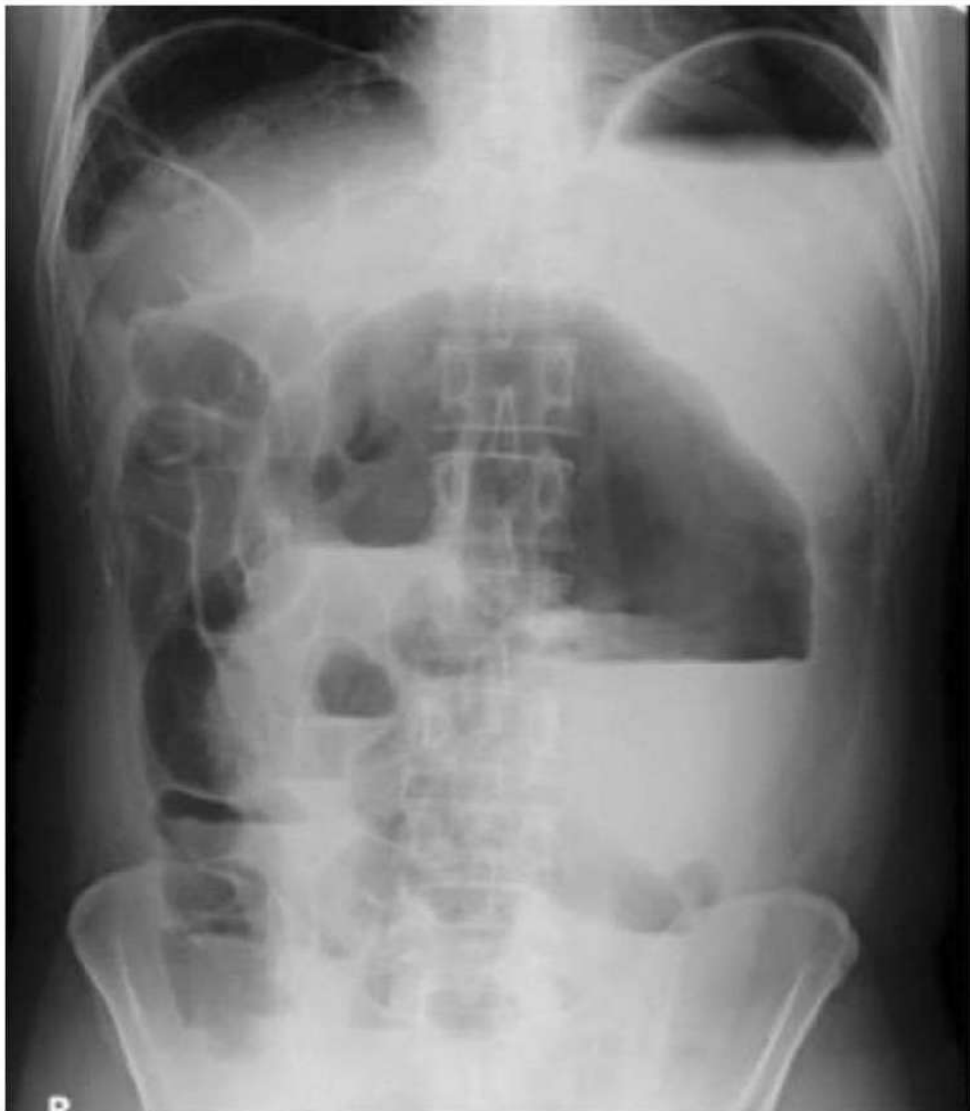**Laith F Najada**

31 May 2022 ·



-Small intestinal obstruction, one is false:  
Diameter is 9cm

-one is true regarding this image:  
Multiple air fluid level ( كانت مكتوبة fluid fluid level)



1

Respond ▾







Sondos Ziyad Alabbadi

31 May 2022 · 📷



Most common cause of pneumothorax?

Chest trauma or injury ✓



Like



Comment



Sondos Ziyad Alabbadi

31 May 2022 · 📷



Anterior mediastinal masses, False?

-lymphoma

-schwannoma ✓



Like



Comment




Sondos Ziyad Alabbadi

31 May 2022 · 📷



The largest of the tarsal bones is?  
Calcaneus 😊



Like



Comment



Laith F Naiada



Respond ▼





Supine abdominal x-ray demonstrates a large pneumoperitoneum which outlines the falciform ligament giving the classical appearances of football sign and falciform ligament sign.



Like



Comment

**Sondos Ziyad Alabbadi**

31 May 2022 · 📷

Air bronchogram commonly?

-pneumonia ✓

First sign of degenerative disk disease?

-osteophytes

-...

5 comments



Like



Comment

**Sondos Ziyad Alabbadi**

31 May 2022 · 📷

Most common cause of pneumothorax?

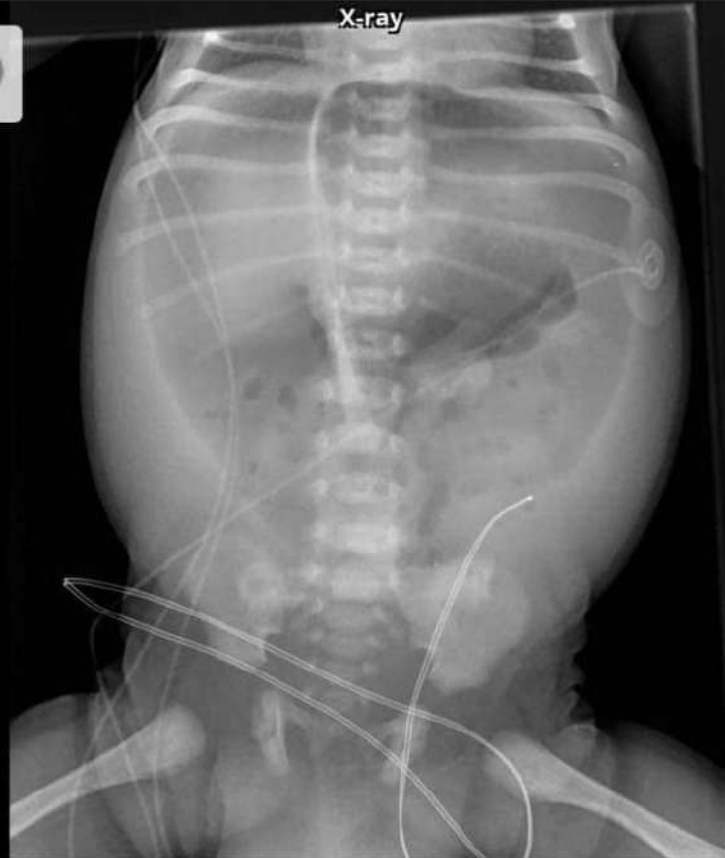Chest trauma or injury ✓

Respond ▼



**Izzat Ababneh**

31 May 2022 · 📷



Frontal

Supine abdominal x-ray demonstrates a large pneumoperitoneum which outlines the falciform ligament giving the classical appearances of football sign and falciform ligament sign.



Like



Comment

**Respond** ▼



-Acute thyroiditis attack

1

Like

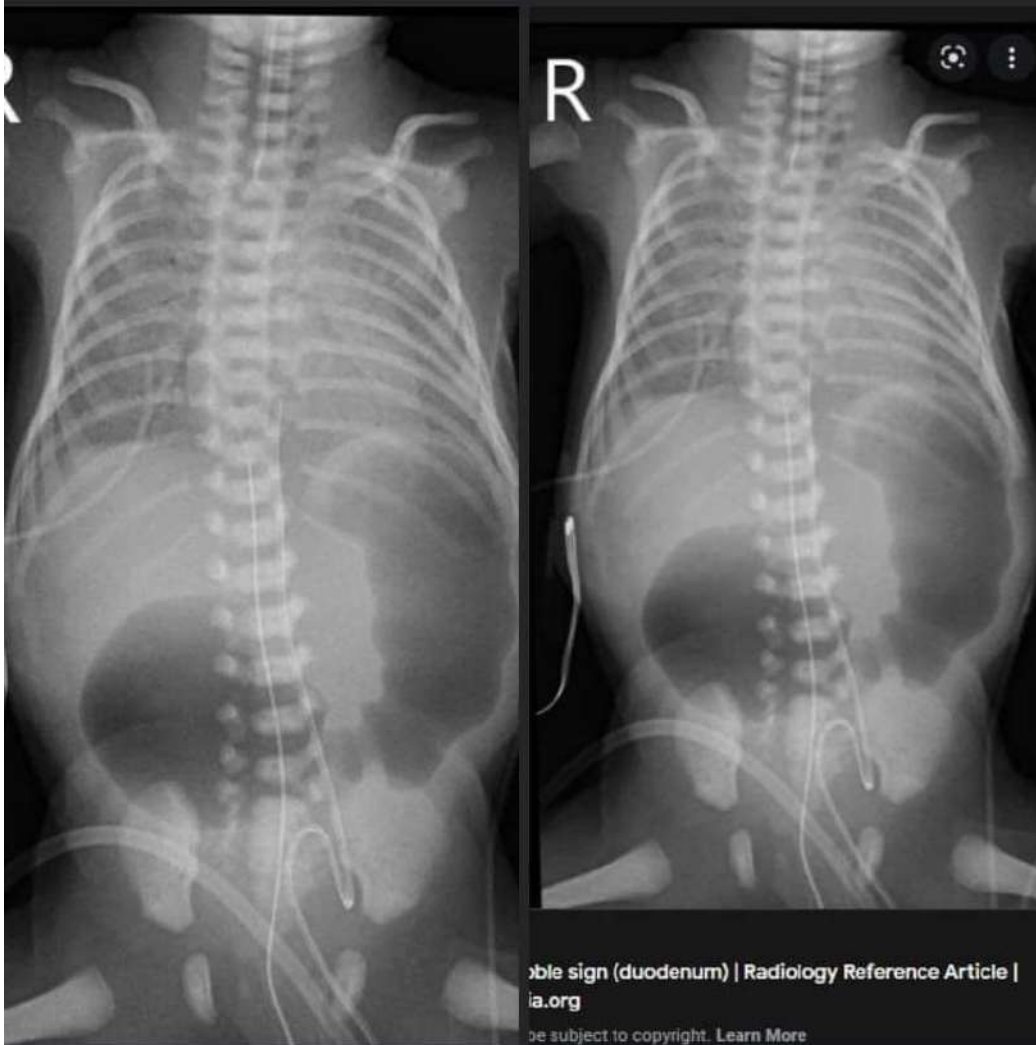
Comment



محمود بركات

31 May 2022

تعديل هاي الصورة



9 comments

Like

Comment

Respond

