


ARCHIVE ANATOMY

Lab  أثر

DONE BY:

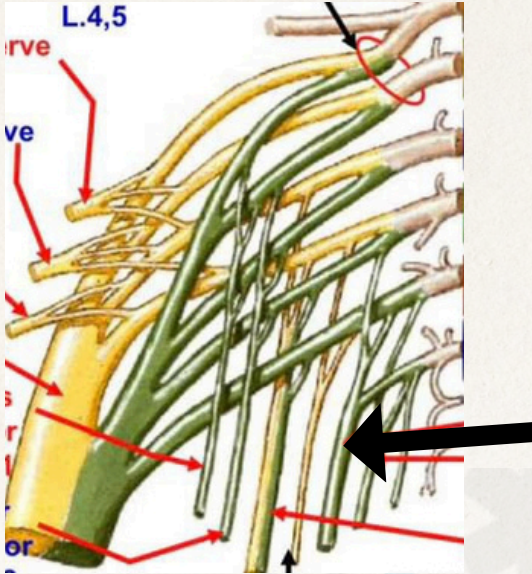
شاهد الأيوبين

ليان حسام



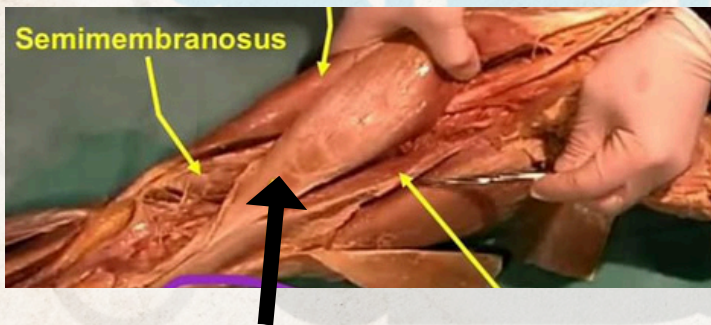

الطب والجراحة
لجنة

1- what is the pointed structure :



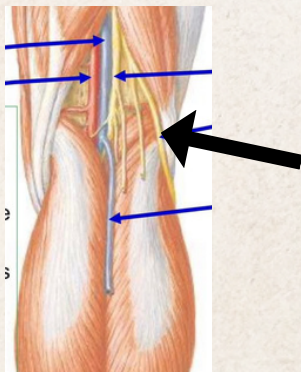
pudendal nerve

2- what is the pointed structure :

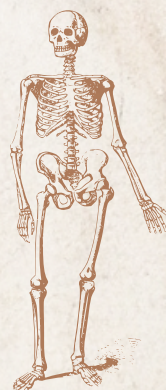


long head of biceps

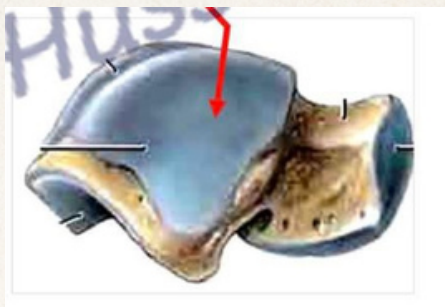3- what is the pointed structure :



Common peroneal nerve

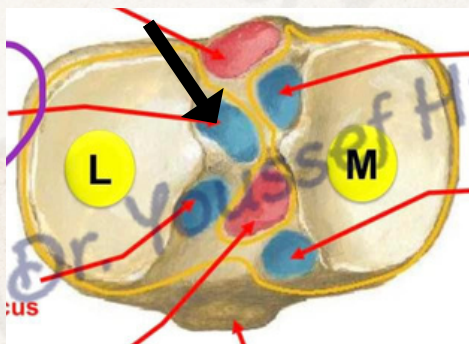


4- what is the pointed structure :



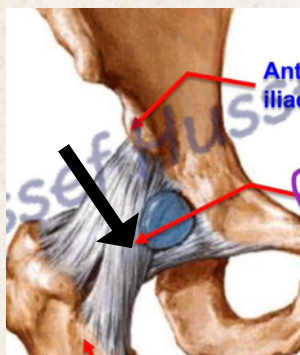
Triangle shape articulates with lateral malleolus

5- what is the pointed structure :

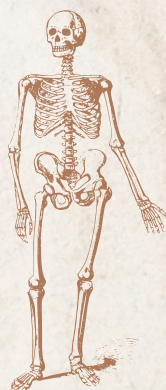


posterior horn of lateral meniscus

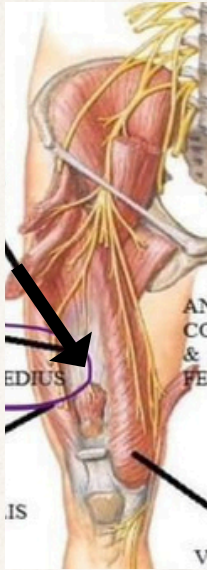
6- what is the pointed structure :



Iliofemoral ligament

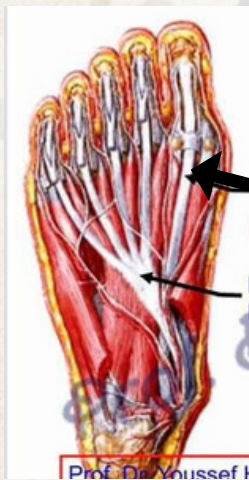

7- what is the pointed structure :



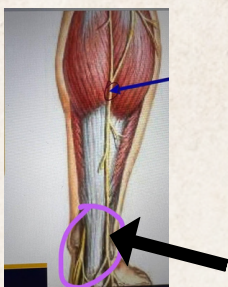
VASTUS INTERMEDIOS

8- what is the pointed structure :

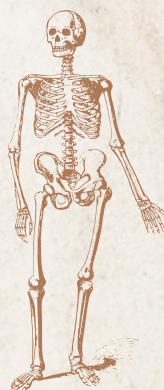


flexor hallucis longus

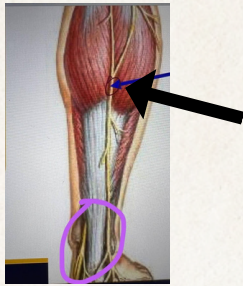
9- what is the nerve pointed structure :



sural nerve

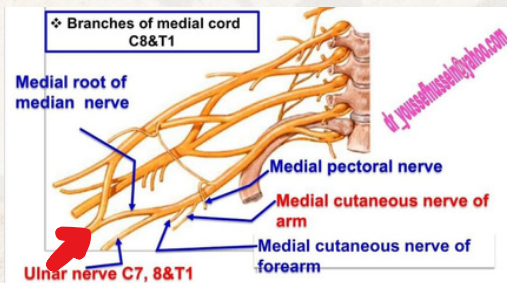


9- what is the muscle in the pointed structure :



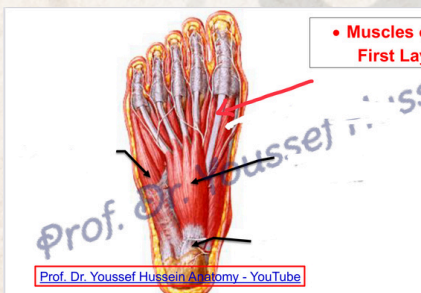gastrocnemius

9- what is the nerve in the pointed structure :



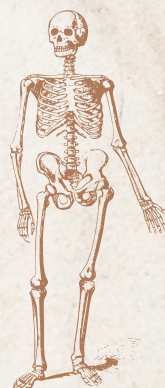
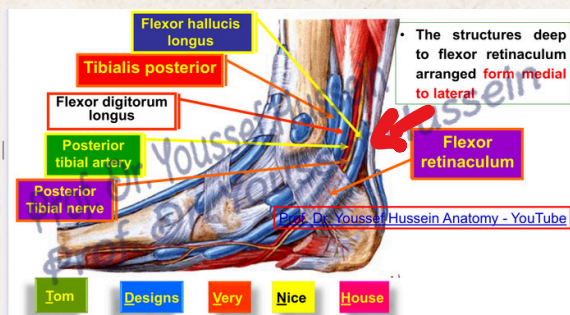
Medial nerve

9- the pointed structure **الاسم الاحمر:**

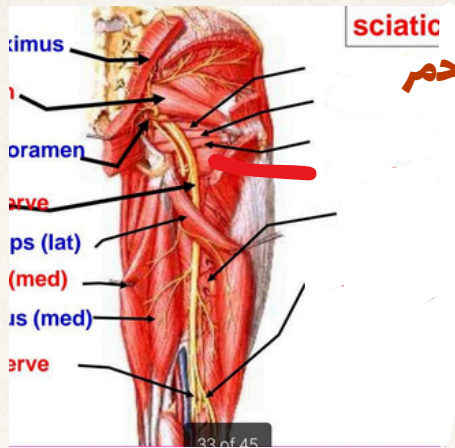


Flexor hallucis longus

9- the pointed structure **الاسم الاحمر:**



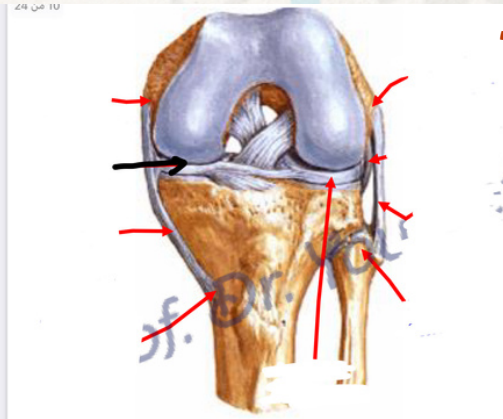
9- what is the muscle in the pointed structure :



السهم الاحمر

Quadratus femoris

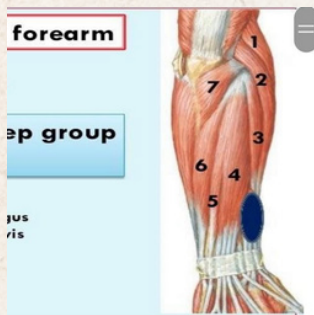
9- what is the pointed structure :



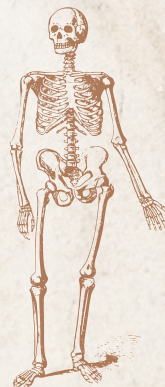
السهم الاسود

Medial meniscus

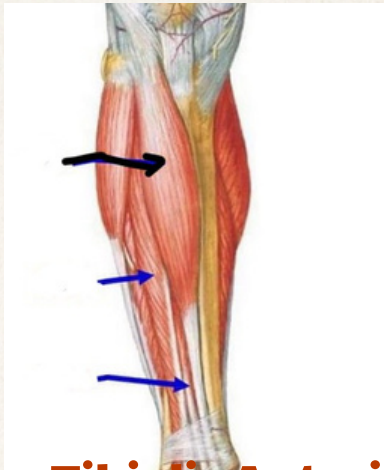
9- what is the Muscle in number 6 structure :



Extensor Carpi ulnaris (6)

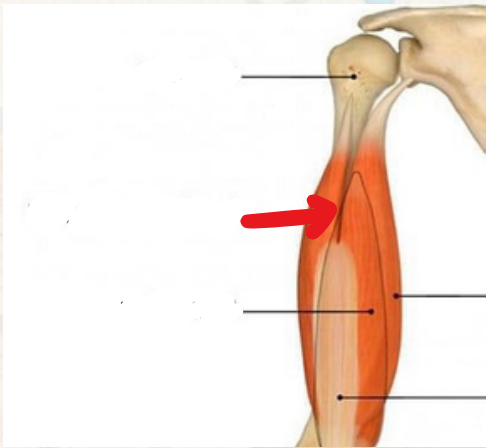


9- what is the muscle in the pointed structure :



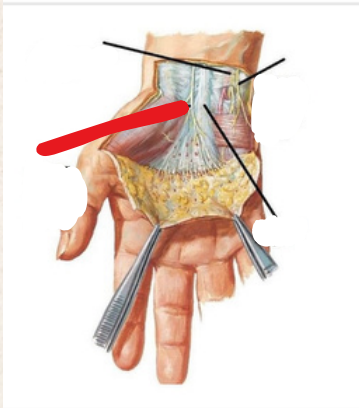
Tibialis Anterior

9- what is the muscle in the pointed structure :

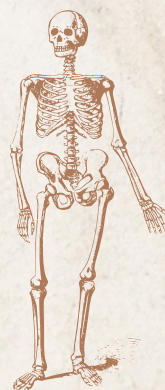


Lateral head of triceps

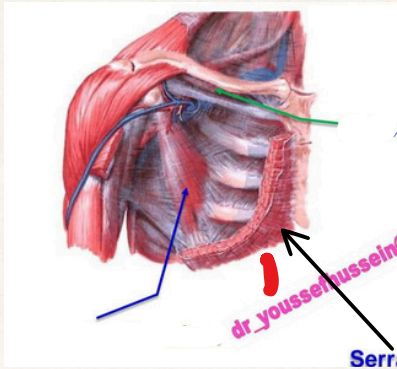
9- what is the Nerve in the pointed structure :



Palmar cutaneous branch of median nerve

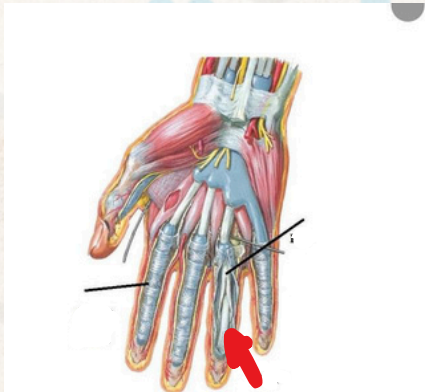

9- what is the muscle in the pointed structure :



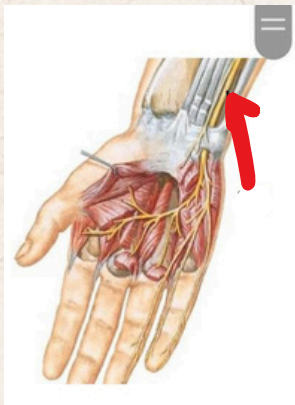
Pectoralis major

9- what is the pointed structure :

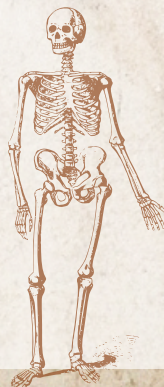


FDP

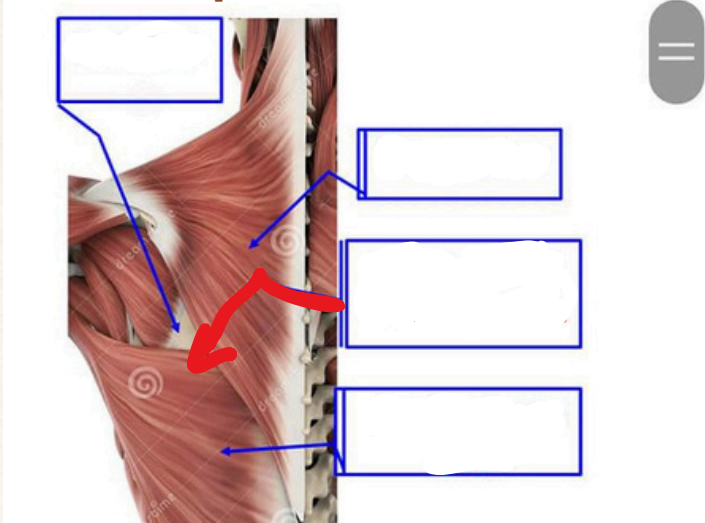
9- what is the Nerve in the pointed structure :



Ulnar nerve

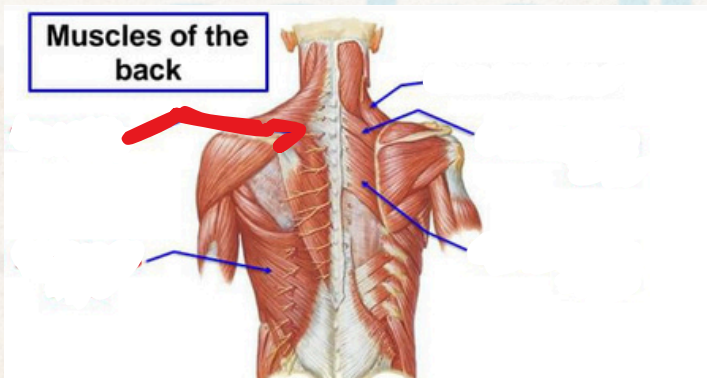


9- what is the pointed structure :



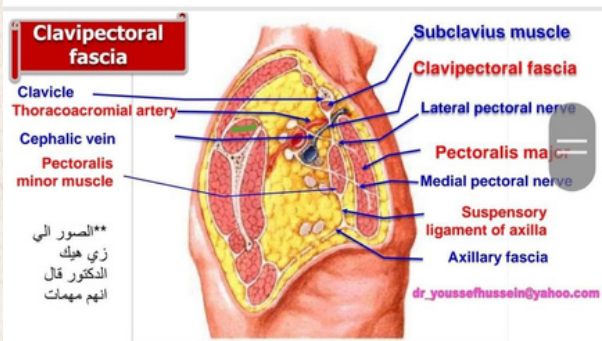
Latissimus Doris muscle

9- what is the muscle in the pointed structure :

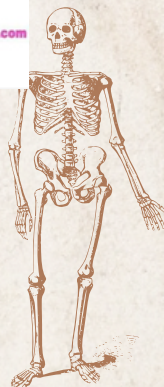


Trapezius

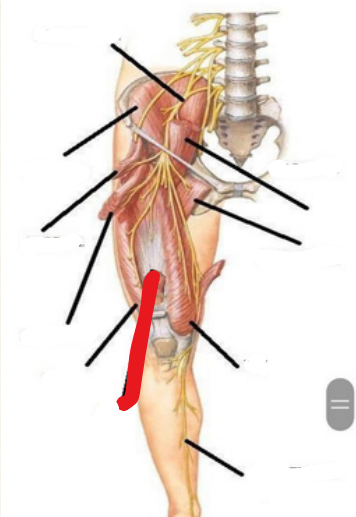
9- what is the pointed structure :



Spirasinatus

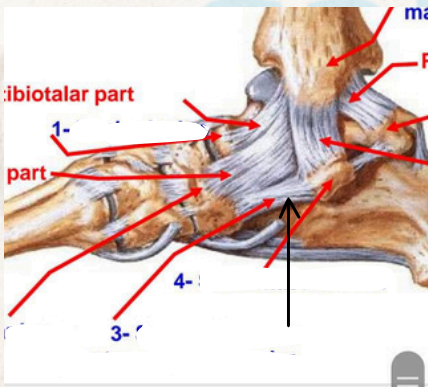


9- what is the pointed structure :



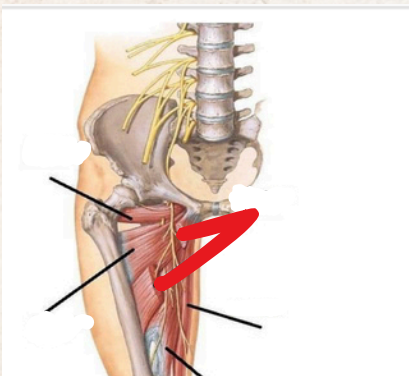
Vastus intermedius

9- what is the pointed structure(3):

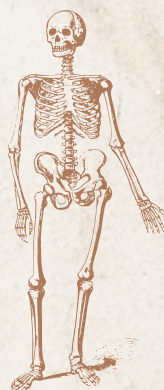


Spring ligament

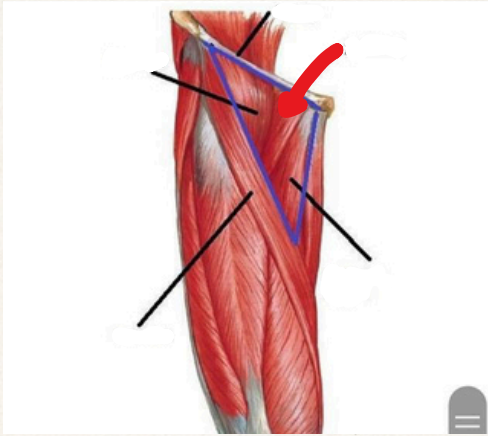
9- what is the pointed structure :



Adductor longus

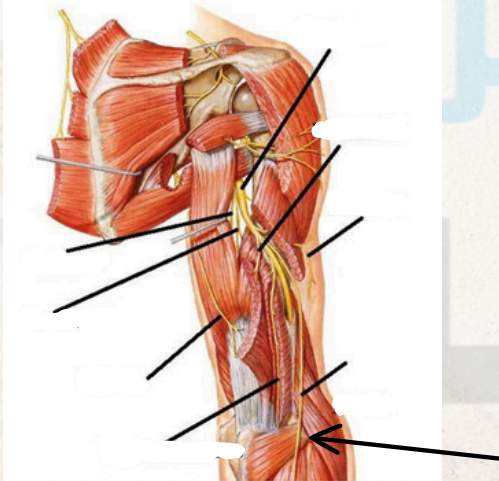


9- what is the pointed structure :



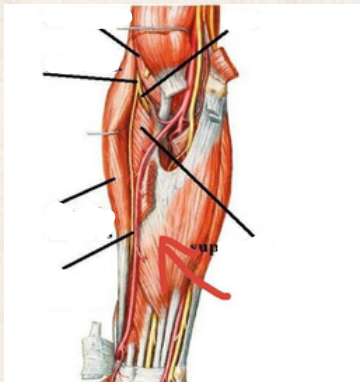
Pectinus

9- what is the pointed structure :



Posterior cutaneous nerve of forearm

9- what is the pointed structure :



FDS

