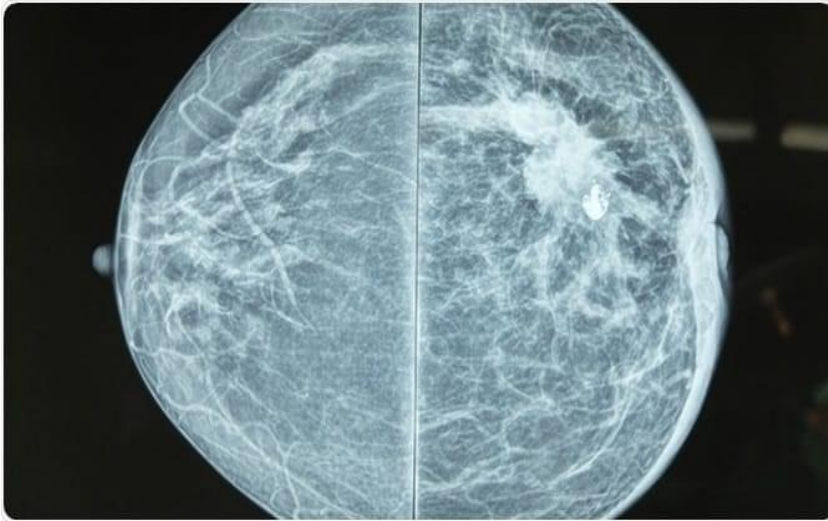


Radiology final exam MCQ

Done by : Yosor Alajaleen

✓ الامتحان كان كله صور

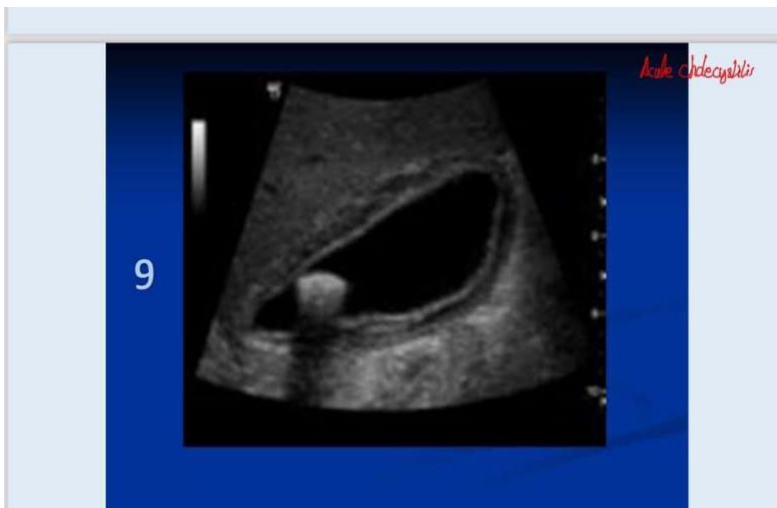
1)



A) malignancy ✓

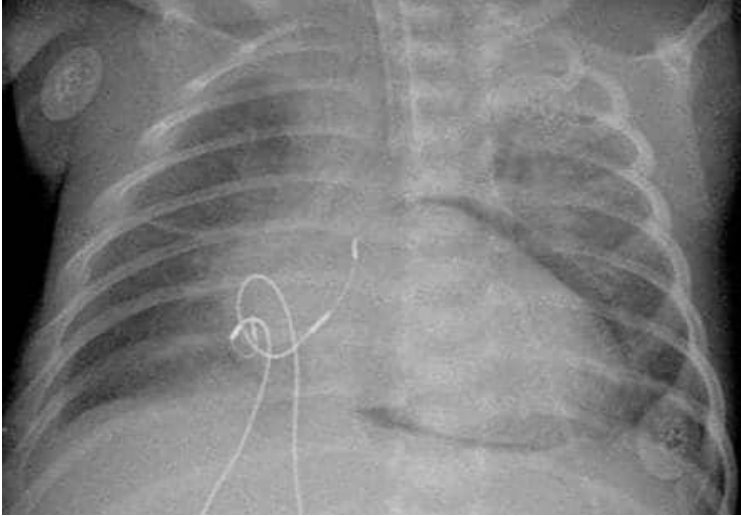
B) benign

2)




Acute cholecystitis ✓

3)



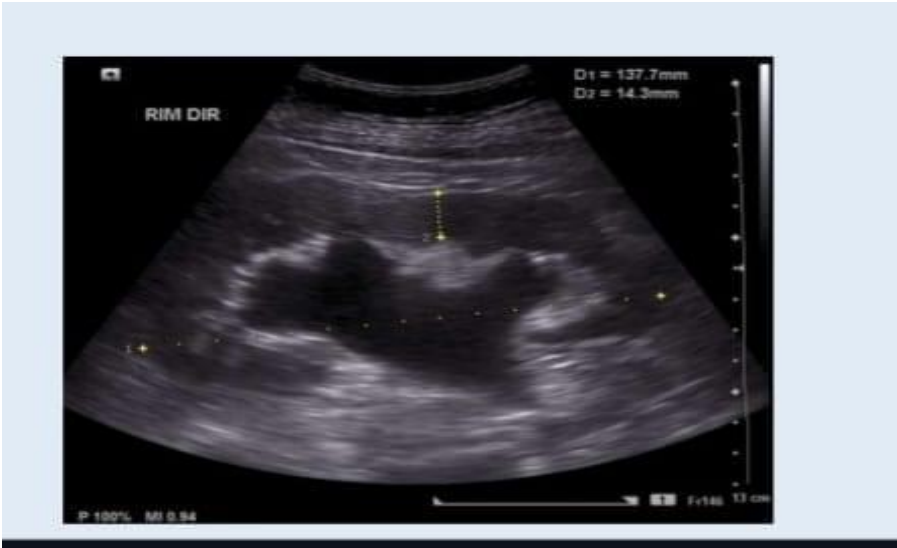Pneumopericardium ✓

4)



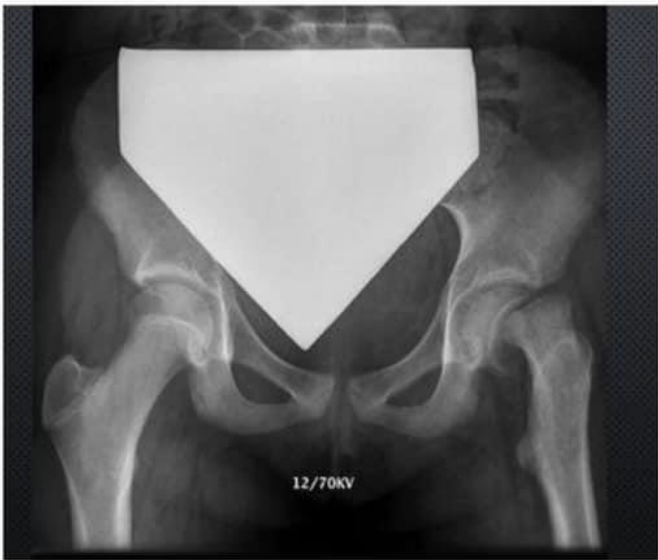- A) MRCP ✓
- B) ERCP
- C) MRI LIVER

7)



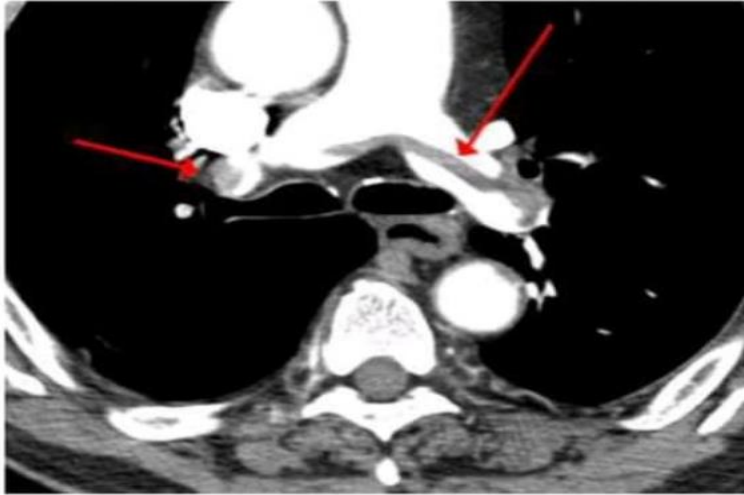
Hydronephrosis without stone

8)



Slipped capital femoral epiphysis

9)

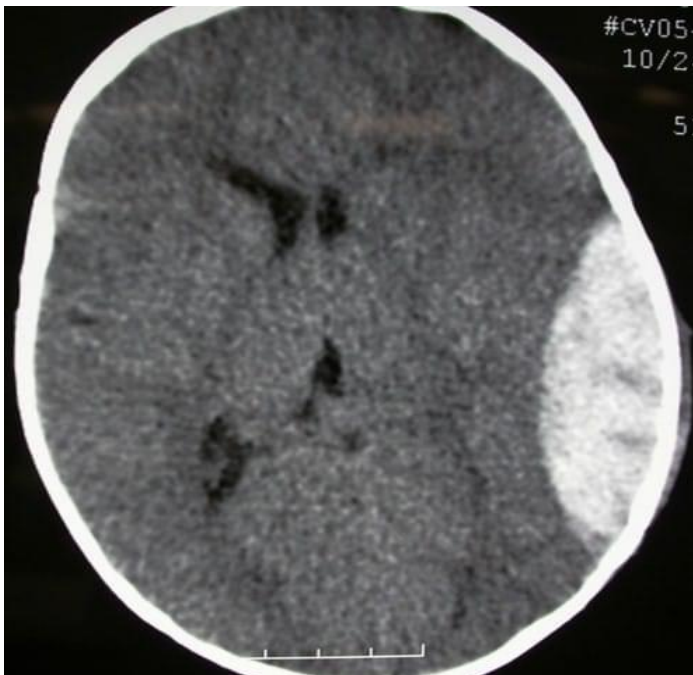

A) major PE ✓

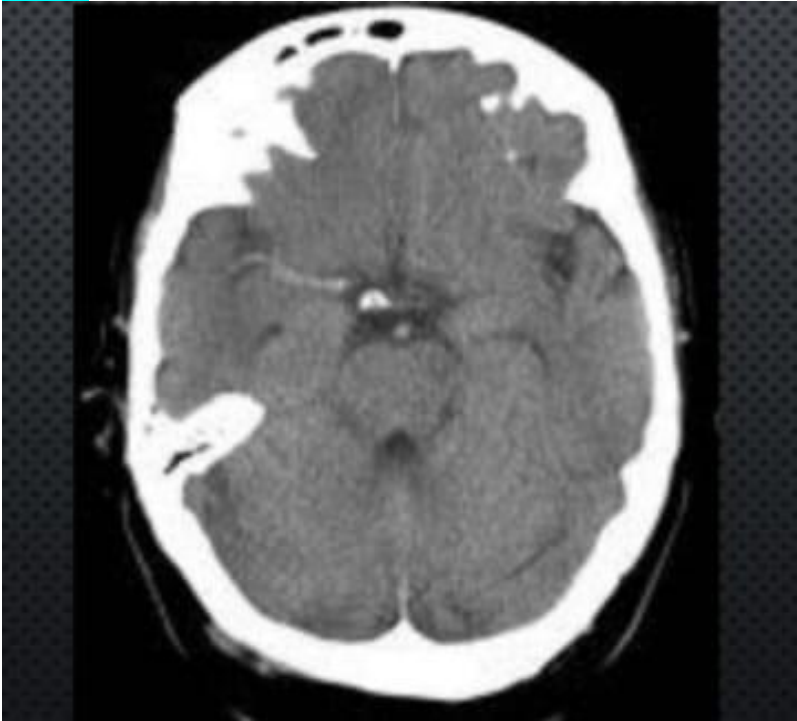B) minor PE

10)

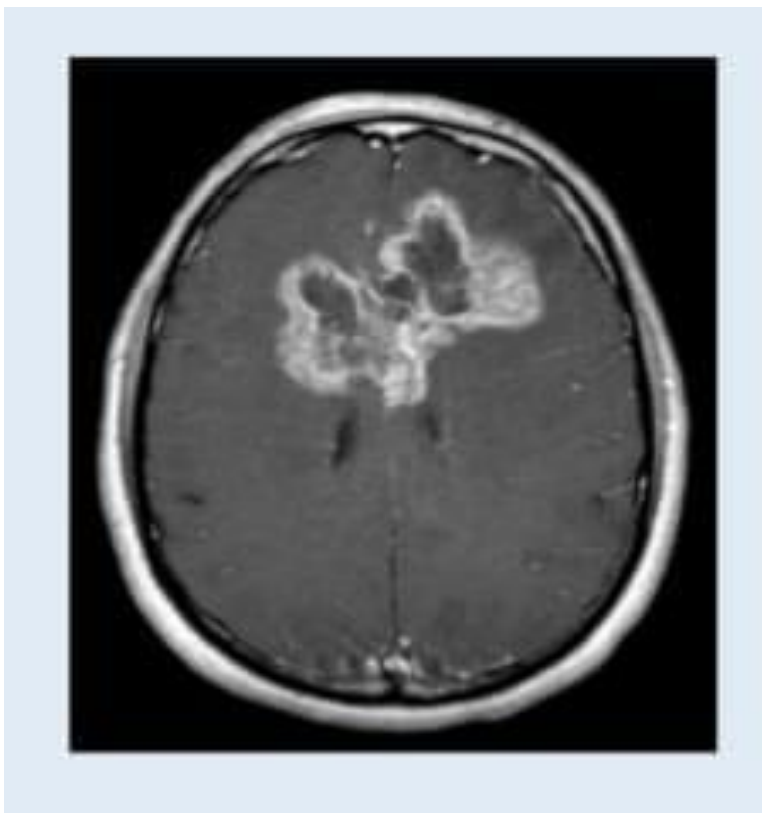
Acute epidural hematoma.



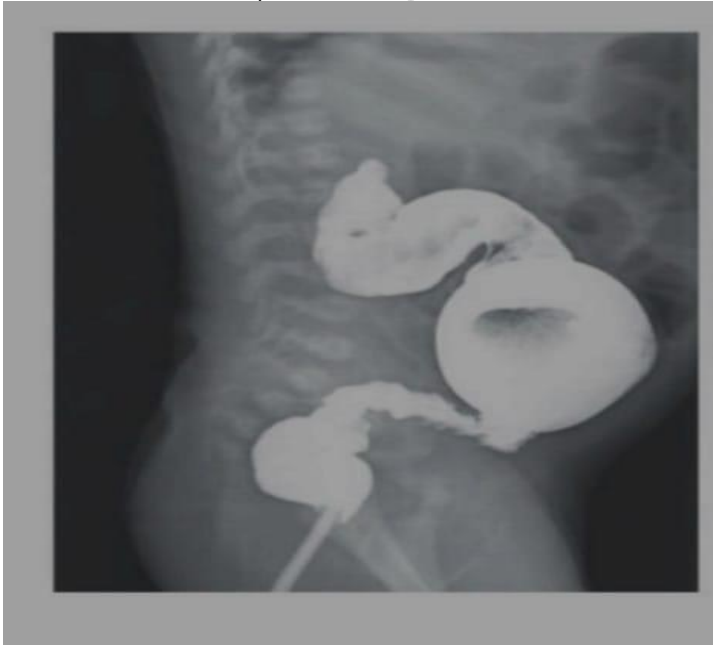11) MCA Thrombosis



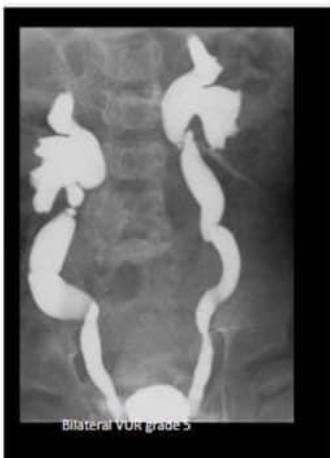12) glioblastoma multiform (high grade glioma)



13) Hirsch sprung disease



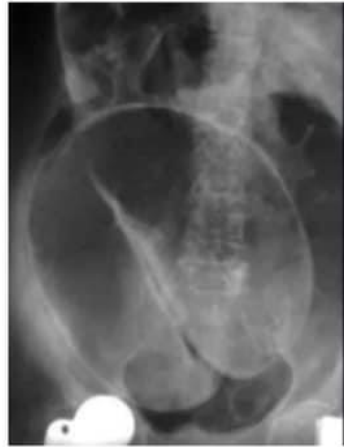14)



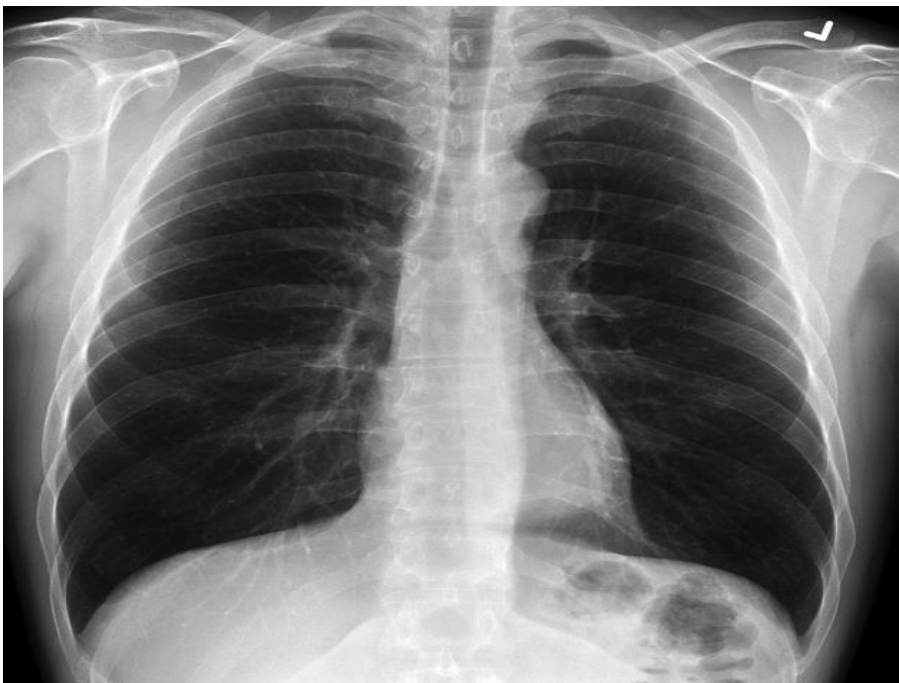stage 5 VUR

15)

Sigmoid valvulus

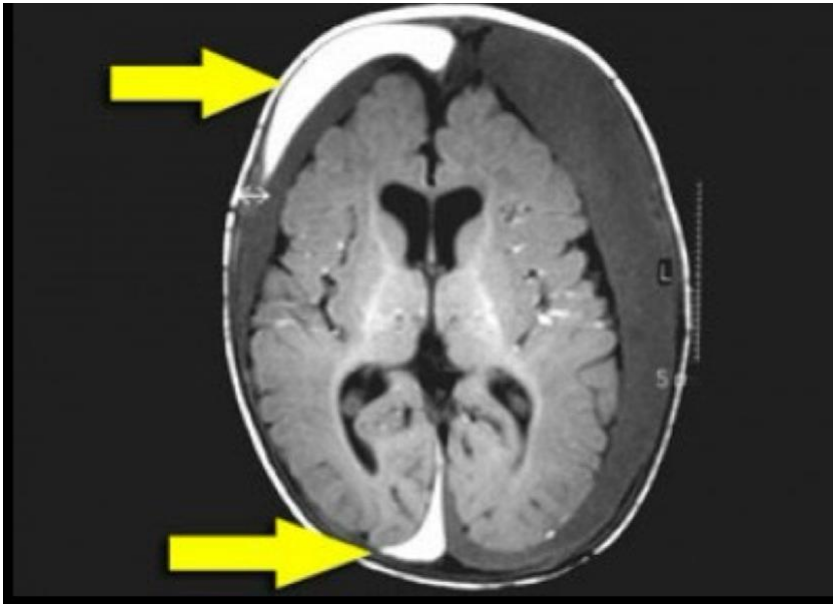


16)



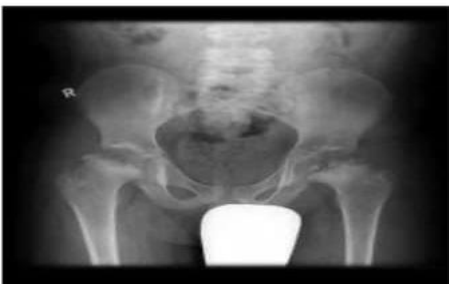Normal CXR

17)



- A) just epidural hematoma
- B) child abuse ✓

18)

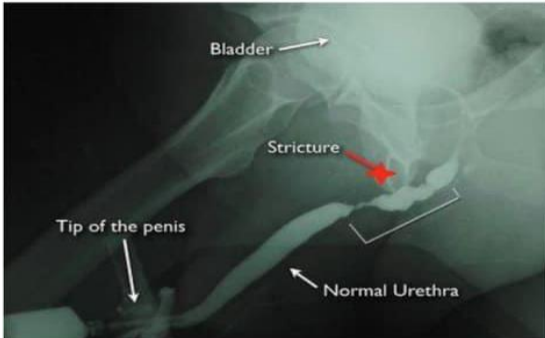


Select one:

- a. IT IS A NORMAL PELVIS FOR SUCH AGE.
- b. IT IS URGENT FOR INTERNAL FIXATION SURGICAL TREAT
- c. IT IS BILATERAL PERTHES DISEASE
- d. NO COXA MAGNA SEEN.
- e. NO COXA PLANA SEEN

19)

18. One is wrong:



Intact distal penile urethra

Stricture at bulbar urethra

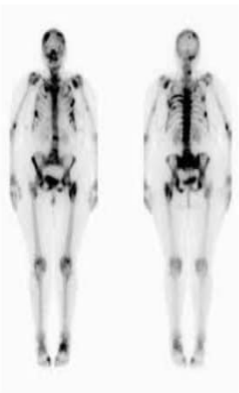
Leak at membranous urethra XXX

The Q : where is the stricture

- A) **Bulbar** ✓
- B) **Membranous**

20)

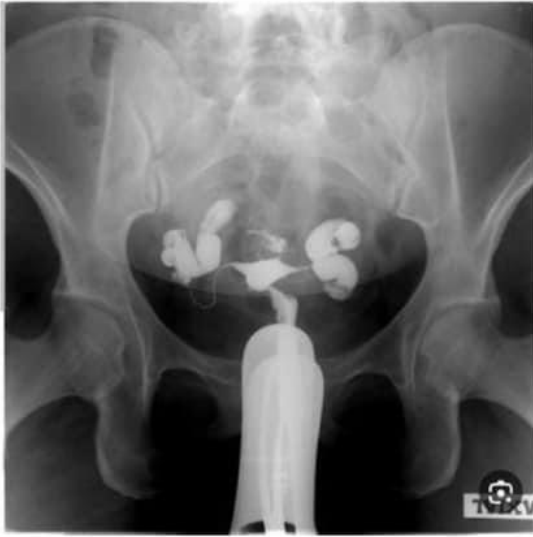21.



Bone mets due to **breast cancer**

21)

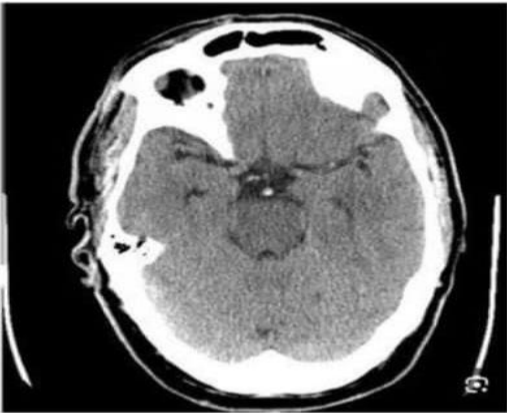
24.



Bilateral hydrosplinx

22)

30.



Basilar vein thrombosis

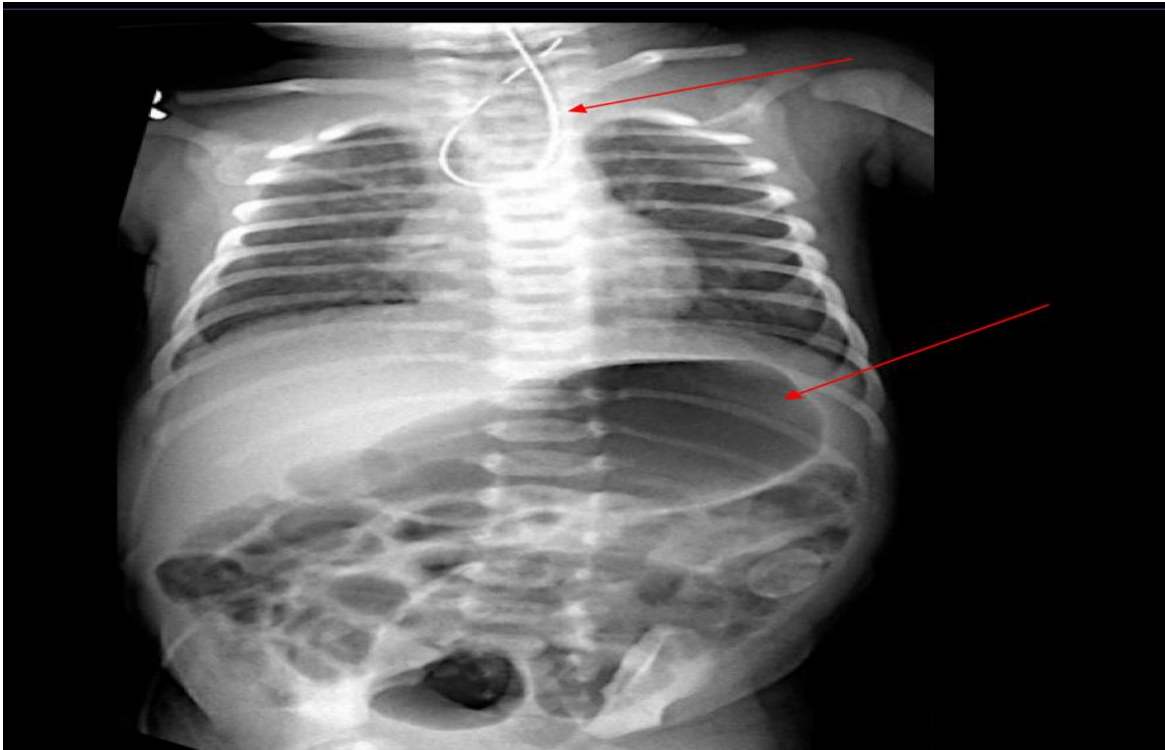
23) dexa scan

وكانوا 1- .. 1- .. 0.5 .. 0.5- .. 0.8-

NORMAL

بتوخذ اقل رقم من الأرقام وبناء عليه بتجاوب

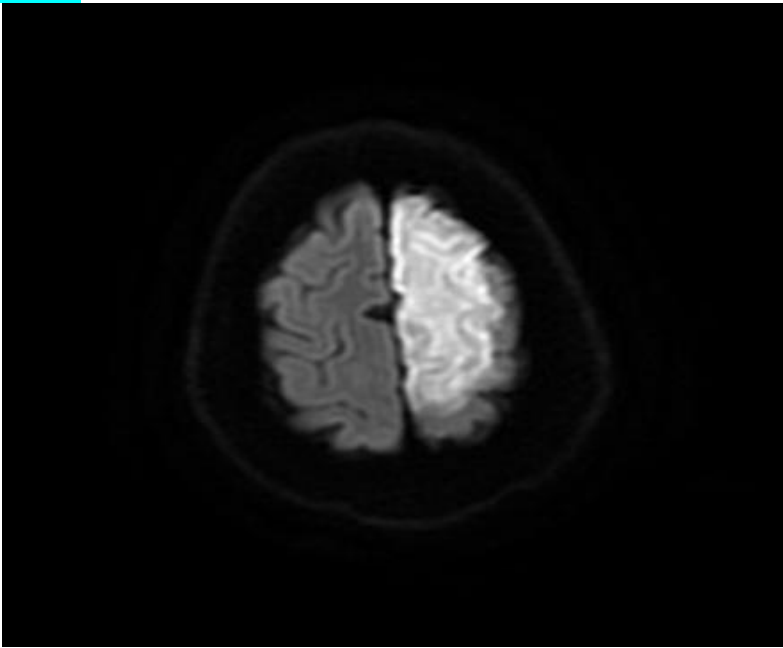
24)



A) Esophageal atresia without fistula

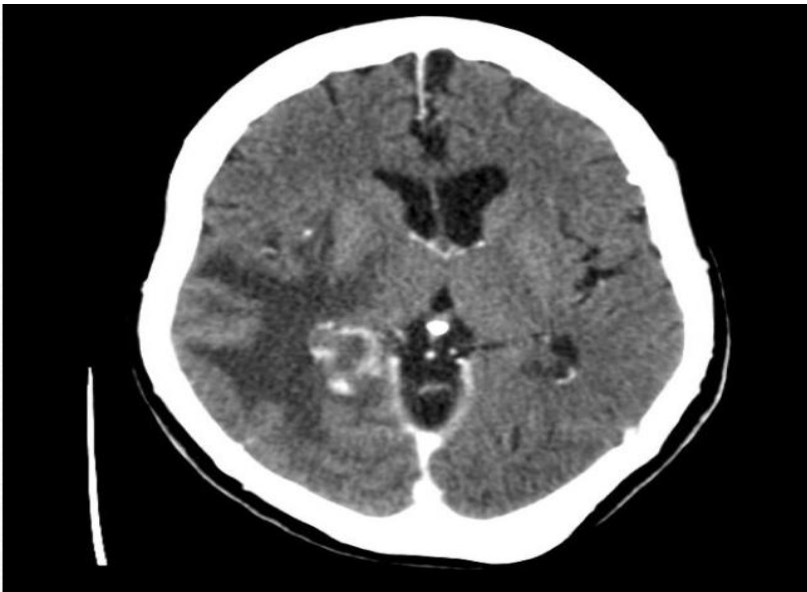B) Esophageal atresia with fistula ✓

25)



- A) ASA infarction ✓
- B) MSA infarction

26)



- A) Metastasis ✓
- B) meningioma
- C) high grade glioma

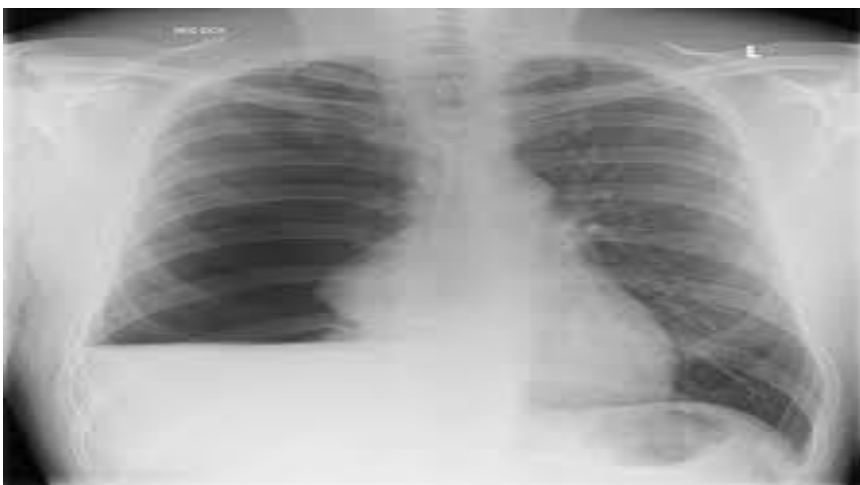27) ultra sound machine



28) “aprone” used by radiologist in:

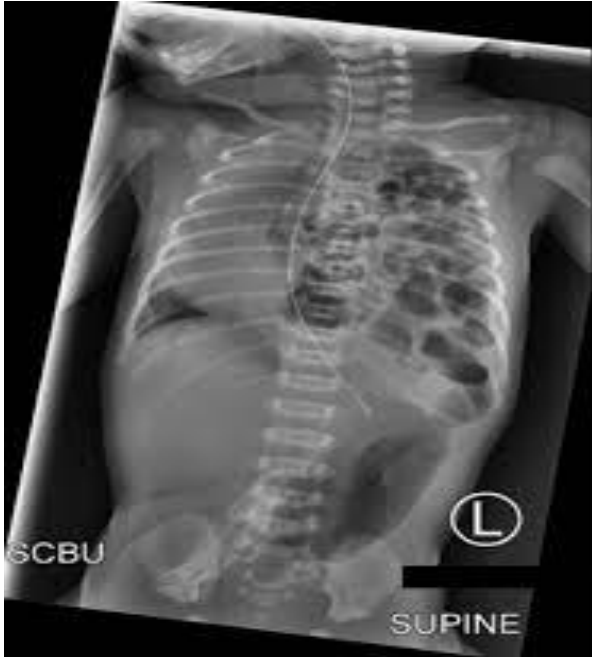- A) MRI
- B) CT ✓
- C) US

29)



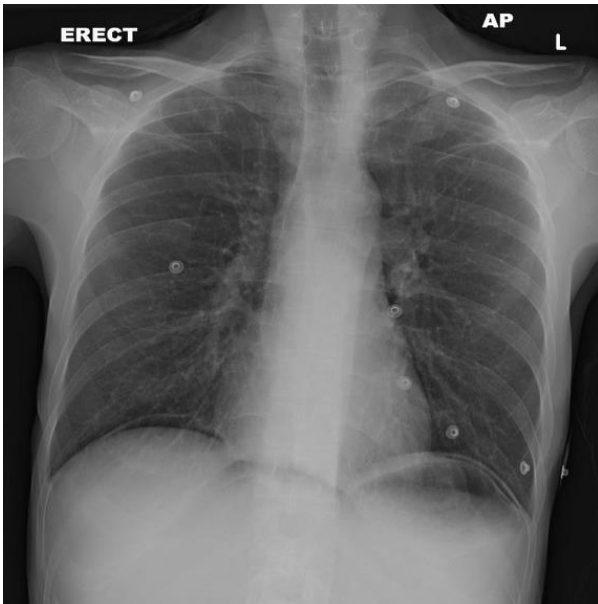
Hydro pneumothorax ✓

30)

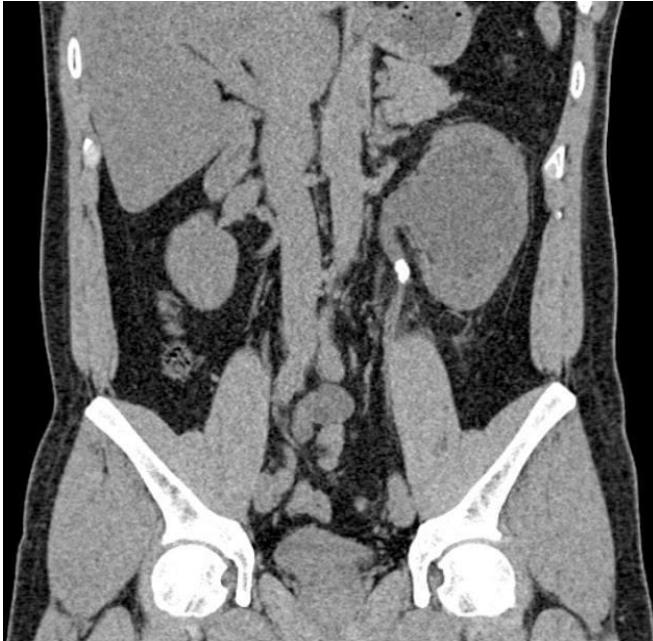

Diaphragmatic Hernia ✓

31) Pneumoperitoneum

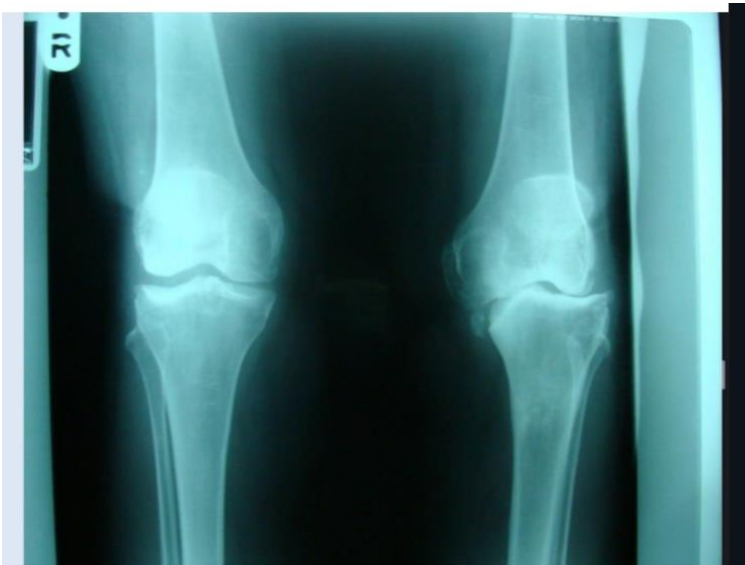


32)

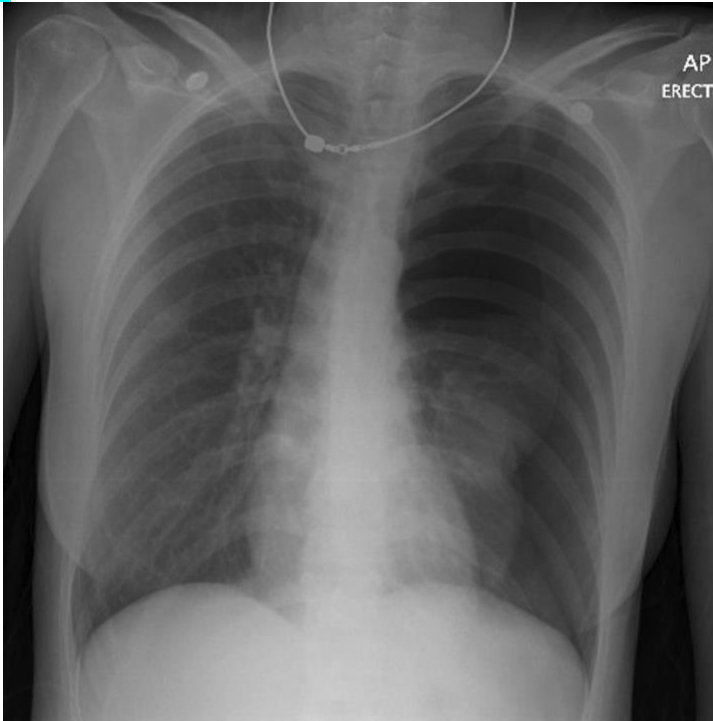


- A) ureteric stone ✓
- B) tumor in the lt kidney
- C) Incomplete duplication of both kidneys.

33) Degenerative osteoarthritis ✓



34)



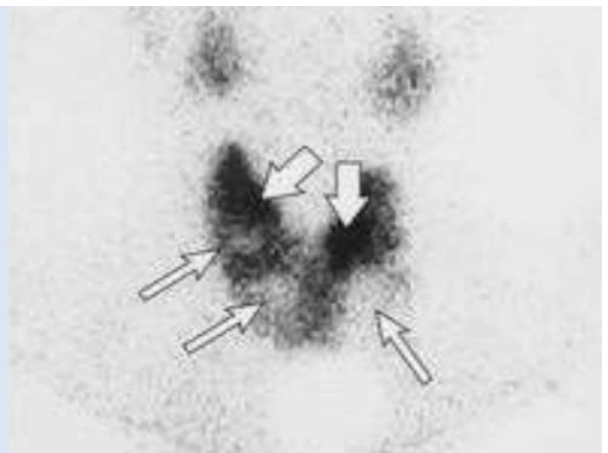
A) tension pneumothorax ✓

B) non tension

الصوره ما كانت واضحه هييك

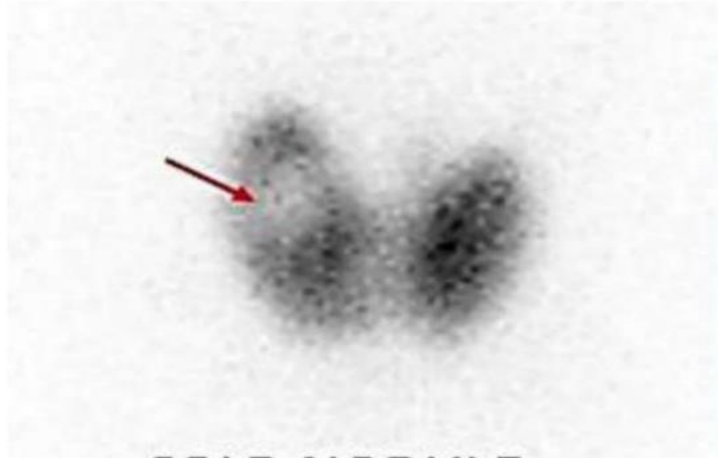
35)

- 1-polysystic kidney
- 2-multinodular goiter
- 3-cold nodule
- 4-gravis disease



36)

- a) **Cold nodule**
- b) Hot nodule
- c) Normal thyroid
- d) Graves' disease

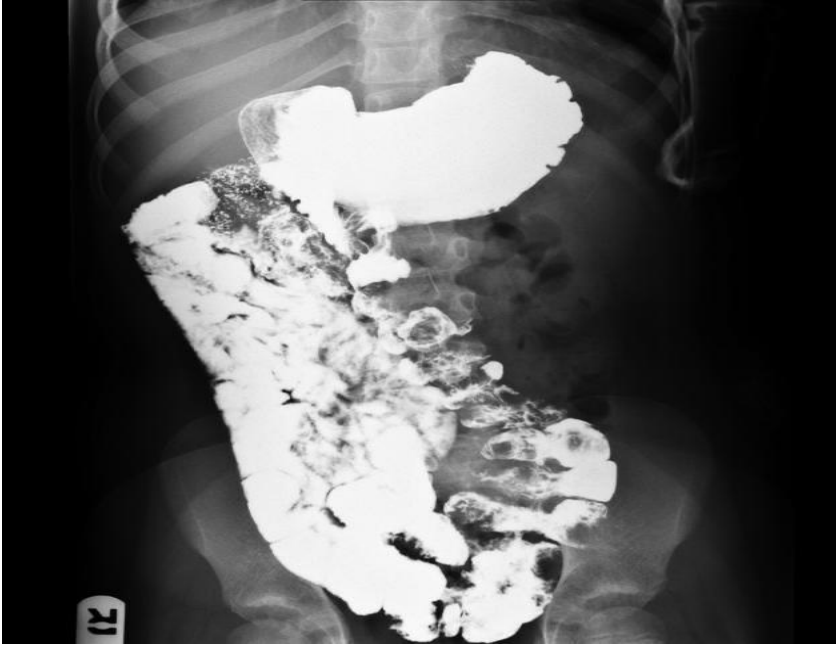


37)

- a) Normal thyroid
- b) **Graves' disease**
- c) Kidney image

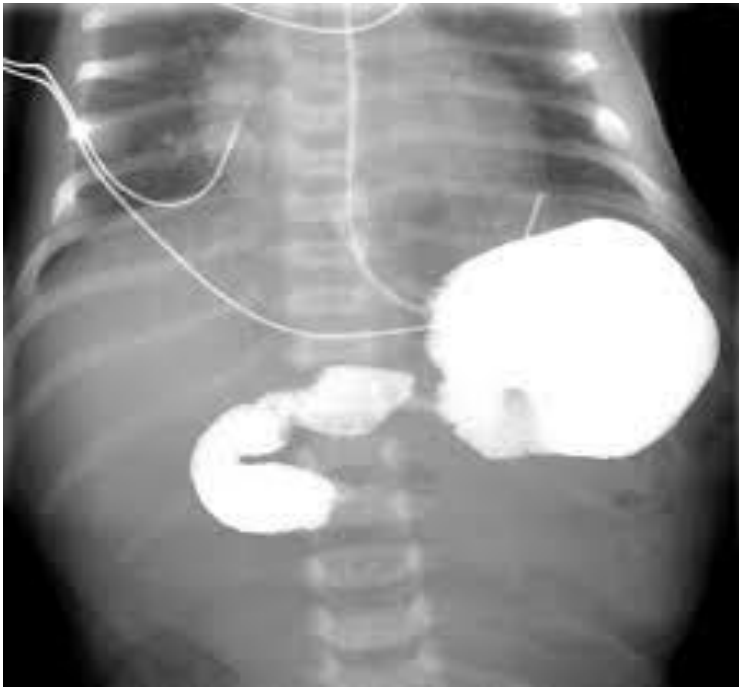


38)



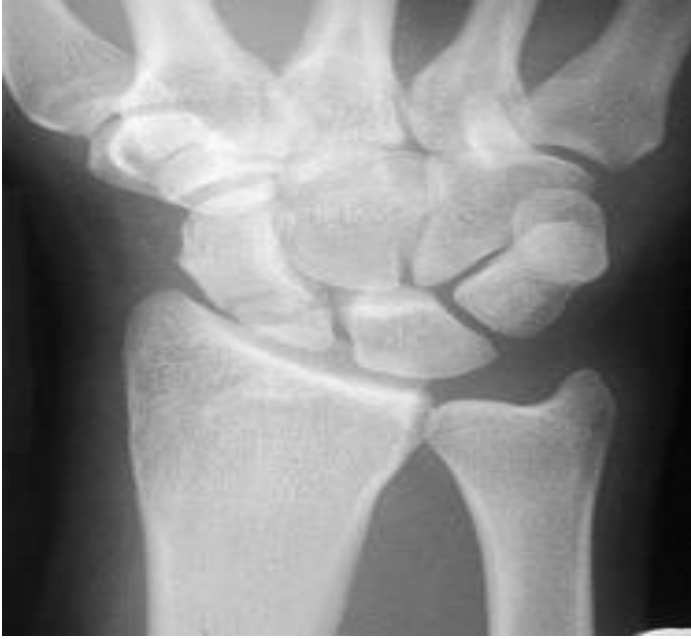Intestinal malrotation ✓

39)



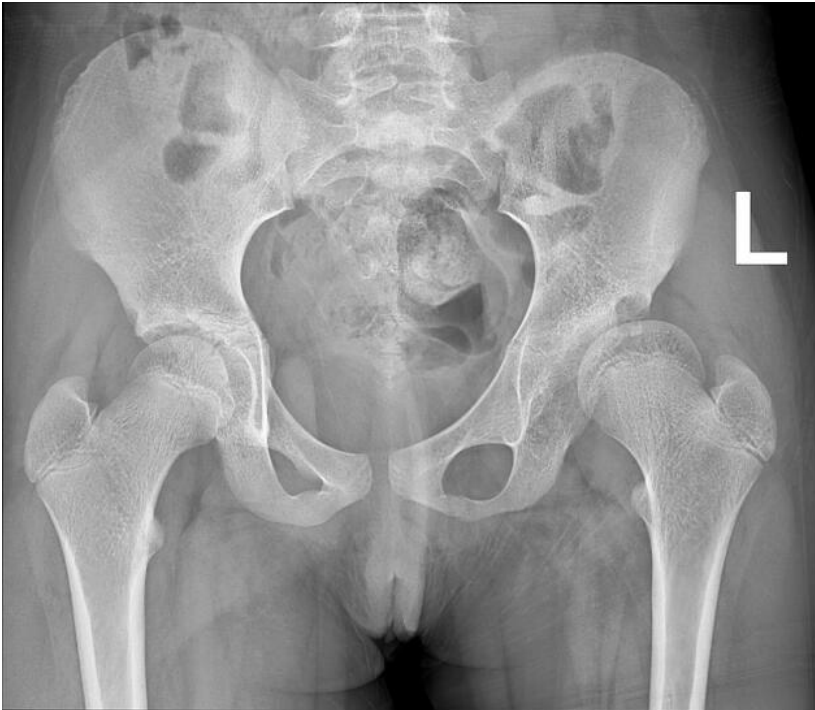Midgut valvulus ✓

40)



Scaphoid fracture ✓

41)



DDH ✓