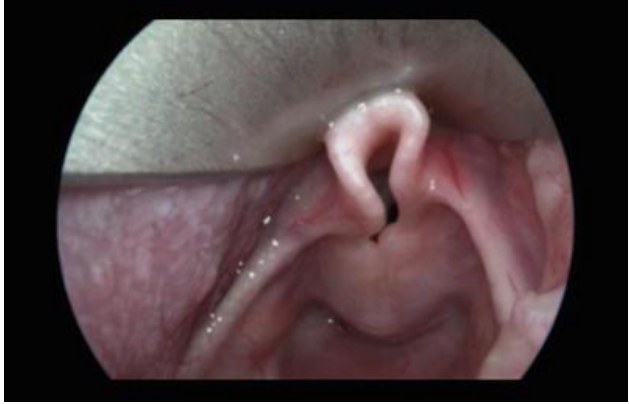

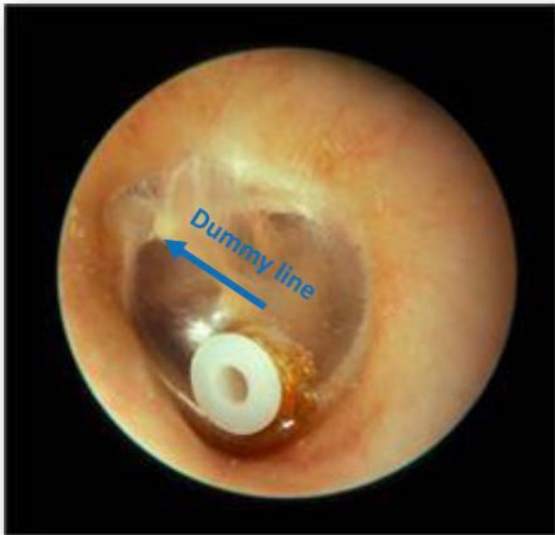ارشيف اذنية المجموعة الأولى

الامتحان كان عبارة عن ٧ صور ، ٢٠ سؤال اختيار من متعدد ، ٢٠ دقيقة ، ٤٠ علامة



1-omega sign

2-laryngomalacia



1/True about it

1\_ left ear foreign body

2\_ right ear foreign body

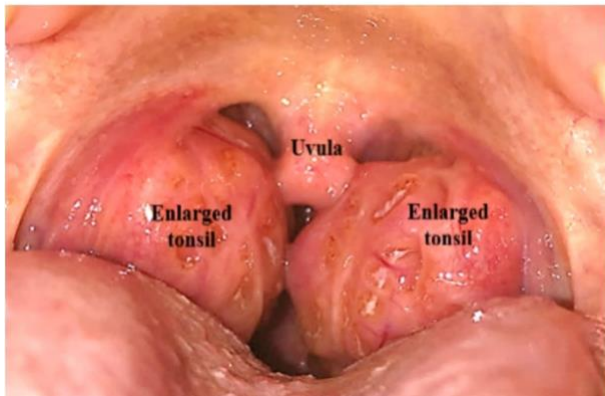
3-left ear with grommet insertion \*\*\*\*

2/ In which of the following cases is it used?

chronic suppurative otitis media

Chronic serous infection

3. Sleep apnoea syndrome due to enlarged tonsils.



child with snoring , sleeps during the day

1/spot diagnosis

obstructive sleep apnea

2/ false about it

Grade 3

Bifid uvula

3/ best treatment

Steroid

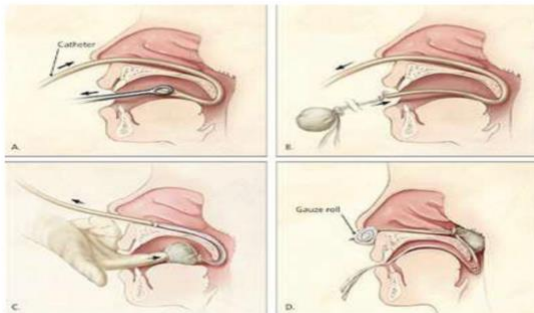
Antibiotic

Tonsillectomy

4/cause of bleeding after 7 days of tonsillectomy

infection

### Posterior Nasal Packs



1/All the following complication except

1-ala necrosis

2-vasovagal attack

3-aspiration

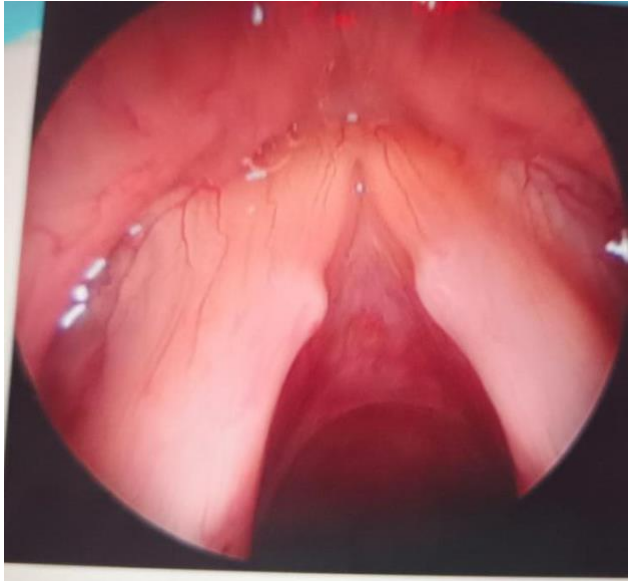4- facial pain\*\*\*\*\*

2/The name of this procedure

posterior nasal packs

3/ when we use it

posterior epistaxis

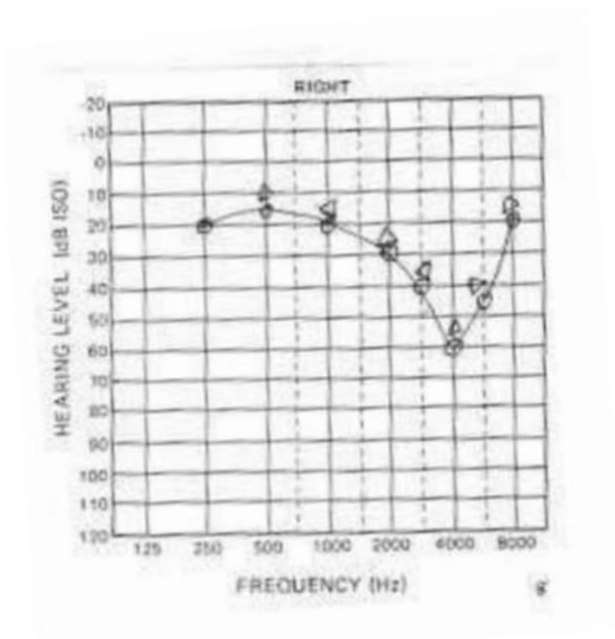


1/spot diagnose

Vocal cord nodules

2/ Caused by

voice abuse

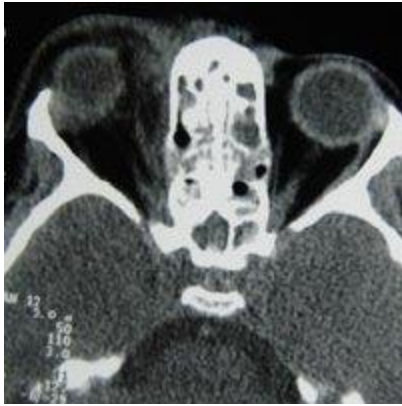

1/The name of this test

pure tone audiometry

2/diagnose

Noise-induced hearing loss



صورة شبه هاي

1/(? ) Sinus CT axial scan, right proptosis and ethmoiditis

2/ When we ask for ? ct scan

To assess impending complications

3/ complication

periorbital abscess

4/ wrong statement

give antihistamine