

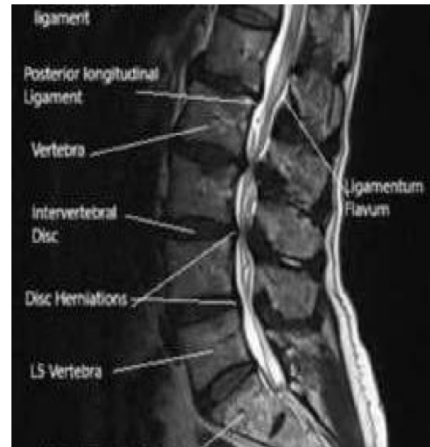Orthopedics

Wateen Group 2

Q1:

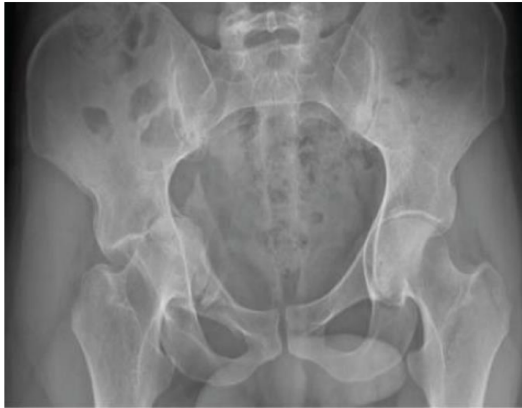3. A case of patient had lumbar canal stenosis (this information was not written in the question), according to difference between vascular and neurological claudication choose the true answer

Answer :Downhill more painful



Q2:

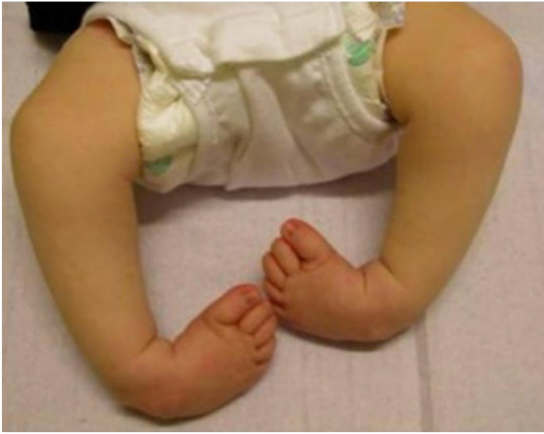All of these are late complications except



- a. sciatic nerve injury
- b. Avascular necrosis
- c. Secondary osteoarthritis

answer : a

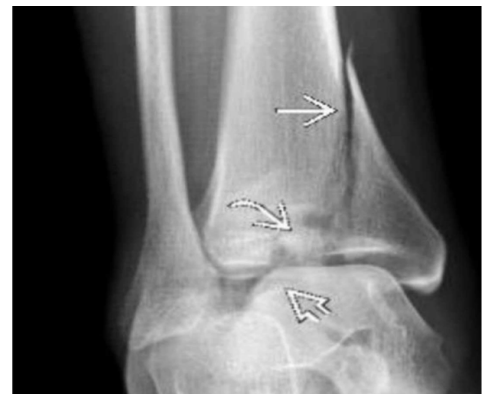Q3:



18-All of the following regarding this deformity are true except : last step of management is varus

Q4:

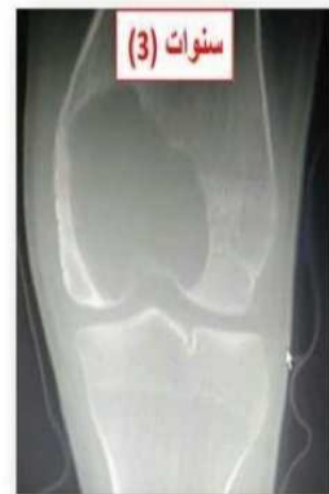Mechanism of this fracture?
Axial loading



Q5:

❖ What are the differential diagnoses ?

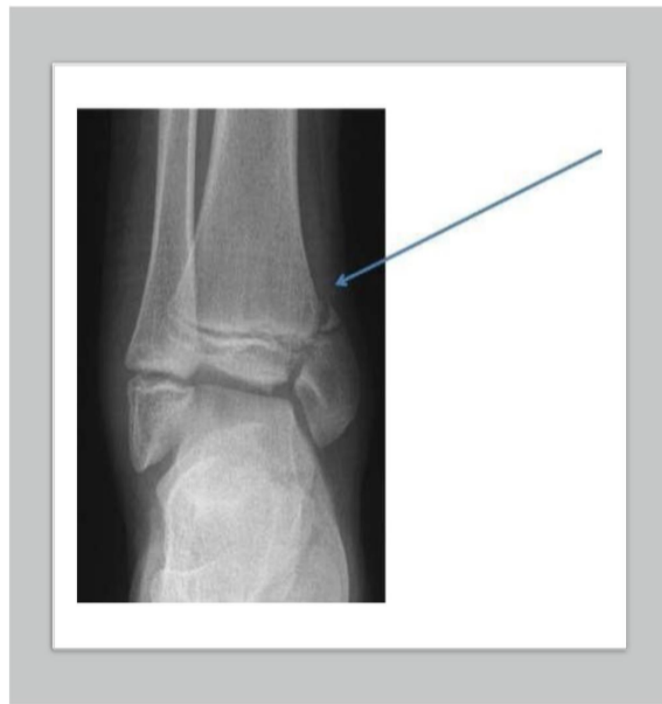- Giant cell tumor
- Chondroblastoma



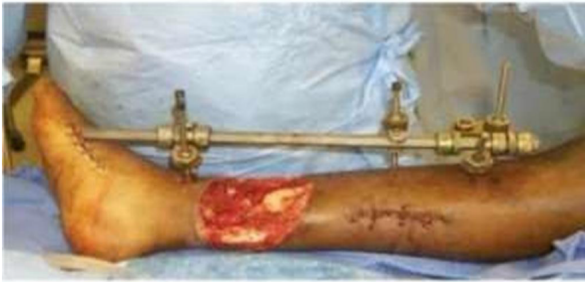Q6:

9-According to Salter- Harris classification, what is the type of this fracture?

Type
IV .



Q7:

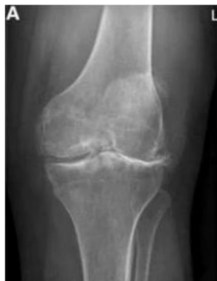

(صورة open fracture بس غير)
Q; all of the following are emergency management except:

- 1-internal fixation
- 2-dressing and casting

Q8:

All presentations are true for this case, except

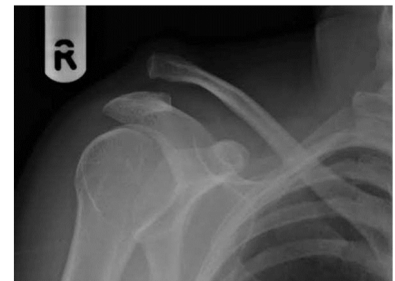

- a. Joint line tenderness
- b. Genu Valgus
- c. Narrowing of joint space
- d. Swelling and effusion
- e. Osteophyte and stiffness

answer : b

Q9:

Case of seizure came to er
At whar position the shoulder was locked in?



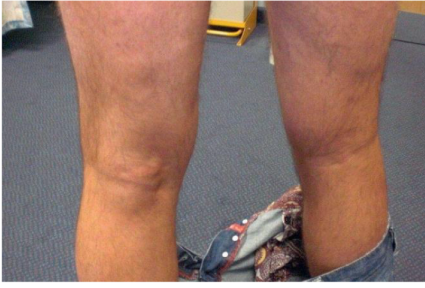- a. Adduction
- b. Abduction
- c. Internal rotation
- d. External rotation
- e. Extension

answer : c

Q 10:

All the following can cause this except

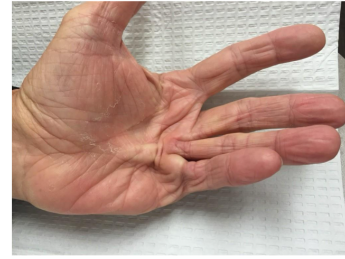
سورہ قریبتے



Infrapatellar bursitis(CLERGYMAN'S KNEE)

Q 11:

What is your diagnosis ?



Dupuytren's contracture

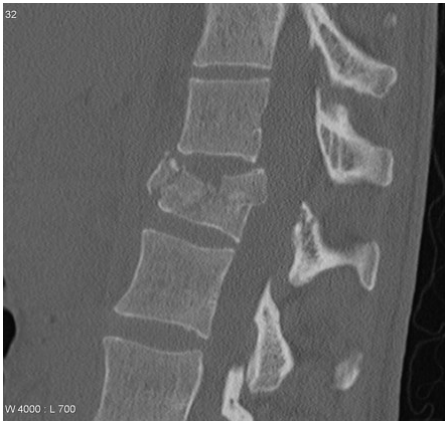Q 12

After RTA ,BP:107/80, the pressure on the compartments of the leg are as follows (anterior 27,lateral 53, posterior superficial 22, posterior deep 27) What is the most likely function loss the pt will complaint from:

- a-loss of sensation on the dorsum of the foot including the first web space
- b-loss of sensation on the 1st ,3rd, 4th fingers
- c-loss of ankle dorsiflexion
- d-loss of adduction
- e-loss of ankle plantarflexion

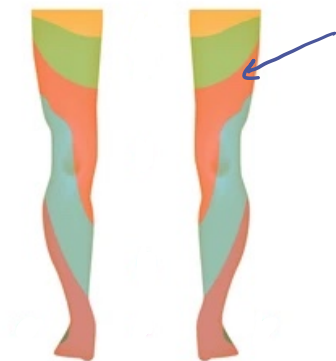Note:Intracompartment pressure<diastolic BP if<30 it's compartment syndrome, and the nerve that supplies the lateral compartment is superficial peroneal nerve so the answer is b or c

Q 13:



Burst Fracture

Q 14:

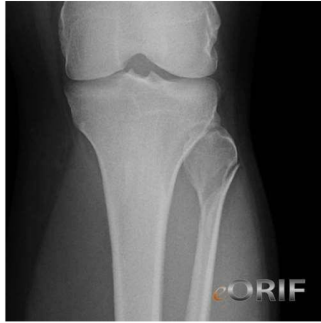

One of the following results from this dermatome

Knee jerk (it's L3)

Q 15:

WHICH NERVE AFFECTED IN THIS INJURY ?



Common peroneal nerve

All of the following are supplied by the affected nerve except:

Tibialis posterior

Q 16:

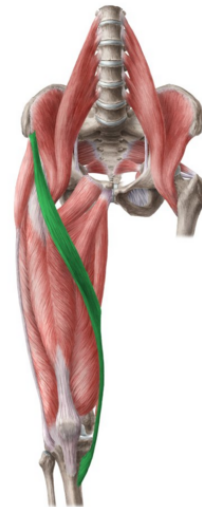
Which of the following is true about the muscle:
Supplied by femoral artery

Does hip flexion and knee flexion

Origin of ASIS and inserted in the proximal tibia in the pes anserinus

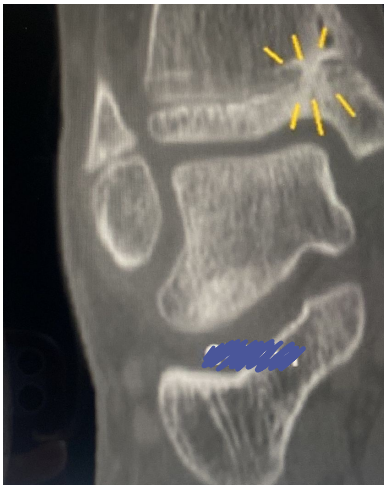Synergistically work with hamstring

Most superficial in the anterior compartment



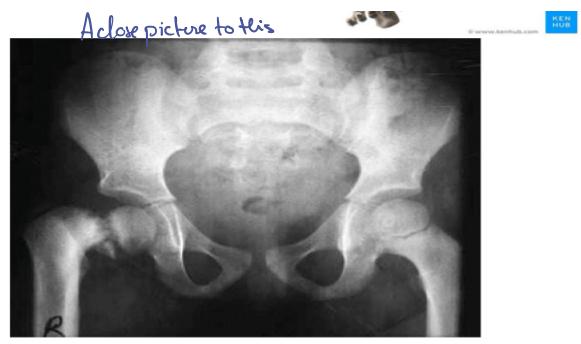
© www.kennhub.com

Q 17:

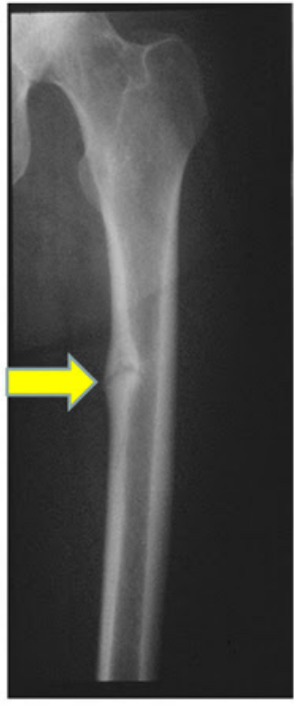

All are true about this except:
Best seen with X-ray

Q18: 20. What is the diagnosis?
Coxa vara

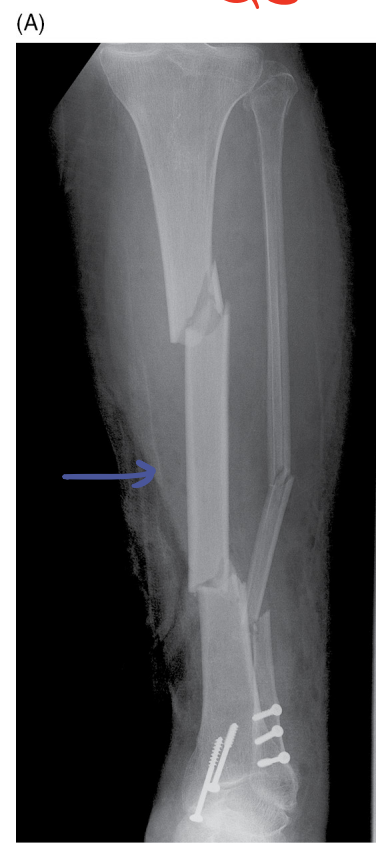

Q19:



Loser's zone fracture

Q20:



Segmental fracture