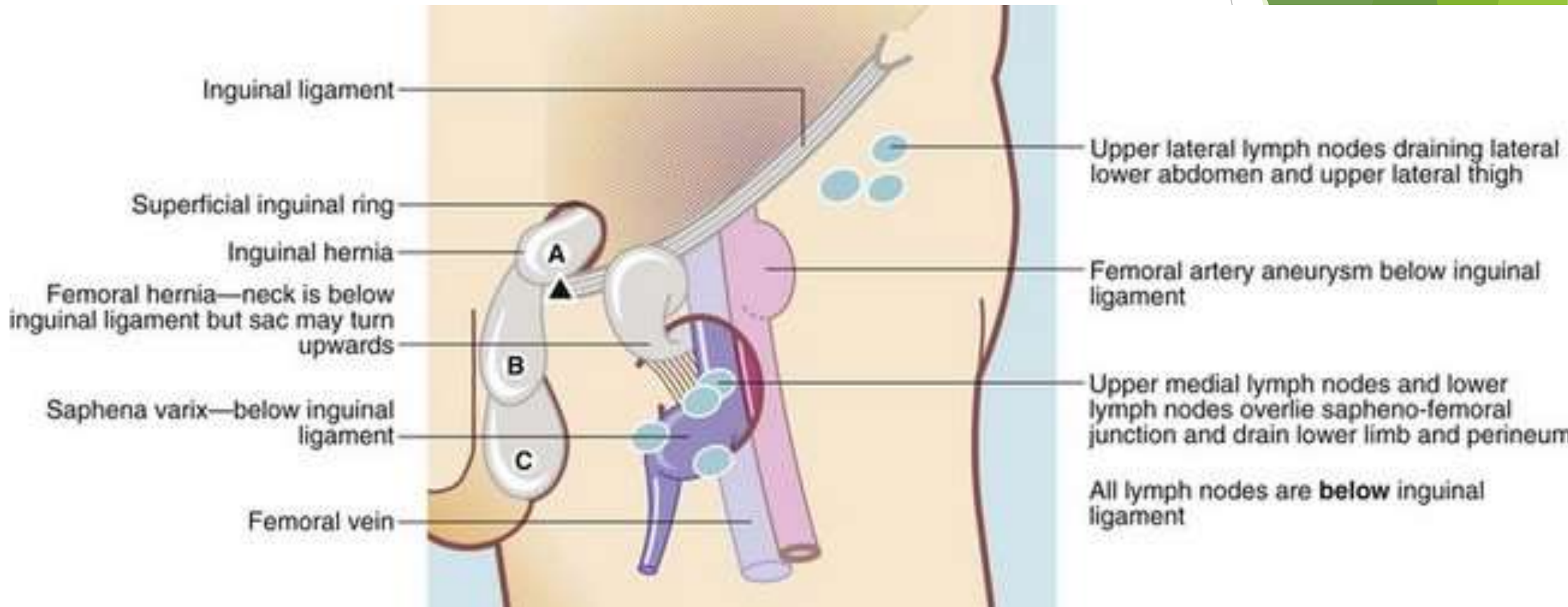


Inguinoscrotal condition

Dr. Anas Albattikhi

Differential diagnosis

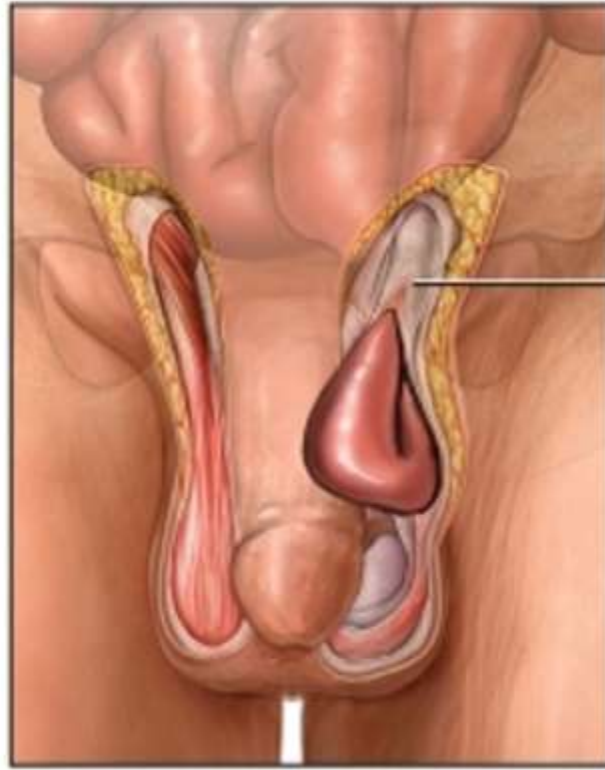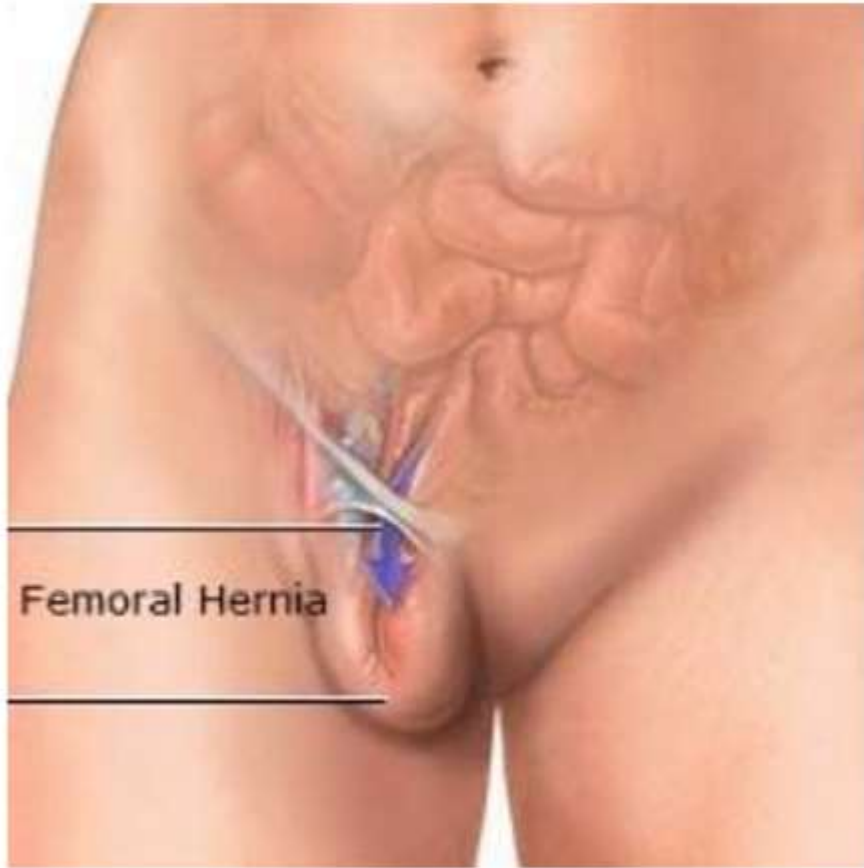
- ▶ Emergencies and non Emergencies conditions involving the inguinal region and scrotum are common and can be caused by a plethora of different causes.



Hernias

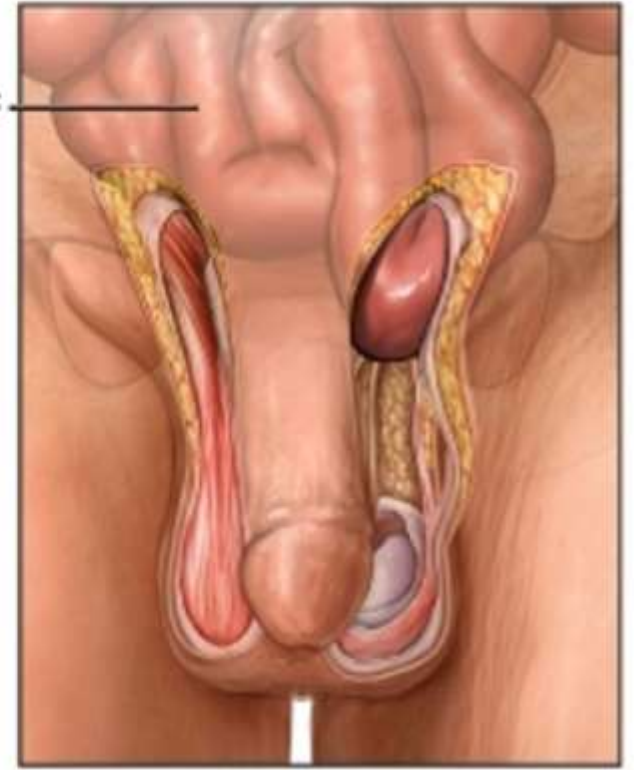
- ▶ **inguinal hernias** , direct and indirect.
- ▶ **Femoral hernias.**

The picture can't be displayed.



Small intestine

Inguinal canal



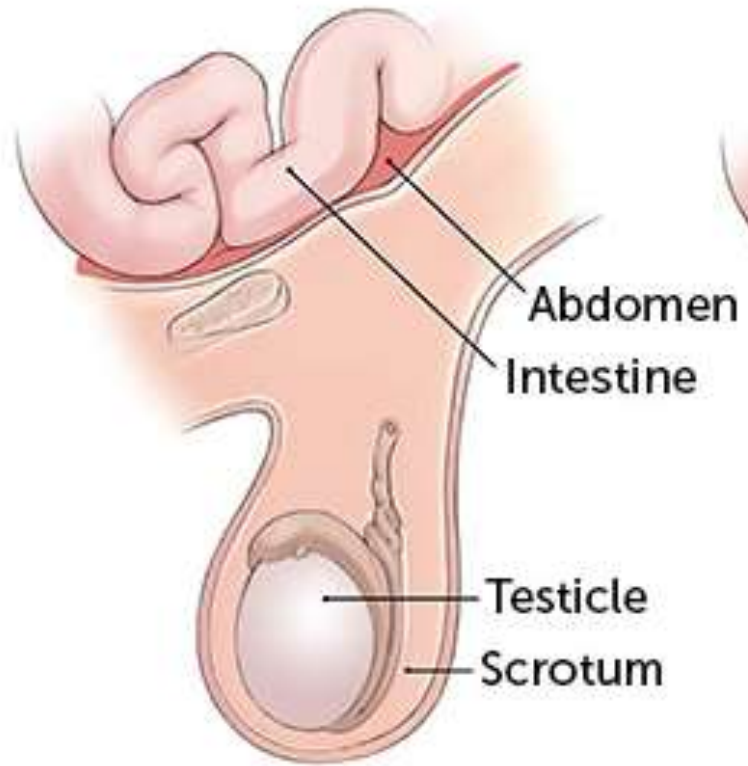
<https://www.laparoscopyhospital.com/femoral-hernia.html>

Copyright © Nucleus Medical Media, Inc.

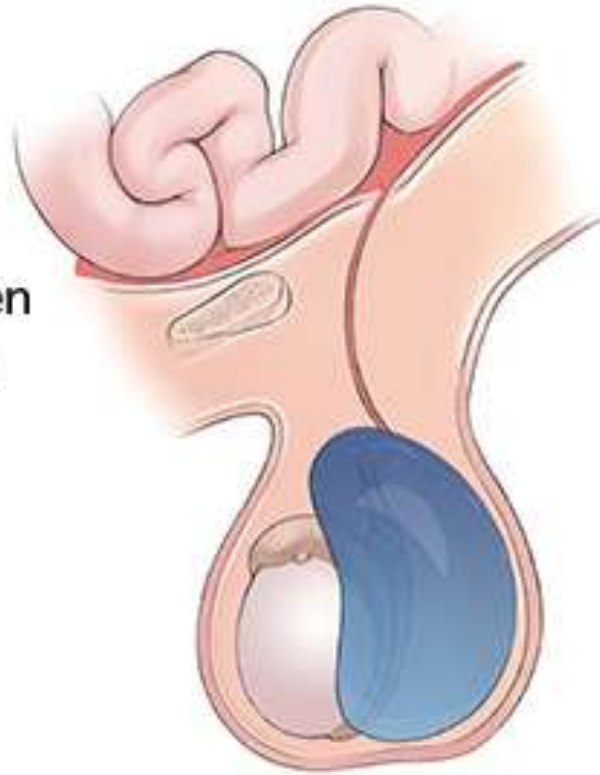

▶ Hematocele and
Hydrocele

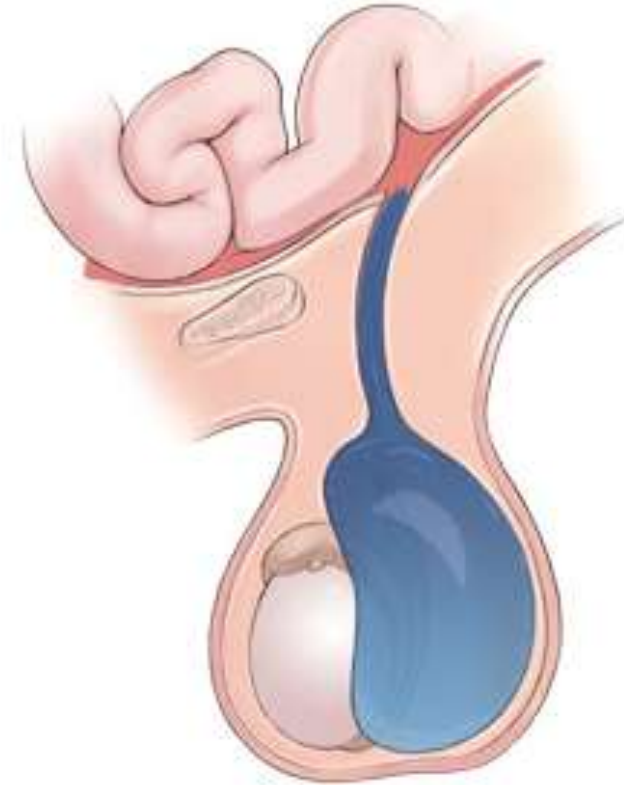Normal

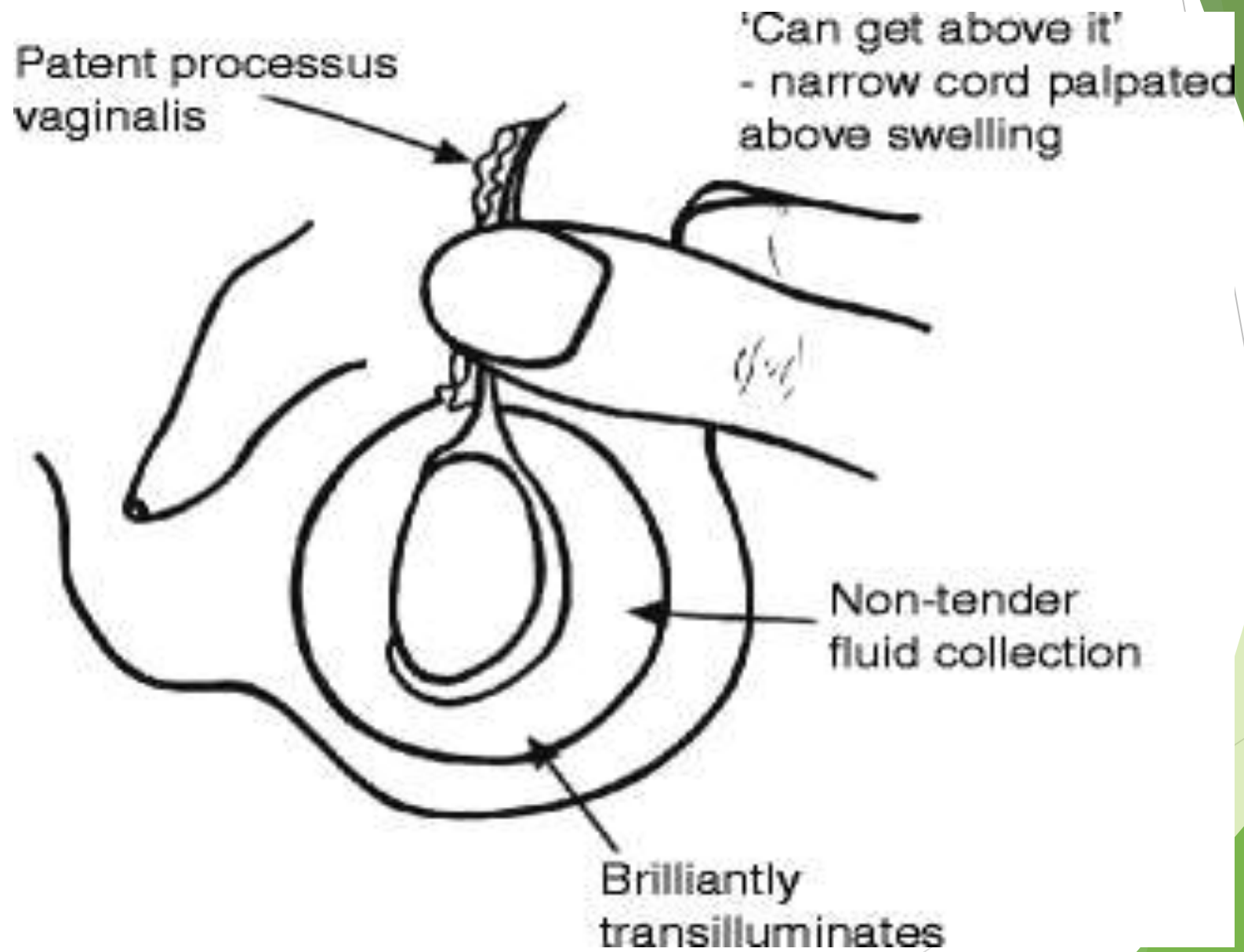


Non-Communicating
Hydrocele

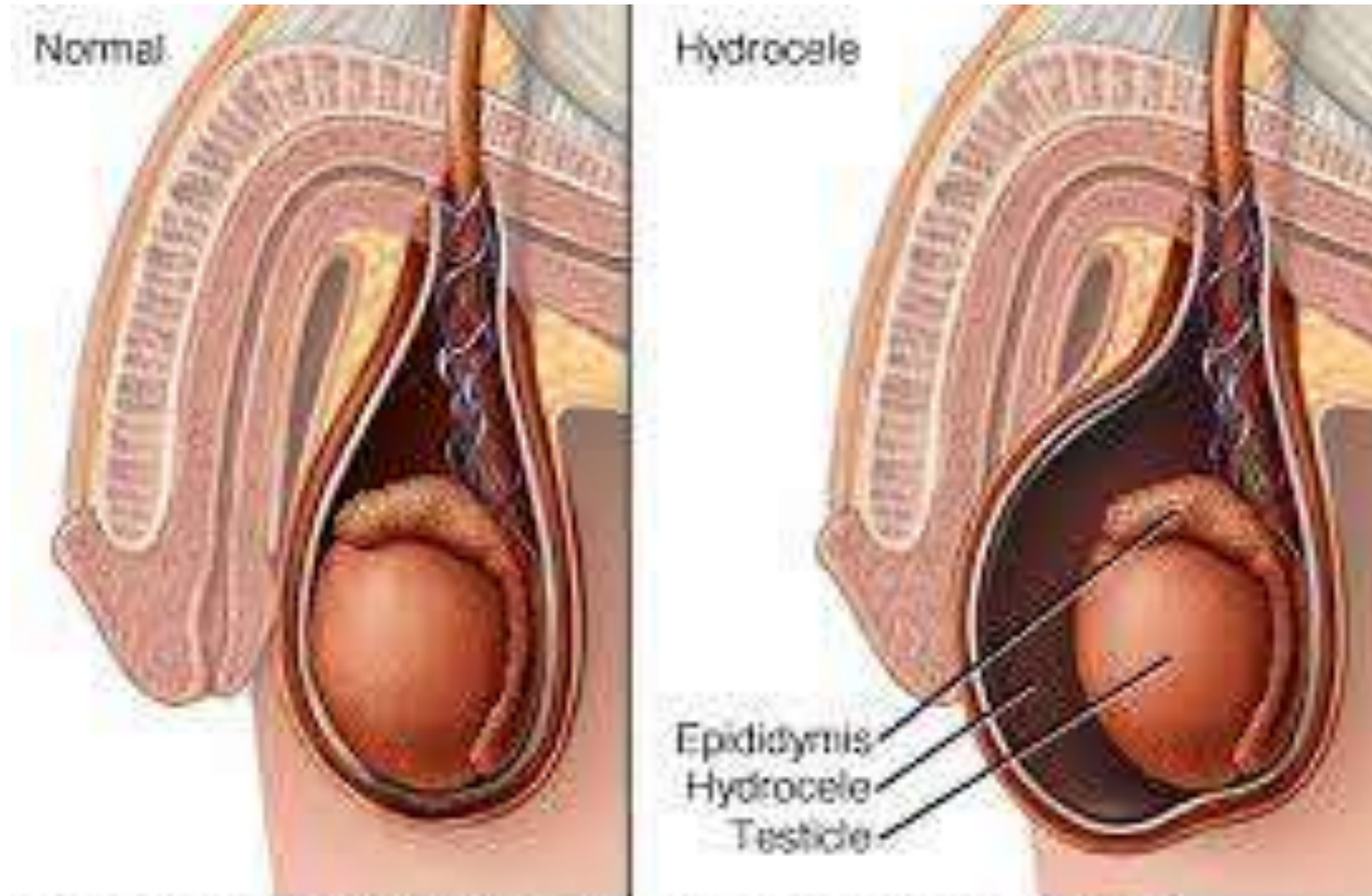


Communicating
Hydrocele

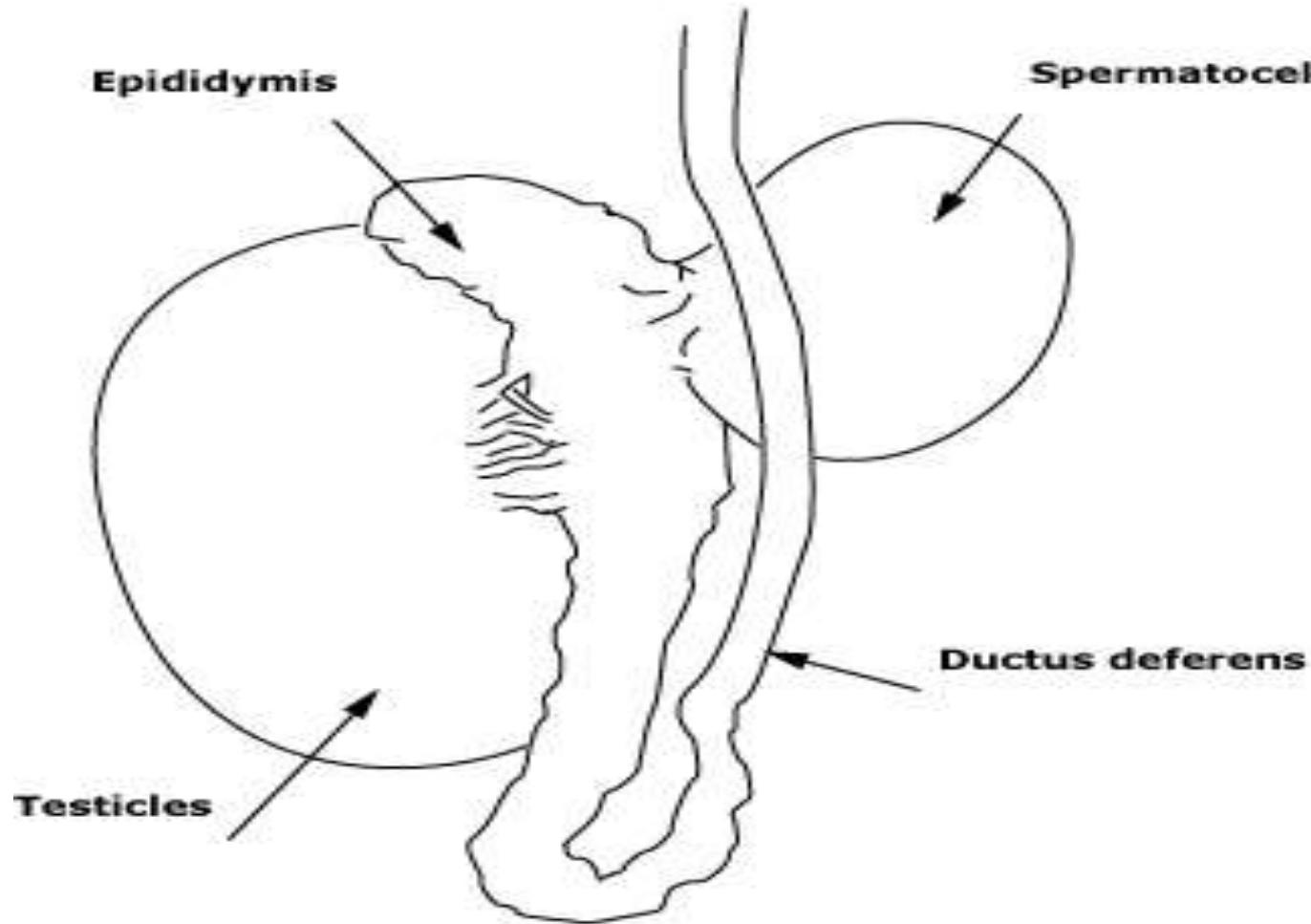




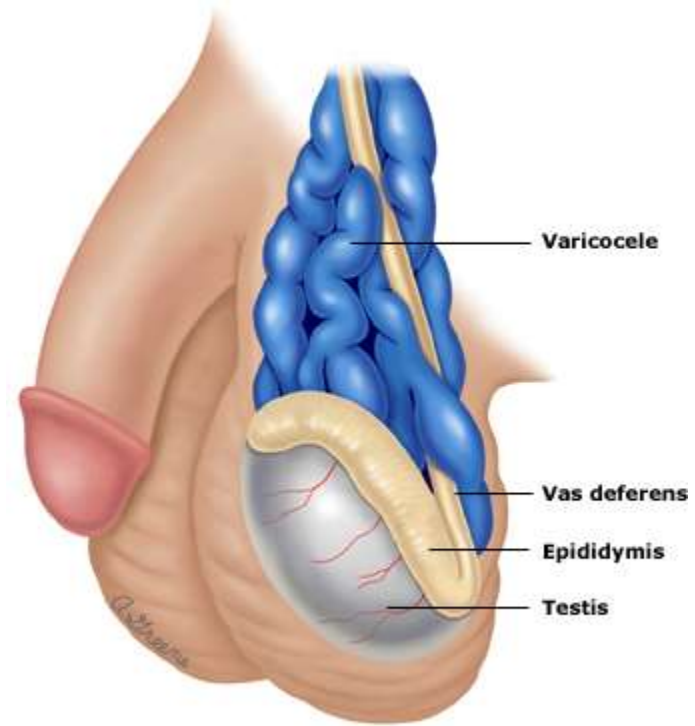
Hematocele



A spermatocele epididymal cyst is a painless, fluid-filled cyst of the epididymis. It can be palpated as distinct from the testis and mass.

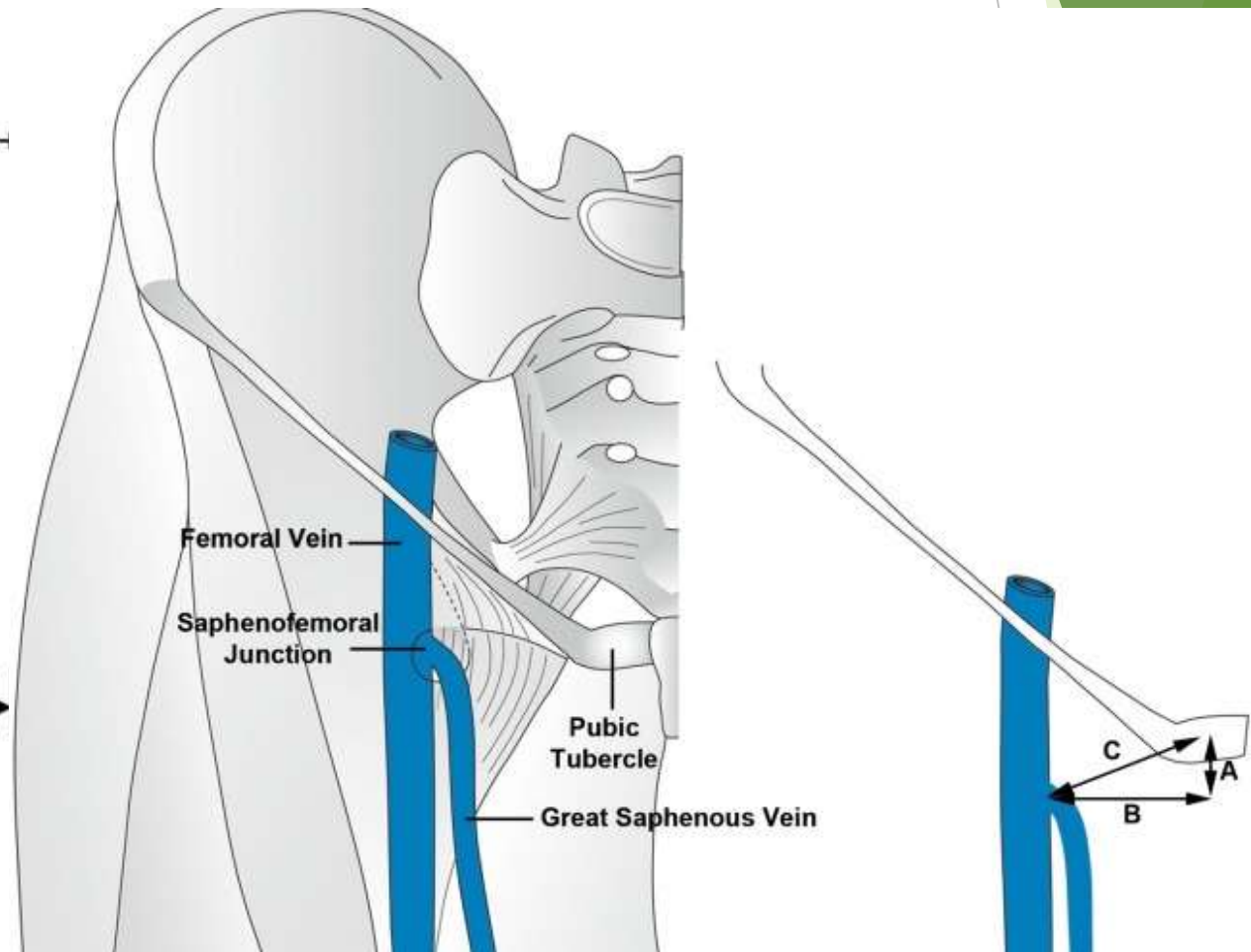
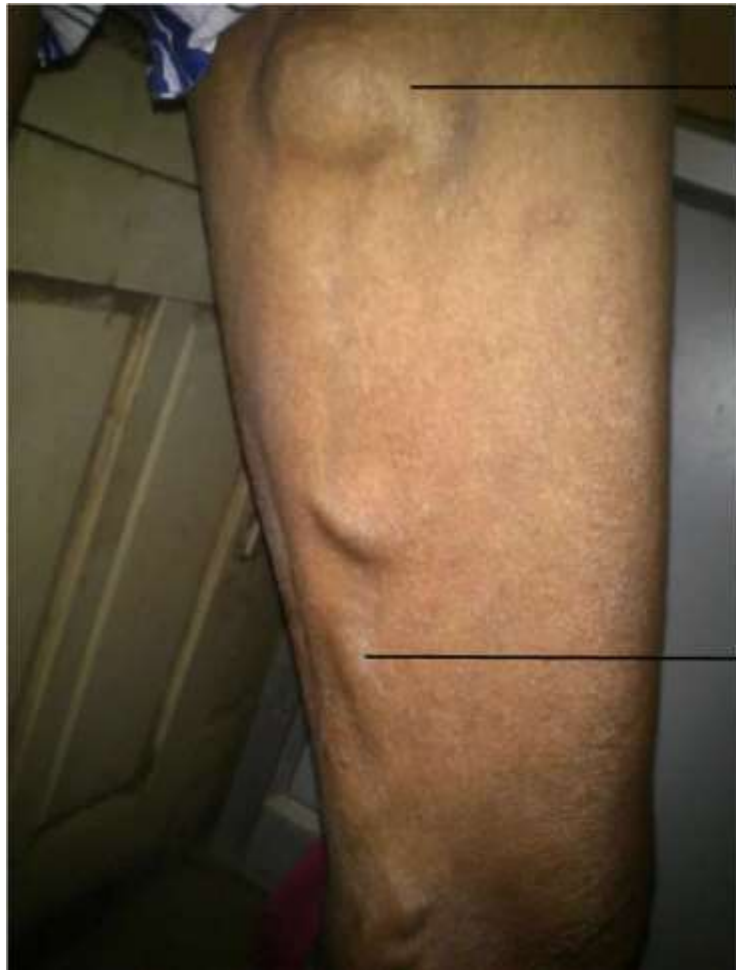

Vascular problem varicocele

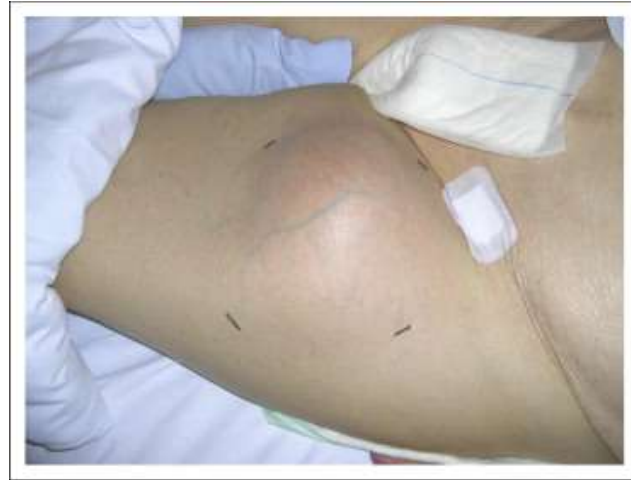

Vascular problem

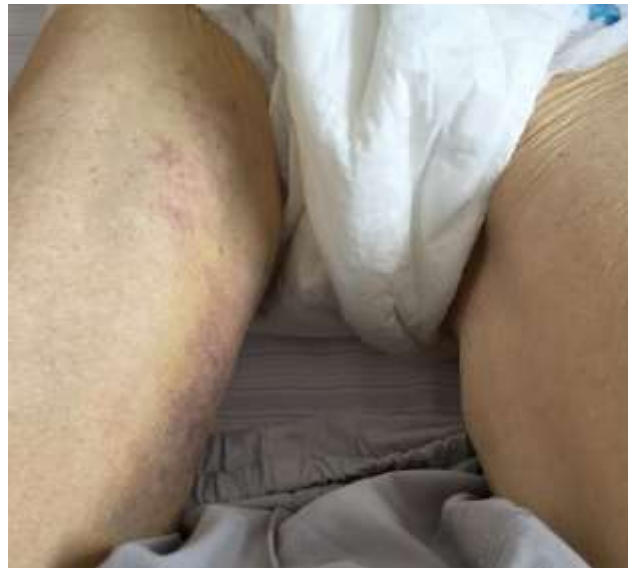Saphena varix



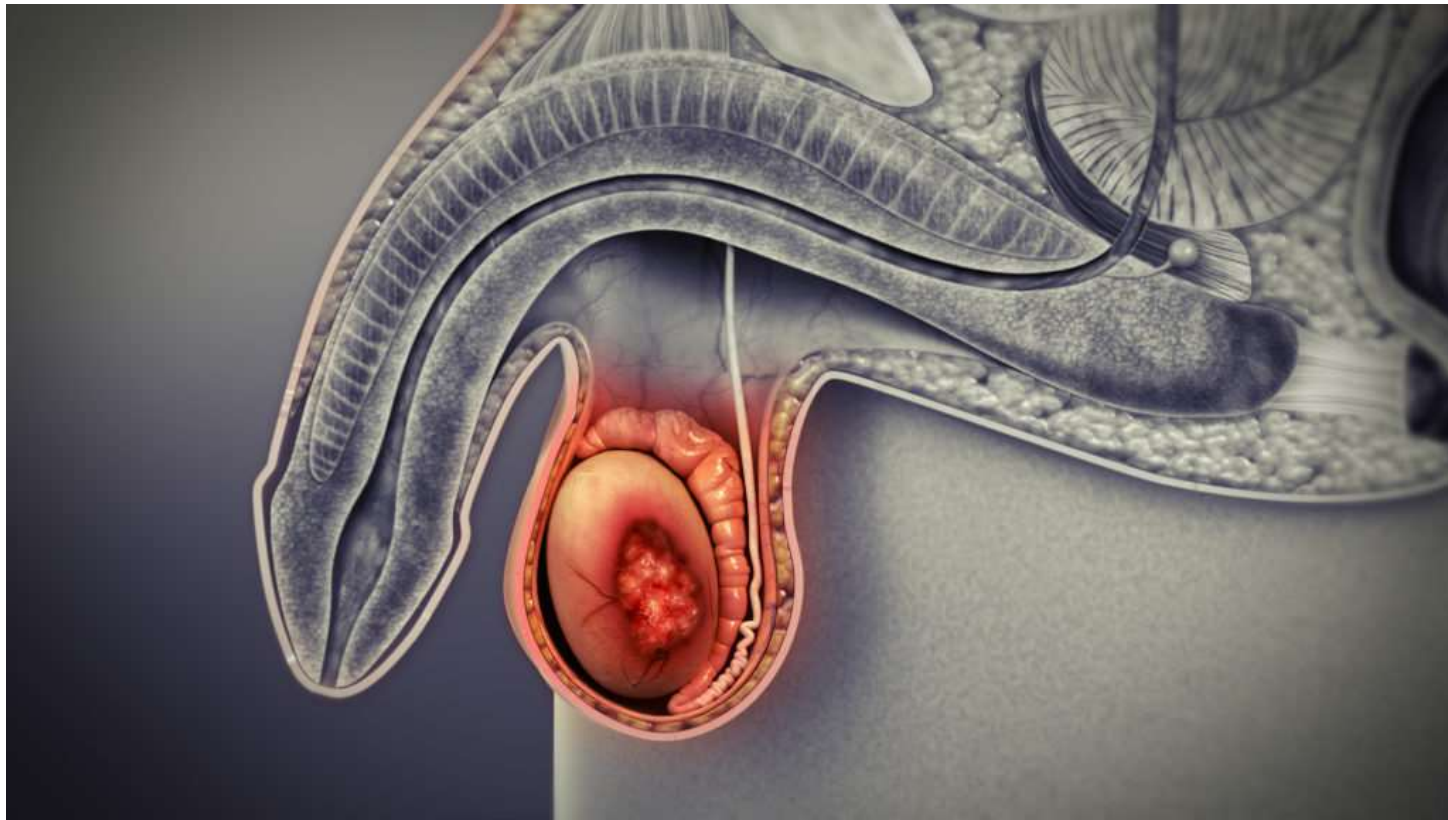
Femoral artery aneurysm



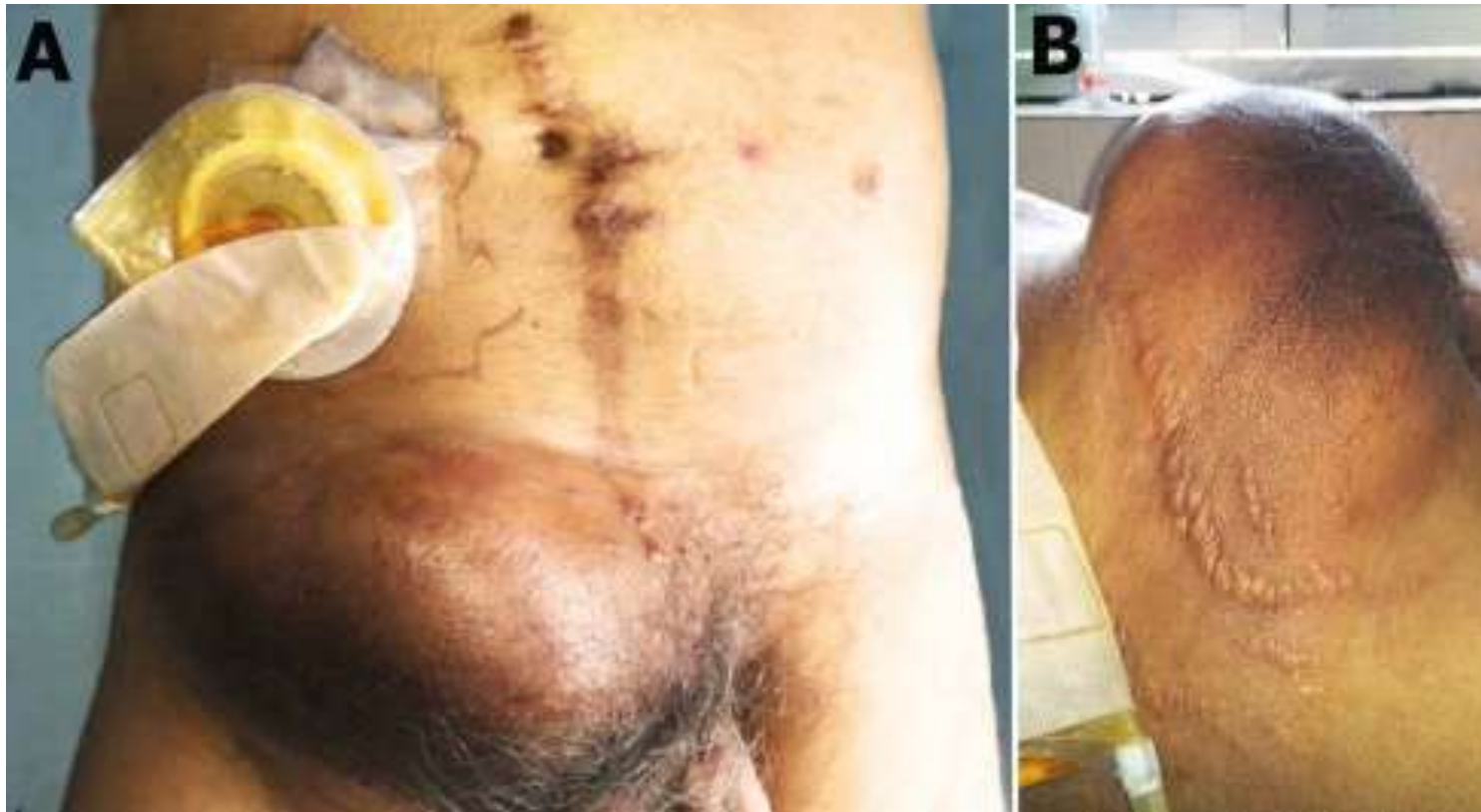Iliopsoas hematoma



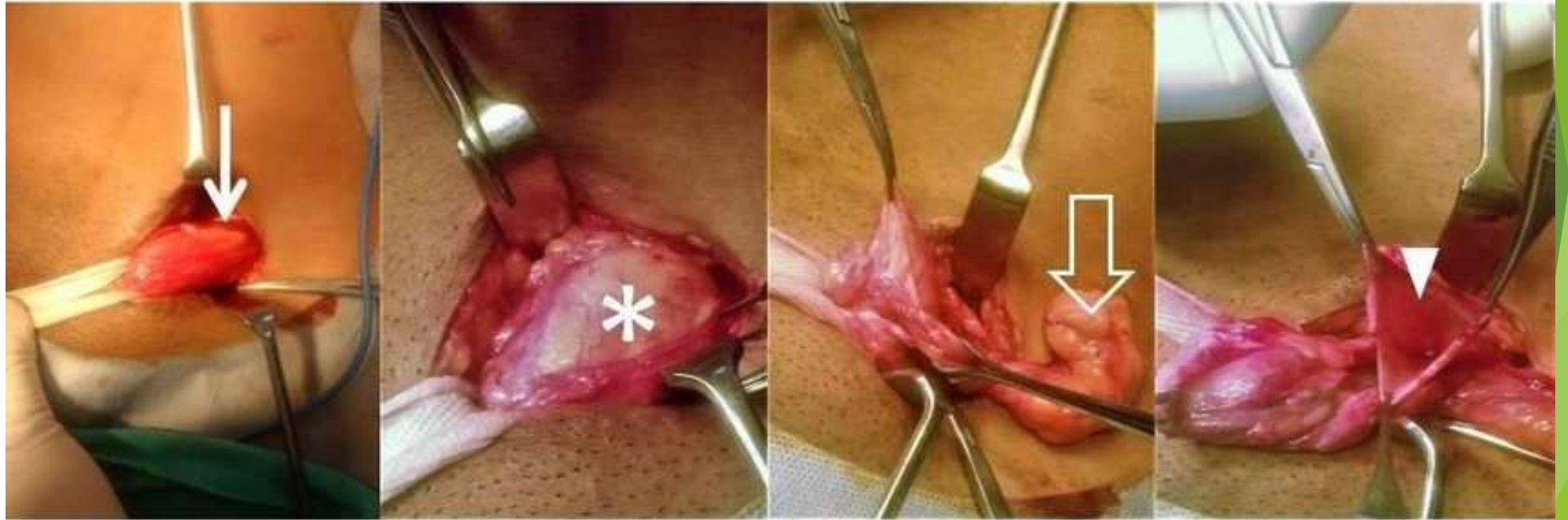
Tumor testicular cancer



Lymph node metastasis



Tumor benign



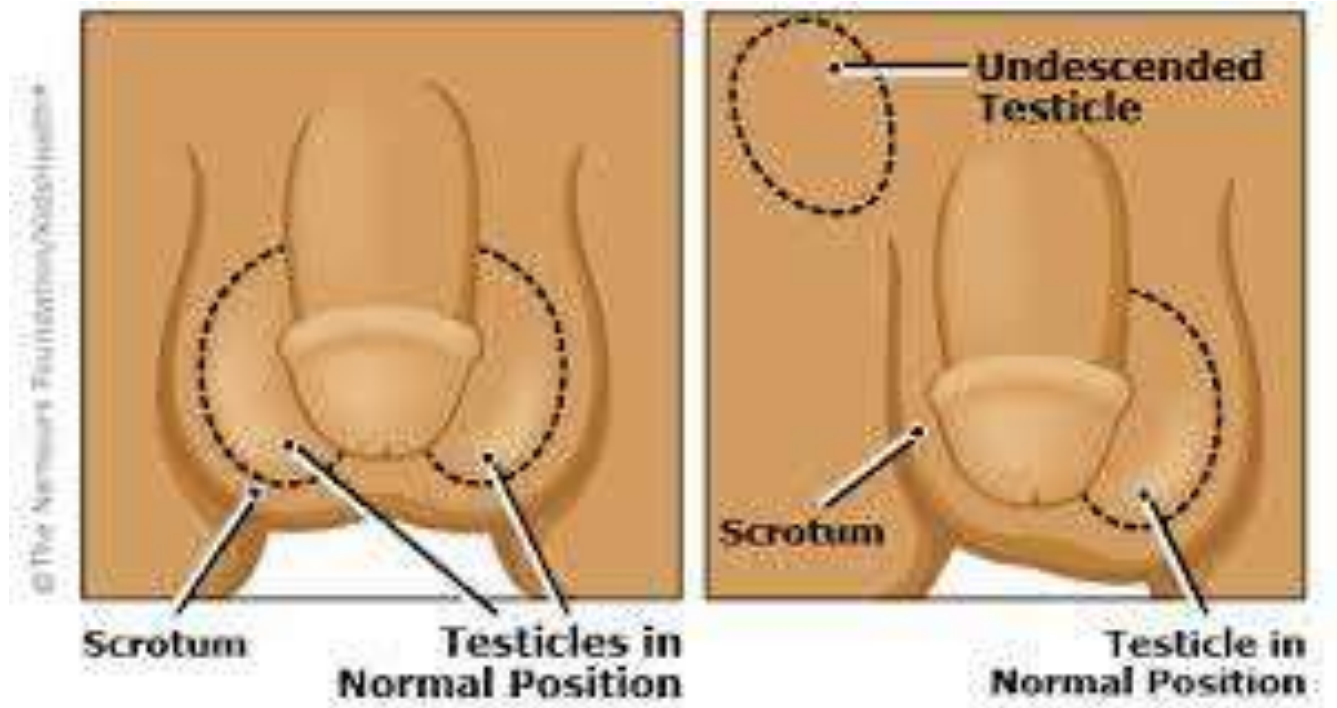
3a

3b

3c

3d

Undescended Testis



Fournier's gangrene

