

**6** A 65-year-old man complains of a persistent nosebleed. His physician uses a cotton swab to apply pressure at the source, the inferior and posterior aspects of the lateral nasal wall. Which artery is the most likely source of the bleeding?

- (A) Greater palatine
- (B) Infraorbital
- (C) Facial
- (D) Anterior ethmoidal
- (E) Sphenopalatine

The answer is E

**10**

A 68-year-old man was choking on a piece of steak at a family restaurant. Despite attempts to dislodge the food via abdominal thrusts (or the Heimlich maneuver), his upper airway remained blocked. An emergency medical technician (EMT), eating at the scene, performed an emergency tracheotomy to enable the man to breathe. Which subcutaneous structure was most likely cut during this procedure?

- (A) Cricoid cartilage
- (B) Thyrohyoid membrane
- (C) Cricothyroid membrane
- (D) Tracheal rings
- (E) Isthmus of thyroid gland

The answer is C

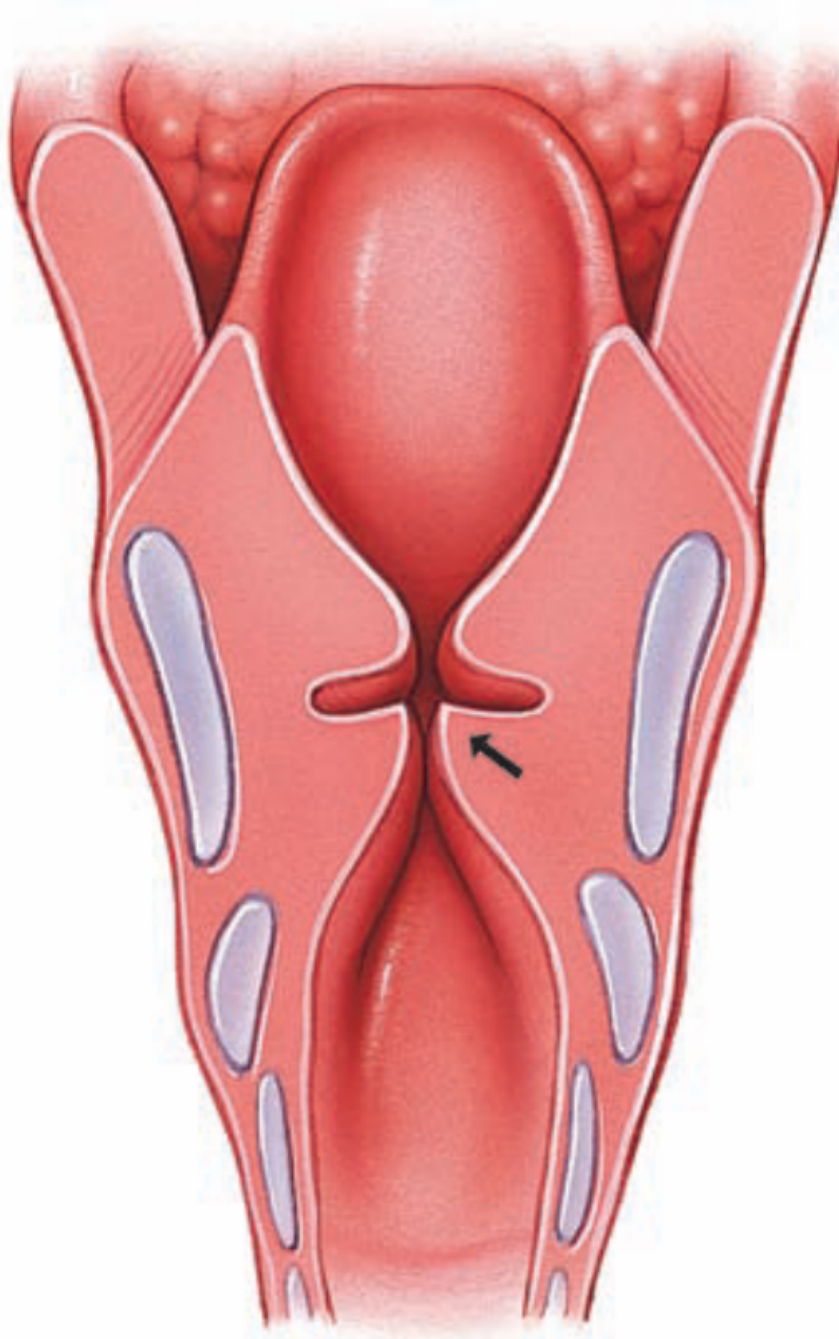
**12** A newborn infant exhibits labored, gasping breathes and unusual vocal tones when crying. Thorough examination reveals the child has malformed vocal folds due to displaced attachments of the vocal ligaments. Which of the following structures is most likely defective in this condition?

- (A) Arytenoid cartilages
- (B) Cricoid cartilage
- (C) Epiglottic cartilage
- (D) Corniculate cartilages
- (E) Cuneiform cartilages

The answer is A

15

A 60-year-old female yodeler with a 43-year history of smoking complains of pain during swallowing and hoarseness in her voice. A fiberoptic endoscopy reveals a laryngeal squamous cell carcinoma at the location identified by the arrow within the given figure. What structure is most likely affected by this laryngeal cancer?

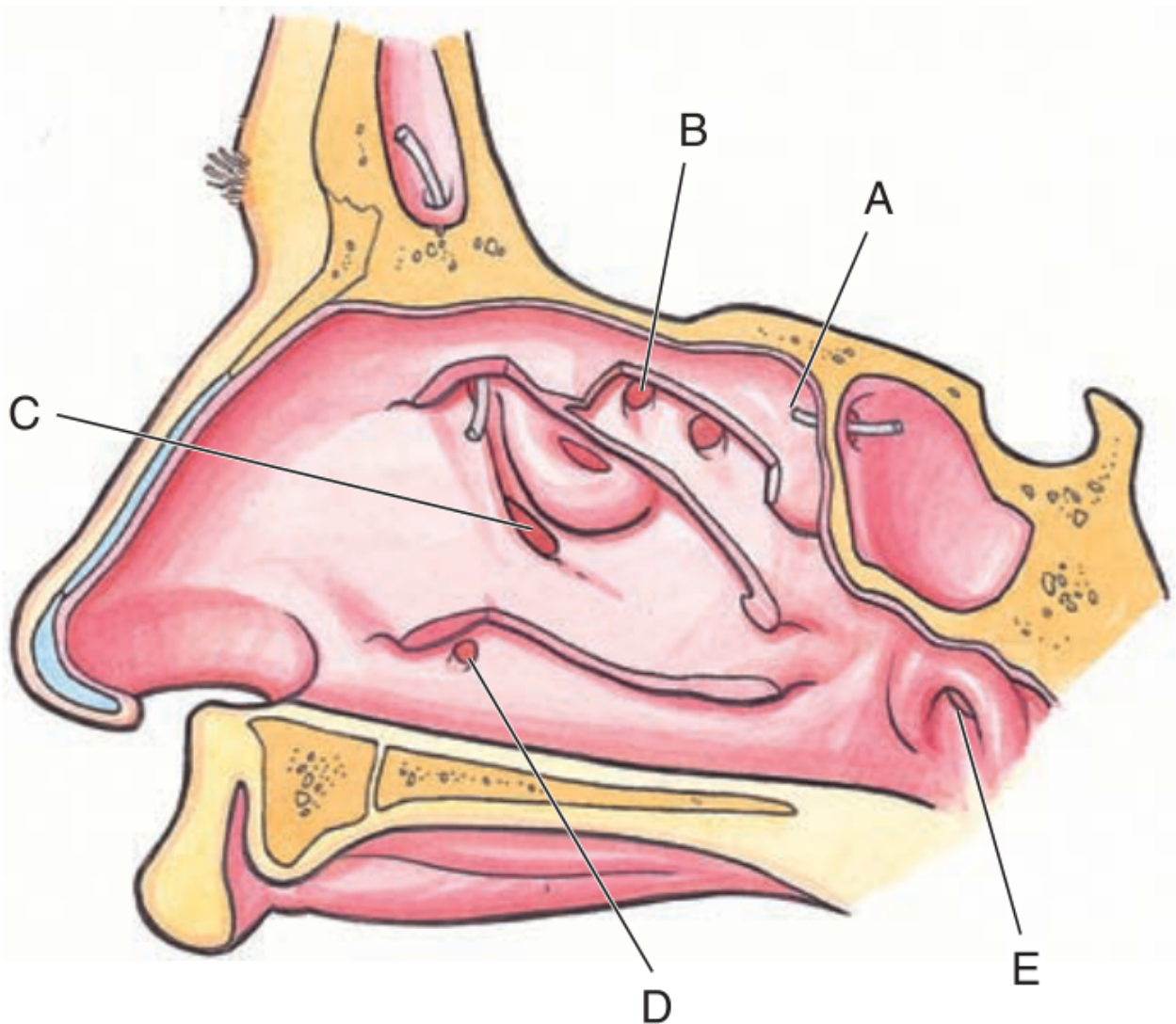


- (A) Infraglottic cavity
- (B) Vocal folds
- (C) Vestibular folds
- (D) Laryngeal vestibule
- (E) Epiglottis

The answer is B:

47

A 35-year-old man complains to his physician that he feels congested, has trouble with nasal breathing, and is experiencing a yellowish nasal mucus discharge. He also mentions that his right side upper molar teeth ache terribly. A thorough physical examination reveals maxillary sinusitis. The discharge from this sinus initially drains into the nasal cavity at which of the labeled points within this drawing of the lateral nasal wall?



The answer is C

**2** A 23-year-old man is stabbed in a bar fight. The blade of the knife enters his chest in the left 5th intercostal space, just lateral to the sternum, and pierces to a depth of approximately 4 cm. What structure is most likely damaged?

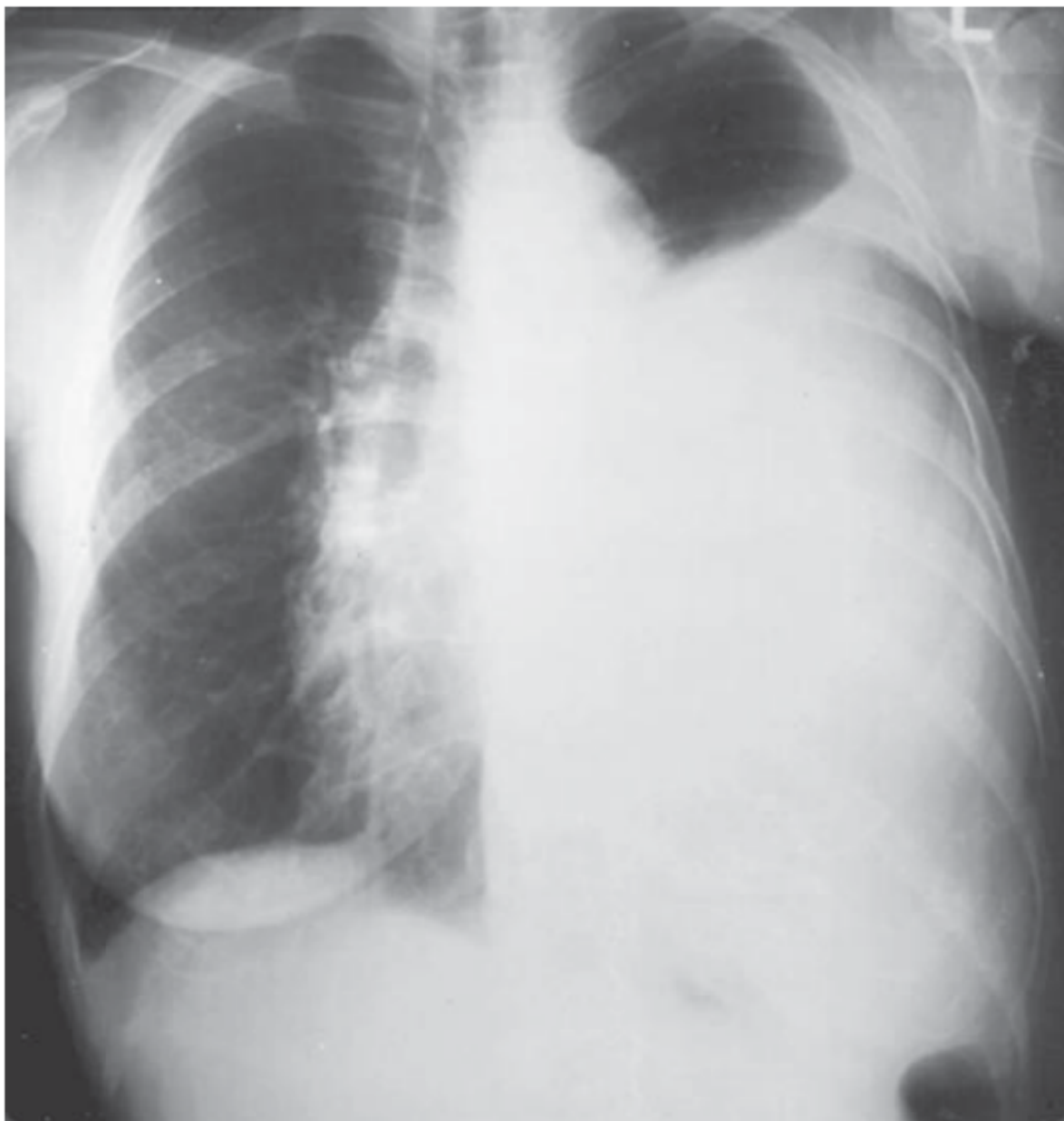
- (A) Left lung
- (B) Pulmonary trunk
- (C) Left bronchus
- (D) Stomach
- (E) Pericardium

The answer is E:



**5**

An 87-year-old woman with a history of metastatic adenocarcinoma of the breast presents with difficulty in breathing. A plain chest film reveals massive left pleural effusion, as noted in the photo. The physician chooses to drain the fluid with a thoracentesis. What is the proper location for placement of the cannula (hollow needle) to drain the pleural effusion?



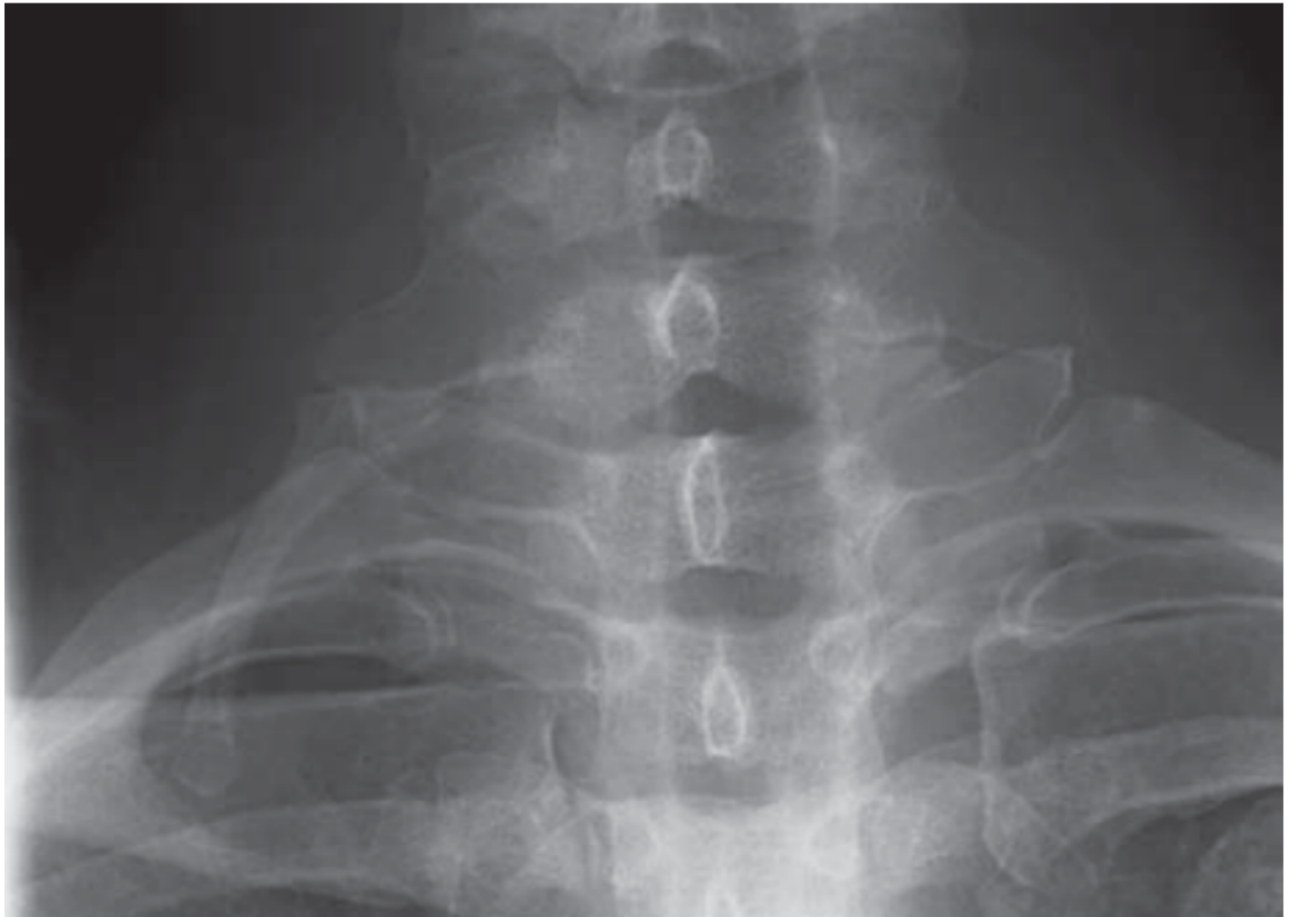- (A) Midaxillary line—6th intercostal space
- (B) Midaxillary line—9th intercostal space
- (C) Parasternal line—6th intercostal space
- (D) Parasternal line—2nd intercostal space
- (E) Midclavicular line—5th intercostal space

The answer is B



**11**

A 56-year-old construction worker comes to his family physician complaining of pain in the neck and shoulder, numbness and tingling in the right fingers, and a weak grip in his right hand. His symptoms are exacerbated by carrying heavy objects on his right shoulder. The given plain X-ray film indicates the presence of a right cervical (C7) rib in close approximation to the proximal part of the first rib. Given the signs and symptoms of this patient, what structure is most likely impinged by the cervical rib?



- (A) Right common carotid artery
- (B) Brachiocephalic trunk
- (C) Right subclavian artery
- (D) Vertebral artery
- (E) Right brachiocephalic vein

The answer is C

**26**

A young medical student finds herself at a moment of great relaxation during her pre-exam meditation. Which of the following events is characteristic of the inspiratory phase of normal, quiet respiration?

- (A) Diaphragm flattens
- (B) Intercostal muscles relax
- (C) Ribs lower
- (D) Abdominal wall muscles contract
- (E) Horizontal dimension of the rib cage decreases

The answer is A

**29**

A 25-year-old man is brought to the emergency room after suffering a deep stab wound directly through the right 5th intercostal space in the midclavicular line. Which of the following structures is most likely pierced?

- (A) Superior lobe of the lung
- (B) Lingula of the lung
- (C) Inferior lobe of the lung
- (D) Apex of the lung
- (E) Middle lobe of the lung

The answer is E

**35**

A 2-year-old boy comes to the ER due to accidental inhalation of a peanut. Which of the following sites is the most likely location for the aspirated peanut in the thorax?

- (A) Larynx
- (B) Carina of the trachea
- (C) Left main bronchus
- (D) Right main bronchus
- (E) Right upper lobar bronchus

The answer is D