

Necrosis

♥ It is an uncontrolled cell death that results in swelling of the cell organelles, plasma membrane rupture and eventual lysis of the cell, and spillage of intracellular contents into the surrounding tissue leading to tissue damage.

♥ Considered as culmination of reversible cell injury that cannot be corrected.

♥ Usually elicits a local host reaction, inflammation (due to the release of heat shock proteins, uric acid, ATP, DNA, and nuclear proteins).



♥ H&E is the combination of two histological stains: hematoxylin and eosin.

♥ The hematoxylin stains cell nuclei a purplish blue, and eosin stains the extracellular matrix and cytoplasm pink


Microscopic appearance of Necrotic dead cells: ♥ nuclear ♥ cytoplasmic

Cytoplasmic

♥ increased binding of eosin to denatured cytoplasmic proteins, loss of basophilic ribonucleic acid (RNA) in the cytoplasm .

♥ A glassy, homogeneous appearance, mostly because of the loss of lighter staining glycogen particles.

♥ cytoplasm vacuolated and appears "moth-eaten", due to enzymes



Nuclear changes

* Result from break down of DNA; appear as three patterns:

♥ Pyknosis: shrinkage and increased basophilia.

♥ Karyorrhexis: fragmentation of pyknotic nucleus

♥ Karyolysis: decrease basophilia of chromatin, DNAase: [deoxyribonuclease, DNA digestion].

In 1-2 days the nucleus in a dead cell may completely disappear.

Morphologic Patterns of Necrosis

♥ Coagulative necrosis ♥ Liquefactive necrosis


♥ Caseous necrosis ♥ Fat necrosis ♥ Fibrinoid necrosis

1. Coagulative necrosis

♥ proteins can denature [coagulate] to leave 'ghost' outlines behind. The dead cells lose their nuclei and may stain more intensely.

♥ The most common form of necrosis (particularly in myocardium, liver, kidney)

♥ characteristic of hypoxic cell death in all tissues except in the brain



2. Liquefactive necrosis

♥ Infiltration of dead tissue by large numbers of neutrophils leads to digestion of cell proteins. This leads to loss of normal tissue architecture and is known as liquefactive necrosis.

♥ Liquefactive necrosis is common after cell death in lipid- rich tissue such as the brain (cerebral infarction).

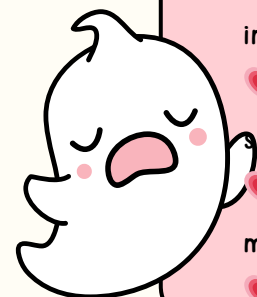
3. Caseous necrosis

♥ Type of necrosis that occur in the center of granulomas, typically seen in mycobacterial infection.

♥ Granulomas are aggregates of epithelioid macrophages and giant cell macrophages, often surrounded by lymphocytes.

♥ Granulomas are found as a response to foreign bodies, in some autoimmune diseases, and in mycobacterial infection (e.g. M.tuberculosis).

♥ Gross morphology of caseous necrosis appear as cheese-like.



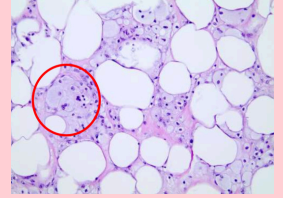
4. Fat necrosis

♥ a pattern of necrosis that occurs due to degradation of fatty tissue by lipases (released from dead cells) to form chalky deposits.

♥ This can be seen in acute pancreatitis (acute inflammation of the pancreas causing necrosis of pancreatic acinar cells and lipase release), or from trauma to fatty tissues.



fatty acids bind and precipitate calcium * foamy macrophages adjacent to adipose tissue ions, forming insoluble salts.




5. Fibrinoid necrosis

♥ increased binding of eosin to denatured cytoplasmic proteins, loss of basophilic ribonucleic acid (RNA) in the cytoplasm.

♥ A glassy, homogeneous appearance, mostly because of the loss of lighter staining glycogen particles.

♥ cytoplasm vacuolated and appears "moth-eaten", due to enzymes



وَأَنْ لَّيْسَ لِلْإِنْسَانِ إِلَّا مَا سَعَى

Fate of Necrosis

♥ Most of necrotic tissue is removed by leukocyte (Phagocytosis) combined with extracellular enzyme digestion

♥ If necrotic tissue is not eliminated

♥ it attracts Ca^{++} salts

♥ dystrophic calcification



Leakage of intracellular proteins through the damaged cell membrane and ultimately into the circulation provides a means of detecting tissue-specific necrosis using blood or serum samples:

